

Tubulointerstitial Nephritis and Uveitis Syndrome in an Elderly Man

Case Report and Literature Review

Wen-hui Lei, MD, Jun Xin, MD, Xue-ping Yu, MD, Jie Li, MD, Ming-feng Mao, MD, Jian-song Ji, MD, Chui-fen Wu, MD, Chao-yong Zhu, MD, and Lie Jin, MD

Abstract: Tubulointerstitial nephritis and uveitis (TINU) syndrome is a rare disease of unknown etiology defined by the combination of tubulointerstitial nephritis, uveitis, and biochemical abnormalities. It has been reported that TINU mainly affects adolescents and young women. Here we reported a special case regarding a 60-year-old man with acute renal failure due to TINU syndrome documented by renal biopsy.

We present a rare case of an elderly patient, who had been suffering from a fever for 2 weeks, characterized by sudden onset and resolving spontaneously, and accompanied by extreme fatigue, loss of appetite, and shivering. Renal biopsy showed a tubulointerstitial nephritis, with polymorphonuclear infiltration and acute tubulitis. In the outpatient clinic, he was diagnosed with idiopathic bilateral anterior uveitis 1 month ago. Ophthalmological examination revealed anterior asymptomatic bilateral uveitis. Human leukocyte antigen (HLA) typing (HLA-DQA1*0101/0201 and HLA-DQB1*0303/0503) was found which supported the suspect of TINU syndrome. The patient was treated with oral prednisone (1 mg/kg) and continued for 8 weeks on tapering doses. Serum creatinine normalized within 3 and 6 months later renal function also recovered completely.

Editor: Muhammed Mubarak.

Received: August 21, 2015; revised: October 25, 2015; accepted: October 27, 2015.

From the Department of Nephrology, Lishui Hospital of Zhejiang University, Lishui, Zhejiang Province (W-hL, JL, M-FM, C-YZ, LJ); Department of Infection Diseases and Department of Urology, The first hospital of Quanzhou affiliated to Fujian Medical University, Fujian Province (X-PY, JX); and Department of Radiology, Lishui Hospital of Zhejiang University, Zhejiang Province, People's Republic of China (J-SJ), Department of Nephrology, Qingyuan county people's hospital, Lishui, Zhejiang Province, China (C-FW).

Correspondence: Lie Jin, Department of Nephrology, Lishui Hospital of Zhejiang University, Lishui, Zhejiang Province 323000, People's Republic of China (e-mail: lsjingl@yeah.net). Jun Xin, Department of Urology, The first hospital of Quanzhou affiliated to Fujian Medical University, Quanzhou 362000, Fujian, China (e-mail:15859516868@163.com).

Chao-yong Zhu, Department of Nephrology, Lishui Hospital of Zhejiang University, Lishui, Zhejiang Province 323000, People's Republic of China (e-mail: zcy5714@126.com) Chui-fen Wu, Department of Nephrology, Qingyuan County People's hospital, Lishui, Zhejiang Province, China (E-mail: zjqywf@163.com).

Jun Xin, Chao-yong Zhu, and Chui-fen Wu are Co-corresponding author.

There was no financial support or funding for this case report. Informed patient consent was obtained for publication of this case report.

The authors have no conflicts of interest to disclose.

W-hL and CZ planned the article and contributed to data collection, discussing content, writing, and reviewing the article. LJ, XY, JL, JX, C-FW and MM conceived the study, participated in its design, study supervision, and helped to write the article.

Copyright © 2015 Wolters Kluwer Health, Inc. All rights reserved.

This is an open access article distributed under the Creative Commons Attribution-NoDerivatives License 4.0, which allows for redistribution, commercial and non-commercial, as long as it is passed along unchanged and in whole, with credit to the author.

ISSN: 0025-7974

DOI: 10.1097/MD.0000000000002101

This case highlights that TINU syndrome is probably an underdiagnosed disease responsible for some cases of idiopathic anterior uveitis in elderly male patients. It is of critical importance to be aware of this syndrome by nephrologist and ophthalmologists in this special population. Further studies are needed to elucidate clinical characteristic and pathogenesis of TINU syndrome in elderly population.

(*Medicine* 94(47):e2101)

Abbreviations: AIN = acute tubulointerstitial nephritis, BUN = blood urea nitrogen, CRP = C-reactive protein, ESR = erythrocyte sedimentation rate, GFR = glomerular filtration rate, HLA = human leukocyte antigen, n.v. = normal values, WBC = white blood count.

INTRODUCTION

Tubulointerstitial nephritis and uveitis (TINU) syndrome is a relatively uncommon disease combined with the development of acute tubulointerstitial nephritis (AIN) and uveitis. It was first reported by Dobrin et al¹ in 1975, since then, many clinicians have submitted case reports to journals around the world. Many clinicians have inferred that TINU syndrome is an immunological abnormality. The median age of onset is 15 and there is a female predominance. In 2001, Mandeville et al² reviewed 133 published cases of TINU syndrome showing a median age at presentation of 15. Most patients with TINU syndrome are young women and adolescents. However, to our knowledge, only several cases of TINU syndrome in the elderly were described in the medical literature. Here, we report the case of 60-year-old man with TINU syndrome who presented with acute renal failure.

CASE PRESENTATION

A 60-year-old Asian man was referred to the nephrology clinic with a 2-week history of fever characterized by rapid spontaneous resolution in a few hours, and accompanied by extreme fatigue, loss of appetite, and shivering. He was treated with ceftriaxone sodium (2.0 g/day) for 5 days, with defervescence but aggravation of weight loss and fatigue. He presented to an Ophthalmic Emergency Department and was diagnosed with bilateral anterior uveitis 1 month ago. He was treated with local steroids and the uveitis resolved rapidly. His past medical history was unremarkable. His family history was not noteworthy. No one in the family presented genetic disease, neither renal nor ocular disease. Blood and urine tests were normal according to previous laboratory investigations.

At the first admission, he was afebrile and the physical examination was normal. His weight was 60 kg, height was 170 cm, and his blood pressure was 130/60 mm Hg. His laboratory test results revealed acute renal failure (blood urea nitrogen [BUN]: 24 mg/dL; creatinine, 2.5 mg/dL; creatinine clearance,

58 mL/minute/1.73 m²). Erythrocyte sedimentation rate (ESR) (90 mm/hour) and C-reactive protein (CRP) (45 mg/dL) were increased. Test results showed that serum calcium, phosphorus, other electrolytes, liver function, and blood gas values were also normal. Whole blood counts revealed elevated white count of 12,300/mm³ but with no evidence of anemia or thrombocytopenia. Urinalysis showed low urine osmolality (390 mOsm/kg), nonnephrotic proteinuria (0.60 g/L), urinary pH 6.5, normoglycemic glycosuria (>500 mg/dL), and moderate hematuria (40 cells/ μ l), microalbuminuria (0.08 g/L) with normal proteinemia, alpha-1 (0.08 g/mL, n.v. < 0.01) and high values of beta-2 microglobulin (4.0 mg/L, n.v. 0.8–2.2). Urine cultures showed no evidence of microbial growth. Antineutrophil cytoplasmic (ANCA), antinuclear (ANA), and C3 and C4 levels were normal. All these findings were consistent with acute interstitial nephritis. In order to make a differential diagnosis, tests and CT scans of the lung were performed. Sarcoidosis that is one of the etiologic factors was not found. Renal sonography and voiding cystography were unremarkable. A renal biopsy was performed. The biopsy specimen revealed dense variable eosinophils, plasmacytes, and lymphocytes in the interstitium and tubulitis in the tubule as well as hyaline cylinders and focal debris in the tubule (Figures 1–3). Glomerular structures were normal. Immunofluorescence microscopy revealed that immunoglobulin A and M staining at the tubular level was negative. There were no vascular lesions. Renal biopsy was consistent with tubulointerstitial nephritis.

To complete the diagnostic workup of tubulointerstitial nephritis, an ophthalmic examination was performed and we identified fine keratic precipitations which was consistent with previous anterior bilateral uveitis. The suspect of TINU syndrome was further supported by human leukocyte antigen (HLA) typing presence of HLADQA1*0101/0201 and HLADQB1*0303/0503. The patient received 1 mg/kg of prednisone for 4 weeks, and then the dose was tapered and discontinued within 2 months. His kidney function improved after a period of prednisone therapy. After about 8 weeks of treatment, urea (20 mg/dL) and creatinine (0.85 mg/dL), (glomerular filtration rate—GFR 76 mL/minute/1.73 m²) levels returned to normal. Urine analysis, proteinuria, and glycosuria improved rapidly. There were no relapses of uveitis or ocular complications during follow-up of 6 months.

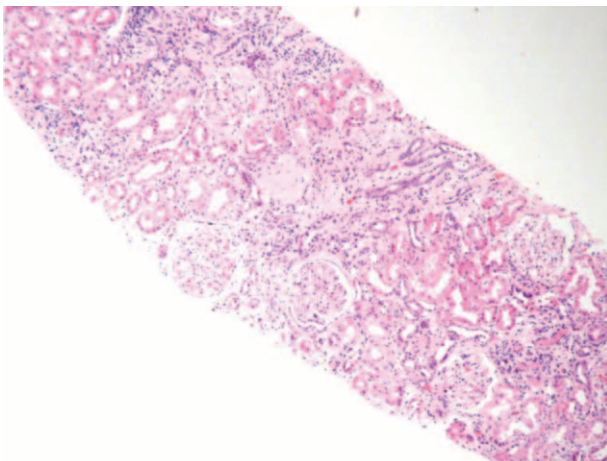


FIGURE 1. Interstitial mixed inflammatory infiltration, tubulitis. Hematoxylin–eosin 100 \times .

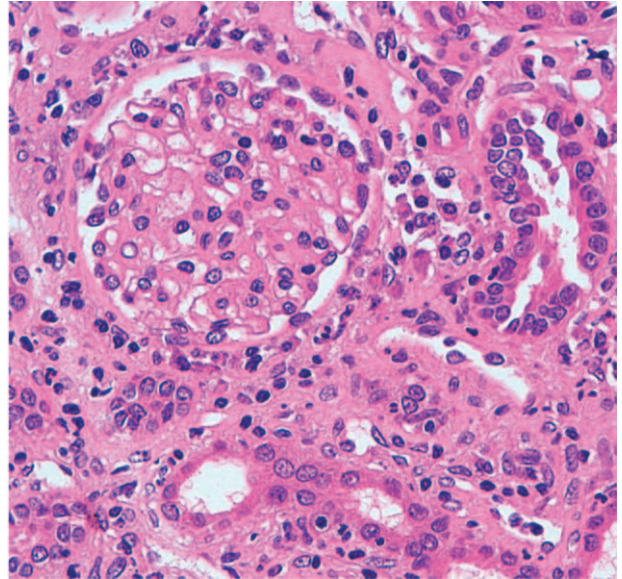


FIGURE 2. Mixed inflammatory infiltrate between the cortical tubules (lymphocytes, plasma cells, histiocytes, and polymorphs). Hematoxylin–eosin 400 \times .

DISCUSSION

TINU syndrome is characterized by the association of interstitial nephritis and uveitis. It is a rare autoimmune condition defined by the combination of tubulointerstitial nephritis, uveitis, and biochemical abnormalities.³ Systemic symptoms such as fatigue, fever, arthralgia, and weight loss may predominate. Fewer than 200 cases have been reported in the medical literature. No standard diagnostic criteria have been established for this syndrome, because of the limited number of cases. But Mandeville et al² proposed the first diagnostic criteria based on a review of 133 reported cases in 2001. To ultimately confirm the diagnosis, the criteria require extensive clinical evidence of AIN or histopathological confirmation and bilateral anterior uveitis 12 months after onset of AIN or within 2 months before

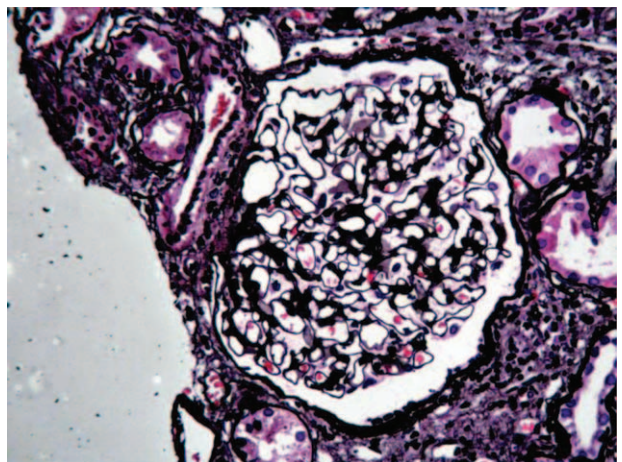


FIGURE 3. Objective photomicrograph shows an interstitial inflammatory process with associated tubulitis. The glomeruli show ischemic change with tuft shrinkage and wrinkling of the capillary loops with mild arteriolar intimal wall thickening. Periodic acid-Schiff (PAS) stained 400 \times .

with no other known systemic diseases to cause interstitial nephritis or uveitis. The literature had demonstrated a strong association of HLA-DQB1*05, HLA-DQA1*01, and HLA-DQB1*01 with TINU.⁴⁻⁶ Our patient's clinical features and laboratory test results (biopsy-proven AIN, HLA typing, and onset of typical bilateral uveitis 1 month before the diagnosis of AIN) were in accord with these proposed diagnostic criteria. However, in the present case, duration between the onset of disease and the initiation of the therapy is too long (55 days). Early diagnosis of TINU syndrome is of critical importance for nephrologist to cure this disease.

Patients with TINU syndrome present with nonspecific systemic manifestations including² fever, fatigue, headache, malaise, weight loss, myalgia, and arthralgia. Renal manifestations⁷ include flank pain, hematuria, sterile pyuria, proteinuria, renal insufficiency, and/or acute kidney injury (AKI). Literature reported^{8,9} that urinary β 2-microglobulin was increased in patients with TINU syndrome. We also detected increased β 2-microglobulin levels in our case. However, the nonspecific systemic manifestations such as myalgia, arthralgia, flank pain, and headache were not seen in our case.

TINU syndrome is a disease of adolescent. This disorder affects primarily young females with about 3 times as many females as males developing the syndrome.² Goda et al⁸ reported that patients was at a median age of 21 and females accounted for 83% of the cases by reviewing the clinical features in 12 patients with TINU syndrome. A limited number of studies described TINU syndrome in elderly man with acute renal failure. The previously described cases^{7,10-15} in patients aged 60 and older shows that the clinical and laboratory findings do not differ significantly from classic TINU syndrome in younger individuals. In the present case, the patient also presented with nonspecific systemic manifestations such as fever, fatigue, and weight loss, which was consistent with previous literature. Also, histological findings and biochemical findings did not differ significantly from other literature. However, this man presented at an unusually older age, and to the best of our knowledge, few cases of TINU syndrome in aged man were described and he is a rare case of TINU syndrome in a male individual aged 60 and older.

Standard treatment has not been established for TINU syndrome. Patients with progressive renal failure got typical treatment of prednisone for 3 to 6 months.¹⁶ Early steroid administration (usually prednisone 1 mg/kg/day for 2 or 3 weeks, followed by gradually tapering dose over 3 or 4 weeks) may be required to reduce the extent of inflammatory infiltrates and subsequent fibrosis.^{8,17} No randomized controlled trials have supported the use of corticosteroids in the treatment of AIN. However, some literature reported that renal function typically improved within few days after initiation of corticosteroids therapy.

So we decided to use steroid administration (1 mg/kg/day) after having obtained bioptic evidence of tubulointerstitial nephritis. Prognosis was favorable, with rapidly improved renal function and disappearance of clinical symptoms. Thus, prednisone was progressively tapered without recurrence of either nephritis or uveitis. But Li et al¹⁸ reported that patients with TINU tended to have a high rate of recurrence and most patients had incomplete renal recovery in Chinese adults. Luckily, the patients in our case had complete renal recovery. However, the incidence of relapse, the relapse-free interval and underlying complications are uncertain, because it was just a 6 months follow-up study. Further recognition and study of this disorder

are needed to better understand the clinical characteristics of TINU syndrome in the elderly.

CONCLUSIONS

In summary, this case study on TINU syndrome in an elderly man who presented with acute renal failure. However, to our knowledge, only a limited number of studies of TINU syndrome in older age had been reported in the medical literature. Early diagnosis of TINU syndrome in the elderly is challenging. Thus, the present experience shows that it is important to early diagnose and treat this reversible disease in the old. Further recognition and study of this disorder are needed to understand its etiology and pathogenesis in this special population.

REFERENCES

- Dobrin RS, Vernier RL, Fish AL. Acute eosinophilic interstitial nephritis and renal failure with bone marrow-lymph node granulomas and anterior uveitis. A new syndrome. *Am J Med.* 1975;59:325-333.
- Mandeville JT, Levinson RD, Holland GN. The tubulointerstitial nephritis and uveitis syndrome. *Surv Ophthalmol.* 2001;46:195-208.
- Paladini A, Venturoli V, Mosconi G, et al. Tubulointerstitial nephritis and uveitis syndrome in a twelve-year-old girl. *Case Rep Pediatr.* 2013;2013:652043.
- Mackensen F, David F, Schwenger V, et al. HLA-DRB1*0102 is associated with TINU syndrome and bilateral, sudden-onset anterior uveitis but not with interstitial nephritis alone. *Br J Ophthalmol.* 2011;95:971-975.
- Levinson RD, Park MS, Ridders SM, et al. Strong associations between specific HLA-DQ and HLA-DR alleles and the tubulointerstitial nephritis and uveitis syndrome. *Invest Ophthalmol Vis Sci.* 2003;44:653-657.
- Li JY, Yong TY, Bennett G, et al. Human leucocyte antigen DQ alpha heterodimers and human leucocyte antigen DR alleles in tubulointerstitial nephritis and uveitis syndrome. *Nephrology (Carlton, Vic).* 2008;13:755-757.
- Weinstein O, Tovbin D, Rogachev B, et al. Clinical manifestations of adult tubulointerstitial nephritis and uveitis (TINU) syndrome. *Int Ophthalmol.* 2010;30:621-628.
- Goda C, Kotake S, Ichiishi A, et al. Clinical features in tubulointerstitial nephritis and uveitis (TINU) syndrome. *Am J Ophthalmol.* 2005;140:637-641.
- Azar R, Verove C, Boldron A. Delayed onset of uveitis in TINU syndrome. *J Nephrol.* 2000;13:381-383.
- Han JM, Lee YJ, Woo SJ. A case of tubulointerstitial nephritis and uveitis syndrome in an elderly patient. *Korean J Ophthalmol.* 2012;26:398-401.
- Yasuda K, Sasaki K, Yamato M, et al. Tubulointerstitial nephritis and uveitis syndrome with transient hyperthyroidism in an elderly patient. *Clin Exp Nephrol.* 2011;15:927-932.
- Salu P, Stempels N, Vanden Houste K, et al. Acute tubulointerstitial nephritis and uveitis syndrome in the elderly. *Br J Ophthalmol.* 1990;74:53-55.
- Cacoub P, Deray G, Le Hoang P, et al. Idiopathic acute interstitial nephritis associated with anterior uveitis in adults. *Clin Nephrol.* 1989;31:307-310.
- Gafter U, Kalechman Y, Zevin D, et al. Tubulointerstitial nephritis and uveitis: association with suppressed cellular immunity. *Nephrol Dial Transplant.* 1993;8:821-826.

15. Ramakrishnan S, Dilip R. Syndrome of tubulointerstitial nephritis and uveitis. *J Assoc Physicians India*. 2009;57:177–179.
16. Takemura T, Okada M, Hino S, et al. Course and outcome of tubulointerstitial nephritis and uveitis syndrome. *Am J Kidney*. 1999;34:1016–1021.
17. Pusey CD, Saltissi D, Bloodworth L, et al. Drug associated acute interstitial nephritis: clinical and pathological features and the response to high dose steroid therapy. *Q J Med*. 1983;52:194–211.
18. Li C, Su T, Chu R, et al. Tubulointerstitial nephritis with uveitis in Chinese adults. *Clin J Am Soc Nephrol*. 2014;9:21–28.