


CASE REPORT

Open Access



Successful laparoscopic repair for reduction en masse of infantile inguinal hernia: a case report of this rare condition

Keisuke Yano¹, Koshiro Sugita¹, Koji Yamada¹, Mayu Matsui¹, Waka Yamada^{1,2}, Chihiro Kedoin¹, Masakazu Murakami¹, Toshio Harumatsu¹, Shun Onishi¹, Takafumi Kawano¹, Mitsuru Muto¹ and Satoshi Ieiri^{1*} 

Abstract

Background: Reduction en masse (REM) is a rare condition following manual inguinal hernia (IH) reduction in which a hernia sac is reduced back into the preperitoneal space with a loop of the bowel incarcerated at the neck of the sac. It resembles successful manual reduction and may thus be overlooked easily. We herein report an infantile case of REM of an IH that was successfully treated laparoscopically.

Case presentation: A 10-month-old boy with a surgical history of bilateral open IH repair at 4 months old presented with a bulge in his left groin and vomiting. A left incarcerated recurrent IH was suspected, and manual reduction was performed. The hernia was apparently reduced successfully, but abdominal distention and vomiting persisted. He was admitted for further observation due to the symptoms. On day 2 after admission, abdominal X-ray showed extensive small bowel obstruction (SBO). Enhanced computed tomography (CT) revealed protrusion of the small bowel with a closed-loop in the left groin. A closed-loop SBO due to postoperative adhesion or an internal hernia was suspected. To assess the etiology of SBO, emergent laparoscopic exploration with hernia repair was planned. Laparoscopy revealed REM of the left incarcerated IH with a thickened peritoneum at the neck of the sac. Laparoscopic reduction was performed, and the incarcerated small bowel showed no signs of ischemia. The hernia sac was not associated with the previously ligated processes vaginalis, which had been closed by a previous Potts' procedure. It was located at the inside of the processes vaginalis. The sac was successfully closed by laparoscopic percutaneous extraperitoneal closure procedures, and iliopubic tract repair was also performed via the previous inguinal incision. The postoperative course was uneventful.

Conclusion: Pediatric IH is due to the patent processes vaginalis, and REM is extremely rare. Laparoscopic surgery for REM is a relatively common and useful approach for the diagnosis and treatment of adults. In our infantile case, the laparoscopic approach was similarly effective for both investigating the cause of SBO and performing high ligation of the sac for this rare condition with IH.

Keywords: Reduction en masse, Laparoscopic percutaneous extraperitoneal closure, Pediatric surgery, Inguinal hernia, Incarcerated hernia, Small bowel obstruction, Manual reduction, Rare condition

Background

Reduction en masse (REM) is a rare condition following manual inguinal hernia (IH) reduction in which a hernia sac is reduced back into the preperitoneal space with a loop of the bowel incarcerated at the neck of the sac [1]. It is necessary to perform emergent surgical treatment

*Correspondence: sieiri@m.kufm.kagoshima-u.ac.jp

¹ Department of Pediatric Surgery, Research Field in Medicine and Health Sciences, Medical and Dental Sciences Area, Research and Education Assembly, Kagoshima University, 8-35-1 Sakuragaoka, Kagoshima City 890-8520, Japan
Full list of author information is available at the end of the article

for REM because incarcerated hernia remains. However, the diagnosis of REM is often difficult, as it is a rare complication, and it initially appears as if manual reduction was successfully performed. Therefore, when it occurs, it is easily overlooked, which results in a delayed diagnosis and the need for emergent surgery.

We herein report an infantile case of REM of IH that was successfully treated by laparoscopic procedures.

Case presentation

The case was a 10-month-old boy who had a surgical history of bilateral open inguinal hernia repair at 4 months of age at our institution. He presented with a bulge on his left groin and vomiting (Fig. 1). A left incarcerated recurrent inguinal hernia was suspected, and manual reduction was performed. The hernia was apparently reduced

successfully, but abdominal distention and vomiting persisted. Therefore, he was admitted for further observation due to the symptoms.

Immediately after manual reduction and on the first day after admission, abdominal X-ray showed mild small bowel dilatation. On the second day after admission, abdominal X-ray showed extensive dilatation of the small bowel and a paucity of gas in the colon (Fig. 2). Enhanced computed tomography (CT) was performed to investigate causes of small bowel obstruction (SBO). It revealed protrusion of the small bowel with a closed-loop in the left groin (Fig. 3). SBO with a closed-loop due to post-operative adhesion or internal hernia was suspected. To clarify the cause of the SBO, emergent laparoscopic exploration with recurrent inguinal hernia repair was planned.

Under general anesthesia with the patient in a supine position, the umbilicus was opened through a 1.5-cm longitudinal incision, and a wound retractor (LAP PROTECTOR Mini-mini; Hakko Co., Ltd., Tokyo, Japan) was applied. Two 5-mm trocars (scope and operator's right hand, respectively) were inserted through a multichannel port device (E•Z access; Hakko Co., Ltd.) to attach to the wound retractor, and pneumoperitoneum was established (8 mm Hg, 5 L/min CO₂ insufflation). Laparoscopy revealed a small amount of ascites, small bowel dilatation and a loop of small remained trapped in the hernia with a thickened peritoneum at the neck of the sac in the left inguinal lesion (Fig. 4a). Laparoscopic reduction was performed by grasping and pulling the incarcerated small intestine using an atraumatic grasper. After successful reduction, the incarcerated small bowel showed no signs of ischemia, so intestinal anastomosis was not

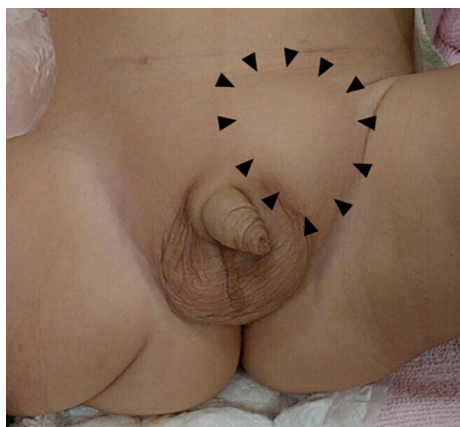

Fig. 1 A bulge at the patient's left groin

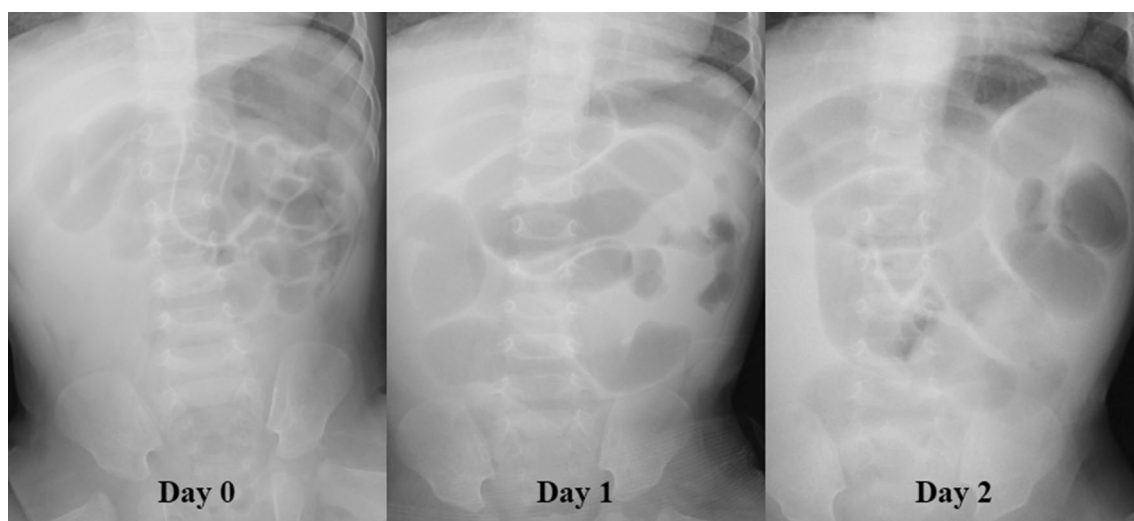


Fig. 2 Abdominal X-ray findings

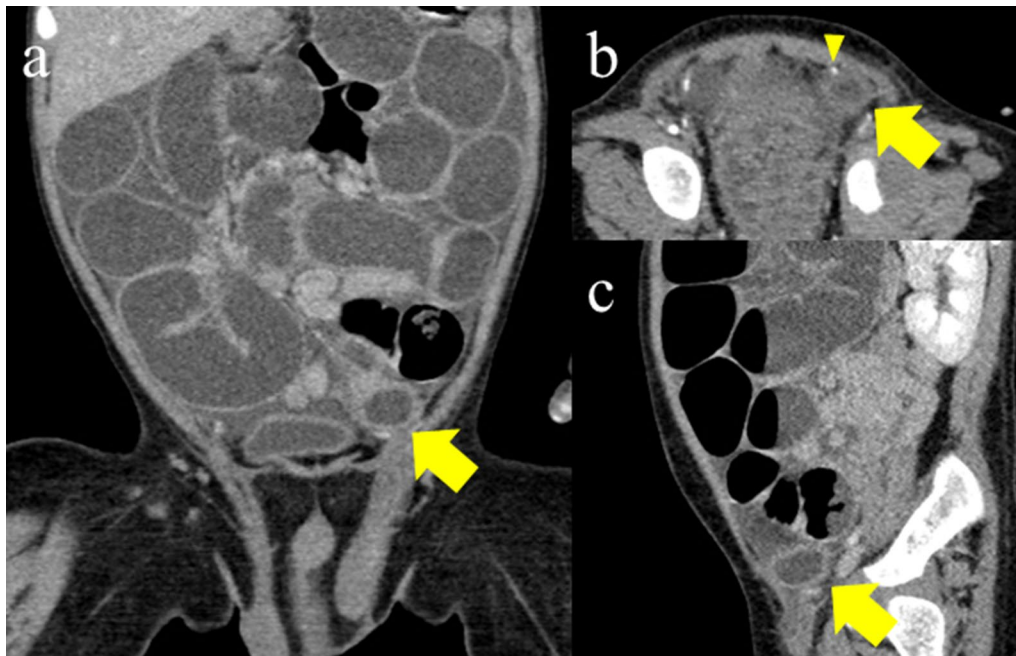


Fig. 3 Enhanced CT findings. Closed loop in the left groin (yellow arrow). **a** Coronal section. **b** Axial section and inferior gastric artery (yellow arrowhead). **c** Sagittal section

performed. Laparoscopy and inserting forceps revealed that the processus vaginalis (PV) had remained closed by a previous operation for IH. The hernia sac at the laparoscopic procedure was not associated with the PV that had been closed by previous open IH repair. It was also located away from the testicular artery and vein as well as the vas deferens, and not inside of the inferior gastric artery (Fig. 4b). To ligate the neck of the hernia sac, a Lapa-Her-Closure needle™ (Hakko Co., Ltd.) was percutaneously inserted into the preperitoneal space just above the neck of the sac. The needle came down half-way around the neck, passed through the peritoneum, released a suture, and then went back, this time coming through the opposite side half-way around the neck and catching the suture before exiting the body (Fig. 4c). The neck was encircled without skipping, and the thickened peritoneum was high ligated (Fig. 4d). Because direct hernia was also suspected, we additionally performed iliopubic tract repair via the previous inguinal incision. The postoperative course was uneventful (Additional file 1).

Discussion

The incidence of REM is reportedly 1 in 13,000 hernias [2]; however, because of an increasing number of early-period surgical repair procedures for hernias after a definitive diagnosis, the incidence is likely far less than that reported [3]. The hernia sack is made by persistent stimulation of the peritoneum, which results in fibrotic

thickening and stenosis, leading to the formation of a new hernia phylum [4]. Despite the disappearance of groin swelling, some patients complain of abdominal symptoms and prolonged findings of SBO [5]. When SBO is found after manual reduction of IH, as in the present case, it is possible that REM has occurred, so caution is required.

The occurrence of REM requires several criteria be met: (1) the hernia sac must have a narrow neck, making it difficult for the bowel to move back out of the sac; (2) the hernia sac must be mobile within the inguinal canal; and (3) there must be enough laxity in the peritoneal cavity without displacing the bowel loops from the sac [6]. In some cases, REM can be manually reduced by the patients themselves [7]. It is generally thought that children are at a lower risk of REM than adults because their hernia sacs tend to adhere tightly to the neighboring cord structures [8]. Regarding REM in pediatric patients, there are two case reports available [8, 9]. Both cases had findings of SBO after manual reduction of IH, similar to our present case. On the other hand, not similar to our present case, they were not recurrent IH after surgery and older than our present case. Their more detailed type of IH was not described, however, it was considered that lack of adhere and vulnerable of their IH sac caused REM [8, 9]. In our present case, it was considered that the initial Potts procedure made the IH sac lacking adhere and vulnerable similarly to them.

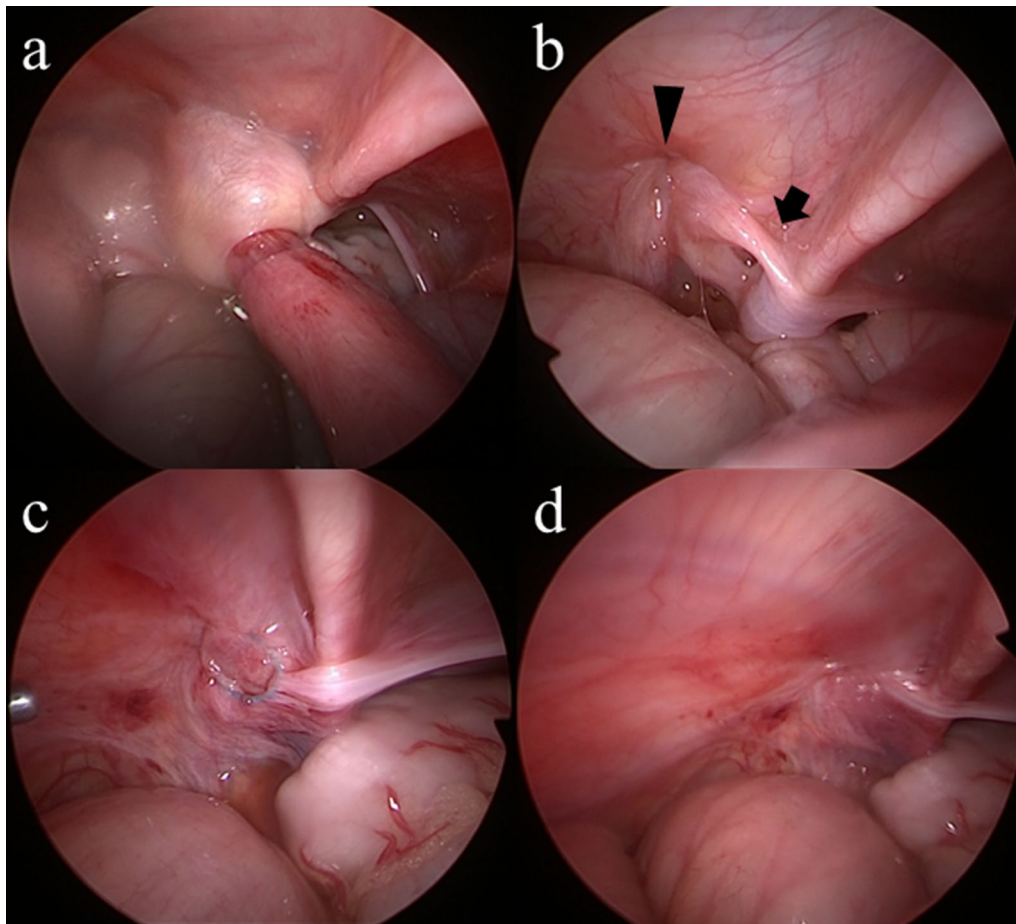


Fig. 4 Operative findings. **a** Small bowel dilatation and a loop of small intestine remained trapped in the hernia with a thickened peritoneum at the neck of the sac in the left inguinal. **b** The hernia sac (black arrow) was not associated with the processus vaginalis (black arrowhead), which had been closed by a previous open procedure. **c** The hernia neck was encircled without skipping. **d** The hernia neck received high ligation

Regarding the mechanism underlying recurrent IH after the Potts procedure at four months old in our present case, it was not associated with the recurrence of patent PV. The laparoscopic findings showed the incarcerated small bowel located inside the previously ligated PV. Retrospectively, enhanced CT revealed that hernia sac and trapped small bowel had not been inside of the inferior gastric artery, and they appeared that they had headed into internal inguinal ring through outside of the inferior gastric artery (Fig. 3). The mechanism underlying recurrent IH in our present case is thus considered to not involve the recurrence of repaired indirect hernia or complicated congenital direct hernia after the Potts procedure. Our present case is thought to be a recurrence as de novo type of external IH. There have been reports concerning the effectiveness of laparoscopic reduction for REM of IH in adult cases [10]. Similarly, in our present case, a laparoscopic procedure was also effective for the

treatment and diagnosis of this rare condition of pediatric REM and recurrent IH.

Conclusion

In cases of SBO after manual reduction of IH, the potential involvement of REM should be considered. Laparoscopic procedures for REM are effective for the diagnosis and treatment of REM in infantile cases of this extremely rare condition.

Abbreviations

REM: Reduction en masse; IH: Inguinal hernia; SBO: Short bowel obstruction; PV: Processus vaginalis.

Supplementary Information

The online version contains supplementary material available at <https://doi.org/10.1186/s40792-022-01535-1>.

Additional file 1.

Acknowledgements

We thank Mr. Brian Quinn for his comments and help with the manuscript. This study was supported by Grants-in-Aid for Scientific Research from the Japan Society for the Promotion of Science (JSPS, No. 16K11350, 19K09150, 20K10403), a research grant from the JFE (Japanese Foundation for Research and Promotion of Endoscopy), a research grant from the J-CASE (Japanese Consortium of Advanced Surgical Endoscopy), a research grant from the Kyushu Society of Endoscopic and Robotic Surgery, a research grant in the form of the Karl Storz Award from the Japan Society for Endoscopic Surgery, a research Grant from The Mother and Child Health Foundation, and a research grant from the Kawano Masanori Memorial Public Interest Incorporated Foundation for Promotion of Pediatrics.

Author contributions

KY wrote this manuscript; KS and MM designed the study; KY, MM, WY, CK, MM, TH and SO data curation; TK and SI gave technical support and conceptual advice. All authors checked and approved this manuscript. All authors were involved in the preparation of this manuscript. All authors read and approved the final manuscript.

Funding

Not applicable.

Availability of data and materials

The datasets supporting the conclusions of this article are included within the article.

Declarations**Ethics approval and consent to participate**

Not applicable.

Consent for publication

Written informed consent was obtained from the parent of the patient for the publication of this case report and any accompanying images.

Competing interests

The authors declare that they have no competing interests.

Author details

¹Department of Pediatric Surgery, Research Field in Medicine and Health Sciences, Medical and Dental Sciences Area, Research and Education Assembly, Kagoshima University, 8-35-1 Sakuragaoka, Kagoshima City 890-8520, Japan.

²Clinical Training Center, Kagoshima University Hospital, Kagoshima, Japan.

Received: 15 July 2022 Accepted: 18 September 2022

Published online: 26 September 2022

References

1. Ravikumar H, Babu S, Govindarajan M, Kalyanpur A. Reduction en-masse of inguinal hernia with strangulated obstruction. *Biomed Imaging Interv J*. 2009;5: e14.
2. He P. Strangulated hernia reduced en masse. *Surg Gynecol Obstet*. 1931;53:822–8.
3. Brady MP, Veith FJ. Reduction en masse of incarcerated inguinal hernia. A new look at an old problem. *Am J Surg*. 1964;107:868–70.
4. Oshidari B, Ebrahimian M, Nakhaei M, Ghayebi N. Laparoscopic relief of reduction en-masse in an inguinal hernia: a case report. *Int J Surg Case Rep*. 2022;90: 106724.
5. Sahoo MR, Kumar A. Laparoscopic management of reduction-en-masse. *BMJ Case Rep*. 2012;2012.
6. Nason LH, Mixter CG. Hernia reduced en masse. *J Am Med Assoc*. 1935;105:1675–7.
7. Mings H, Olson JD. Reduction “en masse” of Groin Herniae. *Arch Surg*. 1965;90:764–9.
8. Olguner M, Ağartan C, Akgür FM, Aktuğ T. Pediatric case of hernia reduction en masse. *Pediatr Int*. 2000;42:181–2.

9. Bernie AM, Schwanke T, Keutgen X, Spigland N. Reduction en masse in a 7-year-old boy: an interesting case. *J Pediatr Surg*. 2012;47:E19–20.
10. Cao Y, Kohga A, Kawabe A, Yajima K, Okumura T, Yamashita K, et al. Case of reduction en masse who presented with no symptoms. *Asian J Endosc Surg*. 2019;12:207–10.

Publisher's Note

Springer Nature remains neutral with regard to jurisdictional claims in published maps and institutional affiliations.

Submit your manuscript to a SpringerOpen[®] journal and benefit from:

- Convenient online submission
- Rigorous peer review
- Open access: articles freely available online
- High visibility within the field
- Retaining the copyright to your article

Submit your next manuscript at ► [springeropen.com](https://www.springeropen.com)