

Prepectoral Conversion of Subpectoral Implants for Animation Deformity after Breast Reconstruction: Technique and Experience

Alexander Shikhman, DO*
 Logan Erz, MD†
 Meghan Brown, MD*
 Douglas Wagner, MD*

Background: Implant-based breast reconstruction in postmastectomy patients is commonly performed in a submuscular plane. Following reconstruction, animation deformity can be a displeasing aesthetic result for patients. In addition, patients may experience more postoperative pain with a submuscular reconstruction. Prepectoral conversion of submuscular implant position is an option for addressing these concerns. We describe a detailed technique and review our results.

Methods: A retrospective review was conducted of all prepectoral conversions performed by the senior author (DSW) from 2017 to 2019 after IRB approval. All patients presented with animation deformity and another symptom such as asymmetry, pain, and/or capsular contracture. Patients underwent prepectoral conversion with smooth silicone gel implants. Demographic data, outcomes, and patient satisfaction were reviewed.

Results: Prepectoral conversion was performed in 33 consecutive patients (57 breasts) with animation deformity. Twelve patients had capsular contracture, seven complained of pain, and five had ruptured implants. Postoperative complications included three infections requiring implant removal in two breasts, one implant exposure and one hematoma requiring implant replacement, five seromas requiring aspiration, and one capsular contracture. Seven patients had contour abnormalities addressed with secondary autologous fat grafting. Ultimately, all patients had elimination of animation deformity and were satisfied with the results of the conversion.

Conclusions: Unsatisfactory results of subpectoral implant reconstruction such as animation deformity and chronic pain have led the reconstructive surgeon to consider various techniques to address these issues. The conversion to a prepectoral plane will effectively eliminate animation deformity, resolve pain, and yield satisfactory results in these patients. (*Plast Reconstr Surg Glob Open* 2022;10:e4132; doi: 10.1097/GOX.0000000000004132; Published online 22 February 2022.)

INTRODUCTION

The outcomes of prosthetic breast reconstruction are typically predictable and reproducible. Until recently, implant-based breast reconstruction in postmastectomy patients was most commonly performed in a dual

or submuscular plane immediately or in a delayed fashion. With this approach, the pectoralis muscle must be released from its inferior costal attachment and elevated off of the chest wall. This establishes a pocket, often too small to accommodate a prosthetic implant. Either additional muscle recruitment is necessary, such as the serratus anterior, or ADM is used for the lower pole sling. Unfortunately, there are complications that accompany this technique. Along with the prosthetic based complications such as seroma, infection, mastectomy flap necrosis, implant exposure, malposition, and capsular contracture,

From the *Division of Plastic Surgery, Department of Surgery, Summa Health Systems, Akron, OH; and †Department of Surgery, Summa Health Systems, Akron, OH.

Received for publication August 24, 2021; accepted December 14, 2021.

Copyright © 2022 The Authors. Published by Wolters Kluwer Health, Inc. on behalf of The American Society of Plastic Surgeons. This is an open-access article distributed under the terms of the [Creative Commons Attribution-Non Commercial-No Derivatives License 4.0 \(CCBY-NC-ND\)](https://creativecommons.org/licenses/by-nc-nd/4.0/), where it is permissible to download and share the work provided it is properly cited. The work cannot be changed in any way or used commercially without permission from the journal.

DOI: 10.1097/GOX.0000000000004132

Disclosure: The authors have no financial interest to declare in relation to the content of this article.

Related Digital Media are available in the full-text version of the article on www.PRSGlobalOpen.com.

animation deformity is one of the most displeasing aesthetic results. In addition, patients may experience considerably more postreconstruction pain and even limited shoulder range of motion with this technique.¹

The plastic surgeon cannot overlook the aesthetic needs of the postmastectomy patient. In the last decade, prepectoral-based implant reconstruction was reinvigorated with the advent of ADMs, fat grafting, and intraoperative fluorescent angiography. This strategy is less invasive and produces a more natural breast with age-appropriate ptosis and less postoperative pain. This technique was first described in breast reconstruction by Snyderman and Guthrie in 1971 in a delayed fashion.²

Patients with unsatisfactory results from prior submuscular implant-based breast reconstruction may seek treatment for their animation deformity, capsular contracture, pain, or asymmetry. Animation deformity is the unavoidable adhesion between the pectoralis major muscle, the overlying mastectomy skin flap, together with adhesion to the underlying implant capsule.³ An analysis by Fracol et al of patient reported outcomes using the BREAST-Q showed two subsets of patients that may benefit from revision—those who have significant animation deformity with minimal pain and those who have minimal animation deformity but with substantial pain.⁴ Prepectoral conversion of submuscular implant position has been shown to decrease muscle spasms and resolve animation deformity.⁵ Other perceived advantages of prepectoral reconstruction include more natural appearance to the breasts, decreased pain, and shorter operative times because the pectoralis major muscle remains in anatomic position. Prepectoral implant position has been shown safe in a postmastectomy radiation cohort,⁶ as well as in aesthetic patients.⁷ The purpose of our study was to review a single surgeon's experience treating patients with animation deformity, describe the technique, and evaluate our outcomes in subpectoral to prepectoral implant position conversion.

METHODS

We conducted a retrospective review of all prepectoral conversions performed by the senior author (DSW), from 2017 to 2019 after approval from the institutional review board. All patients presented with animation deformity along with another symptom such as asymmetry, pain, and/or capsular contracture. Patients underwent implant removal, partial capsulectomy, myoplasty of the pectoralis major muscle into original anatomic position, and dissection of a prepectoral plane followed by creation of an ADM envelope for total anterior implant coverage and smooth silicone gel implant placement. Patients were followed for routine postoperative care and queried on subjective overall satisfaction of the revision. Postoperative complications were also recorded.

SURGICAL TECHNIQUE

The conversion technique remained consistent throughout the study period. The surgical technique begins with preoperative markings. (See [Video 1 \[online\]](#), which demonstrates flap elevation, partial capsulectomy,

Takeaways

Question: How can patients with symptomatic subpectoral implant-based breast reconstruction be managed in a reliable, efficacious, and reproducible way?

Findings: Our technique is reliable and efficacious in eliminating animation deformity and chronic pain.

Meaning: Prepectoral conversion will yield satisfactory results by eliminating animation deformity and chronic pain.

myoplasty, and pocket measurements.) Once the patient is under anesthesia and draped for surgery the incisions are made along the prior scar. Wide unsightly scars should be excised down to the pectoralis muscle. The next step is to elevate the skin and subcutaneous flap from the prior pectoralis major and acellular dermal matrix (ADM) construct, assuring that all of the subcutaneous fat stays with the skin and none left on the muscle. This can be a very tedious process; however, it is necessary to preserve the blood supply to the mastectomy flap, particularly the subdermal plexus. This is a relatively clean dissection, as it is a scar plane with no significant vasculature present. The flap is raised in the plane between the capsule and the subcutaneous tissue inferiorly ([Fig. 1](#)). As the dissection continues medially, large perforating vessels may be encountered. This is an indication that the original dissection was completed up to this point. After the muscle and ADM is completely exposed, the periprosthetic space is entered. A small cuff of ADM is left on the inferior edge of the pectoralis muscle to aid in myoplasty ([Fig. 2](#)). After entering the periprosthetic space, the implant is removed and evaluated. The capsule is thoroughly inspected to assure that no gross pathologic changes exist. A total capsulectomy is typically not performed because the capsule beneath the muscle will facilitate gliding excursion for the pectoralis muscle over the chest wall. It is important to adequately dissect the prepectoral plane so that the new ADM envelope can be optimally positioned. The footprint of the prepectoral space should correspond to the base diameter of the implant to be used. We choose to use contour perforated AlloDerm (Abbvie, Allergan, LifeCell, Branchburg, N.J.) for the envelope. Medially, the internal mammary perforators should be preserved. Over dissection lateral and superior may be done to facilitate the reconstruction.

A partial capsulectomy is performed at the lower outer aspect of the breast pocket ([Fig. 3](#)). This is the area where the previous ADM capsule would, otherwise, be in contact with the new implant and the new AlloDerm envelope. The same principle is used here when removing the capsule from the subcutaneous tissue and skin; all of the subcutaneous tissue should remain with the skin.

Next, the pectoralis major muscle myoplasty is performed by advancing and anchoring the pectoralis and its ADM/capsule cuff to the chest wall along its original origin with eight to 12 interrupted figure-of-eight 2-0 Vicryl Plus sutures (Ethicon, Somerville, N.J.). These sutures incorporate rib periosteum for secure fixation. The

myoplasty is performed along the medial inferior edge of the muscle starting at the sternal border and working laterally up to the free edge of the pectoralis muscle that would exist in undisturbed anatomy (Fig. 4). Often, the pectoralis muscle needs to be stretched to reach the inferior medial sternal origin, as it may have retracted over time after its initial release.

After the myoplasty, the subcutaneous breast pocket is measured to ensure that there is adequate space to accommodate the chosen implant base diameter. The pocket is dissected to be larger than the base diameter of the implant to assist with placing the AlloDerm envelope and securing it circumferentially to the chest wall. However, the medial and inferior aspect of the dissection will be exactly the edge of the AlloDerm envelope. The appropriate sizer is placed in the breast pocket, and the skin is temporarily closed. The shape of the breast is evaluated specifically noting the medial and IMF contour. In our experience, we note that sometimes the upper pole transition from chest to breast is smoother compared with a submuscular implant. If necessary, further augmentation

of the upper pole transition can be accomplished with fat grafting at a later date. The sizer is removed, and the base diameter of the implant is marked. The markings begin medially and inferiorly at the edge of the dissection and continue laterally and superiorly. A ruler is used to measure from the established medial border to the lateral border and the established inferior border to superior border of the pocket to determine the exact base diameter desired. A circle of the exact implant base diameter should ultimately be marked on the chest wall. The circle is bisected with another line from superior lateral to inferior medial. This will be the equator of the two pieces of contour perforated AlloDerm used to construct the envelope. The breast pocket is thoroughly irrigated with triple antibiotic solution before insertion of any prostheses.

Two pieces (per side) of perforated and triple antibiotic soaked AlloDerm are selected for the creation of the breast envelope. (See Video 2 [online], which demonstrates AlloDerm positioning and securing, implant insertion, and closure.) The contour AlloDerm has a long and a short edge as well as a shiny and a matte finish side. The matte finish side, which is the basement membrane side, is placed facing up toward the skin to facilitate integration

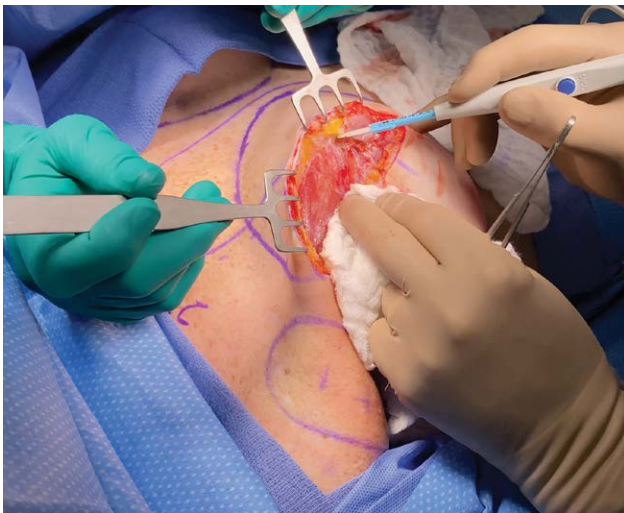


Fig. 1. Plane of dissection.

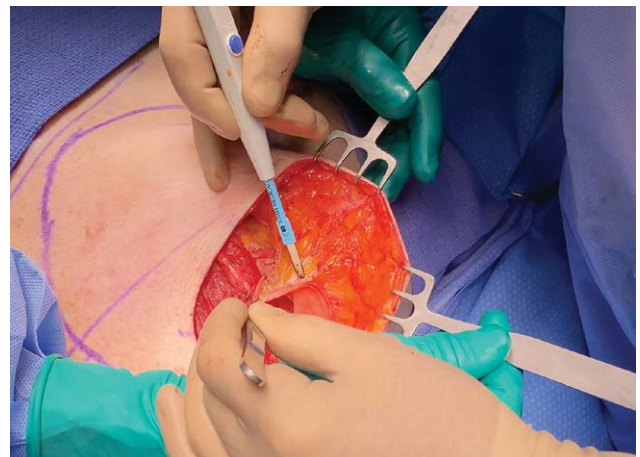


Fig. 3. Partial capsulectomy of the lower outer capsule.

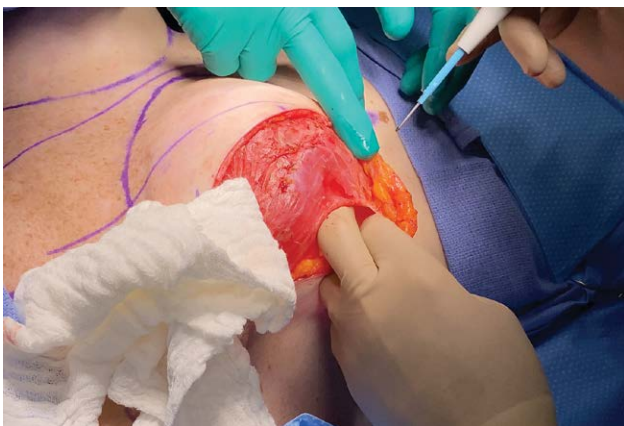


Fig. 2. Implant pocket accessed, leaving a 1 cm cuff of ADM on the pectoralis major muscle.

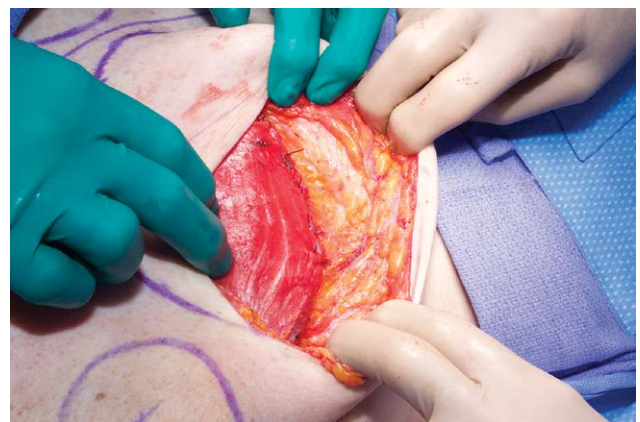

Fig. 4. Completed myoplasty along the anatomic origin.

into the subcutaneous flap. The long edge of the AlloDerm is placed along the circumference of the circle. Corners of the two pieces of AlloDerm are secured with two 2-0 PDS sutures (Ethicon, Somerville, N.J.) placed on either side of the equator (Fig. 5). Occasionally, the circumference of the AlloDerm is larger than the base diameter drawn on the chest wall. Therefore, the upper pole and lower pole AlloDerm excess is distributed equally along the base diameter circumference. To secure the circumference of the remaining AlloDerm to the chest wall the previously placed 2-0 PDS sutures are run in a continuous fashion to the opposite side. The needles are left on the suture to later assist with closing the equator. One suture is used for the upper pole, and the other suture is used for the lower pole. The lower pole AlloDerm is reinforced with an additional running suture to assist with the implant weight. Laterally, the AlloDerm is secured to the fascia of the serratus anterior.

Before inserting the implant, the equator is partially closed medially and laterally for about 3–4cm (Fig. 6).

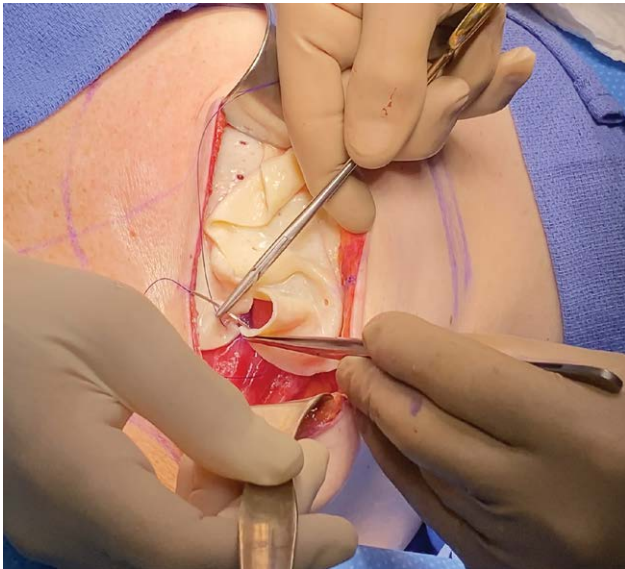


Fig. 5. Lateral ADM corners secured to the chest wall.

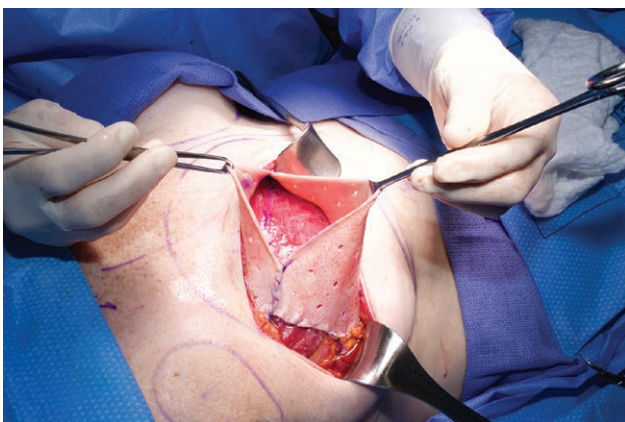


Fig. 6. The ADM equator is partially closed medially and laterally.

This will assist with visualization of the final equator closure to avoid damaging the implant inadvertently. The breast pocket is irrigated with triple antibiotic solution again. The surgeon's gloves are changed, and a minimal touch technique is utilized to insert the implant within the AlloDerm envelope (Fig. 7). The position of the implant is confirmed to ensure it is lying flat with the implant markings facing the chest wall. Finally, the equator is closed with a new 2-0 PDS suture (Fig. 8). A small malleable retractor is helpful to protect the implant during final envelope closure. Two 7-mm Jackson-Pratt type drains are placed within the breast pocket between the AlloDerm and the subcutaneous tissue before closure of the skin. Drains provide negative pressure to collapse potential dead-space and evacuate seroma fluid, both of which will assist with incorporation of the AlloDerm. In addition, a fibrin sealant (Artiss, Baxter, Deerfield, Ill.) is sprayed into the pocket to discourage seroma formation by early adhesion of the subcutaneous tissue to the AlloDerm. The incision is closed in a standard fashion to complete the reconstruction (Fig. 9).

RESULTS

Our retrospective review resulted in 33 consecutive patients (57 breasts) who underwent prepectoral conversion. The average age was 56.1 years. The preoperative comorbidities included hypertension, smoking, chemotherapy, and radiation before surgery (Table 1).

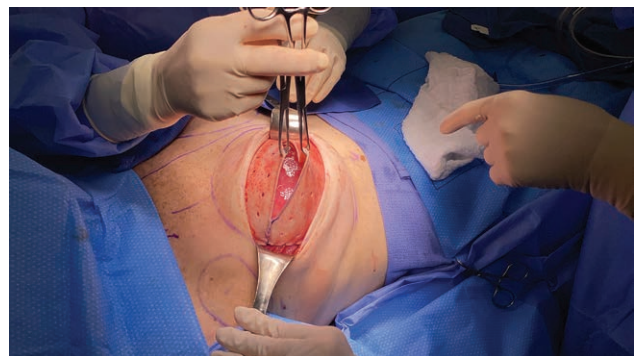


Fig. 7. Implant in position.

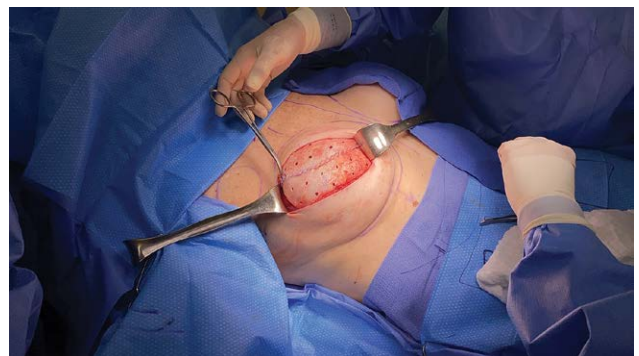

Fig. 8. ADM pocket is closed.

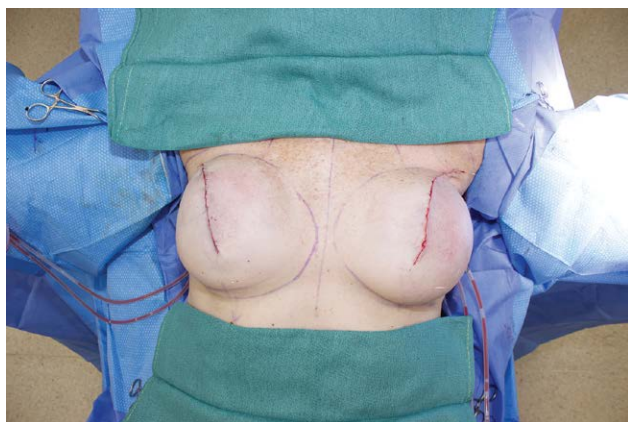

Fig. 9. Completion of prepectoral implant conversion.

Table 1. Demographics

Demographics	
No. patients	33
No. breasts	57
Age mean, y	56.1
Body mass index, mean	27.2
Diabetes	0
Hypertension	11 (33%)
Smoker, current	1 (3%)
Indication for mastectomy	
Prophylactic	8 (24%)
Breast cancer	25 (76%)
Prior chemotherapy	9 (27%)
Prior radiation	5 (15%)

Eight patients had prophylactic nipple-sparing mastectomy at the initial operation. At initial operation, 15 patients had tissue expanders followed by implant placement and 18 underwent direct to implant reconstruction. All patients had moderate to severe animation deformity and asymmetry. In addition, 12 patients had capsular contracture, seven complained of chronic pain, and five were found to have ruptured implants. The average time between initial reconstruction and prepectoral conversion was 10.8 years. The average follow up period was 421 days (range, 8–1128 days).

Postoperative complications consisted of three breast infections in three patients, resulting in implant loss in two patients. The third infection patient was successfully managed with irrigation and implant exchange. One of the patients that developed an infection resulting in implant loss had a history previous breast radiation and was an active smoker at the time of conversion. One patient had implant exposure, which was managed with irrigation and implant exchange. One patient had implant exposure and hematoma requiring hematoma evacuation, irrigation, and implant exchange. This patient was a former smoker and had hypertension. There were three patients that developed a seroma requiring aspiration. Two patients developed bilateral seromas and one developed a unilateral seroma after drain removal. All three patients that developed seromas had a BMI greater than 30 (32, 32.4, and 35.9). One patient that developed a seroma also had

a history of radiation. One patient developed unilateral Baker III/IV capsular contracture necessitating capsulectomy with implant exchange at a later date. Seven patients had contour abnormalities such as implant edge visibility or hollowing, which were addressed with autologous fat grafting at a second stage (Table 2).

Our overall complication rate including minor complications was 24.2%. Our rate of implant loss was 9%. Despite the presence of any complications, all of the patients were either satisfied or very satisfied with their eventual outcome, aesthetic results, and elimination of animation deformity. Preoperative animation deformity (Figs. 10A, 11A) and postoperative results are shown with resolution of animation deformity (Figs. 10B, 11B). Improvement in upper pole contour may occasionally be achieved with prepectoral conversion without fat grafting (Figs. 12, 13).

DISCUSSION

In the last decade, a paradigm shift has emerged toward direct to implant prepectoral implant-based breast reconstruction. Accompanied with the use of ADM, the prepectoral position has revealed pleasing aesthetic and functional outcomes superior to the subpectoral position.⁷ Numerous studies have concluded that animation deformity is detrimental to quality of life. The negative impact of subpectoral implant position often affects active women who exercise. Pectoralis major muscle power reduces by as much as 20% from initial partial detachment and over time due to thinning.^{8,9} Prepectoral prosthetic reconstruction can eliminate multiple complications associated with subpectoral implant-based reconstruction, including animation deformity, muscle spasms, and pain. In patients with prior subpectoral reconstruction animation deformity is common, and its severity partially depends on the degree of initial muscle release. Prepectoral conversion from a submuscular implant position addresses all of the aforementioned undesirable results. Our technique has shown consistent and satisfactory results.

The preservation of all subcutaneous tissue beneath the skin flap is of critical importance for a successful outcome in prepectoral conversion. After a successful initial reconstruction the skin and subcutaneous tissue flaps develop a robust blood supply through the subdermal plexus. By assessing the skin flap thickness, color, and capillary refill, viability can be confirmed after flap elevation. The senior author does not routinely use ICG angiography in conversion procedures; however, ICG angiography is his standard practice to evaluate the mastectomy flaps in immediate prepectoral breast reconstruction. Determining the appropriate flap thickness with the pinch test is useful in immediate reconstruction. In conversion procedures, it has less importance secondary to the delay effect. If there is concern for compromised flap viability ICG angiography can assess perfusion. This scenario may arise in very thin flaps or when inadvertent misadventure occurs during flap elevation.

A total capsulectomy is rarely performed in our prepectoral conversion patients. Similar to Hammond et al.,¹⁰

Table 2. Results

Outcomes	Preoperative	Postoperative	Secondary Procedures
Animation deformity	57 (100%)	0	
Pain (>1 mo postoperative)	9 (16%)	0	
Capsular contracture	15 (26%)	1 (2%)	Capsulectomy
Implant rupture	5 (9%)	0	
Implant exposure		1 (2%)	Implant exchange
Infection		3 (5%)	Implant removal
Purulent		2 (4%)	implant exchange
Nonpurulent		1 (2%)	
Hematoma		1 (2%)	Implant exchange
Seroma		5 (9%)	Aspiration
Contour abnormalities		10 (18%)	Fat grafting

it is the author’s preference to perform a partial capsulectomy of the inferior outer capsule that would, otherwise, be in contact with the new implant. In its natural anatomic form, the pectoralis muscle lies on the chest wall on a thin loose areolar tissue plane. This plane allows the muscle to glide over the chest wall unrestricted during its excursion. For this reason, the capsule beneath the pectoralis muscle is left intact to facilitate this gliding excursion. In addition, a pectoralis major muscle resuspension is performed to replace the muscle to its anatomic position. As studied by

Lesavoy et al, muscle function can return to normal following resuspension.¹¹ In patients with concomitant Baker grade III/IV capsular contracture, a total capsulectomy is performed.

The aesthetic outcome of a prepectoral implant-based reconstruction is influenced by the position of the pocket. In concordance with other authors, including Sbitany, Hammond, Gabriel, and Lenz,^{10,12-15} the implant position is secured with ADM coverage. The senior author employs anterior implant coverage by anchoring the

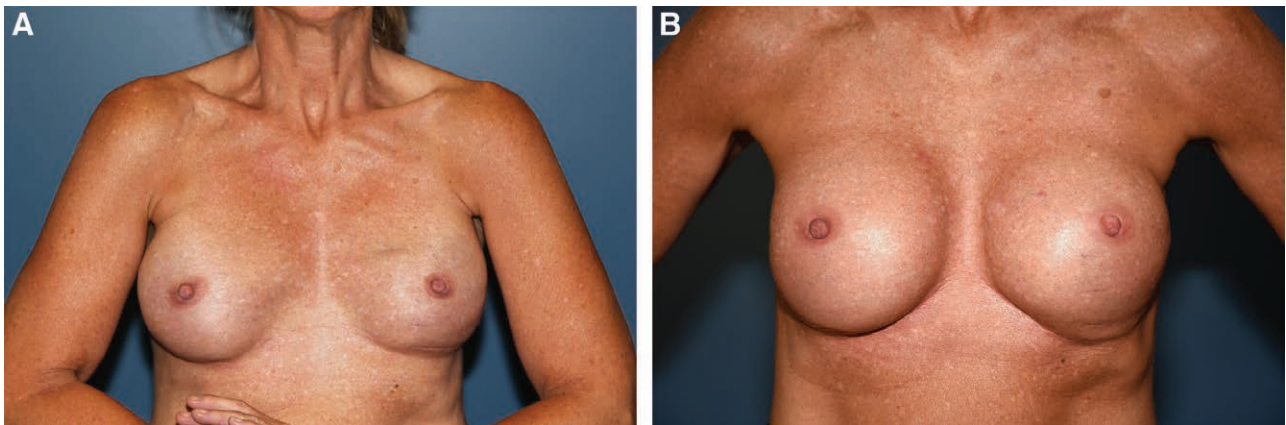


Fig. 10. Patient 1. A, Preoperative animation deformity. B, Postoperative animation deformity resolved.

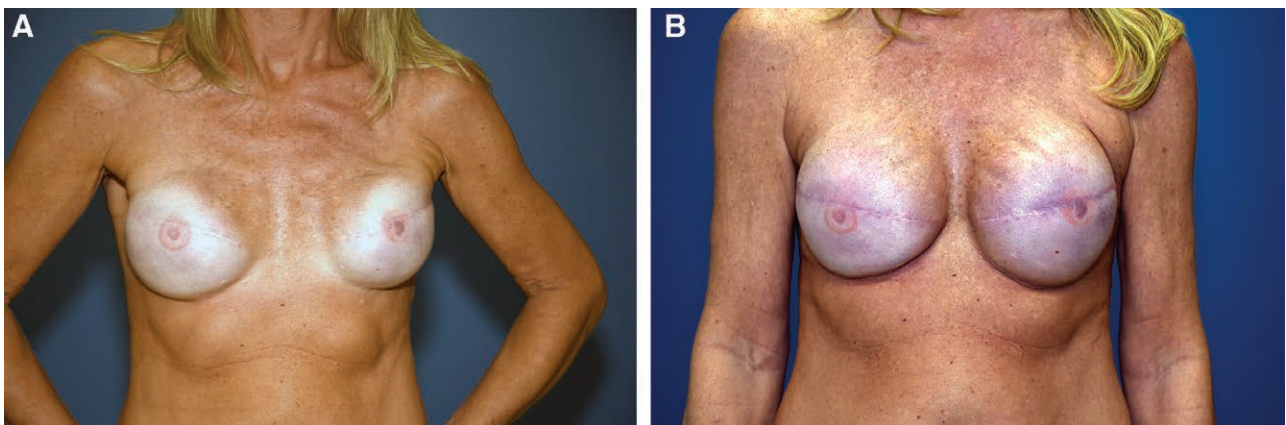


Fig. 11. Patient 2. A, Preoperative animation deformity. B, Postoperative animation deformity resolved.

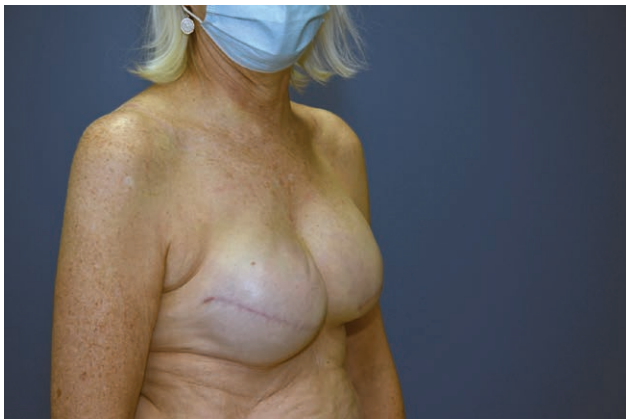

Fig. 12. Preoperative upper pole irregularity.

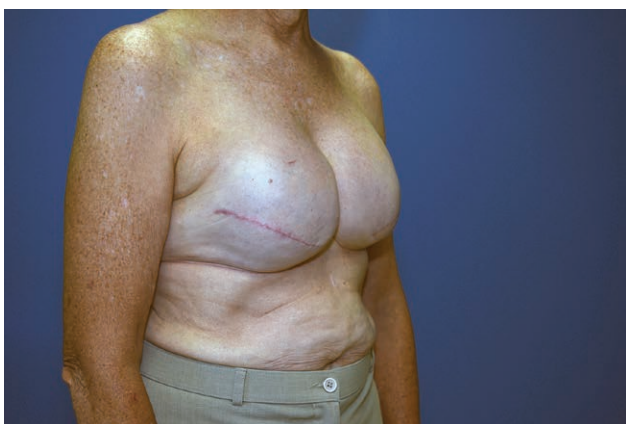

Fig. 13. Postoperative improved upper pole contour, no fat grafting.

ADM envelope to the chest wall, establishing a precisely-positioned periprosthetic space.

Drainage of the breast pocket to prevent seroma is crucial to increasing the integration of ADM to mastectomy flap. Yang et al¹⁶ found prepectoral breast reconstruction with ADM seroma rates of 31.6%. Our technique uses an aerosolized fibrin sealant (Artiss, Baxter, Deerfield, Ill.) before closing the incision. The fibrin sealant assists with decreasing dead-space by providing an adhesive opposition between the mastectomy flaps and the ADM construct covering the implant. Recent studies have shown the utility of fibrin sealants for seroma prevention. Granzier et al found that seroma aspiration rates were significantly higher in patients who had conventional wound closure without flap fixation compared with closure with flap fixation with sutures or adhesive tissue glue.⁷ Integration of the ADM to the mastectomy flap is important to achieve the best aesthetic result and reduce complications. We believe adequate breast pocket drainage and using a fibrin sealant helps achieve this goal.

Our results are in line with findings in other studies and show that prepectoral conversion is safe, effective in addressing animation deformity, and improves patient satisfaction. The limitations of this study include experience

by a single surgeon at a single institution. The results are limited by the nature of retrospective review and small sample size. Another weakness of our study design was the subjective rating of satisfaction of symptom resolution and final aesthetic result. The consistent technique applied to these patients resulting in satisfactory outcomes underscores the reliability of not only the conversion but also prepectoral reconstruction in the reconstruction-naïve patient.

CONCLUSIONS

Unsatisfactory aesthetic results of subpectoral implant-based reconstruction can be corrected with our technique to include prepectoral conversion, partial capsulectomy, myoplasty, ADM, and silicone gel implant revision reconstruction. The conversion to a prepectoral plane will effectively eliminate animation deformity, resolve pain, and yield satisfaction in these patients with relatively unchanged complication profile and incidence when compared with submuscular reconstruction.

Alexander Shikhman, DO

Summa Health System

55 Arch St. Suite 2F

Akron, OH 44309

E-mail: shikhman.alex@gmail.com

REFERENCES

1. Leonardis JM, Lyons DA, Giladi AM, et al. Functional integrity of the shoulder joint and pectoralis major following subpectoral implant breast reconstruction. *J Orthop Res.* 2019;37:1610–1619.
2. Snyderman RK, Guthrie RH. Reconstruction of the female breast following radical mastectomy. *Plast Reconstr Surg.* 1971;47:565–567.
3. Jones GE, King VA, Yoo A. Prepectoral site conversion for animation deformity. *Plast Reconstr Surg Glob Open.* 2019;7:e2301.
4. Fracol M, Qiu CS, Chiu MW, et al. The relationship between animation deformity and patient-reported outcomes: application of the BREAST-Q to a quantitative stratification of animation severity. *Plast Reconstr Surg.* 2020;145:11–17.
5. Sigalove S. Prepectoral breast reconstruction and radiotherapy—a closer look. *Gland Surg.* 2019;8:67–74.
6. Elswick SM, Harless CA, Bishop SN, et al. Prepectoral implant-based breast reconstruction with postmastectomy radiation therapy. *Plast Reconstr Surg.* 2018;142:1–12.
7. Granzier RWY, van Bastelaar J, van Kuijk SMJ, et al. Reducing seroma formation and its sequelae after mastectomy by closure of the dead space: the interim analysis of a multi-center, double-blind randomized controlled trial (SAM trial). *Breast.* 2019;46:81–86.
8. de Haan A, Toor A, Hage JJ, et al. Function of the pectoralis major muscle after combined skin-sparing mastectomy and immediate reconstruction by subpectoral implantation of a prosthesis. *Ann Plast Surg.* 2007;59:605–610.
9. Weck Roxo AC, Nahas FX, Salin R, et al. Volumetric evaluation of the mammary gland and pectoralis major muscle following subglandular and submuscular breast augmentation. *Plast Reconstr Surg.* 2016;137:62–69.
10. Hammond DC, Schmitt WP, O'Connor EA. Treatment of breast animation deformity in implant-based reconstruction with pocket change to the subcutaneous position. *Plast Reconstr Surg.* 2015;135:1540–1544.

11. Lesavoy MA, Trussler AP, Dickinson BP. Difficulties with subpectoral augmentation mammoplasty and its correction: the role of subglandular site change in revision aesthetic breast surgery. *Plast Reconstr Surg.* 2010;125:363–371.
12. Sbitany H. Management of the post-breast reconstruction “hyperanimation deformity”. *Plast Reconstr Surg.* 2014;133:897e–898e.
13. Schnarrs RH, Carman CM, Tobin C, et al. Complication rates with human acellular dermal matrices: retrospective review of 211 consecutive breast reconstructions. *Plast Reconstr Surg Glob Open.* 2016;4:e1118.
14. Lentz RB, Piper ML, Gomez-Sanchez C, et al. Correction of breast animation deformity following prosthetic breast reconstruction. *Plast Reconstr Surg.* 2017;140:643e–644e.
15. Gabriel A, Sigalove S, Sigalove NM, et al. Prepectoral revision breast reconstruction for treatment of implant-associated animation deformity: a review of 102 reconstructions. *Aesthet Surg J.* 2018;38:519–526.
16. Yang JY, Kim CW, Lee JW, et al. Considerations for patient selection: prepectoral versus subpectoral implant-based breast reconstruction. *Arch Plast Surg.* 2019;46:550–557.