

Prediction of osteoporosis using dental radiographs and age in females

Guduba Vijay, Parita K. Chitroda, Girish Katti, Syed Shahbaz, Irfan Baba, Bhuvaneshwari

Department of Oral Medicine and Radiology, Al-Badar Dental College and Hospital, Gulbarga, Karnataka, India

ABSTRACT

Aims and Objectives: To evaluate the role of dental radiograph as a screening tool for diagnosis of osteoporosis in females.

Materials and Methods: In the present study, 50 women between the age group of 40-60 were recruited, and patients with systemic disorder and taking calcium supplements, and women who are not willing for investigation were excluded. Their detailed medical history was obtained and dental radiographs were made, bone mineral density was measured at left radial bone using ultrasound. The radiographs were subjected to image analysis method using manual tracing of gonial angle, antegonial angle, antegonial depth, antegonial index, mental index and mandibular cortical index. Statistical discrimination analysis was applied to predict the presence of osteoporosis. With use of these indices, the sensitivity and specificity of orthopantomograph (OPG) radiograph to assess age-related changes in bone were compared. Radiomorphometric indices (RMI) were also scrutinized to depict the sensitivity and specificity of each index in the prediction of osteoporosis.

Results: Study results showed no significant differences between bone mineral density (BMD) and radiomorphometric analysis in the diagnoses of osteoporotic females. Out of 29, diagnosed as osteoporotic by radiograph 23 were confirmed by BMD and six were diagnosed as osteopenic. Among the six indices used, AGA and AGD showed more reproducible results.

Conclusion: With our study results, we come to an arrival that OPG radiographs show overall sensitivity of 0.75 or 75% and specificity of 0.81 or 81% in the diagnosis of osteoporosis, and that anti gonial angle (AGA) and anti gonial depth (AGD) are the most reliable indices. Hence, we conclude that panoramic-based RMI can be used as an ancillary method in the diagnosis of osteoporosis.

Key Words: Bone mineral density, menopause, OPG, osteoporosis

INTRODUCTION

The term osteoporosis is derived from classical Greek word “osteon” meaning bone and “pores” meaning a small passage or pore, and osis meaning condition^[1]

According to the definition of the World Health Organization (WHO) formulated in 1994, osteoporosis is a systemic disease characterized by low bone mineral density (BMD), deterioration of bone structure and increased bone fragility.^[1]

In India 1 out of 8 males and 1 out of 3 females suffer from osteoporosis, making India one of the largest affected countries in the world. Research shows the number

Address for Correspondence: Dr. Guduba Vijay, Al-Badar Dental College and Hospital, Gulbarga, Karnataka, India.
E-mail: drvijayguduba@gmail.com

Access this article online

Quick Response Code:



Website:
www.jmidlifehealth.org

DOI:
10.4103/0976-7800.158952

This is an open access article distributed under the terms of the Creative Commons Attribution-NonCommercial-ShareAlike 3.0 License, which allows others to remix, tweak, and build upon the work non-commercially, as long as the author is credited and the new creations are licensed under the identical terms.

For reprints contact: reprints@medknow.com

How to cite this article: Vijay G, Chitroda PK, Katti G, Shahbaz S, Baba I, Bhuvaneshwari. Prediction of osteoporosis using dental radiographs and age in females. J Mid-life Health 2015;6:70-5.

of osteoporosis patients at approximately 26 million (2003 figures) with the numbers projected to increase to 36 million by 2013. The most important risk factors for osteoporosis are advanced age (involving both genders) and with female predilection showing estrogen deficiency after menopause or oophorectomy, where there is rapid reduction in BMD. Fracture may occur upon application of little force or trauma to the osteoporotic bone. Thus, osteoporosis is considered a risk factor for fracture; hence a distinction between risk factors that affect bone metabolism and risk factors for fracture must be considered separately.

Worldwide, lifetime risk for osteoporotic fractures in women is reported to be 30-50%. Whereas in men risk is 15-30%. Three main types of osteoporosis fractures are wrist fracture, vertebral fracture and hip fracture.^[2] The current gold standard for diagnosing osteoporosis is BMD. BMD is usually measured using a dual energy X-ray absorptiometry (DEXA) examination, however these are considered as less suitable for large-scale screening because of the cost and region-dependent availability.^[3-5]

Bone mass can also be assessed by single photon absorptiometry (SPA), dual photon absorptiometry (DPA), quantitative computed tomography (QCT), radiographic absorptiometry (RA) and quantitative ultrasound (QUS). QUS devices evaluate bone by measuring different properties of an ultrasound wave emitted through or along bone, because osteoporosis results in systemic loss of bone mass and micro-architectural deterioration, researchers have looked to see if dental radiographs may offer a means of screening for osteoporosis and found that panoramic radiographs of the jawbone to be very useful for early detection of osteoporosis. The qualitative and quantitative indices that can be used to assess bone quality and to observe the signs of osteoporosis are mandibular cortical thickness (MCT), panoramic mandibular index (PMI), mandibular cortical index (MCI), antegonial index (AI) and mental index (MI).^[3-5]

MATERIALS AND METHODS

The present study was conducted in the Department of Oral Medicine and Radiology at Al-Badar Dental College and Hospital; the study group consisted of 50 female patients between the age group of 40 and 60 years.

All the patients were subjected to digital radiography and tracing were done. After the radiographic diagnosis all the patients were subjected for BMD using QUS for confirming the radiographic diagnosis.

Measurements of radiomorphometric indices

Gonial angle (GA)

The gonial angle was assessed by tracing a line tangent to the lower border of the mandible and another line tangent to the posterior border of ramus and condyle on each side. The intersection of these two lines formed GA [Figure 1]. Normal gonial angle is $128^{\circ} \pm 7$.^[6]

Antegonial angle (AA)

Measured by tracing two lines parallel to the lower cortical border at antegonial region and measuring the angle of intersection at deepest point of the antegonial notch [Figure 2]. Normal angle is $163^{\circ} \pm 2$.^[7]

Antegonial depth (AD)

Measured as the distance along a perpendicular line from the deepest point of antegonial notch concavity to the line parallel to the inferior cortical border of the mandible [Figure 3]. Normal depth is 1.6 ± 2 mm.^[7]

Antegonial index (AI)

Measurement of the cortical width in the region anterior to the gonial at a point identified by extending a line of best fit on the anterior border of mandible [Figure 4]. Normal value ≥ 3.2 mm.^[8]

Mental index (MI)

Measurement of the cortical width at the mental foramen region is called MI, and a line that passes perpendicular to the tangent of the lower border of the mandible and through the center of the mental foramen [Figure 5]. Normal value ≥ 3.2 mm.^[8]

Mandibular cortical index (MCI)

This is a classification of appearance of the lower border cortex of mandible distal to the mental foramen as viewed on panoramic radiographs on a three-point scale [Figure 6].

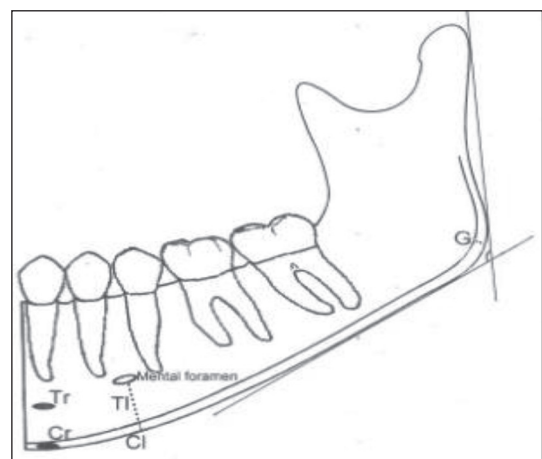


Figure 1: Gonial angle

- C₁: The endosteal margin of the cortex is even and sharp on both sides.
- C₂: The endosteal margin shows semi-linear defects (lacunar resorption) or seems to form endosteal cortical residues (one to three layers) on one or both sides.
- C₃: The cortical layer forms heavy endosteal residues and is clearly porous.^[9]

Measurement of BMD

Measuring the BMD identified osteoporotic patients. For the examination of the BMD, QUS of radial bone was performed using sunlight Omnisense™ 7000 device (Sunlight Medical, Tel Aviv, Israel).

The patients were classified according to World Health Organization Classification based on the BMD data of the radial bone as.^[10]

- Normal (*T*-score > -1.0),
- Osteopenic (*T*-score -1.0 to -2.5) or
- Osteoporotic (*T*-score of < -2.5).

RESULTS

Out of 50 female patients according to radiomorphometric indices (RMI), maximum number of osteoporotic patients was found in the age group of 40 to 45 years that comprises 17 patients and out of them nine (52.94%) were diagnosed as osteoporotic [Figure 7]. According to QUS, maximum number of osteoporotic patients was found in the age group of 46 to 50 years, that comprises 16 and of which eight (50%) were identified as osteoporotic [Figure 8]. For all the age groups, total osteoporotic patients identified by RMI were 29 (58%); BMD has confirmed 23 (46%) as osteoporotic and 6 (12%) as osteopenic [Figure 9]. Accordingly the overall sensitivity of dental radiograph is 0.75 or 75% and specificity is 0.81 or 81%. Statistical value or *p* value was found to be consistently >0.05, which is not significant in all the age groups that is, from 40 to 60 years that shows that sensitivity and specificity is not affected with advancing age. Comparing the subgroups of RMI (GA, AA, AD, AI and MCI) showed no statistical significance. And there is not much difference in the




Figure 2: Antegonial angle

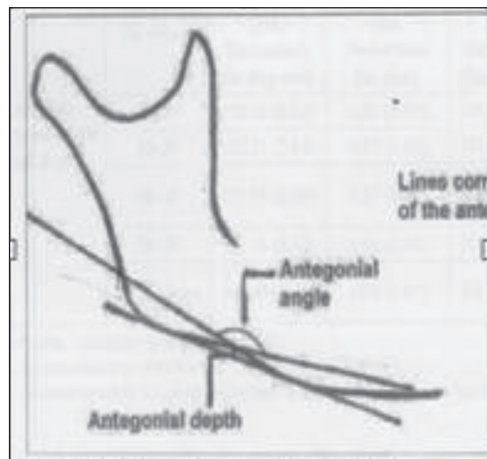


Figure 3: Antegonial depth

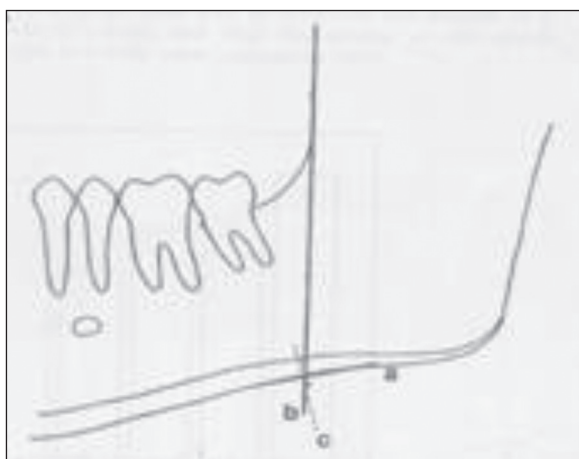


Figure 4: Antegonial index

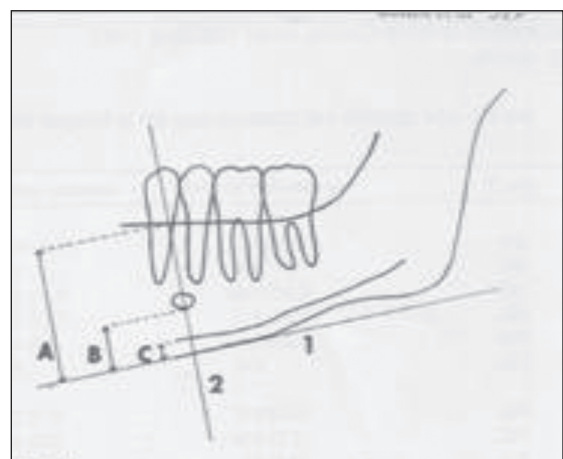


Figure 5: Mental index

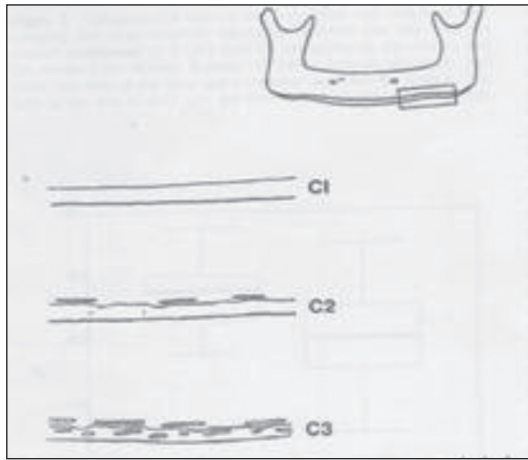


Figure 6: Mandibular cortical index

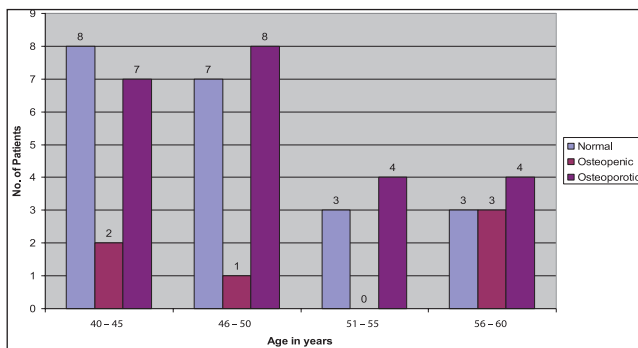


Figure 8: Age-wise distribution of normal, osteopenic and osteoporotic patients who were confirmed with BMD, which was performed using quantitative ultrasound

ability of these RMI to discriminate between normal and osteoporotic patients.

DISCUSSION

Total 50 females in the age range of 40 to 60 years were included in the study, of which the maximum number of patients who reported to us were in the age group of 40 to 45 years (34.0%) and 44 to 50 years (32.0%), although statistically the difference in number of patients between 40-45 years and 46-50 years was not remarkable.

According to Verheij *et al.*, (2008), after the age of 35 years the BMD of men and women gradually decrease with increasing age. Women tend to lose BMD more rapidly than men especially after menopause. As a result osteoporosis is three times more common among women than in men. The risk of fracture of the spine, hip or wrist after the age of 50 years due to osteoporosis is estimated at 40-50%.^[11]

Ayranci *et al.*, (2010) stated that the age of menopause is between 45-55 years all over the world. The maximum number of patients in our study who were diagnosed as

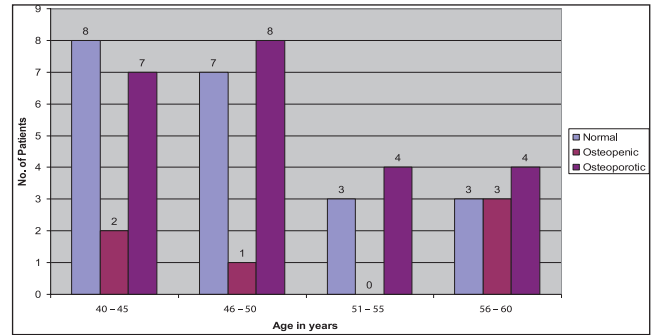


Figure 7: Age-wise distribution of normal, osteopenic and osteoporotic patients confirmed using radiographic indices

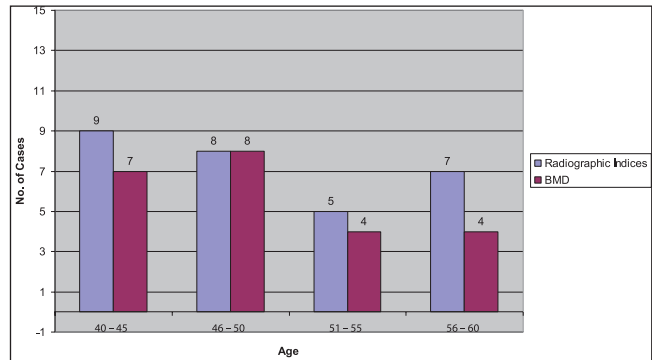


Figure 9: Age-wise comparison of osteoporotic cases as diagnosed by radiomorphometric indices and confirmed by BMD

osteoporotic falls under the same category. Age has been suggested as a useful clinical predictor of osteoporosis by various authors. In our study, it was observed that among the 17 patients in the age group of 56-60 years, 12 were osteoporotic; hence our observation supports the findings of other authors who have stated that risk of developing osteoporosis and incidence of osteoporosis increase with age.^[12]

Recent studies have indicated that a panoramic radiograph may be one of the tools that can be employed to identify individuals with low BMD, high bone turnover, or high risk of osteoporotic fracture. The validity of such a diagnostic tool is dependent upon two factors. First, it is necessary that mandibular BMD relate significantly to that of other sites in the affected skeleton, particularly in individuals with osteoporosis. Second, the sensitivity and specificity of dental panoramic radiographs in reflecting skeletal BMD must be high. In our study, we have used a number of mandibular cortical indices that have been developed to allow quantification of mandibular bone mass and identification of osteoporosis. Thickness of the mandibular cortex at both angles of the mandible (Gonial index [GI]) is more at the anterior region than at the antegonial region (AI, MI and AA). AD and MCI can assess osteoporotic changes in the cortical area of the mandible, using panoramic radiographs.^[13-15]

Dutra *et al.*, (2006) has stated that the mandible also undergoes a change in shape during osteoporotic involution. It was observed by Dutra *et al.*, (2006) that the AA was significantly greater in normal individuals compared with that of low bone mass individuals, and this difference was not affected by age.^[7,16] Also, the AD was significantly greater in osteoporotic and osteopenic patients when compared to normal bone mass individuals. Our study was in accordance with this study.

Dutra and Yang (2005) concluded in their study that there is difficulty of measuring AI and MI in a reproducible manner, but its interaction with dental status and low correlation in younger patients have discouraged its use in detecting patients at risk of osteoporosis.^[8]

Ledgerton *et al.*, evaluated 500 panoramic radiographs of female patients. They evaluated MI and AI, and their relationship with age and dentition, and it was found that both indices demonstrated negative correlation, which was similar to the results obtained by our study. According to our study, AI and MI were not reliable in diagnosing osteoporotic patients. In our study, AI could identify only four patients as osteoporotic among 23 patients because of the reason that there is a continuous remodeling in the mandibular cortex with age and that this is influenced by dental status and gender. Identification of cortical erosion at mental region detected at panoramic radiographs of postmenopausal women results in 73% of correctness in the identification of low mineral bone density. Besides the reproducibility, the validity of these indices, however, depends on their sensitivity and specificity as compared with the bone densitometry results.^[16]

Gulshai *et al.*, in 2008 conducted a study to determine the qualitative and quantitative indices including the MCI for panoramic radiographs to assess the bone quality and to observe signs of resorption of osteoporosis. He also determined the age-related changes that would affect the MCI classification. His study stated that dental panoramic radiography may be one of the tools for detection of high risk osteoporotic fractures. Results of the study suggested that MCI classification based on panoramic radiographs may be a useful index for diagnosis of osteoporosis. There was an age-related increase in the number of individuals with C3 appearance that reflected age-related bone loss. Our study was in agreement with the study done by Gulshai *et al.*^[17]

Our study could not differentiate osteopenic and osteoporotic patients who are C2 and C3. According to a study done by Drozdowska *et al.*, (2002), MCI is a simple three-graded classification of change in the cortex, but its efficacy in diagnosing osteopenic and osteoporotic patient is low to moderate.^[9] In this study, sensitivity of

MCI was 93%, but specificity was 31%. Hence MCI index could be used as a screening tool, but not for diagnosis of osteoporosis. QUS devices measure a number of bone characteristics, including BMD, elasticity, cortical thickness and the microarchitecture of the bone, all of which affect bone strength. In any case, to comply with the need for early detection, researchers have been searching for tools that allow efficient and low-cost screening for osteoporosis. According to Hans *et al.*, (2009) QUS is acceptable, low-cost and a readily accessible alternative to dual X-ray absorptiometry (DXA).^[10] According to our results, 58% of the patients were identified as osteoporotic by RMI, whereas QUS has confirmed 46% patients as osteoporotic and 12% as osteopenic. Statistical correlation was present in between RMI and QUS. Thus, the values of our study were in accordance with few studies that states increased incidence of osteoporosis by QUS. Studies comparing all these indices in a single study have not been frequently found in the literatures and in our study we have made an attempt to do so. On comparing the indices, it was found that GA, AA, AD and MCI were sensitive but not specific in diagnosis of osteoporosis. Panoramic-based RMI can be used as an ancillary method in diagnosis of osteoporosis. By considering the statistical values, radiomorphometric analysis can be utilized for screening of patients in larger population and is a sensitive index for prediction of osteoporotic changes in bone at an earliest stage of particular age group; however, large sample sizes and various other indices may be incorporated in prediction of osteoporotic changes in bone more specifically.

CONCLUSION

The results are suggestive of sensitivity and specificity of panoramic radiograph in diagnosis of osteoporosis, with AGA and ADA being the most reliable indices. Panoramic-based RMI can be used as an ancillary method in diagnosis of osteoporosis.

Financial support and sponsorship

Nil.

Conflict of interest

There are no conflicts of interest.

REFERENCES

1. Stedman T. Stedman's medical dictionary. 26th ed. Baltimore: Williams and Wilkins; 1995.
2. International Osteoporosis Foundation (IOF). Fact Sheet of Osteoporosis. Available form: <http://www.iofbonehealth.org/patients-public/about-osteoporosis> [Last assessed on 2013 Apr 08].
3. Taguchi A, Tsuda M, Ohtsuka M, Kodama I, Sanada M, Nakamoto T, *et al.* Use of dental panoramic radiography in identifying younger postmenopausal women with osteoporosis. *Osteoporos Int* 2006;17:387-94.

4. Lata PF, Elliott ME. Patient assessment in the diagnosis, prevention and treatment of osteoporosis. *Nutr Clin Pract* 2007;22:261-75.
5. Watanabe PC. Morphological study of the Mandibular trabecular bone in panoramic radiographs. *Int J Morphol* 2007;25:875-80.
6. Ceiiareginawinckmahl. Comparison of morphometric indices obtained from dental panoramic radiography of identifying individuals with osteoporosis or osteopenia. *Radiolbris* 2008;41:3.
7. Dutra V, Devlin H, Susin C, Yang J, Horner K, Fernandes AR. Mandibular morphological changes in low bone mass edentulous females: Evaluation of panoramic radiographs. *Oral Surg Oral Med Oral Pathol Oral Radiol Endod* 2006;102:663-8.
8. Dutra V, Yang J, Devlin H, Susin C. Radiomorphometric indices and their relation to gender, age, and dental status. *Oral Surg Oral Med Oral Pathol Oral Radiol Endod* 2005;99:479-84.
9. Drozdowska B, Pluskiewicz W, Tarnawska B. Panoramic-based mandibular indices in relation to mandibular bone mineral density and skeletal status assessed by dual energy X-ray absorptiometry and quantitative ultrasound. *Dentomaxillofac Radiol* 2002;31:361-7.
10. Hans D, Krieg MA. Quantitative ultrasound for the detection and management of osteoporosis. *Salud Publica Mex* 2009;51:S25-37.
11. Verheij JG, Geraets WG, van der Stelt PF, Horner K, Lindh C, Nicopoulou-Karayianni K, *et al.* Prediction of osteoporosis with dental radiographs and age. *Dentomaxillofac Radiol* 2009;38:431-7.
12. Ayranci U, Orsal O, Orsal O, Arslan G, Emeksiz DF. Menopause status and attitudes in a Turkish midlife female population: An epidemiological study. *BMC Women's Health* 2010;10:1.
13. Hastar E, Yilmaz HH, Orhan H. Evaluation of mental index, mandibular cortical index and panoramic mandibular index on dental panoramic radiographs in the elderly. *Euro J Dent* 2011;5:60-7.
14. Atkinson PJ, Woodhead C. Changes in human mandibular structures with age. *Arch Oral Biol* 1968;13:1453-64.
15. Krall EA, Dawson-Hughes B, Papas A, Garcia RI. Tooth loss and skeletal bone density in healthy postmenopausal women. *Osteoporos Int* 1996;4:104-9.
16. Ledgerton D, Horner K, Devlin H, Worthington H. Radiomorphometric indices of the mandible in a British female population. *Dentomaxillofac Radiol* 1999;28:173-81.
17. Gulsahi A, Yüzügüllü B, Imirzalioglu P, Genç Y. Assessment of panoramic radiomorphometric indices in Turkish patients of different age groups, gender and dental status. *Dentomaxillofac Radiol* 2008;37:288-92.