

# Utilizing preprocedural imaging and active fixation lead in cardiac resynchronization therapy device upgrade for persistent left superior vena cava



Christopher Kuo-Wei Chiang, MD,<sup>\*</sup> William Ka-Bo Chan, MD,<sup>†</sup> Aaron So, MD,<sup>‡</sup> Raymond Yee, MD,<sup>†§</sup> Habib Khan, MD, PhD, FHRS<sup>†§</sup>

From the <sup>\*</sup>Department of Internal Medicine, McMaster University, Hamilton, Canada, <sup>†</sup>Department of Cardiology, London Health Sciences Centre, London, Canada, <sup>‡</sup>Robarts Research Institute, Western University, London, Canada, and <sup>§</sup>Department of Cardiology, Schulich School of Medicine and Dentistry, Western University, London, Canada.

## Introduction

Persistent left superior vena cava (PLSVC) is the most common congenital thoracic venous anomaly. For patients requiring cardiac resynchronization therapy (CRT) implantation or upgrade, technical challenges may arise during left ventricular (LV) lead placement owing to the patient's dilated coronary sinus (CS), tortuous coronary venous anatomy, or the inability to perform occlusive venograms to highlight branches suitable for lead placement. Prior case reports have described various strategies to navigate these technical challenges, but a gold-standard implantation technique has yet to be determined.<sup>1-3</sup> We describe a case of using coronary computerized tomography angiography (CCTA) with 3-dimensional (3D) modeling, intraprocedural venoplasty, and an active fixation quadripolar pacing lead in a patient with PLSVC undergoing a CRT pacemaker upgrade.

## Case report

We present a case of an 81-year-old man with dilated non-ischemic cardiomyopathy with NYHA class III symptoms and LV ejection fraction of 15%–20% despite optimal medical therapy. He had a dual-chamber permanent pacemaker inserted in 2003 for intermittent complete heart block and was found to have an isolated PLSVC without right superior vena cava during implant. He had a pulse generator change in 2012 with capping of his right atrial lead owing to persistent

**KEYWORDS** Active fixation lead; Cardiac resynchronization therapy; Computerized tomography angiography; Intraprocedural venoplasty; Persistent left superior vena cava (Heart Rhythm Case Reports 2022;8:50–53)

Financial support: This research did not receive any specific grant from funding agencies in the public, commercial, or not-for-profit sectors. Conflict of interest: The authors involved in this case report declare no conflicts of interests. **Address reprint requests and correspondence:** Dr Habib Khan, Department of Cardiology, Schulich School of Medicine and Dentistry, Western University, 1151 Richmond St, London, Ontario N6A 5C1, Canada. E-mail address: [habib.khan@lhsc.on.ca](mailto:habib.khan@lhsc.on.ca).

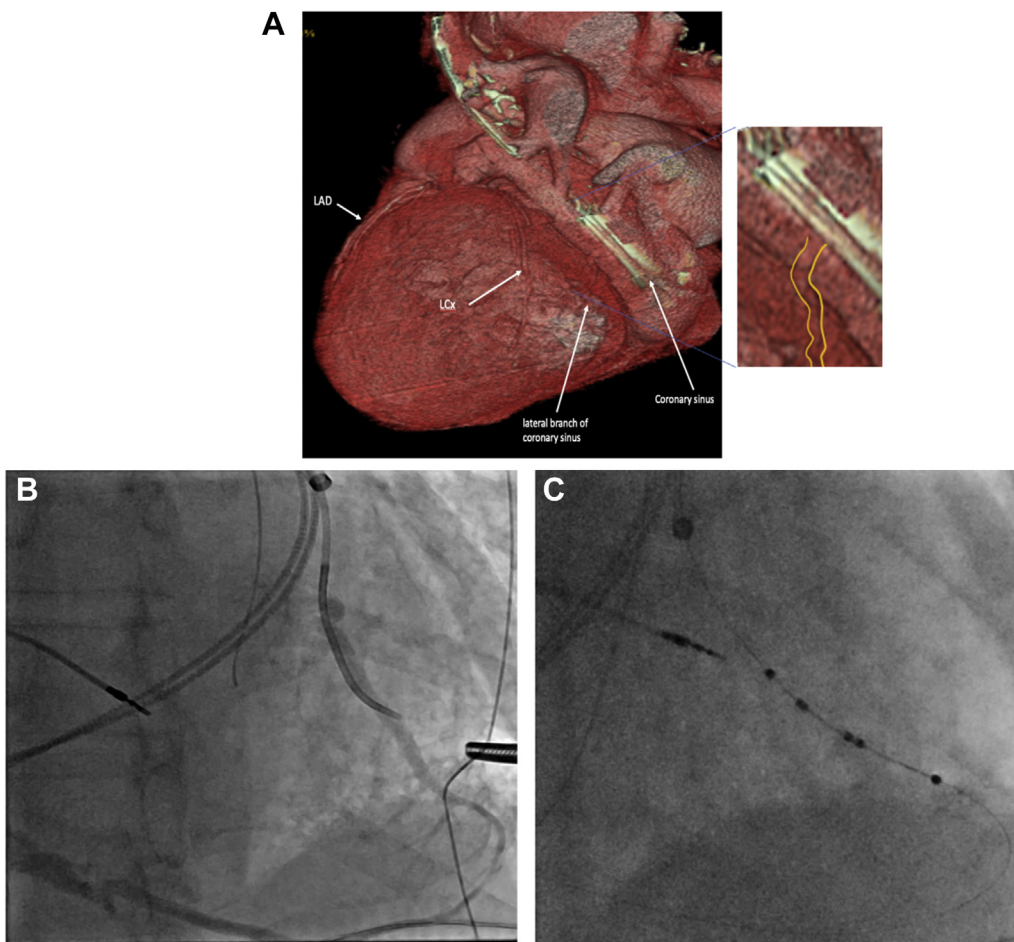
## KEY TEACHING POINTS

- Left-sided superior vena cava upgrades for cardiac resynchronization therapy are rare and difficult to do in persistent left superior vena cava.
- Computed tomography angiography is useful for preprocedural identification and selection of potential targets for left ventricular lead placement.
- Intraprocedural venoplasty assists with successful lead placement.
- Active fixation quadripolar leads increase successful lead placement in challenging coronary venous anatomy.

atrial fibrillation. Over the course of 8 years, his pacing percentage increased to 90%, coinciding with deterioration of his LV function, and his pulse generator battery approached the elective replacement indication.

## Preprocedural preparation

CCTA was completed to acquire anatomical information of the patient's cardiac vasculature, which was then used to generate 3D models. CCTA was completed using a 64-slice volumetric computed tomography (CT) scanner. A test bolus scan using 20 mL of 350 mg/mL of nonionic contrast solution, iohexol, at an injection rate of 4 mL/s was used to determine the acquisition delayed time required for the actual CCTA scan. Fifty milliliters of contrast solution at the same injection rate and concentration was then used for the actual CCTA scan at the following settings: tube voltage of 120 kV, tube current of 600 mA, detector width of 0.625 mm, gantry rotation period of 350 ms. The images were



**Figure 1** A: Labeled 3-dimensional model of the patient's heart and coronary vasculature from a gated cardiac computed tomography angiogram shows a small posterolateral branch arising from the coronary sinus (*inset image*: yellow lines on the margin of vessel). B: Subselective venogram of the branch in left anterior oblique projection reveals the lateral branch as a potential target. C: Active fixation quadripolar lead insertion into the lateral branch over an angioplasty wire.

reconstructed with the standard reconstruction kernel at 0.625 mm slice thickness and 20 cm display field of view. The reconstructed CCTA source images were then used to generate the 3D rendered images of the heart.

The images revealed the 2 existing leads in the PLSVC. There was no communication of the PLSVC with anomalous coronary artery drainage or anomalous communication with the other cardiac chambers. Right-sided SVC was absent. PLSVC images showed 1 small tortuous branch visible over the lateral margin of the left ventricle. The plan was to target this branch (Figure 1A) during the upcoming procedure.

### Procedure

Axillary vein access was obtained under direct fluoroscopy and a 0.032" hydrophilic guidewire was advanced into the CS via the PLSVC. Expectantly, there was stenosis at the proximal PLSVC. Therefore, a 6 × 40 mm noncompliant balloon was used over the guidewire and the vein was serially dilated to the proximal SVC. A standard sheath was then passed over the wire advanced into the CS. An occlusive venogram was not possible owing to the large size of the CS

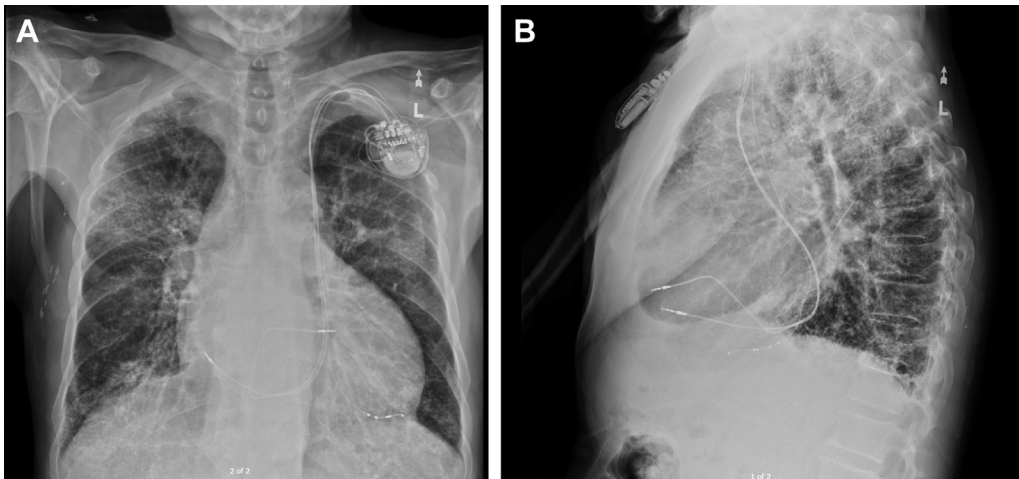
body (36 × 39 mm at the smallest region). Therefore, a braided vertebral subselector sheath was used to selectively access the preidentified lateral branch, which was subsequently opacified with a venogram (Figure 1B).

An additional support wire was used to access the lateral branch and was threaded retrogradely back to the CS body via the middle cardiac vein. An active fixation quadripolar LV lead was advanced over the wire into the lateral branch and fixated (Figure 1C). LV poles 4-3 tested with threshold <2 V @ 0.4 ms pulse width and no phrenic nerve stimulation at 8 V. The right ventricular lead was then connected to the new CRT generator along with the previously abandoned right atrial lead and new LV lead before reinsertion into the pocket. This setup would allow the patient to undergo magnetic resonance imaging scans if required in the future.

Final chest radiography showed reasonable lead positions (Figure 2A and 2B). The patient was discharged on the same day.

### Follow-up

Since the implantation, there have been no recurrences of acute heart failure and the patient described marked



**Figure 2** A: Posteroanterior view of the chest showing final lead placements. B: Lateral view of the chest showing final lead placements attached to cardiac resynchronization therapy pacemaker generator.

improvement in symptoms (NYHA II). During the follow-up after 1, 3, and 6 months, stable electrical parameters and long-term persistence of a narrower QRS wave on surface 12-lead electrocardiogram were observed. A significant early improvement in LV ejection fraction from 15% to 35% was observed after just 6 months of follow-up.

### Discussion:

PLSVC is the most common thoracic venous anomaly. It is present in approximately 0.5% of the general population and up to 10% of patients with congenital heart disease.<sup>4,5</sup> It is formed from a failure of the left common cardinal vein and caudal section of the left superior cardinal vein to regress during embryologic development.<sup>4</sup> In about 90% of cases, PLSVC presents with a coexistent right SVC.<sup>4,5</sup> However, right SVC atresia leads to isolated PLSVC, which can be associated with cardiac situs disorders and other congenital cardiac anomalies, including shunt lesions, conotruncal malformations, left-sided obstructive lesions, and single ventricular anomalies.<sup>4-8</sup> Unless cardiac anomalies are present, PLSVC is often asymptomatic and typically an incidental finding on diagnostic imaging and therapeutic cardiac interventions, such as during device implantation.<sup>4,5</sup>

Clinically, PLSVC is commonly associated with lead manipulation and placement challenges owing to coronary vessel tortuosity.<sup>4</sup> Few PLSVC case reports describe success in CRT lead placement. Strategies with varying success are employed, including the use of a bipolar active fixation LV lead or multimodality imaging to depict coronary venous anatomy for selection of potential target veins.<sup>1,2,9</sup> However, it still remains a technically challenging procedure complicated by an individual's unique coronary sinus anatomy with a predisposition towards de novo right-sided implants to circumvent the challenges of the PLSVC. To the extent of our knowledge, our case report is the first to incorporate the combination of preprocedural CCTA with 3D modeling, venoplasty of a stenosed proximal PLSVC, and active

fixation of a quadripolar lead in a patient with PLSVC undergoing CRT upgrade.

Multimodality imaging has evolved from research purposes to being used in clinical aspects of patient management. CT angiography provides a rapid, noninvasive, and accurate delineation of anatomical structures and is particularly useful to highlight vascular structures. Realistic 3D models of the heart and coronary vasculature can be created, which can help inform patients about their upcoming procedure as to whether they are a candidate or not and can be used as educational training tools. This is particularly useful in guiding preprocedural planning for difficult interventional cases or for those with congenital heart disease.<sup>10,11</sup> In this case, the CT angiograms and 3D modeling were used to identify the single branch of the coronary sinus that was patent and a target for LV lead placement.

During CRT upgrade procedures, it is not unexpected to encounter stenosis of proximal central veins. Venoplasty is arguably necessary to navigate past the stenosed area to proceed with successful lead placement, as demonstrated in our case. However, one of the main challenges that still remains in patients with PLSVC is proper lead placement, lead stability, and preventing lead dislodgement.<sup>12</sup> During left-sided placement, it can be technically challenging to advance and correctly position the defibrillator lead in the right ventricle owing to the sharp takeoff between the CS opening into the right atrium and the tricuspid valve. The number of turns that the lead must make to reach this destination increases the risk for dislodgement.<sup>13</sup> In addition, there is higher volume and velocity flow toward the coronary sinus, which tends to displace the lead retrogradely. This can be circumvented using a quadripolar active fixation lead, which contains a unique helix mechanism for fixation that facilitates precise placement and improves lead stability.<sup>1,2</sup> In addition to increasing pacing vectors from 4 location, quadripolar fixation leads are designed to reduce the risk of lead dislodgement and to prevent over-rotation and vein tissue pinching.<sup>2</sup> With these advantages compared to nonfixation

quadripolar leads, this lead has the potential for use in most types of coronary venous anomalies, especially in those with PLSVC.<sup>2</sup>

## Conclusion

LV lead placement can be technically challenging in patients with PLSVC owing to their unique and complex anatomical variation. In patients with PLSVC, the concurrent use of preprocedural CT angiography, venoplasty, and placement of an active fixation quadripolar lead improves the chance of successful pacing vectors and safe CS lead placement. Preprocedural imaging confirms the presence or absence of associated PLSVC cardiac anomalies and enables the selection of appropriate tools to improve lead placement and stability. This approach is a viable alternative to de novo right-sided CRT implantation in dual SVC patients and those with right SVC atresia.

## References

1. Conti S, Taormina A, Bonomo V, Giordano U, Sgarito G. CRT-D upgrading in a patient with persistent left superior vena cava and right superior vena cava atresia using the novel active-fixation quadripolar left ventricular lead. *World J Cardiovasc Dis* 2018;8:462–466.
2. Caravati F, Golino M, Damiani G, et al. Active fixation coronary sinus lead in a patient with persistence of left superior vena cava. *Clin Case Rep* 2020; 8:1642–1646.
3. Nair GM, Shen S, Nery PB, Redpath CJ, Birnie DH. Cardiac resynchronization therapy in a patient with persistent left superior vena cava draining into the coronary sinus and absent innominate vein: a case report and review of literature. *Indian Pacing Electrophysiol J* 2014;14:268–272.
4. Azizova A, Onder O, Arslan S, Ardali S, Hazirolan T. Persistent left superior vena cava: clinical importance and differential diagnoses. *Insights Imaging* 2020; 11:1–9.
5. Irwin RB, Greaves M, Schmitt M. Left superior vena cava: revisited. *Eur Heart J Cardiovasc Imaging* 2012;13:284–291.
6. Perles Z, Nir A, Gavri S, et al. Prevalence of persistent superior vena cava and association with congenital heart anomalies. *Am J Cardiol* 2013;112:1214–1218.
7. Ari ME, Doğan V, Özgür S, et al. Persistent left superior vena cava accompanying congenital heart disease in children: experience of a tertiary care center. *Echocardiography* 2017;34:436–440.
8. Berg C, Knüppel M, Geipel A, et al. Prenatal diagnosis of persistent left superior vena cava and its associated congenital anomalies. *Ultrasound Obstet Gynecol* 2006;27:274–280.
9. Nguyễn UC, Cluitmans MJ, Luermans JG, et al. Visualisation of coronary venous anatomy by computed tomography angiography prior to cardiac resynchronisation therapy implantation. *Neth Heart J* 2018;26:433–444.
10. Kanawati J, Kanawati AJ, Rowe MK, Khan H, Chan WK, Yee R. Utility of 3-D printing for cardiac resynchronization device implantation in congenital heart disease. *HeartRhythm Case Rep* 2020;6:754–756.
11. Batteux C, Haidar MA, Bonnet D. 3D-printed models for surgical planning in complex congenital heart diseases: a systematic review. *Front Pediatr* 2019; 7:23.
12. Habu MC, Ursaru AM, Petriş AO, Popescu ŞE, Tesloianu ND. Implantation of a dual-chamber automatic cardioverter defibrillator in a patient with persistent left superior vena cava: case report and brief literature review. *Diagnostics* 2020; 10:1071.
13. Abdalwahid KF, Chu GS, Nicolson WB. A case report: upgrade to cardiac resynchronization therapy with a blocked persistent left-sided superior vena cava. *Eur Heart J Case Rep* 2020;4:1–5.