



## Case report

## Blunt renal trauma in ureteropelvic junction obstruction kidney: A case report

Andri Pratama Kurniawan<sup>\*</sup>, Kuncoro Adi

Department of Urology, Faculty of Medicine University of Padjadjaran, Hasan Sadikin Hospital Bandung, Bandung, West Java, Indonesia

## ARTICLE INFO

## Keywords:

Ureteropelvic junction obstruction  
Renal trauma  
AAST  
Renal exploration  
Nephrectomy

## ABSTRACT

**Introduction:** Kidneys are one of the most commonly affected retroperitoneal organ in trauma cases despite its relatively well-protected location. Renal trauma occurs in 80–95% of urogenital trauma cases and 8–10% of abdominal blunt trauma. Renal trauma in hydronephrotic kidney due to *ureteropelvic junction obstruction* (UPJO) is a rare entity, despite of high risk of trauma urogenital due to large size and thin parenchyma. In this case we reported blunt renal injury with a congenital abnormality of the kidney.

**Case presentation:** We present a case of abdominal blunt trauma due to motor-vehicle accident in a 23 year old male patient. The patient complaint of visible hematuria since 1 day after falling from motorcycle with right flank hit the road, accompanied with right flank pain. Vital signs were within normal limits. Physical examinations reveal distention of right flank with no sign of peritonitis. Supporting examination with FAST ultrasound revealed grade 4 hydronephrosis with internal echo, suspected blood accumulation inside the kidney. Abdominal CT scan revealed grade IV hydronephrosis of right kidney with thin parenchyma. We performed laparotomy and renal exploration, intraoperatively we found multiple laceration of the kidney into pelvicalyceal system (AAST grade IV) with hematoma inside the right kidney and UPJ stenosis (about 5 cm). We decided to perform right nephrectomy despite of grade IV injury with consideration of poor renal function, long stenosis segment and thin renal parenchyma will cause many complications in the future for the patient.

**Conclusion:** Renal injury in UPJO kidney is a rare entity despite of high risk of injury in this population. Management of renal injury in this population might be not consistent with guideline for renal trauma, and clinical judgement from the physician plays an important role to provide the best treatment for this patient.

## 1. Introduction

Renal is a common injury organ in urogenital trauma even it is protected with other structures. 80–95% of renal trauma cases usually happen with other structures/organ trauma also. The majority of the renal trauma is blunt trauma, usually in motor vehicle accident (63%) [1]. Diagnosis and Treatment for renal trauma usually non-operative management, except the patient was founded with unstable hemodynamic, such as hypotension. Majority of the renal trauma case usually mild if calculated with AAST classification [1,2]. (See Figs. 1–5.) (See Table 1.)

Ureteropelvic Junction Obstruction (UPJO) is a congenital anomaly in urogenital disease. This condition is a risk factor for higher grade injury in trauma cases. One in 1750 pediatric population born with UPJO. Patients usually has a complaint, such as abdominal or waist pain concurrent with urinary tract infection. Other sign and symptoms, such

as scrotal pain, sandy urine, pyelonephritis and decreased kidney function (from Renal function test) and haematuria [3].

One problem with UPJO concurrent with renal trauma is hydronephrosis. These problems cause damage in renal parenchym without significant bothering sign and symptoms. This case report is discussing about UPJO patient with renal trauma. There are about 5.5% adult population with history of renal disorder, one of them is UPJO, has concurrent renal trauma. Epidemiological data showed there is no significant data about UPJO and renal trauma.

This case report is written following the Surgical Case Report (SCARE) criteria [4].

## 2. Case presentation

A 23 years old-man came to the emergency room of Hasan Sadikin Hospital complained of reddish color urine since a day ago. No blood

<sup>\*</sup> Corresponding author.

E-mail address: [andrip1322@gmail.com](mailto:andrip1322@gmail.com) (A.P. Kurniawan).

<https://doi.org/10.1016/j.ijscr.2022.107005>

Received 28 February 2022; Received in revised form 27 March 2022; Accepted 27 March 2022

Available online 30 March 2022

2210-2612/© 2022 The Authors. Published by Elsevier Ltd on behalf of IJS Publishing Group Ltd. This is an open access article under the CC BY-NC-ND license (<http://creativecommons.org/licenses/by-nc-nd/4.0/>).

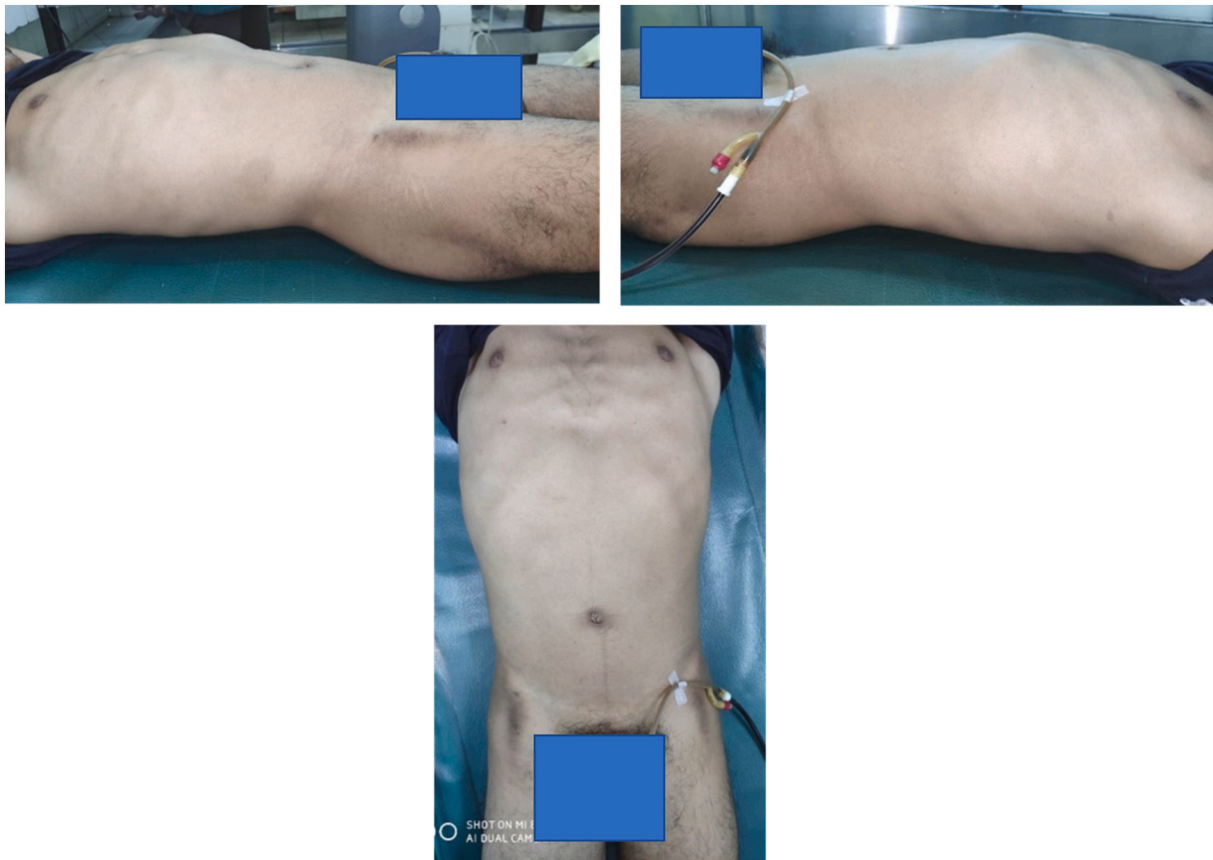


Fig. 1. Patient photo during physical examination.

clots or pain were found while urinated. The patient had a motorcycle accident a day ago and fell forward with the right waist part fell first. Patients complaints of vomited. The patient had no history of urolithiasis or sandy urine, and urine had murky color. The patient doesn't have history of hypertension, diabetes or previous urological surgery.

On physical examination, vital signs are within normal limits. Blood pressure is 110/70 mmHg, pulse is 100 x/min, CRT is 22 s and warm. In urological examination, there was founded red urine after insertion of Foley's 18 Fr. catheter.

In FAST ultrasound examination there was the presence of fluid collection in retrovesica. No free fluids were found in RUQ, LUQ, and subxiphoid.

CT scan of the abdomen with contrast revealed pyohydronephrosis, pelvoectasis of the left kidney, hepatomegaly, and cystitis.

The patient was planned for exploratory laparotomy and exploration of the right kidney. In intraoperative findings, there was a hematoma in right zone I and zone II, peritoneal fluid mixed with blood was found. There was no hematoma, no bulging and no expansion to the left zone I. There was retroperitoneum hematoma about 1000 ml, a 5 cm laceration in the upper pole of the right kidney and 5 cm long UPJ stenosis in the right kidney. Then, it was decided to do right nephrectomy.

Based on the physical examination, supporting examination (with CT scan), and intra-operative findings, the working diagnosis determined in this case was post-exploratory laparotomy + right nephrectomy a.i gross hematuria e.c. right kidney trauma AAST grade IV e.c. Blunt abdominal trauma in right kidney UPJO patient.

### 3. Discussion

The American Association for the Surgery of Trauma (AAST) has classified kidney trauma on a scale ranging from 1 to 5 (1 being the mildest; 5 being the most severe). The AAST classification is a predictor of

morbidity in blunt or sharp trauma to the kidney. In addition, the classification system has a statistically significant correlation for the need for surgical treatment (ranging from 0% to 93%) and the risk of nephrectomy (0–86%). The distribution of the number of cases according to the AAST classification was 22–28% for grade I, 28–30% for grade II, 20–26% for grade III, 15–19% for grade IV, and 6–7% for grade V [1].

The kidney is a retroperitoneal organ that is quite protected, however, it is one of the most frequently injured genitourinary organs in trauma. Renal trauma is more common with other injuries (in 80–95% of cases) but can also occur as an isolated injury. Most of the renal trauma occurred in men (72–93% of cases) with a peak incidence is found at the age of 31–38 years. The peak incidence of penetrating kidney trauma occurs at a younger age, which is 27–28 years. Renal trauma was found in other trauma cases in 0.3–3.25% [1].

The causes of kidney trauma are divided into blunt trauma and sharp trauma. Blunt trauma occurs for 71–95% of cases with renal trauma. A systematic review by Volezke and Leddy found that blunt trauma to the kidneys was found in motor vehicle accidents (63%), falls (43%), sports injuries (11%), and walking accidents (4%). The same systematic review also found that the causes of renal trauma in children were falls (27%) and walking accidents (13%), and a lower incidence of renal trauma in motor vehicle accidents (30%). A more detailed division was carried out by McAleer et al. for children, namely caused by falling from a bicycle (28%), falling (23%), playing small motorized vehicles (8%), falling on a playground (8%), falling from motorcycles (6%), sports injuries (6%), rollerblading (6%), and others. From this study, it was not found that renal trauma resulted in loss of function of one or two kidneys [1,2].

The first evaluation carried out in case of renal trauma is the evaluation of the patient's hemodynamic state. The *Societe Internationale d'Urologie* (SIU) guidelines define a stable hemodynamic state as a systolic blood pressure above 90 mmHg. Patients with visible hematuria

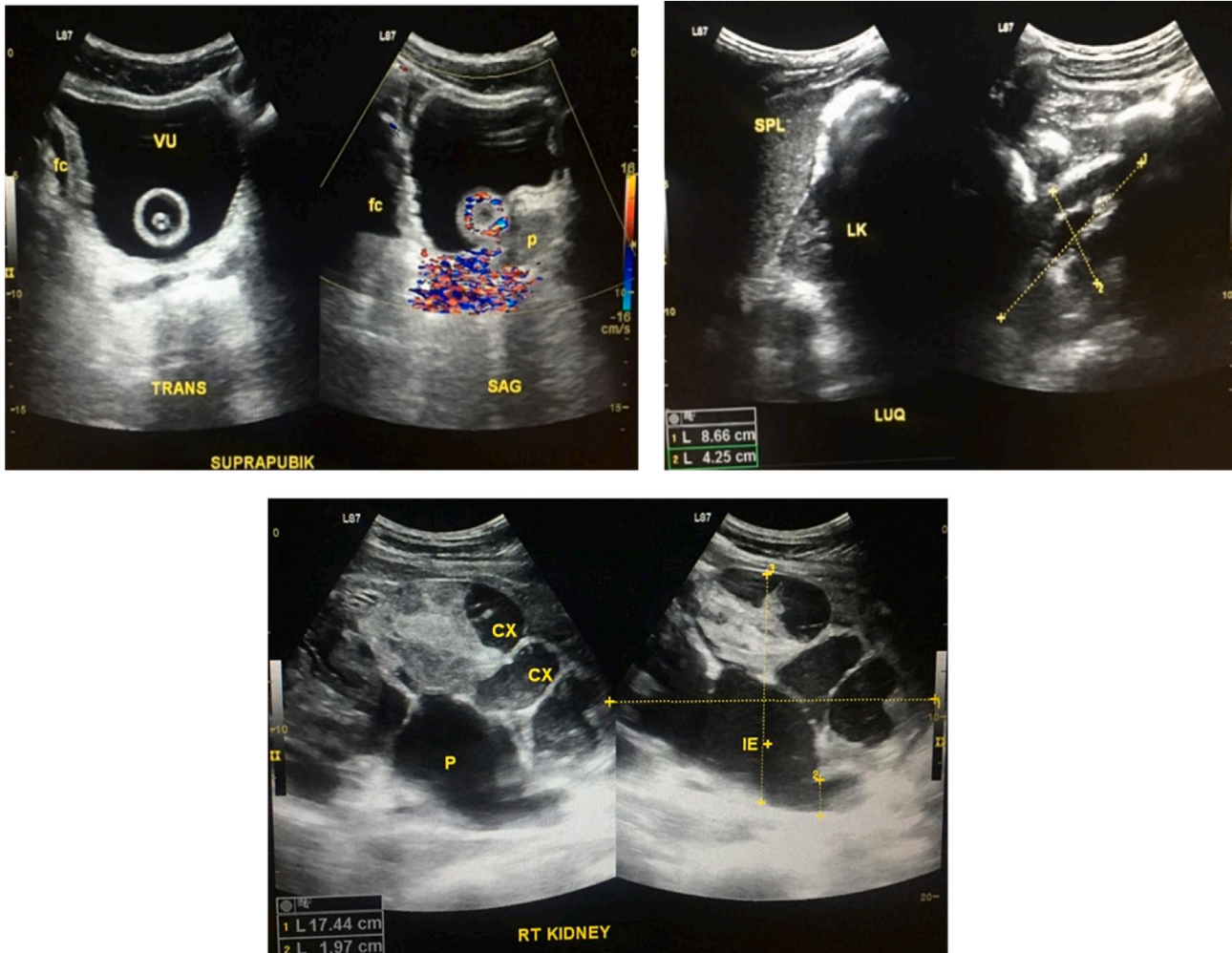


Fig. 2. Ultrasonografi FAST.

require further examination to determine the degree of renal trauma and other sites of trauma, especially sharp trauma [6].

Supporting examination that commonly used to diagnose renal trauma are abdominal or pelvic CT scans. A CT scan can use contrast to determine the degree of trauma to the kidney and can examine other organs that may be involved in the trauma. In addition, CT scan is also able to visualize the ureter and contralateral kidney [5,6].

The main management of renal trauma is to stop bleeding, maintain nephron function, and reduce complication rates. Management of early renal trauma focuses on operative management on the grounds that reconstruction of secondary damage that occurs, such as vascular and *ureteropelvic junction* (UPJ) damage is the most important stage of management to prevent the need for nephrectomy. Current management is starting to use non-operative management when needed to prevent complications from unnecessary operative treatment.

Interventions in renal trauma are based on absolute indications and relative indications. The absolute indications for such intervention are hemodynamic instability and no response after aggressive fluid resuscitation (which is usually due to renal hemorrhage, grade V renal trauma, and pulsatile and/or diffuse hematoma). Relative indications for interventional renal trauma are large laceration of the renal pelvis, avulsion of the UPJ, there is damage to the digestive system or pancreas, persistent urine leakage, and a post-traumatic urinoma or perinephric abscess that cannot be treated with an endoscopic or percutaneous approach. Other relative indications are abnormal IVP examination, devitalization of the renal parenchyma that occurs with leakage of urine, complete thrombosis of the renal arteries in one or both kidneys, and

renal vascular damage that cannot be treated with an angiographic approach [1].

The non-operative approach to renal trauma consists of supportive management accompanied by bed rest and monitoring of vital signs and examination of renal function. Minimally invasive renal trauma interventions (such as angioembolization or ureteral stenting) are used as indicated. Non-operative management of renal trauma covers 84–95% of all cases of renal trauma with 2.7–5.4% of these non-operative treatments fail. Complications that arise in patients with kidney trauma can also be managed non-operatively [1].

Renal exploration is recommended in hemodynamically unstable patients. This exploration can be done by means of a laparotomy. The SIU recommendation is to perform peritoneal exploration if an enlarged or pulsatile retroperitoneal hematoma is found. Bleeding control needs to be done before opening the capsule to get a better post-operative outcome [6].

Early complications of renal trauma are bleeding, infection, perinephric abscess, sepsis, urinary tract fistula, hypertension, urinary extravasation, and urinoma. Further complications of renal trauma are bleeding, hydronephrosis, calculus formation, chronic pyelonephritis, and pseudo-aneurysms. Most of these complications can be managed without surgery with percutaneous or endourological management. Renal trauma only causes hypertension in 5% of cases [1].

Obstruction of the UPJO is a pathological process that can cause hydronephrosis in children. About 1 in 750–1500 children are born with UPJO with a 2:1 ratio for boys to girls. In 10–46% of cases, UPJO occurs bilaterally. There are several theories regarding the occurrence of UPJO,



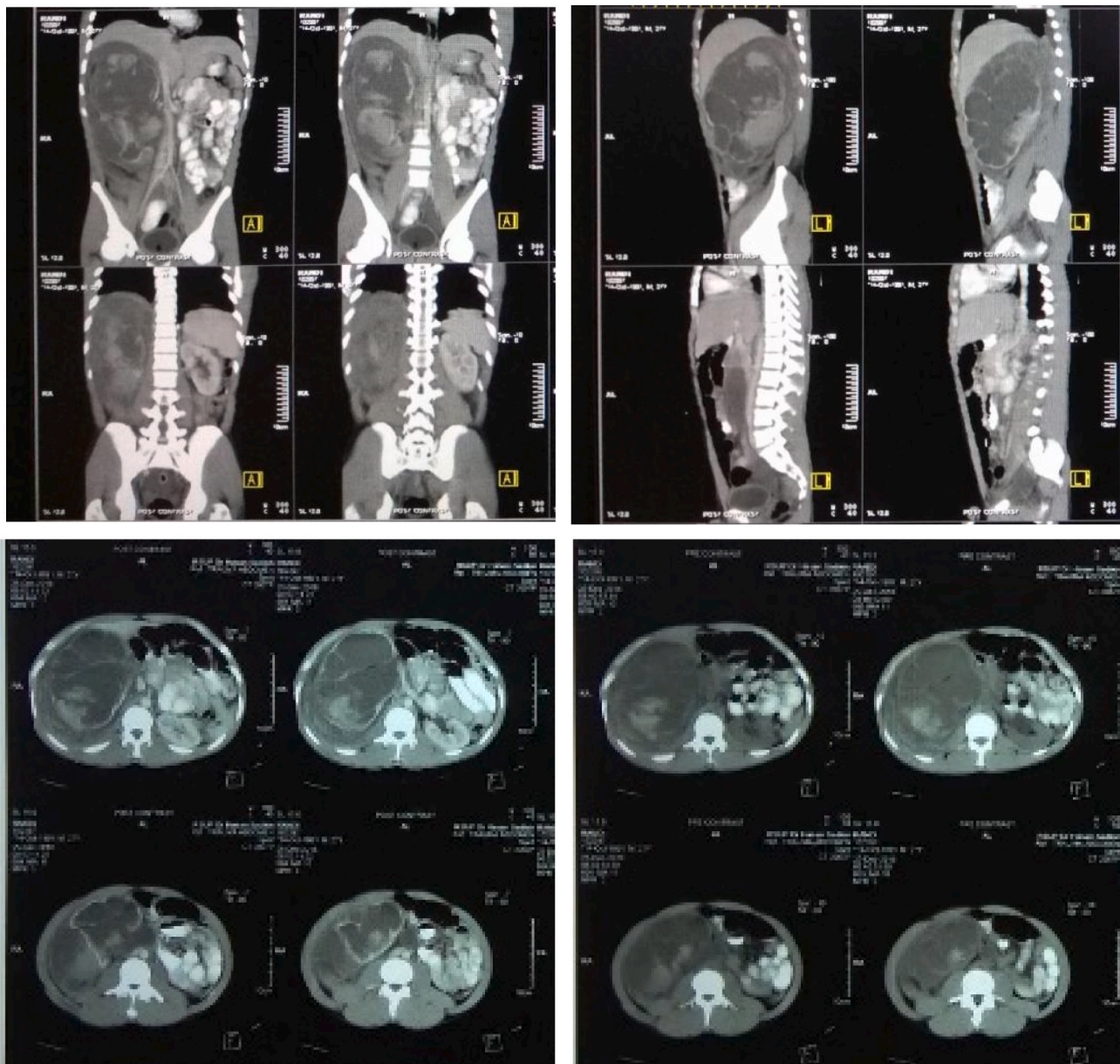


Fig. 3. CT scan abdomen with contrast.

namely damage to the ureteral valve leading to stenosis and decreased number of nerves and ureteral hypoplasia. In adults, secondary causes of UPJO, especially in cases that also cause renal trauma, are cases that are rare and still unknown for the epidemiological data [7,8].

The diagnosis of *ureteropelvic junction obstruction* (UPJO) is through examination of the urinary flow. UPJO patients generally complain of several symptoms such as abdominal or low back pain with recurrent urinary tract infections. Some other signs and symptoms such as pain in the testicles, discharge of sand when urinating, pyelonephritis, impaired kidney function (through kidney function tests) and hematuria [3].

The diagnosis of UPJO is from radiographic examination. Examination using a CT scan is the standard for establishing the diagnosis of UPJO with a sensitivity of 97% and specificity of 92%. The use of MRI can also be used. The advantage of using CT and/or MRI is that it provides detailed anatomic information about the obstruction (location, orientation, and vessel damage) and identification of the cause of the obstruction (such as calculus or urothelial tumor). Renography is one of the other tests that can be used to assess kidney function. Renography uses radioisotopes with short half-lives to determine the location and

degree of obstruction [3].

Indications for operative management in adult patients with UPJO are significant voiding signs and symptoms, impaired renal function with renography examination, presence of kidney stones, and occurrence of hypertension. The goals of treatment are to improve renal drainage, renal function, and reduce signs and symptoms associated with the obstruction. The outcome that was assessed after the surgical procedure was renal function.

There are various operative methods for the management of UPJO. Open pyeloplasty has been one of the standard for handling UPJO for a long time. The technique most often used is *dismembered repairs* popularized by Anderson and Hynes in the mid-20th century or also called *Anderson-Hynes dismembered pyeloplasty*. A more minimally invasive technique is endopielotomy which consists of antegrade (percutaneous) endopielotomy and retrograde (ureteroscopy) endopielotomy. Other methods using laparoscopy have also been used with considerable success [9].

Kidneys with congenital abnormality (such as UPJO) are more susceptible to damage in the trauma event. There were 6 cases of



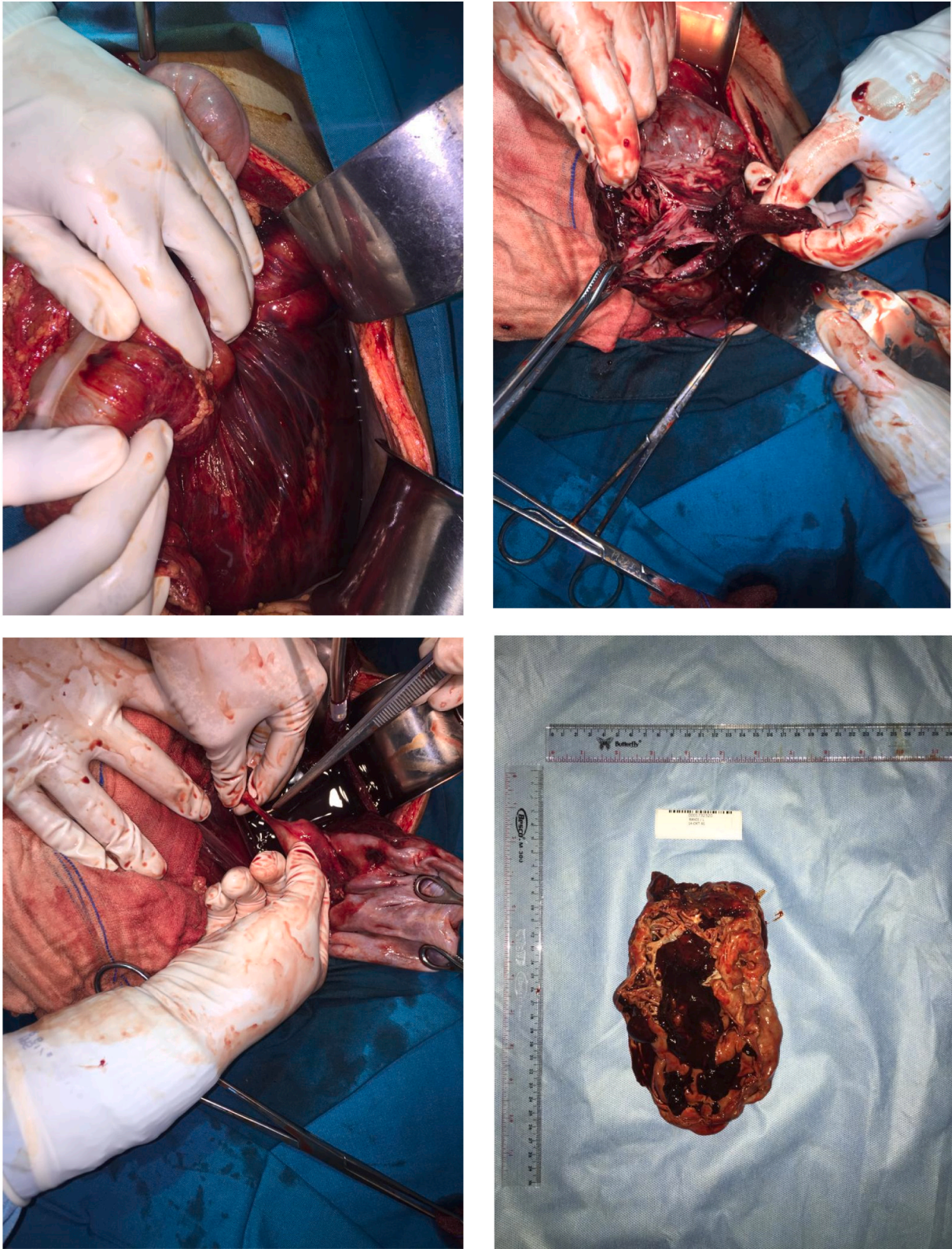


Fig. 4. Intraoperative findings.

hydronephrosis due to UPJO which were found after trauma to the kidney. Research by Sebastia et al. found (through a CT scan of the kidney) characteristics of UPJO as a thinner kidney parenchyma and less parenchymal contrast compared to healthy kidneys. Other studies have found that about 4.4% of adult patients and 15.4% of pediatric patients

with blunt renal trauma have pre-existing renal disease. Of all these cases, it was found that 50% had signs of hydronephrosis, where most of these cases had no symptoms of hydronephrosis.

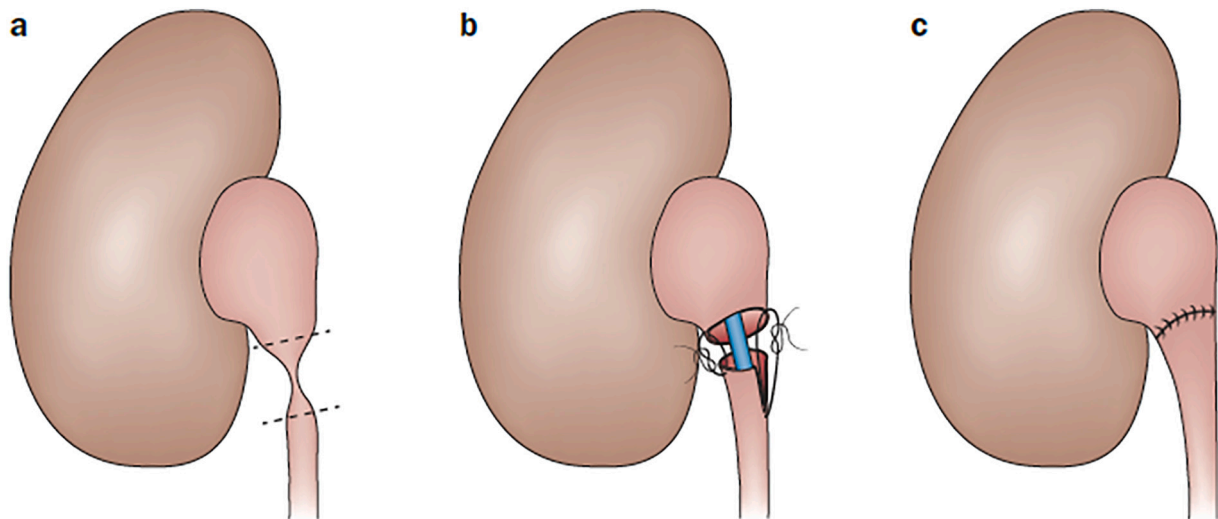


Fig. 5. Anderson-Hayes Pyeloplasty [9].

**Table 1**  
AAST renal trauma classification [1].

Grade	Type of injury	Description
I	Contusion	Microscopic/visible hematuria, normal renal function
	Hematoma	Subcapsular and non-spreading injury, not associated with parenchymal lacerations
II	Hematoma	Perirenal hematoma doesn't spread and present in the retroperitoneum
	Laceration	Renal cortical laceration depth < 1.0 cm without urinary extravasation
III	Laceration	Renal cortical laceration depth > 1.0 without collecting system rupture or urinary extravasation
IV	Laceration	Parenchymal lacerations extending through the renal cortex, medulla, and collecting system
V	Vascular	Renal vein or artery damage with non-spreading bleeding
	Laceration	Kidney destroyed (crushed)
	Vascular	Renal hilum avulsion leading to loss of renal vasculature

#### 4. Conclusion

Renal trauma in UPJO patients is a rare but this population has a high risk for trauma, this is due to the enlarged kidney size and thin renal parenchyma. Management of renal trauma in this population may not conform to guidelines for renal trauma, and clinical judgement from the physician plays an important role in determining the best therapy for the patient.

#### Sources of funding

This research did not receive any specific grant from funding agencies in the public, commercial, or not-for-profit sectors.

#### Ethical approval

This study has received ethical approval at our institution.

#### Consent

Written informed consent was obtained from the patient for publication of this case report and accompanying images. A copy of the written consent is available for review by the Editor-in-Chief of this journal on request.

#### Authors' contribution

Andri P was responsible for the diagnosis and treatment of the disease. Manuscript was prepared by both of the author and the final version of the manuscript is approved by both of the author.

#### Provenance and peer review

Not commissioned, externally peer-reviewed.

#### Research registration number

Not applicable.

#### Guarantor

R. Ayu Hardianti Saputri, ORLHNS specialist at Padjadjaran University/Dr. Hasan Sadikin General Hospital, Bandung.

#### Declaration of competing interest

The authors declare that there is no conflict of interest.

#### References

- [1] T. Erlich, N.D. Kitrey, Renal trauma: the current best practice, *Ther. Adv. Urol.* 10 (10) (2018) 295–303.
- [2] B.B. Voelzke, L. Leddy, The epidemiology of renal trauma, *Transl. Androl. Urol.* 3 (2) (2014) 143–149.
- [3] F. Khan, K. Ahmed, N. Lee, B. Challacombe, M.S. Khan, P. Dasgupta, Management of ureteropelvic junction obstruction in adults, *Nat. Rev. Urol.* 11 (2014) 629.
- [4] R.A. Agha, T. Franchi, C. Sohrabi, G. Mathew, A. Kerwan, A. Thoma, et al., The SCARE 2020 guideline: updating consensus surgical CASE REport (SCARE) guidelines, *Int. J. Surg.* 84 (2020) 226–230.
- [5] M.C. Sebastia, M. Rodriguez-Dobao, S. Quiroga, E. Pallisa, M. Martinez-Rodriguez, A. Alvarez-Castells, Renal trauma in occult ureteropelvic junction obstruction: CT findings, *Eur. Radiol.* 9 (4) (1999) 611–615.
- [6] D.J. Bryk, L.C. Zhao, Guideline of guidelines: a review of urological trauma guidelines, *BJU Int.* 117 (2) (2016) 226–234.
- [7] H. Hashim, C. Woodhouse, Ureteropelvic Junction Obstruction, 2012, 25–32 p.
- [8] M.C. Sebastia, M. Rodriguez-Dobao, S. Quiroga, E. Pallisa, M. Martinez-Rodriguez, A. Alvarez-Castells, Renal trauma in occult ureteropelvic junction obstruction: CT findings, *Eur. Radiol.* 9 (4) (1999) 611–615.
- [9] F. Khan, K. Ahmed, N. Lee, B. Challacombe, M.S. Khan, P. Dasgupta, Management of ureteropelvic junction obstruction in adults, *Nat. Rev. Urol.* 11 (11) (2014) 629–638.