



Value of intestinal ultrasound in pediatric magnet ingestion: a case report

Cristina Bucci¹ · Dolores Ferrara² · Paolo Quitadamo¹ · Casimiro Del Monaco³ · Flora Caruso¹ · Giovanni Gaglione³ · Francesco Esposito² · Mariano Caldore¹

Received: 21 August 2021 / Accepted: 6 October 2021
© Società Italiana di Ultrasonologia in Medicina e Biologia (SIUMB) 2022

Abstract

Ingestion of magnetic foreign bodies in pediatric settings has become more common in the last years due to the marketing of various toys containing small magnetic parts. Most magnets, especially if a single element is ingested, usually pass through the gastrointestinal tract without complications. However, ingestion of multiple magnets or magnets and small metallic components may require a prompt intervention due to the risk of attraction across bowel layers, leading to pressure necrosis, perforation, and even death. Routinely, serial radiological evaluations are needed to follow the progression of magnets through the intestine, while the role of small bowel ultrasound is regarded as marginal. Here we report a case of a 5-years old boy who ingested 8 magnets and in which small bowel ultrasound was pivotal for the correct assessment of magnets location to correct address the surgical approach.

Keywords Magnets · Ingestion · Pediatric · Ultrasound · Diagnosis

Introduction

Ingestion of magnetic foreign bodies in pediatric settings has become more common in the last years due to the marketing of various toys containing small magnetic parts. Most magnets, especially if a single element is ingested, usually pass through the gastrointestinal tract without complications. However, ingestion of multiple magnets or magnets and small metallic components may require a prompt intervention due to the risk of attraction across bowel layers, leading to pressure necrosis, perforation, and even death [1, 2]. Here we report a case of a 5 years old boy who ingested eight magnets and in which the pre-surgical diagnosis was made by small bowel ultrasound.

Case report

A 5-year old boy, otherwise healthy, came to the emergency department with a 3-h history of multiple magnet beads ingestion. After the first clinical assessment, a chest and abdomen radiography (X-Ray) showed seven small round magnets in the stomach and 1 in the right iliac fossa (Fig. 1); the latter was ingested hours before the others, unwitnessed by the parents. The endoscopist was then alerted, and an urgent upper endoscopy was organized. Due to the delay in receiving the SARS-COV-2 test, the endoscopy was performed after 2 h. The endoscopist required a new abdominal X-ray to evaluate the position of the magnets before the procedure. The last X-ray showed that magnets had migrated beyond the ligament of Treitz, making the upper endoscopy useless.

The patient was therefore admitted to a surgical ward for close follow-up. On day 2, the patient showed no symptoms, normal blood analysis, and a routine abdominal examination. A new X-ray examination showed that the 7 upper magnets had reached the magnet located in the right iliac fossa, forming a little chain, apparently without the interposition of intestinal loops. A wait-and-see strategy was then planned to allow a spontaneous passage of the magnets, facilitating its progression with

✉ Cristina Bucci
cristinabucci@hotmail.it

¹ Endoscopy and Gastroenterology Unit, Santobono-Pausilipon Children Hospital, Naples, Italy

² Radiology Department, Santobono-Pausilipon Children Hospital, Naples, Italy

³ Pediatric Surgery Department, Santobono-Pausilipon Children Hospital, Naples, Italy

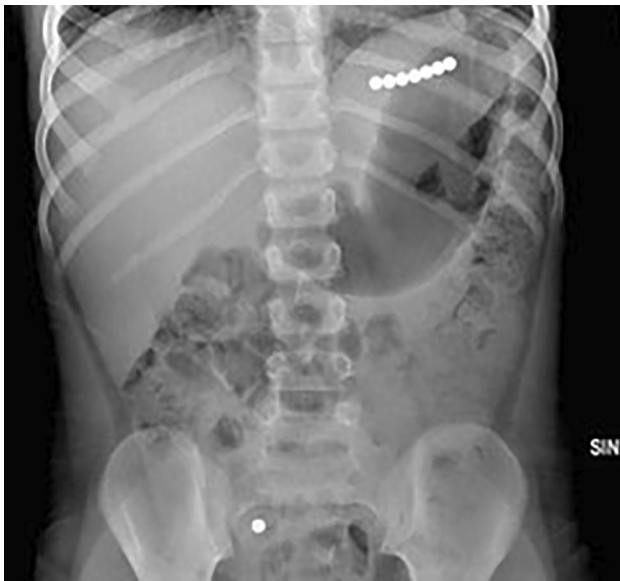

Fig. 1 Basal abdominal X-Ray showing 7 magnets in the epigastric area and one in the right iliac fossa

polyethylene glycol administration. On day 3, the patient was asymptomatic, with no sign of perforation. Another abdominal X-ray and small bowel ultrasound (US) were performed. Although the X-ray showed the little magnets chain in a substantially unchanged position and all regularly spaced (Fig. 2A), the small bowel US clearly showed that there were a gap in the magnet chain as one of them was located in a different intestinal loop and that adjacent intestinal small bowel walls were trapped between two magnets (Fig. 2B). A surgical minilaparotomic approach was planned. The inspection of the whole small bowel revealed two small bowel loops hardly adherent with an initially covered perforation, as shown in Fig. 3. Enterostomy allowed the retrieval of 7 magnets in a loop and the other one in the contiguous loop and perforation's repair. The patient recovered well and was discharged on day 4.

Fig. 2 **A** the abdominal X-Ray performed on day three after ingestion, showing all magnetic beads in a single chain; **B** the US imaging showing the interposition of bowel walls between the last two magnetic beads (arrows)

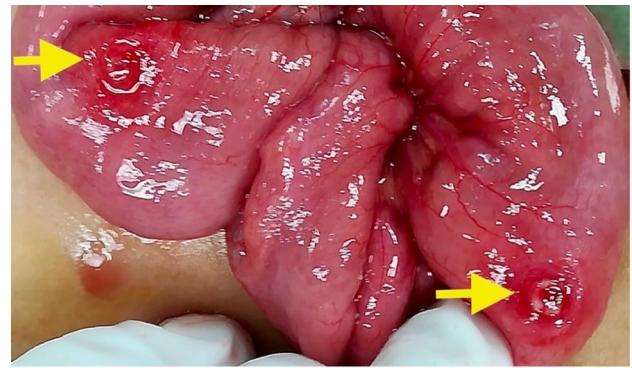
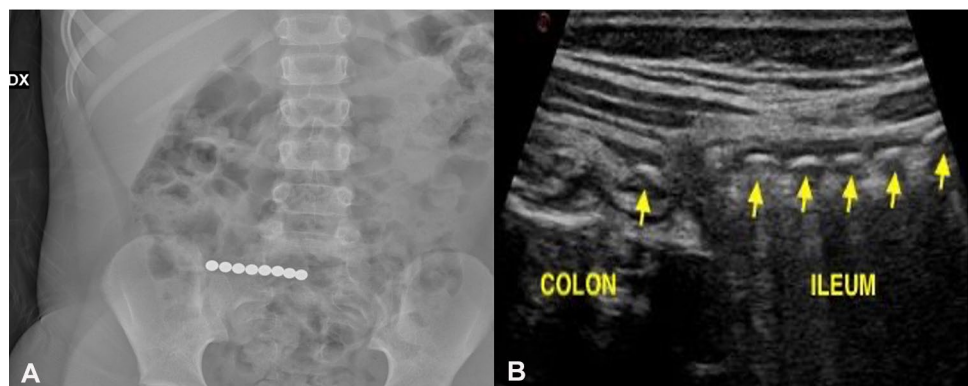


Fig. 3 surgical image clearly showing two small round perforations on opposite bowel walls (arrows)

Discussion

Magnet ingestion in the pediatric population is a potentially fatal health risk that requires special attention and prompt synergic endoscopic and surgical management [2, 3]. Reports of magnet ingestion (and complications, including one death in 2006 of a 20-month-old child [4]) have increased over the past two decades due to more availability for magnet containing toys and to the presence of rare earth magnets, a 5 to tenfold more powerful subtype of magnet containing neodymium.

In 2012, the United States Consumer Product Safety Commission issued a recall and new safety standards for magnet-containing toys, subsequently withdrawn in 2016 because of a legal appeal made by toy manufacturers [5]. In this time interval, a decrease in hospitalization due to magnet ingestion followed by a new increase in the cases was observed [6, 7]. In 2015, the North American Society for Pediatric Gastroenterology, Hepatology and Nutrition (NASPGHAN) first and then a jointed European Society Gastrointestinal Endoscopy (ESGE)/European Society

for pediatric gastroenterology Hepatology and Nutrition (ESPGHAN) commission issued specific guidelines on removing foreign bodies in the pediatric population, including magnetic objects [8–11]. In the case of a single magnet, small enough to pass through the gastrointestinal tract, a more conservative approach can be used to manage the patient in an outpatient setting and facilitate magnet progression with polyethylene glycol. In the case of multiple magnets localized in the esophagus, stomach, or duodenum, endoscopic removal is suggested (or even in the small bowel if enteroscopy is available). In the case of multiple magnets, beyond the ligament of Treitz and proximal to the terminal ileum, going through the bowel separately, a more cautious approach should be used because they can attract each other across different intestinal loops causing intestinal perforation or fistulas. Patients should be admitted, and daily abdominal X-rays should be obtained to document the magnet progression. A laparoscopic removal may be considered if magnet progression fails after 48 h, even in asymptomatic and clinically stable patients [12]. The intestinal US was decisive in the management of our case because it showed the exact location of the magnets in two different intestinal segments and the initial ischemic phenomena affecting the intestinal walls as subsequently confirmed by the surgeon.

The use of bowel US has increased over the last decades, as it may provide a non-invasive method for the initial evaluation of different abdominal diseases. Inflammatory bowel diseases' suspicion and follow-ups are the main indications for this procedure. However, it appears to be a valuable tool in different gastrointestinal and abdominal conditions in both the elective and the emergency setting [13]. Recent studies have shown that US can be useful even for evaluating foreign bodies (FBs) in the gastrointestinal tract and identifying associated complications [14–16]. The role of pediatric Point-Of-Care Ultrasound (POCUS) for detection of FBs (mainly esophageal and gastric) in the emergency departments is becoming more and more relevant as it may assist clinicians integrating the clinical examination with real-time images before using more time- and resource-consuming techniques [17]. In 2013, Jeckovic et al. reported using a water-filled stomach in the diagnostic workup of gastric FBs [18]. Also, the US can be used to detect radiolucent FBs that are not visible with routine X-rays.

The strengths of intestinal US are reproducibility, low cost, and high patient acceptability [19]. Also, it has several advantages over the traditional “static” radiograms (e.g., X-ray and CT scan). First, changes in the patient's position during the examination allow a dynamic evaluation of the location and anatomic position of FBs. Second, a better definition of possible FBs movements with peristalsis is immediately available. Third, a prompt US examination can detect wall entrapment between two magnets placed in two different intestinal loops before the onset of wall bowel

complications. Limitations rely on the patient's anatomy and the operator's experience. Also, in the pediatric setting, intestinal US has the advantage of reducing the need for ionizing radiation, even if the operator should be familiar with children's anatomy and management (including crying and bowel gas).

Based on our experience, if magnets have passed the ligament of Treitz and appear tightly adherent to each other on the first abdominal X-rays, it may be helpful to closely follow magnets progression with the US and reduce the number of X-Rays examination to key moment (decision to operate, home discharge, etc.).

In conclusion, although with its limitations, we recommend including the US examination in managing multiple magnet ingestions. In selected cases, it can allow an earlier definition of intestinal progression, the “continuity” of the magnets chain, and detect the possible interposition of bowel walls, reducing X-ray exposure.

Author contributions All authors contributed to the study conception and design. Material preparation, data collection and analysis were performed by CB and DF. The first draft of the manuscript was written by CB and all authors commented on previous versions of the manuscript. All authors read and approved the final manuscript.

Declarations

Conflict of interest Authors have no conflict of interest to disclose.

References

1. Dutta S, Barzin A (2008) Multiple magnet ingestion as a source of severe gastrointestinal complications requiring surgical intervention. *Arch Pediatr Adolesc Med* 162:123–125
2. Tavarez MM, Saladino RA, Gaines BA et al (2013) Prevalence, clinical features and management of pediatric magnetic foreign body ingestions. *J Emerg Med* 44:261–268
3. Brown J, Otjen J, Drugas G (2013) Too attractive: the growing problem of magnet ingestions in children. *Pediatr Emerg Care* 29:1170–1174
4. Child's death prompts replacement program of magnetic building sets. 2006. [Internet]. Available from: <http://www.cpsc.gov/cpscpub/prerel/prhtml06/06127.html>.
5. North American Society for Pediatric Gastroenterology Hepatology and Nutrition. Warning labels ineffective at preventing high-powered magnet ingestions. [Internet]. Available from: <https://www.aap.org/en-us/about-the-aap/aap-press-room/pages/WarninngLabels-Ineffective-at-Preventing-High-Powered-Magnet-Ingestions.aspx>. 2012.
6. Reeves PT, Nylund CM, Krishnamurthy J et al (2018) Trends of magnet ingestion in children, an ironic attraction. *J Pediatr Gastroenterol Nutr* 66:e116–e121
7. Reeves PT, Rudolph B, Nylund CM (2020) Magnet ingestions in children presenting to emergency departments in the US 2009–2019: a problem in flux. *J Pediatr Gastroenterol Nutr* 71:699–703
8. Kramer RE, Lerner DG, Lin T et al (2015) Management of ingested foreign bodies in children: a clinical report of the

- NASPGHAN endoscopy committee. *J Pediatr Gastroenterol Nutr* 60:562–574
9. Tringali A, Thomson M, Dumonceau J-M et al (2016) Pediatric gastrointestinal endoscopy: European Society of Gastrointestinal Endoscopy (ESGE) and European Society for Paediatric Gastroenterology Hepatology and Nutrition (ESPGHAN) Guideline Executive summary. *Endoscopy* 49:83–91
 10. Oliva S, Romano C, De Angelis P et al (2020) Foreign body and caustic ingestions in children: A clinical practice guideline. *Digest Liver Dis.* <https://doi.org/10.1016/j.dld.2020.07.016>
 11. Quitadamo P, Anselmi F, Caldore M et al (2021) Foreign body ingestion in children: beware of disk batteries and multiple magnets. *Acta Paediatr.* <https://doi.org/10.1111/apa.15957>
 12. Sola R, Rosenfeld EH, Yu YR et al (2018) Magnet foreign body ingestion: rare occurrence but big consequences. *J Pediatr Surg* 53:1815–1819
 13. Cavalcoli F, Zilli A, Fraquelli M et al (2017) Small bowel ultrasound beyond inflammatory bowel disease: an updated review of the recent literature. *Ultrasound Med Biol* 43:1741–1752
 14. Piotto L, Gent R, Kirby CP et al (2009) Preoperative use of ultrasonography to localize an ingested foreign body. *Pediatr Radiol* 39:299–301
 15. Salmon M, Doniger SJ (2013) Ingested foreign bodies: a case series demonstrating a novel application of point-of-care ultrasonography in children. *Pediatr Emerg Care* 29:870–873
 16. Kozaci N, Avci M, Pinarbasili T et al (2019) Ingested foreign body imaging using point-of-care ultrasonography: a case series. *Pediatr Emerg Care* 35:807–810
 17. Buonsenso D, Chiaretti A, Curatola A et al (2021) Pediatrician performed point-of-care ultrasound for the detection of ingested foreign bodies: case series and review of the literature. *J Ultrasound* 24:107–114
 18. Ječković M, Anupindi SA, Barbir SB et al (2013) Is ultrasound useful in detection and follow-up of gastric foreign bodies in children? *Clin Imaging* 37:1043–1047
 19. Derek M (2015) Deborah R (2015) Goldberg US of gastrointestinal tract disease. *Radiographics* 35(1):50–68. <https://doi.org/10.1148/rg.351140003>
 20. Minella R, Minelli R, Rossi E et al (2021) Gastroesophageal and gastric ultrasound in children: the state of the art. *J Ultrasound* 24:11–14

Publisher's Note Springer Nature remains neutral with regard to jurisdictional claims in published maps and institutional affiliations.