





# Critical Role of Clinical Suspicion in the Diagnosis of Arterio-Ureteral Fistula

## 동맥-요관 누공의 진단에 임상적 의심의 중요성

Doyoung Kim, MD<sup>1</sup> , Dong Jae Shim, MD<sup>1,2\*</sup> 

<sup>1</sup>Department of Radiology, Incheon St. Mary's Hospital, College of Medicine, The Catholic University of Korea, Incheon, Korea

<sup>2</sup>Department of Radiology, College of Medicine, The Catholic University of Korea, Seoul, Korea

We read the case report of an arterio-ureteral fistula (AUF) by Lee and Lee (1). with great interest, prompting us to share a similar experience. A 65-year-old female presented with sudden onset left flank pain, hematuria, and hematochezia. She had undergone total proctocolectomy 32 years ago due to familial adenomatous polyposis-associated colon cancer and abdominoperineal resection with concurrent chemoradiation therapy (CCRT) for cancer recurrence 3 years ago. Initial systolic blood pressure was 89 mm Hg and pulse rates were 105 beats/min. Hemoglobin level was decreased to 7.0 g/dL despite transfusion. Gastroduodenoscopy failed to reveal bleeding focus of hematochezia. CT demonstrated high attenuated hematoma in urinary bladder and renal pelvis and small nipple-like aneurysmal projection in common iliac artery adjacent double-J (DJ) ureteral catheter without a sign of contrast-medium extravasation (Fig. 1A). Ongoing evaluation of bleeding focus, her physician consulted to interventional radiologist for renal artery embolization due to continuous hematuria. There was no evidence of active bleeding in kidney on CT review. History of surgery and CCRT and CT findings of nipple-like projection near DJ catheter suggested iliac AUF. Instead of renal artery embolization, we placed balloon expandable polytetrafluoroethylene-covered stent (Lifestream; BD Bard, Tempe, AZ) at external iliac artery with internal iliac artery coils embolization (Fig. 1B, C). After treatment, her symptoms of flank pain, hematuria and hematochezia improved and discharged from hospital with prophylactic antibiotics. Follow-up cystography and CT review revealed a fistula between the bladder and the ileum. The overflowed blood in urinary bladder was the probable cause of hematochezia. She underwent elective surgery to repair vesico-ileal fistula one month later and recovered from the fistula-associated symptoms.

As stated by Lee and Lee (1), the AUF is a rare condition and misdiagnosis can cause dire consequences. Intermittent bleeding natures and subtle abnormal image findings make it difficult to diagnose and to treat earlier (2). Endovascular treatment would be

Received October 15, 2020

Revised October 30, 2020

Accepted October 30, 2020

\*Corresponding author

Dong Jae Shim, MD  
Department of Radiology,  
Incheon St. Mary's Hospital,  
College of Medicine,  
The Catholic University of Korea,  
56 Dongsu-ro, Bupyeong-gu,  
Incheon 21431, Korea.

Tel 82-32-280-5236

Fax 82-32-280-5230

E-mail inharad@naver.com


This is an Open Access article distributed under the terms of the Creative Commons Attribution Non-Commercial License (<https://creativecommons.org/licenses/by-nc/4.0>) which permits unrestricted non-commercial use, distribution, and reproduction in any medium, provided the original work is properly cited.

### ORCID iDs

Doyoung Kim 

[https://](https://orcid.org/0000-0003-1937-0661)

[orcid.org/0000-0003-1937-0661](https://orcid.org/0000-0003-1937-0661)

Dong Jae Shim 

[https://](https://orcid.org/0000-0001-9596-0765)

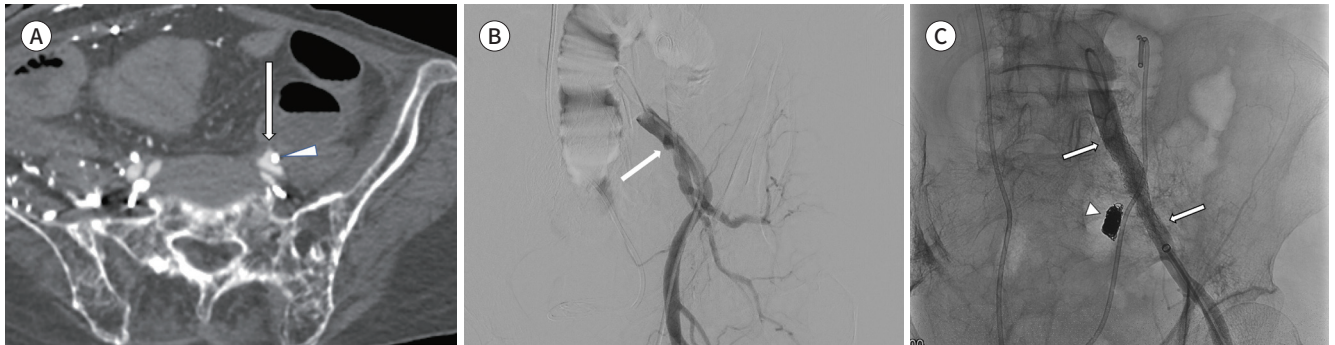[orcid.org/0000-0001-9596-0765](https://orcid.org/0000-0001-9596-0765)

**Fig. 1.** Endovascular treatment of arterio-ureteral fistula using a stent-graft.

**A.** The axial CT image of a 65-year-old female shows small pseudoaneurysm (arrow) in the left common iliac artery adjacent to the double-J ureteral catheter (arrowhead).

**B.** Iliac arteriogram shows a small contour-bulging pseudoaneurysm (arrow) without ureteral contrast media leakage.

**C.** After microcoil embolization of the internal iliac artery (arrowhead) for endoleak prevention, a stent-graft (arrows) was placed in the iliac artery to cover the pseudoaneurysm. Iliac arteriogram shows neither pseudoaneurysm nor endoleaks.



most feasible approach because it is less invasive and most patients had undergone surgery and radiation therapy (3). This presenting case can be a typical secondary AUF due to previous cancer surgery, CCRT, and placement of DJ ureteral stent. Combined vesico-ileal fistula caused hematochezia and obscured the bleeding focus. CT was known to have limited role for diagnosis because it showed positive finding in only 38–42% of patients (3, 4). However, preprocedural CT evaluation with clinical suspicion would be most important for early diagnosis and safe treatment (5). When patients with cancer surgery, CCRT, and ureteral stent present with massive hematuria, radiologists should be aware of possibility of AUF and inspect closely around ureteral stent. We thank to Lee and Lee (1) for presenting interesting case and thorough literature review.

#### Author Contributions

Conceptualization, S.D.J.; investigation, K.D.; supervision, S.D.J.; validation, S.D.J.; visualization, K.D.; writing—original draft, K.D.; and writing—review & editing, S.D.J.

#### Conflicts of Interest

The authors have no potential conflicts of interest to disclose.

#### Funding

None

#### REFERENCES

1. Lee HN, Lee WH. Endovascular treatment for arterio-ureteral fistula of the abdominal aorta: a case report and literature review. *J Korean Soc Radiol* 2020;81:953-957
2. Gao Q, Zhao J, Yang N, Jin Z. Endovascular management of arterio-ureteral fistula in a patient with a challenging hematuria. *Minim Invasive Ther Allied Technol* 2019;28:317-320
3. Noh SY, Shin JH, Yang WJ, Chu HH, Park S, Chen C, et al. Arterio-ureteral fistula: overview of clinical characteristics, endovascular management, and outcomes. *Minim Invasive Ther Allied Technol* 2020:1-9
4. Lee ECH, Tirukonda PS, Tan AGS, Shi H. Clinics in diagnostic imaging (206). Arterio-ureteral fistula (AUF). *Singapore Med J* 2020;61:327-330
5. Van den Bergh RC, Moll FL, De Vries JP, Yeung KK, Lock TM. Arterio-ureteral fistula: 11 new cases of a wolf in sheep's clothing. *J Urol* 2008;179:578-581