

Ulnar buttress arthroplasty after enbloc resection of a giant cell tumor of the distal ulna

Monappa A Naik, Premjit Sujir, Sharath K Rao, Sujit K Tripathy

ABSTRACT

Enbloc resection with or without ulnar stump stabilization is the recommended treatment for giant cell tumors (GCT) of the distal ulna. A few sporadic reports are available where authors have described various procedures to prevent ulnar stump instability and ulnar translation of carpal bones. We report a GCT of the distal ulna in a 43-year-old male which was resected enbloc. The distal radioulnar joint was reconstructed by fixing an iliac crest graft to the distal end of the radius (ulnar buttress arthroplasty) and the ulnar stump was stabilized with extensor carpi ulnaris tenodesis. After a followup at three years, there was no evidence of tumor recurrence or graft resorption; the patient had a normal range of movement of the wrist joint and the functional outcome was excellent as per the score of Ferracini *et al*.

Key words: Distal ulna, enbloc resection, giant cell tumor, ulnar buttress arthroplasty

INTRODUCTION

Giant cell tumor (GCT) of the bone is a rare, benign, locally invasive tumor, comprising 3–5% of all primary bone tumors. The tumor is epiphyseal and commonly seen around the knee joint. The distal ulna is an extremely rare site for a GCT and the incidence as reported in the literature varies from 0.45 to 3.2%.¹ Because of its aggressive nature and high chances of recurrence, enbloc resection is recommended for a GCT of the distal ulna.² The loss of ulnar support causing ulnar translation of carpal bones and ulnar stump instability are the major concerns after resection of the distal ulna.¹⁻⁴ A satisfactory functional outcome has been reported after the placement of a distal radioulnar prosthesis.⁵ Some authors have reported an excellent to good functional outcome following tenodesis of the ulnar stump with or without distal radioulnar stabilization by the modified Sauve-Kapandji procedure.^{3,4,6,7} We report a case of distal ulnar GCT (Enneking stage 2) in a 43-year-old male that was resected enbloc; the ulnar support was

maintained by fixing an iliac crest graft to the distal radius, and ulnar stability was achieved using extensor carpi ulnaris (ECU) tenodesis.

CASE REPORT

A 43-year-old male patient presented with a six-month history of pain and swelling in the nondominant left wrist. The swelling was present over the distal end of the ulna and it was tender. Terminal flexion and ulnar deviation of the wrist joint was restricted. Radiograph of the wrist joint revealed an expansile, lobulated osteolytic lesion of the epiphyseo-metaphyseal region of the distal ulna [Figure 1]. The lesion was hypointense in T1W and heterogenous in T2W images in magnetic resonance imaging (MRI) [Figure 2]. Clinical and radiological findings were suggestive of a benign GCT of the distal ulna. A Trucut biopsy of the lesion was advised which showed multiple osteoclastic giant cells against a background of spindle-shaped stromal cells; this confirmed our diagnosis as a GCT of the distal ulna. Chest radiograph and computed tomography (CT) scan of the chest and abdomen were normal. Bone scan revealed an increase uptake of tracer in the distal part of the ulna.

The patient underwent extraperiosteal resection of the tumor and buttress arthroplasty of the distal ulna. We resected the whole of the distal ulna with 2 cm of normal cuff of bone. The excised specimen measured 9.5 cm in length [Figure 3]. A 1 × 1 cm iliac crest graft was harvested from the ipsilateral iliac crest and fixed to the distal part of the radius with a small fragment cortical (3.5 mm) screw and 1.5 mm K wire; the triangular fibrocartilaginous

Department of Orthopaedics, KMC, Manipal, Karnataka, India

Address for correspondence: Dr. Sujit Kumar Tripathy, Department of Orthopaedics, KMC, Manipal, Karnataka – 576 104, India. E-mail: sujitortho@yahoo.co.in

Access this article online	
Quick Response Code:	Website: www.ijoonline.com
	DOI: 10.4103/0019-5413.108933

complex and ulnar collateral ligament were attached to the graft. The distal end of the ulna was stabilized with the radial slip of the ECU tendon. The tendon slip was passed through the ulnar stump after making a drill hole and it was stitched to its own substance. Histological

examination of the surgical margin was tumor free. In the postoperative period, the wrist joint was splinted in an above-elbow plaster of Paris (POP) slab for two weeks, and then gradual movements of the wrist joint was initiated; complete bony fusion of the graft to the distal end of the radius was confirmed on radiographs after two-and-a-half months of surgery.

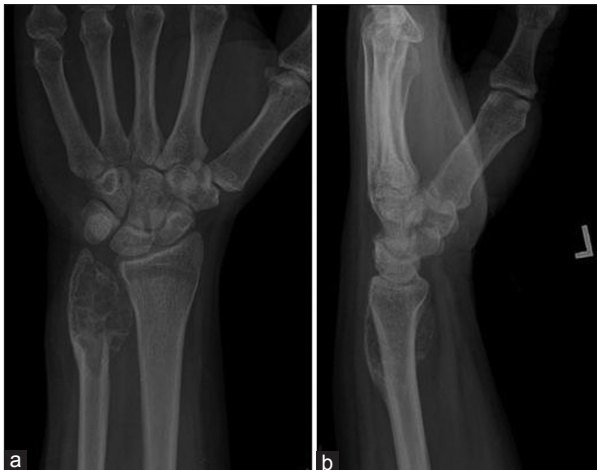

Figure 1: Radiograph anteroposterior (a) and lateral view (b) of forearm and wrist showing expansile, lobulated osteolytic lesion in the distal end of the ulna

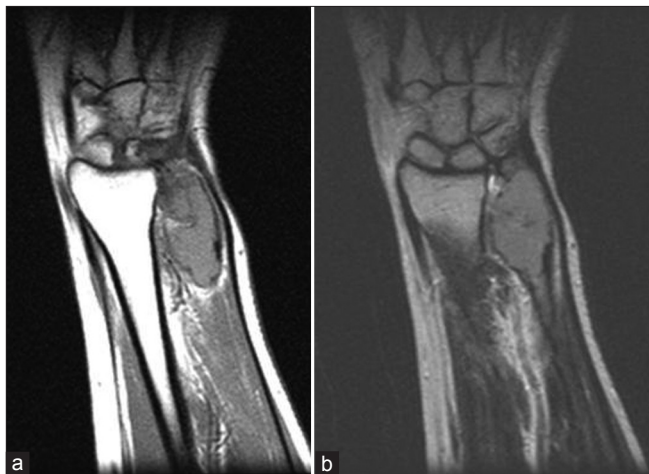

Figure 2: Magnetic resonance imaging showing T1W hypointense and T2W heterogeneous signal in the lesion

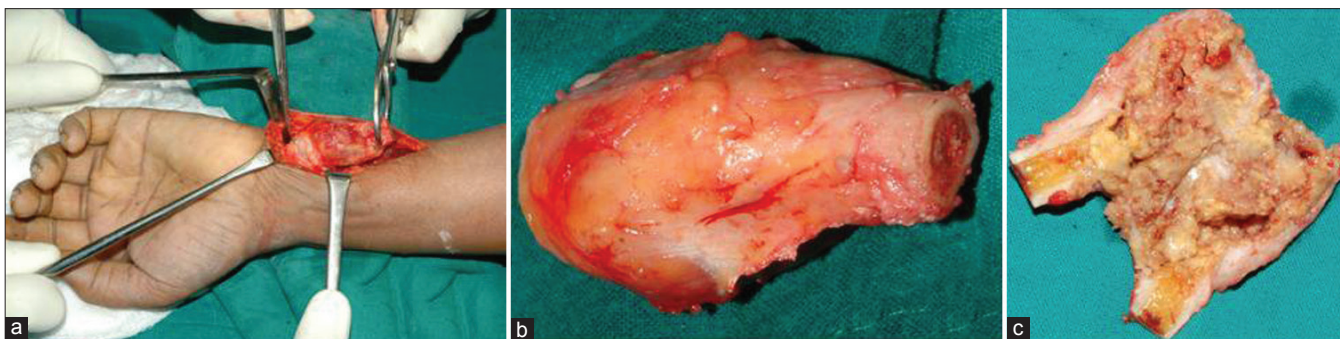


Figure 3: Intraoperative clinical photograph showing GCT of distal ulna (a), resected specimen showing complete excision of distal ulna (b), and cut section of the specimen showing expansile lobulated mass (c)

Three years later, the patient had no evidence of tumor recurrence or graft absorption [Figure 4]. There was no evidence of ulnar translation of carpal bones, and the ulnar stump was centrally placed with no signs of instability (no radioulnar convergence) [Figure 4]. The wrist joint movements were normal with dorsiflexion of 90°, palmar flexion of 90°, pronation of 90°, and supination of 90°. Functional results of the wrist joint were evaluated using the score of Ferracini *et al.*,⁸ which was based on range of motion, pain level, muscle strength, and the presence or absence of ulnar impingement and ulnar or carpal instability. The patient had a score of 18 out of 18, indicating an excellent functional outcome [Figure 4].

DISCUSSION

The distal ulna has been traditionally considered as a dispensable bone. Darrach reported that the distal ulna can be excised without any functional limitations and indicated its excision for degenerative conditions. However, Darrach's belief was not replicated exactly in the literature. The failure rate of Darrach's procedure and its modification has been documented to be 10–50%.⁹ The distal ulna plays an important role in movements of the forearm (supination-pronation), grip strength, and also in maintaining relationship with the carpal bones and the distal end of the radius. The soft tissue structures, that is, the ulnar collateral ligament and the triangular fibrocartilaginous complex help to maintain the ulnar support of the carpal bones.¹

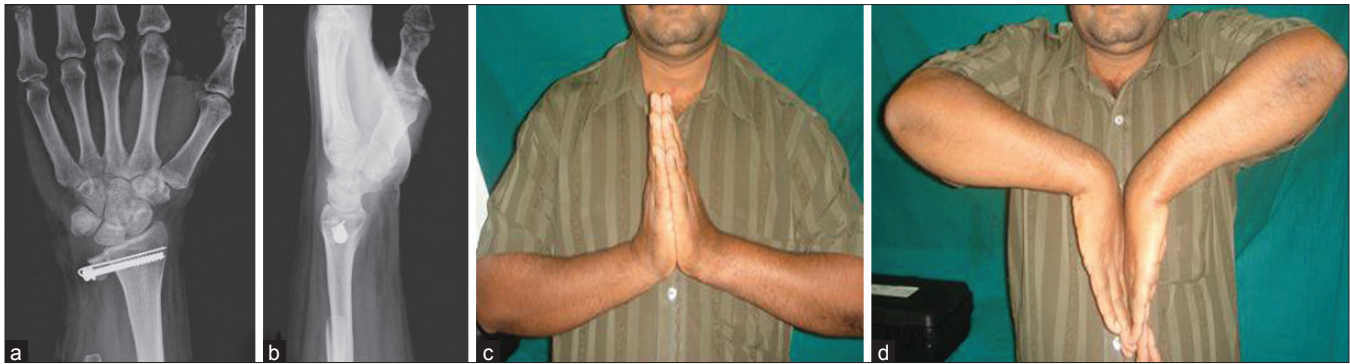

Figure 4: Three years followup radiographs (a) anteroposterior, (b) lateral view showing complete fusion of graft to the distal radius with no evidence of resorption or radioulnar convergence, (c and d) clinical photographs showing good range of motion of the wrist joints

Most of the reports focus on wide resection of the distal ulna for treatment of GCTs. Cooney *et al.* reported 75% excellent outcome after distal ulnar GCT excision.¹⁰ As per their report, osseous defect reconstruction may not be indicated in all cases after resection. Contrary to this, a few other reports revealed problems of loss of the ulnar support of carpal bones and ulnar stump instability after wide resection of the distal ulna. Many authors believe that the outcome of excision of the distal ulna for GCTs may not be equivalent to that of Darrach's resection or its modified technique, which was originally meant for degenerative conditions.¹ First of all, the resection in case of a GCT is quite extensive and hence, a significant portion of the ulna is excised from its lower end. As the dissection remains extraperiosteal, the stabilizing effect of the periosteal sleeve is lost after excision of the tumor. Second, a significant portion of the soft tissue envelope is also excised in tumor surgery, and thus, chances of instability of the ulnar stump and surgical complications are increased. Third, excision of the distal ulna for GCT is performed in younger individuals whose functional demands are high and thus, the issue of stability is more important.¹

Various reconstruction methods of the distal radioulnar joint (DRUJ) and stabilization procedures of the ulnar stump have been described in the literature. Gainor *et al.* reported a 'lasso' tendon graft stabilization procedure for the ulnar stump.¹¹ Ferracini *et al.*⁸ reported eight cases of distal ulna tumor, including five patients with GCTs. They stabilized the ulnar stump with the flexor carpi ulnaris (FCU), fascia lata, with an autograft, or with plate arthrodesis. One patient treated without reconstruction had a fair postoperative result in their series. The authors concluded that soft tissue stabilization of the ulnar stump should be performed whenever possible. The ECU tenodesis was first described by Goldner and Hayes,⁶ in 1979. Subsequently, many authors reported the procedure for stabilization of the ulnar stump after excision of the tumor. The major problem of ECU tenodesis is difficulty in separation of the

tendon from the tumor mass. However, a careful dissection and separation of the tendon may be helpful in stabilizing the ulnar stump.

Wide resection followed by a two-stage allograft reconstruction of the DRUJ was reported by Wurapa with good functional results.¹² Bone transport by an Ilizarov fixator was described by Stoffelen *et al.* with satisfactory movements of the wrist, elbow, and shoulder.¹³ Ulnar buttress arthroplasty was first described by Hashizume *et al.* for the treatment of GCTs of the distal ulna.⁷ They resected the distal ulna en bloc and grafted the iliac bone to the ulnar side of the radius as a buttress using a screw and a K wire. They had excellent results at follow up of six months. Subsequently, Minami *et al.* reported a satisfactory outcome following 'modified ulnar buttress arthroplasty' in a 23-year-old man after resection of a GCT of the distal ulna.³

We believe that both reconstruction of the DRUJ and stabilization of the ulna are equally important for functional rehabilitation after wide resection of the distal ulna. Fixation of an iliac crest strut graft to the distal radius restores the anatomy of the DRUJ. The soft tissue sleeves can be easily attached to the graft and thus, it can provide better ulnar support to the carpal bones. On the opposite end, tenodesis of ulnar stump provides better stability. This combined procedure resulted in excellent functional outcome in our case with near a normal range of movement and grip strength.

En bloc resection of the tumor followed by reconstruction of the DRUJ using iliac crest strut graft and stabilizing the ulnar stump by tenodesis of the ECU is a viable treatment option for a GCT of the distal ulna.

REFERENCES

1. Kayias EH, Drosos GI, Anagnostopoulou GA. Resection of the distal ulna for tumours and stabilisation of the stump: A case report and literature review. *Acta Orthop Belg* 2006;72:484-91.

2. Harness NG, Mankin HJ. Giant cell tumor of the distal forearm. *J Hand Surg* 2004;29A:188-93.
3. Minami A, Iwasaki N, Nishida K, Motomiya M, Yamada K, Momma D. "Giant-cell tumor of the distal ulna treated by wide resection and ulnar support reconstruction: A case report." *Case Rep Med* 2010;2010:8712-78.
4. Singh M, Sharma S, Peshin C, Wani IH, Tikoo A, Gupta SK, *et al.* Wide resection and stabilization of ulnar stump by extensor carpi ulnaris for giant cell tumor of distal ulna: Two case reports. *Cases J* 2009;2:861-7.
5. Gracia I, Proubasta IR, Trullols L, Peiro A, Moya E, Cortes S, *et al.* Distal radioulnar joint prosthesis for the treatment of giant cell tumor of the distal ulna: A case report and literature review. *Strat Traum Limb Recon* 2011;6:103-6.
6. Goldner JL, Hayes MG. Stabilization of the remaining ulna using one-half of the extensor carpi ulnaris tendon after resection of the distal ulna. *Orthop Trans* 1979;3:330-1.
7. Hashizume H, Kawai A, Nishida K, Sasaki K, Inoue H. Ulnar buttress arthroplasty for reconstruction after resection of the distal ulna for giant cell tumour. *J Hand Surg* 1996;21-B:213-5.
8. Ferracini R, Masterson EL, Bell RS, Wunder JS. Distal ulnar tumours. Results of management by enbloc resection in nine patients and review of the literature. *J Hand Surg* 1988;23-B:517-21.
9. Dingman PV. Resection of the distal end of the ulna (Darrach operation); an end result study of twenty four cases. *J Bone Joint Surg Am* 1952;34A:893-900.
10. Cooney WP, Damson TA, Sim FH, Linscheid RL. Enbloc resection of tumors of the distal ulna. *J Bone Joint Surg* 1997;79-A:406-12.
11. Gainor BJ. Lasso stabilization of the distal ulna after tumour resection: A report of two cases. *J Hand Surg* 1995;20-A:324-6.
12. Wurapa RK, Whipple R. Distal radioulnar allograft reconstruction after giant cell tumor resection. *Am J Orthop* 2003;32:397-400.
13. Stoffelen D, Lammens J, Fabry G. Resection of a periosteal osteosarcoma and reconstruction using the Ilizarov technique of segmental transport. *J Hand Surg* 1993;18-B:144-6.

How to cite this article: Naik MA, Sujir P, Rao SK, Tripathy SK. Ulnar buttress arthroplasty after enbloc resection of a giant cell tumor of the distal ulna. *Indian J Orthop* 2013;47:211-4.

Source of Support: Nil, **Conflict of Interest:** None.