

# Interventional radiology in the management of renal vascular injury: A prospective study

Puneet Garg, Charu Paruthi, Krishna Bhardwaj, Venkatram Krishnan\*,  
Sunil Kumar Bajaj, Ritu Nair Misra

Department of Radiology, Vardhaman Mahavir Medical College and Safdarjung Hospital, New Delhi, India

\*E-mail: kvktram@gmail.com

## ABSTRACT

**Introduction:** Endovascular and percutaneous interventions are promising alternatives to surgical management of traumatic renal injuries and often avert the need for nephrectomies. In this study, we aimed to evaluate the role of interventional radiology and angiographic interventions in the management of renal vascular injury.

**Materials and Methods:** Our prospective study was performed over a period of 6 months. Twenty-five patients who presented with either persistent hematuria or hemodynamic instability after traumatic or iatrogenic renal injuries were selected. Angiographic embolization using varying combinations of coils, glue, and Gelfoam® was performed to address the vascular injuries, either directly in hemodynamically unstable patients or after preprocedural imaging in hemodynamically stable patients. Patients were then followed up till discharge from hospital 48 h later and at 2 weeks and 4 weeks postprocedure for any recurrence of hematuria or hemodynamic instability. Technical and clinical success rates were calculated using descriptive statistics.

**Results:** Pseudoaneurysms were the most common form of arterial injury (22 cases), followed by arteriovenous fistula (8) and active extravasation (5). Segmental arteries are the most commonly involved (12 cases), followed by interlobar (9) and arcuate (3) arteries. Gelfoam® was used in five patients with active contrast extravasation and was 100% effective in arresting active bleeding. Coiling alone had a 79.16% technical success rate in management, while additional use of glue in four failed cases led to a 95.83% technical success rate in the first attempt. The ultimate technical and clinical success rate of interventional radiology in renal trauma management (after the second attempt in one failed case) was 100%.

**Conclusion:** Endovascular management is an effective and safe alternative to surgical management of both iatrogenic and accidental renal vascular injuries.

## INTRODUCTION

Renal vascular injury is not infrequent and blunt abdominal trauma during road traffic accidents, stab injuries, projectile injuries, and iatrogenic injuries during interventional procedures such as percutaneous nephrolithotomy (PCNL) or percutaneous nephrostomy and percutaneous renal biopsies are the main causes, leading to the formation of the pseudoaneurysms and arteriovenous fistulas (AVFs). Minimally invasive procedures such as endovascular

embolization can treat these patients and avert unnecessary nephrectomies. Pseudoaneurysms can be asymptomatic or can present with flank pain, mild to life-threatening hematuria, and hemodynamic compromise.

We evaluated the effectiveness of endovascular interventions in treating renal arterial injuries. We also describe some novel modifications of, and additions to, the standard intravascular procedure of coiling with use of percutaneous techniques in some cases.

This is an open access journal, and articles are distributed under the terms of the Creative Commons Attribution-NonCommercial-ShareAlike 4.0 License, which allows others to remix, tweak, and build upon the work non-commercially, as long as appropriate credit is given and the new creations are licensed under the identical terms.


**For reprints contact:** reprints@medknow.com

**Received:** 21.03.2020, **Revised:** 12.06.2020

**Accepted:** 23.06.2020, **Published:** 01.10.2020

**Financial support and sponsorship:** Nil.

**Conflicts of interest:** There are no conflicts of interest.

Access this article online	
Quick Response Code:	Website: www.indianjurol.com
	DOI: 10.4103/iju.IJU_92_20

## MATERIALS AND METHODS

We performed a prospective study over a period of 6 months with patients referred from the department of urology and renal transplantation for endovascular management of renal vascular injuries. A total of 25 patients who presented with either persistent hematuria or hemodynamic instability after accidental or iatrogenic injuries to the kidney were selected. Written and informed consent was obtained from each participant before inclusion in the study after providing detailed information regarding all the procedures involved. The institutional ethics committee approval was obtained for the study protocol, and all procedures in the study adhered to the ethical guidelines of the Declaration of Helsinki and its amendments. All the original data reported in the study are accessible and available with the authors.

Preprocedural noninvasive imaging was based on the hemodynamic status of the patient. Any hemodynamically unstable patient (4 cases in our study) was taken up for digital subtraction angiography (DSA) directly for both diagnosis and treatment. Hemodynamically stable patients first underwent an ultrasound scan with color Doppler. If any lesion was visualized (7 cases), DSA was performed subsequently. If not, then patients with adequate renal function (10 cases) underwent computed tomographic (CT) angiography for diagnosis, followed by DSA. Those with inadequate renal function (10 cases) underwent DSA directly after ultrasound. The diagnostic protocol is detailed in Figure 1.

Preprocedure blood transfusions were used based on the clinical status of the patient. Images from the DSA workstation were analyzed for the technical details of the procedure. Clinical data were retrieved from medical records. Post-embolization renal angiogram was the final

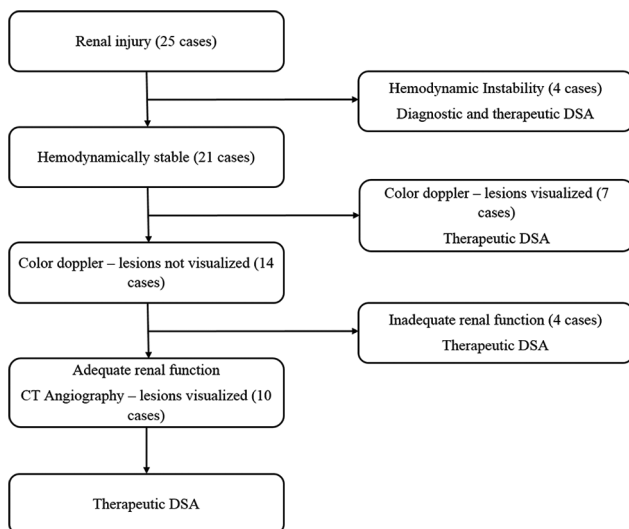
imaging performed. Patients were discharged 48 h after complete clinical resolution of hematuria and stabilization of hematocrit and blood pressure. Post-procedure blood transfusions to improve hematocrit were used as clinically necessary. Patients were clinically followed up till discharge and at 2 weeks and 4 weeks post-procedure with a plan for repeat DSA in case of recurrent hematuria or hemodynamic deterioration. Renal function was also monitored before and after the procedure up to 4 weeks using serum creatinine levels. No follow-up imaging was deemed necessary if post-procedure angiogram documented technical success, and complete clinical recovery was observed.

Technical success was defined as angiographic documentation of complete resolution and nonvisualization of all vascular lesions on the final angiographic run. Clinical success was defined as complete resolution of hematuria with stabilization of hematocrit, with no recurrence up to 4 weeks postprocedure. Statistical analysis was performed using descriptive statistics to calculate the means, proportions, and percentages.

Standard triple-phase renal CT angiography was performed on Siemens SOMATOM dual-energy CT scanner. 80 mL of nonionic iodinated contrast was administered at 5 mL/s using bolus tracking technique. Scans included arterial, venous, and delayed phases obtained at 25 s, 60 s, and 8 min postcontrast administration, respectively. Arterial phase images were evaluated for renal arterial mapping, to visualize any accessory renal, lumbar, and intercostal arteries and to diagnose renal pseudoaneurysm or AVF. Delayed phase images helped diagnose any contrast extravasation or venous injury. Coronal maximum intensity projection and volume rendering technique images and multiplanar reconstruction images were evaluated to plan embolization.

DSA was performed on Allura FD 20/20 (Philips, The Netherlands) biplanar DSA machine. Standard right common femoral arterial puncture was performed and access secured using a 6F arterial sheath. A 5F renal double-curve (RDC) catheter (Cook, USA) was used to cannulate the involved side main renal artery. Renal angiograms were obtained in standard posterior to anterior projection at three frames per second with bone subtraction and evaluated for arterial injuries (pseudoaneurysm, AVF, or extravasation). Oblique views were obtained to visualize overlapping arteries. Superselective catheterization was done using a 2.7 F microcatheter (Progreat, Terumo, Japan) to reach as distally as possible toward the lesion, and superselective runs were obtained and flow dynamics evaluated to select the embolic material to be used.

Push coils 018 system (Hilal, Cook, USA) of appropriate sizes including 18-3-2, 18-3-3, 18-5-2, and 18-5-3 were used. Check angiograms were obtained after 10 min (to



**Figure 1:** Flowchart for diagnostic algorithm

allow sufficient time for thrombus formation in the coil) to confirm resolution of the lesion. Gelfoam® was additionally used in cases with active contrast extravasation or expanding perinephric hematoma. Two Luer Lock syringes and a 3-way Stop Cock were used to churn the particulate Gelfoam® and prepare an injectable slurry. N-butyl cyanoacrylate (NBCA) glue was used when coiling failed to completely occlude the injured vessel, after confirming sufficient forward flow. Varying glue dilutions (20%–50%) mixed with Lipiodol were used. After embolizing all the involved vessels, final check angiogram was obtained from the RDC catheter to document technical success.

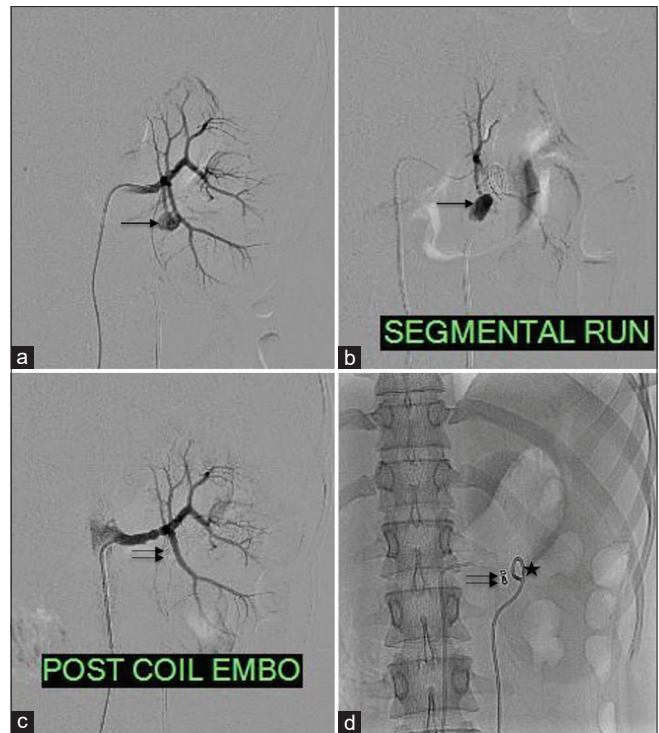
Abdominal aortogram and additional catheterization of accessory renal, lumbar, and intercostal arteries were also done in some cases as necessary. Super-selective catheterization of each segmental artery was performed in seemingly negative initial angiograms from the main renal artery. After the procedure, femoral sheath was removed and hemostasis was secured using standard manual compression.

**RESULTS**

A total of 25 participants were evaluated. The average age of the participants was 30.2 years. Sixteen patients were male (64%), while nine were female (36%). The average age of female subjects (31.3 years) was more than that of male subjects (28.2 years). Twenty-three out of the 25 procedures were performed on native kidneys and two on transplant kidneys. Among native kidneys, 15 of the 23 procedures (65.22%) were performed on the left kidney and 8 on the right (34.78%).

Regarding the etiology of renal trauma, six participants (24%) sustained trauma, five had blunt trauma and one had a stab injury. The remaining 19 participants (76%) had iatrogenic renal injury, nine following percutaneous biopsy, eight following PCNL, one following DJ stent insertion, and one following surgical exploration (transplant kidney with early post-transplant graft dysfunction with perinephric collection, for which surgical exploration and open biopsy were performed).

Pseudoaneurysms were the most common form of arterial injury, present in 22 out of 25 patients (88%) [Figures 2-4], while AVFs were present in eight patients (32%) [Figures 3 and 4]. Active contrast extravasation (representing active bleeding from arterial rupture) was present in five patients (20%), one of whom had an expanding perinephric hematoma [Table 1]. The most common vascular segment involved was segmental artery seen in 12 participants (48%), closely followed by the interlobar artery in 9 (36%). The arcuate artery was involved in 3 (12%) and left subcostal artery in the remaining one participant. Accessory polar artery was additionally injured in one of the participants.



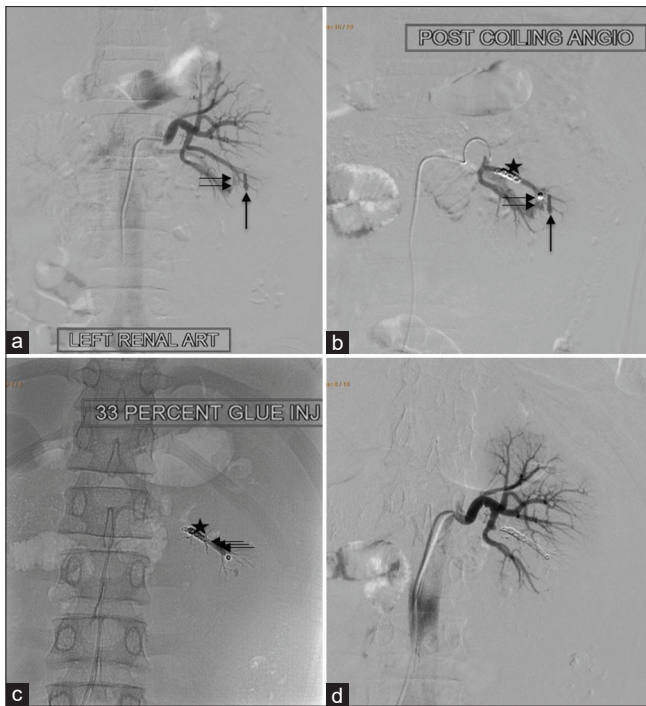**Figure 2:** A 25-year-old female presenting with hematuria post-DJ stent placement. (a) Left main renal artery run shows a pseudoaneurysm (arrow) arising directly from the fifth segmental artery. (b) Superselective runs from the segmental artery show filling of the pseudoaneurysm. (c) Coil embolization of the segmental branch was done, with postembolization run showing the coil mass *in situ* (double arrow) with nonopacification of the pseudoaneurysm. (d) Coil mass (double arrow) seen and DJ stent (asterisk) *in situ*

**Table 1: Digital subtraction angiography findings of arterial injuries**

DSA finding	Number of cases
Pseudoaneurysm alone	13
AVF alone	2
Extravasation alone	1
Pseudoaneurysm plus AVF	5
Pseudoaneurysm plus extravasation	3
Pseudoaneurysm plus AVF plus extravasation	1

DSA=Digital subtraction angiography, AVF=Arteriovenous fistulas

Coils were deployed in the feeding arteries in 24 participants. Gelfoam® was used in the five participants with active contrast extravasation, and extravasation was arrested in all five (100%). In four out of the five cases with extravasation, the injured vessel could be localized and coiling was performed after Gelfoam® injection to prevent recurrence. In one case, the injured vessel could not be definitively identified, and hence, coils were not deployed. DSA showed complete resolution of vascular lesions in 19 out of 24 cases after coiling, indicating a technical success rate of 79.16% with coiling alone. In five cases, post-coiling angiogram showed persistent filling of pseudoaneurysm. Intravascular glue injection was used in four of these patients in the same sitting which resulted in complete resolution, confirmed on post-procedure angiogram [Figures 2 and 3]. In total, 23

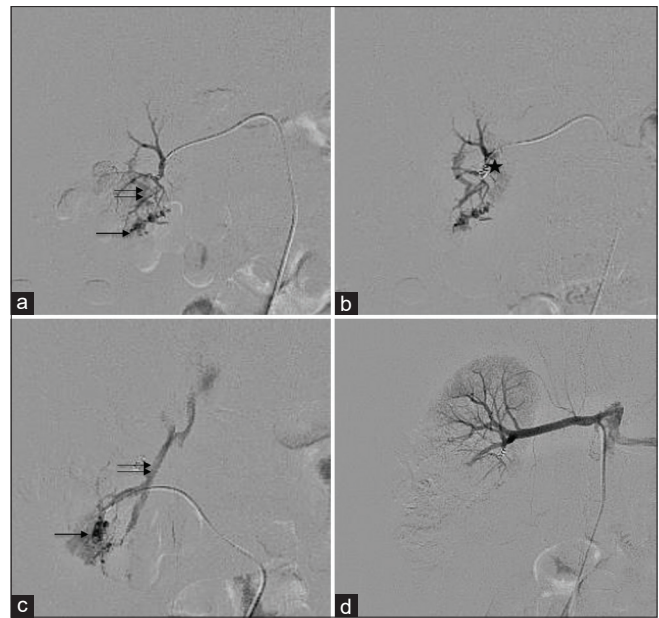

**Figure 3:** A 15-year-old boy with RPGN with hematuria postrenal biopsy. (a) Left main renal artery run shows pseudoaneurysm (arrows) from the third segmental artery, with proximal AV fistula (double arrow). (b) Coil embolization with coil mass *in situ* (star) and persistent flow in pseudoaneurysm (arrows). (c) Recatheterization with microcatheter and 33% glue injection done distally; coil mass (star) and glue cast (triple arrows) *in situ*. (d) Postembolization run shows complete resolution

out of 24 patients (95.83%) had technical success of the endovascular procedure in the first attempt.

In one of the five cases where coiling failed to occlude the pseudoaneurysm, intravascular access to the pseudoaneurysm was lost due to the deployment of multiple coils and resulted in failure of endovascular intervention in the first attempt. The failure rate for the first attempt was 4.17% (one out of 24). Subsequently, the patient had continued hematuria and falling hematocrit requiring blood transfusion post-procedure. Twenty-four hours later, persistent flow in the pseudoaneurysm was confirmed on color Doppler, and the patient was taken up for a second attempt. Percutaneous glue injection was performed into the pseudoaneurysm under ultrasound guidance, followed by a check DSA which confirmed the complete absence of flow in the pseudoaneurysm.

The ultimate technical success rate in our study for interventional radiology in the management of renal trauma was 100%. All 25 patients had complete resolution of hematuria with recovery of hemodynamic stability and stabilization of hematocrit at the time of discharge. None of them had clinical recurrence at either 2 weeks or 4 weeks post-procedure on follow-up, indicating 100% clinical success rate. None of the patients had significant deterioration of renal function up to 4 weeks post-procedure.



**Figure 4:** A 21-year-old female with postrenal biopsy hematuria. (a) Right main renal artery shows multiple pseudoaneurysms (arrow) from subsegmental branches with associated early draining vein (double arrows) suggestive of an arteriovenous fistula. (b) Coil (asterisk) embolization with lesion occlusion. Multiple similar lesions were seen which were similarly treated. (c) Superselective runs of an accessory renal artery show pseudoaneurysm (arrow) with an early draining vein (double arrow) s/o arteriovenous fistula, which were also embolized. (d) Postembolization run of main renal artery shows complete resolution of all lesions

## DISCUSSION

Kidney is the most commonly injured genitourinary organ in abdominal trauma.<sup>[1]</sup> Approximately half of the renal injuries are iatrogenic.<sup>[2]</sup> Some of these can be ascribed to incorrect technique, but complications may occur despite proper technique.<sup>[3]</sup> Pseudoaneurysm and AVF usually occur when the pressure from an injured renal artery is transmitted to a low-pressure renal vein or calyx through the needle tract. Approximately 75% of these lesions heal spontaneously; however, some of them require intervention.<sup>[4]</sup> Factors that inhibit spontaneous healing include nephrosclerotic kidney, lack of tamponade, uremia, infection, and major arterial injury.<sup>[5]</sup> In renal trauma, Grade I, II, and III injuries respond well to endovascular techniques, while trials in treating Grade IV and V injuries show promising results with nephrectomies averted in 78% and 83% of cases, respectively.<sup>[6]</sup>

Patients with persistent hematuria for more than 72 h or hemodynamically instability post-procedure should be promptly investigated and angiographically embolized if there is evidence of vascular injury.<sup>[7]</sup> Pre-procedural imaging, either color Doppler or magnetic resonance (MR)/CT angiography, improves success rates. MR angiography can be used only in hemodynamically stable patients, either with deranged renal function or in children/pregnant women. DSA may be performed directly when the patient

is hemodynamically unstable or if renal function is deranged (to limit contrast administration). We followed this protocol for pre-procedural imaging in our study without using MR angiography in any patient.

Segmental, inter-lobar, and arcuate arteries are injured in decreasing order of frequency in literature;<sup>[3]</sup> our study findings were similar. Very rarely, the main renal artery or its anterior or posterior divisions are injured and these require the deployment of stent grafts for endovascular management.

Transcatheter embolization for pseudoaneurysms has been described since the 1970s.<sup>[8]</sup> Vozianov described treating pseudoaneurysms following blunt trauma with a 90% success rate, comparable to ours.<sup>[9]</sup> Renal trauma predominantly involves arterial injury which can be rapidly diagnosed and managed using DSA without any need for general anesthesia, even if the patient is unstable. Renal vasculature consists of end arteries; it is easy to obtain proximal occlusion without any risk of collateral refilling (of pseudoaneurysms, for instance). Endovascular procedures can be repeated easily if the first procedure fails.

The choice of embolic agent used depends on the location and size of the lesion, caliber of the artery, associated vascular lesions, and availability of embolic agents. Metallic coils are presently the agents of the choice because of the widespread availability, ease of use, precision of deployment, and low risk of collateral damage. Gelfoam<sup>®</sup> is used if there is an active contrast extravasation to reduce forward flow. NBCA glue with Lipiodol is inexpensive but carries the risk of reflux and catheter adherence. Many researchers have used different embolic agents such as ethanol, thrombin, and Onyx with varying success rates.<sup>[10-12]</sup> We could even treat a large (3 cm sized) pseudoaneurysm arising from an interlobar artery successfully with the use of coiling alone, without the need for additional embolizing agents.

Gelfoam<sup>®</sup> is highly effective in arresting active bleeding. Being a temporary embolizing agent, the risk of recurrence is high and the risk of significant renal parenchymal loss is low. Subsequent coiling reduces recurrence. We faced one case of active extravasation where the injured vessel could not be localized; extravasation was arrested by Gelfoam<sup>®</sup> injection into suspect interlobar arteries without subsequent coiling. On follow-up, there was no recurrence. A recurrence in this case may have necessitated coiling of the suspect arteries. With the use of Gelfoam<sup>®</sup>, even if exact vascular localization is not achieved, it can still safely be managed intravascularly.

A major advantage of NBCA glue is its ability to be used percutaneously also as was demonstrated in one of our cases where endovascular management failed and subsequently percutaneous glue injection was used to occlude the pseudoaneurysm. The endovascular coils functioned to prevent proximal reflux of the glue and resultant non-target embolization. While this was technically a

failure of stand-alone endovascular management, additional nonsurgical techniques could successfully manage the patient, taking advantage of the endovascular coils.

Managing vascular complications in transplanted kidneys requires meticulous care. We performed endovascular procedures to treat two transplant kidneys with pseudoaneurysms secondary to biopsy who presented with persistent hematuria. DSA was performed directly to reduce contrast utilization. About 50 mL of contrast was used in each patient. Preprocedure transfusion and periprocedure hemodialysis were required in one patient. Eventually, renal function recovered post-procedure with modification of immunosuppressive regimens in both.

Technical success rates of 98%–100% and clinical success rates of 83%–98% for endovascular management of renal vascular injuries have been reported, similar to ours.<sup>[13-15]</sup> Endovascular management has high success rates with fewer complications, rapid recovery, and a better safety profile as compared to surgery. Complications can be due to access site aneurysm, hematoma or dissection, renal artery dissection or perforation, non-target embolization, and rarely significant parenchymal loss causing hypertension or even renal failure. The availability of micro-catheters allows coaxial technique with superselective cannulation and coiling of distal vessels. This resulted in higher success rates, fewer complications, and milder post-embolization syndrome in our study. Two cases had mild renal artery dissection and 16 had mild post-embolization syndrome (1–2 weeks) which were managed conservatively. Caution in contrast utilization is necessary to avoid precipitating contrast-induced nephropathy, particularly in patients with deranged renal function, transplanted kidneys, or significant parenchymal loss. Pre-procedural CT angiography can be avoided in patients with deranged renal function or transplanted kidneys, and immediate post-procedure hemodialysis may be necessary in some cases.

No lesion may be identified in some patients despite extensive angiograms and patients may still have persistent hematuria. In such cases, the rare possibility of venous injury should be considered. We did not encounter this in our study. Further, associated injuries of the intra-abdominal organs can also be managed simultaneously using endovascular techniques in blunt abdominal injury patients. In our study, out of the five patients with blunt abdominal trauma, one had an adrenal hematoma, while another had a splenic laceration, both of which were diagnosed on CT angiography. Neither required additional endovascular management for the associated injuries.

## CONCLUSION

Endovascular management is an effective and safe alternative to surgical management in cases of both iatrogenic and accidental renal vascular injuries. Meticulous pre-procedure

imaging and careful study of angiograms are required to identify the injured vasculature. A variety of embolic agents are currently available to achieve therapeutic embolization with a success rate in the first attempt of over 95%. Repeat procedures or alternative interventional approaches to control bleeding are easy to perform in case of failure in the first attempt. Technical and clinical success is rapidly achieved without any significant morbidity and with success rates of nearly 100% using endovascular techniques in the management of renal trauma.

## REFERENCES

1. Titton RL, Gervais DA, Boland GW, Mueller PR. Renal trauma: Radiologic evaluation and percutaneous treatment of nonvascular injuries. *AJR Am J Roentgenol* 2002;178:1507-11.
2. Poulakis V, Ferakis N, Becht E, Deliveliotis C, Duex M. Treatment of renal-vascular injury by transcatheter embolization: Immediate and long-term effects on renal function. *J Endourol* 2006;20:405-9.
3. Clayman RV, Surya V, Hunter D, Castaneda-Zuniga WR, Miller RP, Coleman C, *et al.* Renal vascular complications associated with the percutaneous removal of renal calculi. *J Urol* 1984;132:228-30.
4. Huppert PE, Duda SH, Erley CM, Roth M, Lauchart W, Dietz K, *et al.* Embolization of renal vascular lesions: Clinical experience with microcoils and tracker catheters. *Cardiovasc Intervent Radiol* 1993;16:361-7.
5. Cope C, Zeit RM. Pseudoaneurysms after nephrostomy. *AJR Am J Roentgenol* 1982;139:255-61.
6. Ramaswamy RS, Darcy MD. Arterial embolization for the treatment of renal masses and traumatic renal injuries. *Tech Vasc Interv Radiol* 2016;19:203-10.
7. Antunes PR, Araújo SA, Miranda SM, Prado FF, Antunes LF, de Siqueira EC, *et al.* Post-Biopsy Complications Associated with Percutaneous Kidney Biopsy. *Renal Diseases*. London: IntechOpen; 2019. Available from: <https://www.intechopen.com/books/renal-diseases/post-biopsy-complications-associated-with-percutaneous-kidney-biopsy>. DOI: 10.5772/intechopen.89226, [Last accessed on 2020 Jun 23].
8. Sauk S, Zuckerman DA. Renal artery embolization. *Semin Intervent Radiol* 2011;28:396-406.
9. Vozianov S, Sabadash M, Shulyak A. Experience of renal artery embolization in patients with blunt kidney trauma. *Cent European J Urol* 2015;68:471-7.
10. Singh B, Sudan D, Singh P, Kaul U. Intraarterial ethanol for the management of iatrogenic renal artery pseudoaneurysm. *Cathet Cardiovasc Diagn* 1998;45:442-4.
11. Schellhammer F, Steinhaus D, Cohnen M, Hoppe J, Mödder U, Fürst G. Minimally invasive therapy of pseudoaneurysms of the trunk: Application of thrombin. *Cardiovasc Intervent Radiol* 2008;31:535-41.
12. Zelenák K, Sopilko I, Svihra J, Kliment J. Successful embolization of a renal artery pseudoaneurysm with arteriovenous fistula and extravasations using Onyx after partial nephrectomy for renal cell carcinoma. *Cardiovasc Intervent Radiol* 2009;32:163-5.
13. Chiramel GK, Keshava SN, Moses V, Kekre N, Tamilarasi V, Devasia A. Clinical outcomes of endovascularly managed iatrogenic renal hemorrhages. *Indian J Radiol Imaging* 2015;25:380-90.
14. Somani BK, Nabi G, Thorpe P, McClinton S. Endovascular control of haemorrhagic urological emergencies: An observational study. *BMC Urol* 2006;6:27.
15. Phadke RV, Sawlani V, Rastogi H, Kumar S, Roy S, Bajjal SS, *et al.* Iatrogenic renal vascular injuries and their radiological management. *Clin Radiol* 1997;52:119-23.

How to cite this article: Garg P, Paruthi C, Bhardwaj K, Krishnan V, Bajaj SK, Misra RN. Interventional radiology in the management of renal vascular injury: A prospective study. *Indian J Urol* 2020;36:303-8.