

Three-Dimensional Reconstruction and Swept-Source Optical Coherence Tomography for Crystalline Lens Tilt and Decentration Relative to the Corneal Vertex

Jing Dong¹, Xiao-Liang Wang², Minghui Deng³, and Xiao-Gang Wang⁴

¹ Department of Ophthalmology, The First Hospital of Shanxi Medical University, Taiyuan, Shanxi, China

² School of Aeronautics and Astronautics, Shanghai Jiao Tong University, Shanghai, China

³ Department of Cataract, Linfen Yaodu Eye Hospital, Linfen, Shanxi, China

⁴ Department of Cataract, Shanxi Eye Hospital, Taiyuan, Shanxi, China

Correspondence: Xiao-Gang Wang, Department of Cataract, Shanxi Eye Hospital, No. 100 Fudong Street, Taiyuan, Shanxi 030002, China. e-mail: movie6521@163.com

Received: May 15, 2021

Accepted: July 14, 2021

Published: August 13, 2021

Keywords: corneal vertex; limbus plane; lens plane; 3D; OCT; tilt; decentration

Citation: Dong J, Wang XL, Deng M, Wang XG. Three-dimensional reconstruction and swept-source optical coherence tomography for crystalline lens tilt and decentration relative to the corneal vertex. *Transl Vis Sci Technol.* 2021;10(9):13, <https://doi.org/10.1167/tvst.10.9.13>

Purpose: To investigate crystalline lens tilt and decentration with respect to the corneal vertex (CV) using swept-source optical coherence tomography (SS-OCT) combined with three-dimensional (3D) reconstruction.

Methods: Thirty consecutive patients with cataract (30 right eyes) were included in this prospective, observational, pilot case series study. SS-OCT anterior segment images and 3D reconstructions were used for data analysis.

Results: The mean distance between the central points of crystalline lens plane and limbus plane was approximately 0.33 ± 0.18 mm. The distance of the center of the limbus plane relative to the CV was approximately 0.31 ± 0.14 mm, which approximated the distance of the center of the crystalline lens plane relative to the CV at 0.33 ± 0.20 mm ($P = 0.354$). However, the centers of the limbus and crystalline planes were not in the same quadrant in 80% of eyes (24/30). Moreover, the crystalline lens tilted by approximately $4.16^\circ \pm 1.97^\circ$ relative to the CV.

Conclusions: The center of the limbus plane was not consistent with that of the crystalline lens plane. The tilt and decentration of the crystalline lens were natural phenomena.

Translational Relevance: The SS-OCT technology combined with 3D reconstruction was useful for quantifying the tilt and decentration of the crystalline lens. The definition of angle alpha used for premium IOL screening should be updated.

Introduction

The accurate centration of premium intraocular lens (IOLs) is essential to ensure enhanced postoperative visual function. The relatively large distance of decentration of (or the center of) the multifocal IOL from the visual axis may result in the passage of central light through the diffractive rings but not the center of optic zone, resulting in higher order aberrations that can affect patient satisfaction. Therefore, the iTrace device (Tracey Technologies, Houston, TX) is used to obtain the angle alpha data for premium IOL selection in clinical practice. Angle alpha, which is defined as the potential difference between the center of the

limbus and visual axis, is preferred for the screening of candidates for premium IOLs in the clinic setting over angle kappa (the potential difference between the pupillary center and visual axis).¹ However, the calculation of angle alpha is based on the hypothesis that the central point of the limbus plane is the same as the central point of the lens plane. Obviously, the reliability of this hypothesis should be tested. Moreover, Wang et al.² demonstrated the existence of a natural tilt of approximately $3.7^\circ \pm 1.1^\circ$ in the crystalline lens with respect to the visual axis using a swept-source optical coherence tomography (SS-OCT) biometer. Moreover, we believe that the magnitude of not only the tilt but also the crystalline lens could be decentered relative to the visual axis.

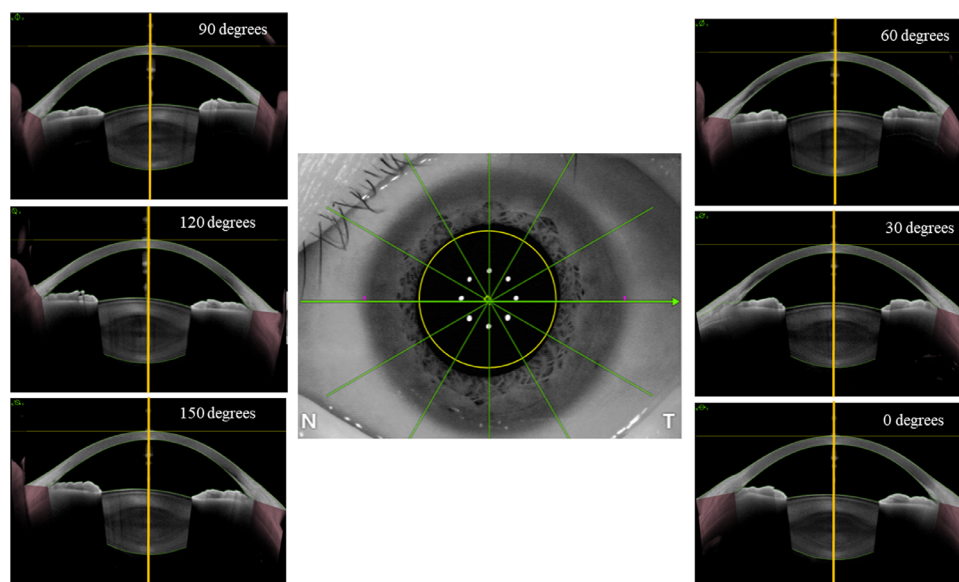


Figure 1. Six high-resolution, cross-sectional anterior segment images with 30° intervals centered on the corneal vertex (yellow vertical line in each B-scan image) used for 3D reconstruction of the crystalline lens.

The ANTERION Metrics App (Heidelberg Engineering, Heidelberg, Germany), in conjunction with a high-resolution SS-OCT imaging device, can provide six high-resolution cross-sectional anterior segment images with 30° intervals centered on the corneal vertex (CV) (Fig. 1). The CV is a stable and preferred morphological reference point, which is nearly the best approximation that can be used to determine the alignment to the visual axis.³ The Metrics App can also clearly reveal information regarding the cornea, anterior chamber, lens anterior, and posterior capsule in one cross-sectional image. The above-mentioned imaging information makes three-dimensional (3D) reconstruction of the anterior segment possible, which enables verification of prior assumptions about the respective centers of the limbus and the lens. Moreover, it also can provide more information about the crystalline lens tilt and decentration relative to the CV.

To the best of our knowledge, this was the first study to analyze the potential difference between the central point of the limbus plane and that of the crystalline lens plane and the crystalline lens tilt and decentration with reference to the CV using 3D reconstruction and SS-OCT imaging.

Methods

This study was conducted at Shanxi Eye Hospital (Taiyuan, Shanxi, China). The research protocol

was approved by the institutional review board and performed according to the tenets of the Declaration of Helsinki. Written informed consent was obtained from each participant after they were told the nature of this study.

Participants

The study included a total of 30 consecutive patients with cataract (30 right eyes), who presented to our clinic in good general health and met the inclusion criteria. The eligibility criteria included a best-corrected visual acuity $\geq 4/20$ with the ability to cooperate during the SS-OCT image acquisition procedure. The exclusion criteria were all detectable ocular diseases and inability to complete the examination, recent ocular surgery, contact lens usage, and use of any eye drops.

SS-OCT Imaging

SS-OCT anterior imaging was performed by the same technician (X-GW) using the ANTERION device (software version 1.3.4.0; Heidelberg Engineering) in a semi-dark room without pupillary dilation, with the patient in the sitting position. The anterior segment Metrics App scan model with an axial resolution of less than 10 μm and lateral resolution of less than 30 μm was used. The images were obtained on six axes at 30° intervals (0°–180°, 30°–210°, 60°–240°, 90°–270°, 120°–300°, and 150°–330°), and the anterior and posterior optical surfaces of the crystalline lens

were imaged with reference to the CV. For each cross-sectional anterior segment image, six successive B-scans were captured and averaged. The quality of each measurement was examined by an expert, and the captured images that met the acquisition quality criteria (the parameters evaluated included motion, fixation, tear film and lid, camera image segmentation, refraction correction, and tracking) were used for further analysis. The above-mentioned six-meridian B-scan cross-sectional images and corresponding ocular camera image allowed 3D reconstruction of the anterior ocular segment, which included the crystalline lens and limbus planes.

Lens Tilt and Decentration Calculation

The crystalline lens tilt and decentration relative to CV were calculated using a self-designed image processing software that utilized the MATLAB version 9.4.0.813654 (MathWorks, Natick, MA) with a method that was partially similar to our previously published method (Supplementary Material S1).⁴ First, the zoom factor of each cross-sectional OCT image and the ocular camera image was calculated. This step was incorporated to readjust and ensure that the above-mentioned images used the same scale for the subsequent steps. Second, the reference points in the B-scan images and ocular camera image, such as the center point of the six scan lines, which was also the CV, were matched. This step ensured that the ocular camera image and B-scan images could be reconstructed using the same 3D coordinates. Third, parabolas were fitted to the anterior and posterior capsules to reconstruct the 3D lens shape and automatically calculate the crystalline lens plane, its central point, and normal vector (the line perpendicular to the crystalline lens plane). Fourth, best fitting of the circular plane of the horizontal limbus end points was performed to reconstruct the limbus plane and automatically calculate its center point. Finally, the lens tilt angle (i.e., the angle between the normal vector and CV) and the lens decentration (i.e., the plane offset distance between the central point of the lens and CV point on the camera image) were calculated (Fig. 2). The repeatability of this method for measuring the crystalline lens tilt and decentration was evaluated using three repeated measurements in 15 eyes.

Statistical Analysis

Statistical analyses were performed using commercially available software (SPSS Statistics 22.0; IBM Inc., Armonk, NY). A paired-sample *t*-test was performed to compare the measurement results for the

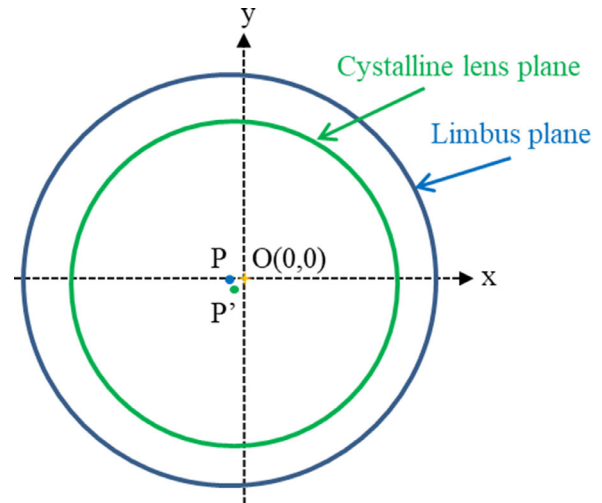


Figure 2. Diagrammatic representation of the corneal vertex (yellow dot, O, is the point of origin), center point of the crystalline lens plane (green dot, P'), and center point of the limbus plane (blue dot, P) in the plane-coordinate system. The length of OP is defined as the crystalline decentration distance relative to the corneal vertex; the length of OP' is defined as the distance from the center point of the limbus plane relative to the corneal vertex; and the length of PP' is defined as the displacement between the center points of the limbus plane and crystalline lens plane.

distance of the center point of the limbus plane and the distance of the center point of the crystalline lens plane relative to the CV. The intraclass correlation coefficient (ICC) and pooled within-subject standard deviations (SD) were used to make the repeatability assessment. All of the tests had a significance level of 5%.

Results

A total of 30 participants (30 right eyes) were evaluated in this prospective pilot study. The mean age was approximately 53 ± 18 years (range, 23–80), and the axial length, anterior chamber depth, and lens thickness (automatically measured by the ANTERION device) were approximately 24.20 ± 1.89 mm (range, 22.16–29.48), 3.35 ± 0.37 mm (range, 2.61–3.98), and 4.26 ± 0.47 mm (range, 2.89–5.18), respectively.

In 15 right eyes of 15 participants, the within-subject SD values were 0.43° for tilt magnitude and 0.04 mm for decentration distance. The ICC values were 0.928 for tilt magnitude and 0.960 for decentration distance. The mean tilt magnitude of the crystalline lens relative to the CV was $4.16^\circ \pm 1.97^\circ$ (range, 1.12° – 9.51°). The mean distance from the CV to the center of the limbus, which was 0.31 ± 0.14 mm (range, 0.07–0.65), did not differ significantly from the mean distance from the CV to the center of the crystalline plane, which was 0.33 ± 0.20 mm (range, 0.05–0.87);

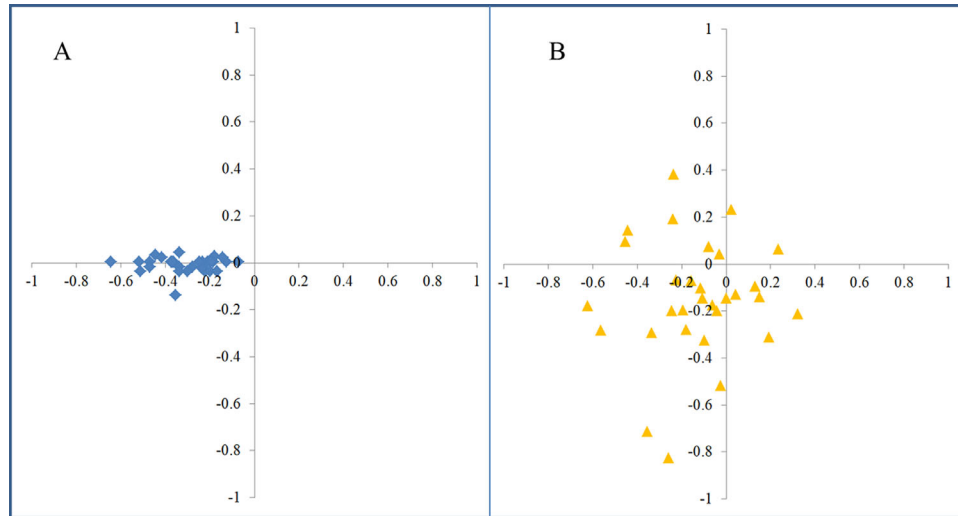


Figure 3. The distribution of the location of the center point of the limbus plane (A, blue diamond) and the center point of the crystalline lens plane (B, yellow triangle) relative to the corneal vertex (expressed in millimeters) in the coordinate system (30 eyes).

$P = 0.354$). However, the central point of the limbus plane was not located in the same quadrant as the center of the crystalline plane in 80% of the cases (24/30) (Fig. 3). Moreover, the distance from the center of the limbus plane to the center of crystalline plane in the camera image was approximately 0.33 ± 0.19 mm (range, 0.08–0.81).

Discussion

This prospective observational study found that the center of the limbus plane was not consistent with that of the crystalline lens plane, and the tilt and decentration of the crystalline lens were natural phenomena. The crystalline lens and intraocular lens tilt and decentration have been investigated in previous studies with the help of different imaging techniques, such as Purkinje reflection imaging, ultrasound biomicroscopy, time-domain anterior segment OCT, and Scheimpflug imaging.^{4–9} However, the reference points or planes (iris plane or the center of the pupil) used to evaluate lens tilt and decentration evaluation were inconsistent in the above-mentioned studies, which rendered comparison of the research data impossible. The visual axis is an important reference landmark. It is a straight line that passes through the center of the fovea and the center of the pupil and is the best approximate for determining the alignment to the CV and plays an important role in formulating the surgical plan for premium IOLs. The SS-OCT biometry imaging devices, such as the IOLMaster 700 and ANTERION,

can provide whole-eye or anterior segment OCT scans with reference to the visual axis and CV, respectively. Wang et al. investigated the crystalline lens and IOL tilt using IOLMaster 700 with the visual axis as reference.² Moreover, it was possible to investigate the consistency of the center point of the limbus plane and crystalline lens plane, and tilt and decentration of the crystalline lens relative to the CV in this study with the help of SS-OCT anterior-segment imaging technology and 3D reconstruction.

In the current study, we investigated the crystalline lens tilt and decentration, and the potential inconsistency between the center point of the limbus and crystalline lens using the ANTERION device. To the best of our knowledge, Wang et al.² and Hirnschall et al.¹⁰ conducted the only studies that have evaluated lens tilt, and they used the IOLMaster 700 (Carl Zeiss Meditec, Jena, Germany), which differs from the ANTERION device used in this study. Our current study also yielded the following novel findings, which were distinct from those of the two above-mentioned studies: (1) use of the ANTERION biometer offers relatively good repeatability of the crystalline lens decentration measurements, and (2) the center point of the limbus plane is not consistent with the center point of the crystalline lens plane.

In this study, the mean tilt magnitude of all crystalline lenses relative to the CV was $4.16^\circ \pm 1.97^\circ$, which is similar to the corresponding magnitude of $4.3^\circ \pm 0.9^\circ$ in the study by Hirnschall et al.¹⁰ and is slightly higher than the corresponding data of $3.7^\circ \pm 1.1^\circ$ reported by Wang et al.² These discrepancies may be attributed to the following: (1) each study

had different sample sizes (number of eyes); (2) pupillary dilation was not performed for SS-OCT imaging in our study and that of Wang et al.²; (3) only the right eye was included in the final data analysis in this study; (4) the axial length range varied among different studies; (5) potential differences may exist between the self-designed analysis software used in each study; and (6) the CV is an approximate reference point but is not exactly the same as the visual axis.³

The mean decentration distance of all crystalline lenses relative to the CV was 0.33 ± 0.20 mm, which was considerably higher than 0.12 mm reported by Kimura et al.,⁸ who used the corneal topographic axis (the line passing through the center of the entrance pupil and normal to the corneal surface) as the reference line.¹¹ We believe that the reason for the significant difference is mainly due to the different reference lines used in these two studies. The natural crystalline lens tilt and decentration also may cause internal coma, similar to the IOL, which can be evaluated using aberrometers and can be influenced by pupil size.^{12,13} Horizontal coma may cause astigmatism and defocus, and vertical coma may be proportional to the spherical aberration correction of the IOL.^{14,15} Therefore, both studies demonstrated the existence of natural decentration in the crystalline lens, which may provide useful information for premium IOL screening.

Angle alpha, defined as the distance between the center of the limbus and visual axis, plays an important role in premium IOL screening. Mahr et al.¹⁶ found that the mean angle alpha magnitude measured with iTrace (Tracey Technologies) was 0.44 ± 0.19 mm in a population that underwent cataract surgery. Angle alpha should ideally indicate the difference between the center of the lens and visual axis. The blockage of the iris tissue makes it difficult to visualize the whole lens with most devices. Therefore, some devices use the center of limbus as the center of the lens to calculate angle alpha. The SS-OCT imaging technique, in conjunction with the 3D reconstruction method, especially the Metrics App in ANTERION, facilitated precise calculation of the center of the lens and verification of the potential difference between the center of the limbus and the center of the lens. In this study, we found that the center of the lens and the center of the limbus were different and were located at a distance of 0.33 ± 0.19 mm from each other. Moreover, although the distance between the CV and lens center was 0.33 ± 0.20 mm, which is similar to the corresponding angle alpha data (0.33 ± 0.14 mm) obtained by Fu et al.¹ using iTrace, both values are not exactly the same. Although Fu et al.¹ found that no significant correlation between angle alpha and some objective vision quality parameters after multifocal IOL

implantation, we still believe that angle alpha is an important factor influencing premium IOL selection.¹ However, our finding emphasizes that the angle alpha data calculated from the distance between the limbus center (recognized as the lens center point) and visual axis in some clinical devices should be updated in the future. Our sample size was relatively small, and the effect of size for our sample size was 0.3442; therefore, a bigger sample size and postoperative IOL tilt and decentration, as well as their correlations with higher order aberrations, should also be investigated in further studies.

In conclusion, the potential difference between the central point of the limbus plane and the central point of the crystalline lens plane should be observed in clinical practice. Moreover, the tilt and decentration of the crystalline lens exist naturally with respect to the CV.

Acknowledgments

Supported by grants from the National Natural Science Foundation of China (81971697 and 81501544).

Disclosure: **J. Dong**, None; **X.-L. Wang**, None; **M. Deng**, None; **X.-G. Wang**, None

References

1. Fu Y, Kou J, Chen D, et al. Influence of angle kappa and angle alpha on visual quality after implantation of multifocal intraocular lenses. *J Cataract Refract Surg*. 2019;45(9):1258–1264.
2. Wang L, de Souza RG, Weikert MP, Koch DD. Evaluation of crystalline lens and intraocular lens tilt using a swept-source optical coherence tomography biometer. *J Cataract Refract Surg*. 2019;45(1):35–40.
3. Arba Mosquera S, Verma S, McAlinden C. Centration axis in refractive surgery. *Eye Vis (Lond)*. 2015;2:4.
4. Wang X, Dong J, Wu Q. IOL tilt and decentration estimation from 3 dimensional reconstruction of OCT image. *PLoS One*. 2013;8(3):e59109.
5. Mura JJ, Pavlin CJ, Condon GP, et al. Ultrasound biomicroscopic analysis of iris-sutured foldable posterior chamber intraocular lenses. *Am J Ophthalmol*. 2010;149(2):245–252.e2.
6. de Castro A, Rosales P, Marcos S. Tilt and decentration of intraocular lenses in vivo from Purkinje

- and Scheimpflug imaging. Validation study. *J Cataract Refract Surg*. 2007;33(3):418–429.
7. Rosales P, de Castro A, Jiménez-Alfaro I, Marcos S. Intraocular lens alignment from Purkinje and Scheimpflug imaging. *Clin Exp Optom*. 2010;93(6):400–408.
 8. Kimura S, Morizane Y, Shiode Y, et al. Assessment of tilt and decentration of crystalline lens and intraocular lens relative to the corneal topographic axis using anterior segment optical coherence tomography. *PLoS One*. 2017;12(9):e0184066.
 9. Kumar DA, Agarwal A, Prakash G, Jacob S, Saravanan Y, Agarwal A. Evaluation of intraocular lens tilt with anterior segment optical coherence tomography. *Am J Ophthalmol*. 2011;151(3):406–412.e2.
 10. Hirnschall N, Buehren T, Bajramovic F, Trost M, Teuber T, Findl O. Prediction of postoperative intraocular lens tilt using swept-source optical coherence tomography. *J Cataract Refract Surg*. 2017;43(6):732–736.
 11. Pande M, Hillman JS. Optical zone centration in keratorefractive surgery. Entrance pupil center, visual axis, coaxially sighted corneal reflex, or geometric corneal center? *Ophthalmology*. 1993;100(8):1230–1237.
 12. Won JB, Kim SW, Kim EW, Ha BJ, Kim T-I. Comparison of internal and total optical aberrations for 2 aberrometers: iTrace and OPD scan. *Korean J Ophthalmol*. 2008;22(4):210–213.
 13. Ashena Z, Maqsood S, Ahmed SN, Navavaty MA. Effect of intraocular lens tilt and decentration on visual acuity, dysphotopsia and wavefront aberrations. *Vision (Basel)*. 2020;4(3):41.
 14. Eppig T, Scholz K, Löffler A, Messner A, Langenbacher A. Effect of decentration and tilt on the image quality of aspheric intraocular lens designs in a model eye. *J Cataract Refract Surg*. 2009;35(6):1091–1100.
 15. Fujikado T, Saika M. Evaluation of actual retinal images produced by misaligned aspheric intraocular lenses in a model eye. *Clin Ophthalmol*. 2014;8:2415–2423.
 16. Mahr MA, Simpson MJ, Erie JC. Angle alpha orientation and magnitude distribution in a cataract surgery population. *J Cataract Refract Surg*. 2020;46(3):372–377.