
Bevacizumab for the Treatment of Non-Resectable Pseudomyxoma peritonei Associated with Mucinous Ovarian Tumor of Low Malignant Potential – A Comparison of Two Cases

Ira Winer^a Ronald J. Buckanovich^{a, b}

^aDepartment of Obstetrics and Gynecology, and ^bDepartment of Internal Medicine, Division of Hematology/Oncology, and Department of Obstetrics and Gynecology, Division of Gynecologic Oncology, University of Michigan, Ann Arbor, Mich., USA

Key Words

Pseudomyxoma · Ovarian tumor of low malignant potential · Bevacizumab

Abstract

Pseudomyxoma peritonei (PMP) is a rare tumor syndrome that can be diagnosed in association with mucinous ovarian tumors of low malignant potential. Surgical debulking is the primary treatment modality as chemotherapy has generally proven ineffective in this slowly progressive tumor. When patients with PMP are not surgical candidates, there is no effective treatment, and patients will die of progressive disease. We report two patients with PMP with associated mucinous ovarian tumor of low malignant potential treated with Bevacizumab therapy. Both patients demonstrated disease response to single agent Bevacizumab therapy. One patient had a prolonged response while on therapy, remained stable for 6 months when treatment was held, and then after progressing responded to a second course of therapy. We discuss here (1) the clinical features which may predict a better response to Bevacizumab therapy, and (2) evidence for the use of chemotherapy for inoperable PMP. These cases suggest that Bevacizumab may represent a rare effective therapy for patients with inoperable PMP with ovarian involvement and should be considered for clinical trials in this patient population.

Introduction

Pseudomyxoma peritonei (PMP) is a rare syndrome characterized by loculated gelatinous ascites and peritoneal dissemination of tumor implants [1]. Patients present with symptoms of increasing abdominal girth, bloating, nausea and occasionally intestinal obstruction. PMP is reported to originate primarily from gastrointestinal tumors, however, PMP has been associated in patients with mucinous ovarian tumors of low malignant potential (LMP) and in association with mature cystic teratomas [2]. In addition, because many patients with PMP of intestinal origin can present with ovarian masses and peritoneal disease consistent with ovarian malignancy, many of these patients are treated by gynecologic oncologists.

The diagnosis of PMP associated with ovarian invasion versus primary ovarian tumor remains difficult as appendiceal tumors and borderline mucinous ovarian tumors have very similar histological appearances. Histopathologically, PMP is sub-classified into high-grade peritoneal mucinous carcinomatosis (PMCA) [3] or low-grade disseminated peritoneal adenomucinosis (DPAM). PMCA demonstrates aggressive growth patterns, invasion and a poorer prognosis. Histologically DPAM can be indistinguishable from intestinal type mucinous ovarian LMP tumors. Similar to ovarian LMP tumors, DPAM PMP tends to be slow growing with a more indolent course.

Regardless of the origin of PMP, traditional treatment for PMP has consisted of aggressive, serial surgical debulking and/or stripping procedures [4]. In an attempt to improve results, several groups have studied the addition of hyperthermic intraperitoneal chemotherapy (HIPEC) administered at the time of debulking. Limited trials and case series have suggested improved survival with HIPEC [5]. In addition with increased experience, morbidity has been reduced. However, morbidity can still be significant, many patients are not candidates for surgery or HIPEC, and HIPEC is not available at many centers. Even after aggressive surgery and HIPEC, many patients can progress either as a result of technical complications or disease biology [6].

When patients with PMP are not surgical candidates, they ultimately succumb to the underlying cancer. The use of traditional chemotherapy has not demonstrated a survival advantage over surgery alone [7]. Biologic therapy, therefore, has appeal for the treatment of PMP. Bevacizumab (Bevacizumab[®], Genentech) binds to the vascular endothelial growth factor (VEGF) and inhibits angiogenesis. We speculated that Bevacizumab would be an effective agent against PMP with significant ovarian invasion because: (1) VEGF levels at the time of cytoreductive surgeries for PMP have been inversely correlated with survival [8], (2) Bevacizumab has activity in other non-chemoresponsive cancers [9], and (3) Bevacizumab has activity in both gastrointestinal tumors and refractory ovarian cancer [10, 11]. We describe here two patients with unresectable PMP and ovarian mucinous LMP tumors treated with Bevacizumab.

Case Reports

Case 1

A 33-year-old female presented with bloating and constipation. Ultrasound revealed bilateral ovarian masses with diffuse carcinomatosis. She underwent a modified radical TAH-BSO and omentectomy with optimal debulking. Pathology revealed a stage IIIb mucinous ovarian LMP tumor with associated PMP. No gross appendiceal involvement was noted at the time of surgery and an appendectomy was not performed. The patient showed signs of disease progression early after surgery

and she was treated with multiple chemotherapy regimens including 7 cycles of carboplatinum-paclitaxel, 3 cycles of topotecan, 5 cycles of liposomal doxorubicin, 32 cycles of gemcitabine, 3 cycles of etoposide and 2 cycles of doxorubicin-cyclophosphamide. With each she demonstrated progressive disease.

The patient then transferred care to our center. She underwent an aggressive interval debulking, however, she was deemed not to be a candidate for HIPEC. Pathology revealed diffuse peritoneal adenomucinosis consistent with PMP. Postoperatively she progressed and continued to have symptoms of bloating and early satiety. Her CA19-9 was 523. Bevacizumab was initiated at 10 mg/kg every other week. While on Bevacizumab therapy, the patient's CA19-9 steadily declined, and her symptoms of bloating and early satiety dramatically improved. Treatment was complicated by hypertension and proteinuria (1.8 g urine protein/24 h) and treatment was temporarily held for two weeks while anti-hypertensives were initiated. The patient's blood pressure was controlled with amlodipine and captopril. While off therapy there was a modest rise in the CA19-9. With re-initiation of Bevacizumab there was a further decline of the CA19-9 to 207. The patient received a total of 11 cycles of Bevacizumab therapy over approximately 9 months (fig. 1ai), then once again developed significant proteinuria (>2 g urine protein/24 h) requiring discontinuation of therapy.

The patient was monitored off therapy with stable symptoms and CA19-9 laboratory values for 6 months. She then developed increasing abdominal pressure and nausea/vomiting. Her CA19-9 was significantly elevated to 617. A CT scan demonstrated an increase in ascites and a partial increase in solid tumor burden (fig. 1b). The patient's blood pressure remained well-controlled on medication and the patient's proteinuria had nearly resolved (168 mg urine protein/24 h). Bevacizumab was reinitiated. Once again, on therapy the patient experienced a complete resolution of symptoms and the CA19-9 declined (fig. 1ai). CT scan revealed a reduction in ascites and a stable appearance of solid tumor burden (fig. 1b). Currently, the patient has received 9 additional months of Bevacizumab therapy without adverse side-effects, though there has been a slight worsening of her proteinuria.

Case 2

A 78-year-old female presented with abdominal bloating and was found to have a large pelvic mass. She underwent a TAH-BSO, appendectomy, omentectomy and debulking. Pathology revealed a stage IIIc ovarian mucinous LMP tumor and associated PMP. Postoperatively, the patient was asymptomatic for 30 months but then presented with progressive disease. At that time she underwent a second surgery. She had a right colectomy, partial small bowel resection, splenectomy and distal pancreatectomy. Despite the aggressive surgery the patient had a suboptimal debulking. She was unable to receive HIPEC secondary to intraoperative complications. Within 3 months of surgery she had clinically evident disease on exam, and she presented to our institution for transfer of care.

At that time the patient's CA19-9 was 202.5, and on exam she had palpable diffuse carcinomatosis of her abdomen. She was reluctant to receive chemotherapy and was initiated on Bevacizumab monotherapy. The patient's CA19-9 peaked at 234 after the first cycle of therapy. After successive cycles of therapy, the CA19-9 decreased to 180 and the patient reported significant symptom improvement (fig. 1aai). After 6 cycles, the patient's physical exam demonstrated increasing tumor burden and the CA19-9 began to increase. Therapy with weekly carboplatinum and biweekly Bevacizumab was started. The response was again observed for an additional 4 months at which point the treatment was discontinued secondary to worsening symptoms.

Discussion

We present here two cases of inoperable, progressive PMP diagnosed in association with mucinous ovarian LMP tumors treated with Bevacizumab. Each of these patients responded to single agent Bevacizumab therapy. However, the quality and duration of the response for each of these patients was rather distinct. Patient 1 responded for over 9 months until therapy was held secondary to proteinuria, remained stable for 6 months, and then responded for an additional 9 months with re-initiation of single agent therapy. Patient 2 responded to single agent therapy for approximately 4 months and then progressed. She then responded for an additional 4 months to combination therapy with Bevacizumab and chemotherapy, before once again progressing.

The distinct difference in durability of response may relate to several clinical differences which distinguish the two patients. Patient 1 had an optimal interval debulking surgery, whereas patient 2 was suboptimally debulked at her interval surgery. Patient 1 was relatively young, whereas patient 2 was an octogenarian at the time of Bevacizumab therapy. Interestingly, Lee et al. [12] reported age as the only prognostic factor in comparing outcomes among groups with ovarian associated PMP, suggesting age plays a significant role in disease biology. Surprisingly, patient 1 had progressed through several lines of chemotherapy yet demonstrated response within 2 cycles of therapy with Bevacizumab (fig. 1). In contrast patient 2 was chemo-naïve at the time of Bevacizumab therapy. Thus younger, optimally debulked patients may be excellent candidates for a trial of Bevacizumab therapy, regardless of previous chemotherapy exposure.

Therapy with Bevacizumab was generally well-tolerated in both of these patients. Patient 1 developed hypertension that was controlled with medication. She also developed worsening proteinuria requiring a prolonged suspension of therapy. Her proteinuria resolved after 4 months. No evidence of significant hemorrhage, deep-venous thrombosis, or gastric perforation was seen.

The origins of PMP remain somewhat controversial. While the majority of PMP is believed to originate from appendiceal/gastrointestinal tumors, rarely it can be associated with tumors from other sites. PMP has been reported in association with ovarian tumors, including mucinous LMP tumors and cystadenocarcinomas arising from mature cystic teratomas [2]. However, recent molecular and immunohistochemical studies suggest that many PMP-associated ovarian tumors are actually gastrointestinal tumors with ovarian invasion [13].

Both of our patients had PMP diagnosed in conjunction with mucinous ovarian LMP tumors. Patient 1 had her primary surgery at a community center and did not have an appendectomy so may have had appendiceal disease. Interestingly, patient 2 had primary surgery, which included appendectomy, at a major academic center. Pathology revealed no evidence of appendiceal disease and intra-ovarian disease without surface involvement, more consistent with ovarian primary.

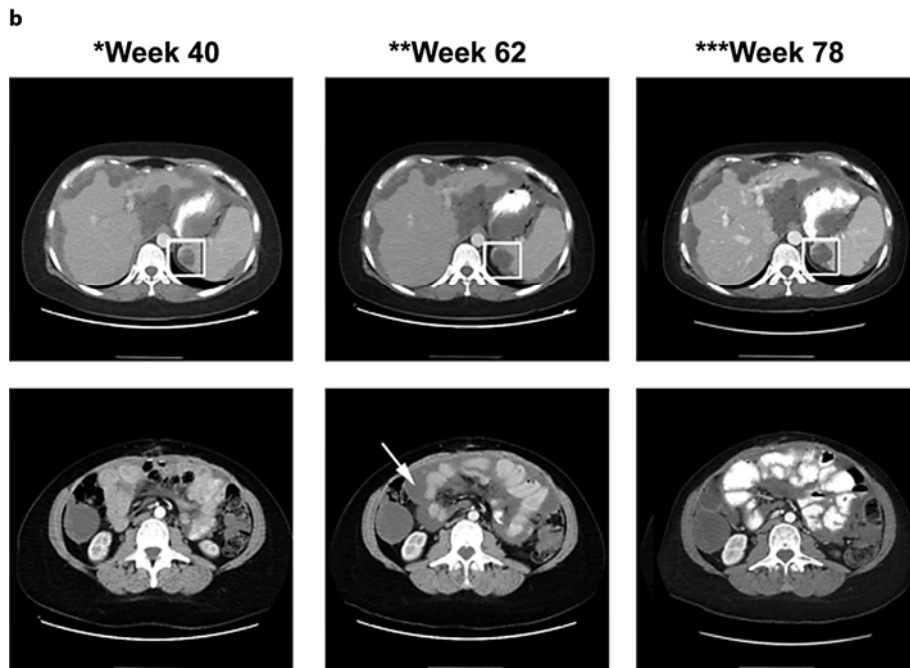
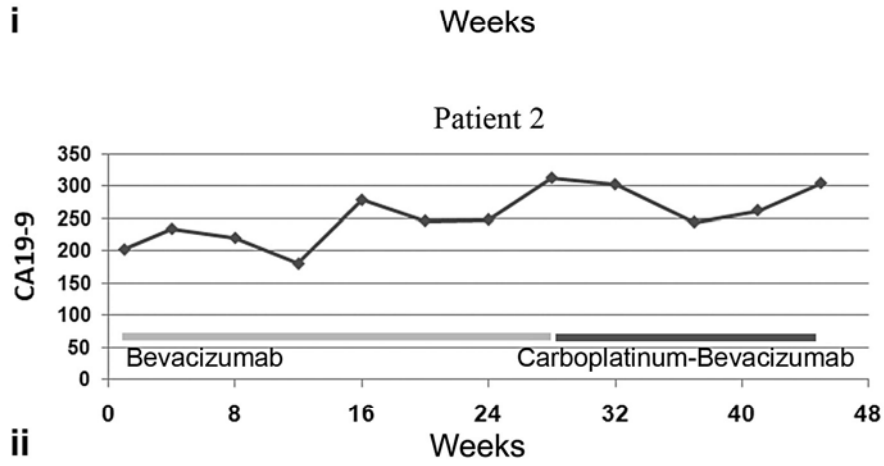
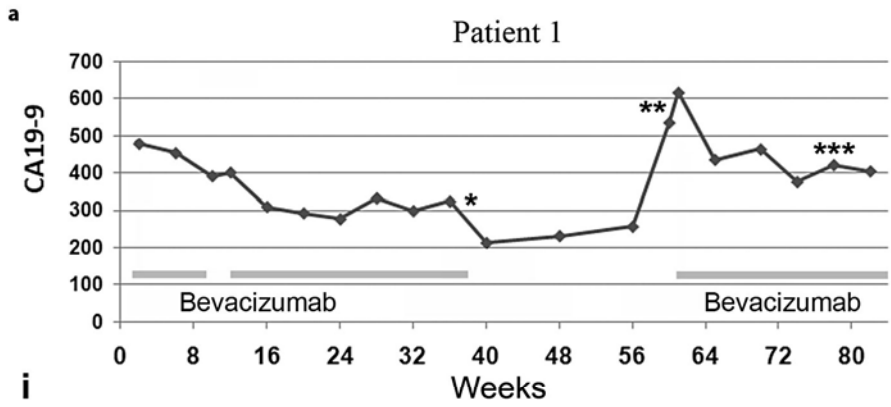
Regardless of the origin, the long-term prognosis for recurrent PMP is poor secondary to disease progression [1, 12]. PMP is classically thought to be resistant to systemic chemotherapy. There have been case reports of pseudomyxoma response to chemotherapy. One patient with a progressive DPAM tumor with neuroendocrine features demonstrated response to therapy with intravenous gemcitabine [14]. A second report suggested activity of FOLFOX chemotherapy delivered adjuvantly to a patient after surgery for an appendiceal pseudomyxoma. The patient was treated with 10 months of chemotherapy and remained without evidence of disease progression at 21 months. More importantly, the first clinical trial suggesting a potential benefit from chemotherapy in this patient population was recently reported. A phase II trial of mitomycin-C and capecitabine in 40 patients with non-resectable PMP reported response or stable disease in 38% of patients [15]. Two thirds of these patients had DPAM. Of the patients with progressive disease, only 14% demonstrated a reduction in disease (3 with decreased ascites and 1 with a decrease in tumor burden). Tumor marker responses in these patients appeared to correlate with disease response. Interestingly, two thirds of eligible patients reported an improvement in their quality of life while on therapy due to a reduction in symptoms.

While this phase II study is encouraging, further management strategies for PMP are clearly necessary; the majority of patients in this study did not receive a clinical benefit. Our experience with Bevacizumab suggests a relatively non-toxic therapy with significant activity in ovarian PMP worthy of further study. Similar to the patients in the trial with mitomycin-C and capecitabine, our patients demonstrated tumor marker response that correlated with disease response. Patient 1 demonstrated a clear reduction in her ascites as well as tumor. Patient 2 had a clinical and biomarker response to both single agent Bevacizumab and Bevacizumab in combination with chemotherapy. This report provides an initial rationale for the use of Bevacizumab in clinical trials in PMP. Given the improved activity observed with Bevacizumab in combination with chemotherapy in other solid tumors and the recent report of an active chemotherapeutic regimen for PMP, trials with Bevacizumab as a single agent or in combination with chemotherapy for unresectable PMP may be warranted.

Table 1. Contrasting clinical characteristics of the two reported cases

	Patient 1	Patient 2
Age, years	38 (33 at presentation)	82 (78 at presentation)
Tumor stage	IIIb	IIIc
Optimal interval debulking	Yes	No
Prior chemotherapies, n	6	None
Time from interval debulking surgery to therapy	2 months	13 months
Progression-free survival	>13 months and >8 months with retreatment	5 months
Side-effects	Hypertension, proteinuria	Neuropathy

Fig. 1. Disease response to Bevacizumab therapy. **a** CA19-9 biomarker response to Bevacizumab therapy in patient 1 (i) and patient 2 (ii), respectively. Light gray bars indicate administration of single agent Bevacizumab. Dark gray bar indicates administration of Bevacizumab and carboplatinum. The timing of serial CT scans shown in **b** are indicated with asterisks. **b** CT scan of patient 2 with serial scans demonstrating disease state after the first course of Bevacizumab therapy (left panels), evidence of progression after discontinuation of therapy (middle panels) and stabilization of disease with re-initiation of therapy (right panels). Boxes indicate representative splenic lesion. The arrow indicates increased ascites at the time of recurrence which significantly resolved with re-initiation of therapy.



References

- 1 Sherer D, Abulafia O, Eliakim R: Pseudomyxoma peritonei: a review of current literature. *Gynecol Obstet Invest* 2001;51:73–80.
- 2 Ronnett BM, Seidman JD: Mucinous tumors arising in ovarian mature cystic teratomas: relationship to the clinical syndrome of pseudomyxoma peritonei. *Am J Surg Pathol* 2003;27:650–657.
- 3 Ronnett BM, Kurman RJ, Zahn CM, et al: Pseudomyxoma peritonei in women: a clinicopathologic analysis of 30 cases with emphasis on site of origin, prognosis, and relationship to ovarian mucinous tumors of low malignant potential. *Hum Pathol* 1995;26:509–524.
- 4 Lo CH, Bohmer RD, Blomfield PI: An evidence-based approach: Sugarbaker protocol and pseudomyxoma peritonei of appendiceal origin. *ANZ J Surg* 2008;78:327–328.
- 5 Elias D, Honore C, Ciuchendea R, et al: Peritoneal pseudomyxoma: results of a systematic policy of complete cytoreductive surgery and hyperthermic intraperitoneal chemotherapy. *Br J Surg* 2008;95:1164–1171.
- 6 Smeenk RM, Verwaal VJ, Antonini N, Zoetmulder FA: Progression of pseudomyxoma peritonei after combined modality treatment: management and outcome. *Ann Surg Oncol* 2007;14:493–499.
- 7 Harshen R, Jyothirmayi R, Mithal N: Pseudomyxoma peritonei. *Clin Oncol (R Coll Radiol)* 2003;15:73–77.
- 8 Logan-Collins JM, Lowy AM, Robinson-Smith TM, et al: VEGF expression predicts survival in patients with peritoneal surface metastases from mucinous adenocarcinoma of the appendix and colon. *Ann Surg Oncol* 2008;15:738–744.
- 9 Wilkes GM: Bevacizumab for renal cell carcinoma, glioblastoma, and other solid tumors. *Oncology* 2009;11(suppl):54–56.
- 10 Starling N, Cunningham D: Monoclonal antibodies against vascular endothelial growth factor and epidermal growth factor receptor in advanced colorectal cancers: present and future directions. *Curr Opin Oncol* 2004;16:385–390.
- 11 Kaye SB: Bevacizumab for the treatment of epithelial ovarian cancer: Will this be its finest hour? *J Clin Oncol* 2007;25:5150–5152.
- 12 Lee JK, Song SH, Kim I, et al: Retrospective multicenter study of a clinicopathologic analysis of pseudomyxoma peritonei associated with ovarian tumors (KGOG 3005). *Int J Gynecol Cancer* 2008;18:916–920.
- 13 Szych C, Staebler A, Connolly DC, et al: Molecular genetic evidence supporting the clonality and appendiceal origin of Pseudomyxoma peritonei in women. *Am J Pathol* 1999;154:1849–1855.
- 14 Eisele L, Sheu SY, Muller-Beissenhertz H, et al: Response of pseudomyxoma peritonei to gemcitabine. *Acta Oncol* 2006;45:98–100.
- 15 Farquharson AL, Pranesh N, Witham G, et al: A phase II study evaluating the use of concurrent mitomycin C and capecitabine in patients with advanced unresectable pseudomyxoma peritonei. *Br J Cancer* 2008;99:591–596.