

## Original Research



## OPEN ACCESS

**Received:** Jul 16, 2021

**Revised:** Sep 2, 2021

**Accepted:** Sep 29, 2021

**Published online:** Oct 28, 2021

### Correspondence to

**Young-Guk Ko, MD**








Division of Cardiology, Yonsei Cardiovascular Hospital, Yonsei University College of Medicine, 50, Yonsei-ro, Seodaemun-gu, Seoul 03722, Korea.  
Email: ygko@yuhs.ac

\*Jung-Joon Cha and Jae-Hwan Lee contributed equally to this work.




Copyright © 2022. The Korean Society of Cardiology

This is an Open Access article distributed under the terms of the Creative Commons Attribution Non-Commercial License (<https://creativecommons.org/licenses/by-nc/4.0>) which permits unrestricted noncommercial use, distribution, and reproduction in any medium, provided the original work is properly cited.

### ORCID iDs

Jung-Joon Cha   
<https://orcid.org/0000-0002-8299-1877>  
Jae-Hwan Lee   
<https://orcid.org/0000-0002-6561-7760>  
Young-Guk Ko   
<https://orcid.org/0000-0001-7748-5788>  
Jae-Hyung Roh   
<https://orcid.org/0000-0003-3675-3541>  
Yong-Hoon Yoon   
<https://orcid.org/0000-0002-5598-003X>  
Yong-Joon Lee   
<https://orcid.org/0000-0003-4526-6120>  
Seung-Jun Lee   
<https://orcid.org/0000-0002-9201-4818>

# Clinical Outcomes of Atherectomy Plus Drug-coated Balloon Versus Drug-coated Balloon Alone in the Treatment of Femoropopliteal Artery Disease

Jung-Joon Cha <sup>1,\*</sup>, Jae-Hwan Lee <sup>1,\*</sup>, Young-Guk Ko <sup>1,3</sup>, Jae-Hyung Roh <sup>1,3</sup>, Yong-Hoon Yoon <sup>1,3</sup>, Yong-Joon Lee <sup>1,3</sup>, Seung-Jun Lee <sup>1,3</sup>, Sung-Jin Hong <sup>1,3</sup>, Chul-Min Ahn <sup>1,3</sup>, Jung-Sun Kim <sup>1,3</sup>, Byeong-Keuk Kim <sup>1,3</sup>, Donghoon Choi <sup>1,3</sup>, Myeong-Ki Hong <sup>1,3</sup>, and Yangsoo Jang <sup>1,3</sup>

<sup>1</sup>Division of Cardiology, Korea University Anam Hospital, Korea University College of Medicine, Seoul, Korea

<sup>2</sup>Division of Cardiology, Chungnam National University Sejong Hospital, Sejong, Korea

<sup>3</sup>Division of Cardiology, Severance Cardiovascular Hospital, Yonsei University College of Medicine, Seoul, Korea

<sup>4</sup>Division of Cardiology, Yongin Severance Hospital, Yonsei University College of Medicine, Yongin, Korea

## AUTHOR'S SUMMARY








Drug-coated balloons (DCBs) emerged as an attractive treatment option for femoropopliteal artery disease. However, achieving the best outcome with DCB needed proper vessel preparation. Thus, the reduction and modification of atherosclerotic plaques by atherectomy were suggested. This study investigated the efficacy of atherectomy in native femoropopliteal artery disease compared with DCB alone using two-center cohorts. As a result, the pretreatment with atherectomy improved the technical success of DCB treatment; however, it was associated with increased minor complications. Additionally, atherectomy plus DCB showed no clinical benefit regarding TLR-free survival or clinical patency compared with DCB treatment alone.

## ABSTRACT

**Background and Objectives:** Atherectomy as a pretreatment has the potential to improve the outcomes of drug-coated balloon (DCB) treatment by reducing and modifying atherosclerotic plaques. The present study investigated the outcomes of atherectomy plus DCB (A+DCB) compared with DCB alone for the treatment of femoropopliteal artery disease.

**Methods:** A total of 311 patients (348 limbs) underwent endovascular therapy using DCB for native femoropopliteal artery lesions at two endovascular centers. Of these, 82 limbs were treated with A+DCB and 266 limbs with DCB alone. After propensity score matching based on clinical and lesion characteristics, a total of 82 pairs was compared for immediate and mid-term outcomes.

**Results:** For the matched study groups, the lesion length was 172.7±111.2 mm, and severe calcification was observed in 43.3%. The technical success rate was higher in the A+DCB group than in the DCB group (80.5% vs. 62.2%, p=0.015). However, the A+DCB group

Sung-Jin Hong   
<https://orcid.org/0000-0003-4893-039X>  
 Chul-Min Ahn   
<https://orcid.org/0000-0002-7071-4370>  
 Jung-Sun Kim   
<https://orcid.org/0000-0003-2263-3274>  
 Byeong-Keuk Kim   
<https://orcid.org/0000-0003-2493-066X>  
 Donghoon Choi   
<https://orcid.org/0000-0002-2009-9760>  
 Myeong-Ki Hong   
<https://orcid.org/0000-0002-2090-2031>  
 Yangsoo Jang   
<https://orcid.org/0000-0002-2169-3112>

### Funding

This research was supported by grants from the Korea Health Technology R&D Project through the Korea Health Industry Development Institute (KHIDI) and a grant of Patient-Centered Clinical Research Coordinating Center (PACEN) funded by the Ministry of Health & Welfare, Republic of Korea (HC20C0081), the Korea Medical Device Development Fund funded by the Korean government (the Ministry of Science and ICT, the Ministry of Trade, Industry and Energy, the Ministry of Health & Welfare, the Ministry of Food and Drug Safety) (202011B29-03, 202011D12-02) and the Cardiovascular Research Center (Seoul, Korea).

### Conflict of Interest

The authors have no financial conflicts of interest.

### Data Sharing Statement

The data generated in this study is available from the corresponding author(s) upon reasonable request.

### Author Contributions

Conceptualization: Cha JJ, Lee JH, Ko YG;  
 Data curation: Cha JJ, Lee JH, Ko YG; Formal analysis: Cha JJ, Ko YG; Funding acquisition: Ko YG; Investigation: Cha JJ, Lee JH, Ko YG; Project administration: Ko YG; Resources: Roh JH, Yoon YH, Lee YJ, Lee SJ, Hong SJ, Ahn CM, Kim JS, Kim BK, Choi D, Hong MK, Jang Y; Supervision: Cha JJ, Lee JH, Ko YG, Roh JH, Yoon YH, Lee YJ, Lee SJ, Hong SJ, Ahn CM, Kim JS, Kim BK, Choi D, Hong MK, Jang Y; Visualization: Cha JJ, Lee JH, Ko YG; Writing - original draft: Cha JJ, Lee JH, Ko YG; Writing - review & editing: Cha JJ, Lee JH, Ko YG.

showed more procedure-related minor complications (37.0% vs. 13.4%,  $p=0.047$ ). At 2-year follow-up, primary clinical patency (73.8% vs. 82.6%,  $p=0.158$ ) and the target lesion revascularization (TLR)-free survival (84.3% vs. 88.2%,  $p=0.261$ ) did not differ between the two groups. In Cox proportional hazard analysis, atherectomy showed no significant impact on the outcome of DCB treatments.

**Conclusions:** The pretreatment with atherectomy improved technical success of DCB treatment; however, it was associated with increased minor complications. In this study, A+DCB showed no clinical benefit in terms of TLR-free survival or clinical patency compared with DCB treatment alone.

**Keywords:** Femoral artery; Popliteal artery; Atherectomy; Paclitaxel; Balloon angioplasty

## INTRODUCTION

The femoropopliteal artery (FPA) is a common target for endovascular therapy in patients with symptomatic lower-extremity artery disease.<sup>1</sup> However, providing optimal endovascular therapy for FPA disease is often challenging because these lesions are usually long, occlusive, and calcified.<sup>1</sup> Furthermore, the FPA is affected by various mechanical forces generated by leg movements and surrounding structures.<sup>2</sup> Implantation of self-expanding nitinol stents has been shown to achieve outcomes superior to those with balloon angioplasty in FPA lesions of intermediate lesion length.<sup>3</sup> However, with increasing lesion length, the rate of restenosis after stent implantation rises significantly. In addition, stenting in the distal superficial femoral artery or popliteal artery and in long lesions has been associated with increased risk of stent fractures.<sup>4</sup>

Drug-coated balloons (DCBs) with a concept of “leave nothing behind” emerged as an attractive treatment option for FPA disease. In randomized controlled trials and global registry studies, DCBs demonstrated excellent clinical outcomes.<sup>5-8</sup> The recent guidelines recommend an endovascular-first strategy and drug-eluting technologies including DCBs for FPA lesions shorter than 25 cm.<sup>9</sup> However, relatively long lesions frequently require provisional stenting due to severe arterial dissections or significant residual stenosis after DCB treatment.<sup>7,10</sup> Furthermore, severe calcification has been shown to be associated with increased risk for restenosis after DCB.<sup>11</sup> Thus, the reduction and modification of atherosclerotic plaques by atherectomy was suggested as a vessel preparation with potential to improve the outcomes of DCB.<sup>12,13</sup> However, two pilot randomized controlled trials showed no significant superiority of atherectomy plus DCB (A+DCB) over DCB alone in the late clinical outcomes,<sup>14,15</sup> and the clinical benefit of atherectomy prior to DCB remains uncertain.

Thus, we sought to investigate the efficacy of atherectomy in native FPA disease compared with DCB alone using a two-center cohort.

## METHODS

### Ethical statement

This study protocol complies with the latest ethical guidelines of the Declaration of Helsinki (2013). The Institutional Review Boards at the participating hospitals approved this study and waived the requirement for informed consent for the retrospective cohort patients (approval

number: 4-2013-0463). All patients in the prospective cohort gave written informed consent to data collection.

### Study populations

This study analyzed data from retrospective (from January 2006 to November 2016) and prospective (from December 2016 on) observational cohorts of patients who received endovascular therapy for lower-extremity artery disease at two endovascular centers (Severance Cardiovascular Hospital, Seoul, Korea and Chungnam National University Hospital, Daejeon, Korea). We identified a total of 478 patients who underwent endovascular revascularization with DCBs for FPA disease from December 2012 to September 2018. After exclusion of cases with in-stent restenosis, previous intervention with DCBs, and follow-up loss after hospital discharge, a total of 311 patients (348 limbs) with symptomatic native FPA disease were included in this analysis. Of this study population, 72 patients (82 limbs) were treated with atherectomy as vessel preparation prior to DCB angioplasty.

### Endovascular procedure

All patients received maintenance daily doses of aspirin (100 mg) and 135 clopidogrel (75 mg) for at least 5 days before the procedure or loading doses of aspirin (300 mg) and clopidogrel (300 mg) 1 day before the procedure. Under local anesthesia, vascular access was obtained by percutaneous puncture of the ipsilateral or the contralateral common femoral artery depending on the location of the target lesion. After placement of a 6–7 Fr sheath, an intra-arterial bolus of heparin (70–100 U/kg) and additional heparin doses were administered to maintain an activated clotting time >250 sec during the procedure. A 0.035-, 0.018-, or 0.014-inch guidewires supported by a 4–5 Fr multipurpose catheter or microcatheter was used to pass the target lesions. Occlusive lesions with failed intraluminal recanalization were recanalized by a subintimal approach with reentrance into the true lumen. All lesions were routinely predilated with a balloon catheter except for patients treated with atherectomy prior to DCB. Pretreatment with an atherectomy device was performed at the operator's discretion in selected patients with heavily calcified or long lesions. Distal embolization protection devices (such as SpiderFX [Medtronic, Dublin, Ireland] or Emboshield NAV6 [Abbott Vascular, Santa Clara, CA, USA]) were used in selected cases of atherectomy when the target lesion was long or heavily calcified. After predilation or atherectomy, all lesions were treated with DCBs (IN.PACT Admiral [Medtronic Inc., Santa Rosa, CA, USA] or Lutonix [Bard, Tempe, AZ, USA]). In lesions requiring more than one DCB, a minimal overlap of 10 mm was obtained. If residual stenosis exceeded 30%, post-dilation was performed with an additional uncoated non-compliant balloon. Stenting was considered only as a last resort in the presence of flow-limiting dissection or when residual stenosis exceeded 30% despite post-dilation. After the procedure, dual-antiplatelet therapy with aspirin (100 mg/day) and clopidogrel (75 mg/day) was continued for at least 6 months unless contraindicated. The use of cilostazol (200 mg/day) was determined at the operator's discretion.

### Study endpoints and definitions

The primary endpoint was primary clinical patency defined as freedom from symptom aggravation by at least one Rutherford category change combined with a decrease in ankle-brachial index (ABI) >0.15 or with presence of restenosis (≥50%) on imaging studies, such as duplex ultrasound, computed tomographic angiography, or intra-arterial angiography. For duplex ultrasound, peak velocity ≥180 cm/s or a lesion/adjacent-segment velocity ratio ≥2.4 was considered to indicate significant (≥50%) restenosis. Secondary endpoints were clinically driven target lesion revascularization (TLR) and major adverse limb events (MALE). TLR was

defined as reintervention at the target lesion due to symptoms or decrease in ABI  $>0.15$  when compared with post-procedure ABI. MALE was defined as above-ankle amputation of the index limb or major repeat revascularization of the target limb; and all causes of death.

Technical success was defined as residual stenosis  $\leq 30\%$ . A major complication was defined as any event that was either fatal or required surgical management or rehospitalization within 30 days of the procedure. Dyslipidemia was defined as either total cholesterol  $>200$  mg/dL or previous treatment with a lipid-lowering agent.

The severity of arterial calcification was defined based on the peripheral arterial calcium scoring system.<sup>16)</sup> The presence of unilateral arterial calcification  $<5$  cm in length on fluoroscopy was considered mild calcification (grade 1), whereas calcification was considered moderate if unilateral calcification was  $>5$  cm (grade 2) or if bilateral calcification was  $<5$  cm in length (grade 3). Bilateral calcifications  $>5$  cm in length constituted severe calcification (grade 4).

### Statistical analysis

Categorical variables are reported as numbers (percentages) and were compared using the chi-square test or Fisher exact test. Continuous variables are reported as mean  $\pm$  standard deviation (SD) and were compared using Student's t-test. Propensity score matching (PSM) was performed to reduce treatment-selection bias and potential confounding factors and to adjust for significant differences in characteristics of patients or their lesions. Propensity scores were estimated using a non-parsimonious multiple logistic regression model for usage of atherectomy. Age, sex, hypertension, diabetes mellitus, dyslipidemia, end-stage renal disease, history of coronary artery disease, current smoker, history of a previous stroke, discharge medications (aspirin, clopidogrel, and cilostazol), Trans-Atlantic Inter-Society Consensus (TASC) II C or D lesions, total occlusion, popliteal artery involvement, lesion length, runoff numbers of below-the-knee arteries, and the variables that were significantly different between the two classified groups (critical limb ischemia, chronic kidney disease, combined treatment of infrapopliteal lesion, severe calcification) were selected to calculate the propensity score. Balanced propensity scores were gathered to compare the efficacy of the A+DCB strategy. A local optimal algorithm using the caliper method was used to develop propensity-score-matched pairs without replacement (1:1 match). To ensure that poorly fitting matches were excluded, a matching caliper of 0.2 SDs from the estimated propensity score logit was enforced.

Primary clinical patency, TLR-free survival, MALE-free survival, and overall survival were quantified using the Kaplan-Meier method and were compared by the log-rank test. To identify risk factors of restenosis, univariate and multivariate Cox proportional hazard regression analyses were performed with all baseline clinical and procedural variables. All p values were determined in two-sided tests, and p values  $<0.05$  were considered statistically significant. Analyses were performed using IBM SPSS (version 25, Chicago, IL, USAs).

## RESULTS

### Baseline characteristics

The present study included a total of 348 limbs from 311 patients with native FPA disease who were treated with DCBs (IN.PACT Admiral [Medtronic] or Lutonix [Bard]). Of this study population, 82 limbs (72 patients) were treated with A+ DCB and 266 limbs (236 patients) were

**Table 1.** Baseline clinical characteristics

Treatment strategy	Before matching			After matching		
	A+DCB (n=82)	DCB (n=266)	p	A+DCB (n=82)	DCB (n=82)	p
Age (years)	70.1±10.4	70.0±11.4	0.920	70.1±10.4	68.8±12.6	0.479
Male	67 (81.7)	214 (80.5)	0.927	67 (81.7)	68 (82.9)	1.000
Hypertension	69 (84.1)	201 (75.6)	0.139	69 (84.1)	68 (82.9)	1.000
DM	62 (75.6)	182 (68.4)	0.269	62 (75.6)	58 (70.7)	0.597
Dyslipidemia	60 (73.2)	171 (64.3)	0.175	60 (73.2)	63 (76.8)	0.718
CKD	18 (22.0)	91 (34.2)	0.050	18 (22.0)	18 (22.0)	1.000
ESRD	12 (14.6)	48 (18.0)	0.584	12 (14.6)	14 (17.1)	0.831
CAD	40 (48.8)	139 (52.3)	0.671	40 (48.8)	37 (45.1)	0.754
Current smoker	25 (30.5)	80 (30.1)	1.000	25 (30.5)	20 (24.4)	0.484
Previous stroke	10 (12.2)	44 (16.5)	0.438	10 (12.2)	9 (11.0)	1.000
CLI	26 (31.7)	139 (52.3)	0.002	26 (31.7)	36 (43.9)	0.147
Discharge medication						
Aspirin	70 (85.4)	220 (82.7)	0.693	70 (85.4)	69 (84.1)	1.000
Clopidogrel	65 (79.3)	214 (80.5)	0.939	65 (79.3)	65 (79.3)	1.000
Cilostazol	43 (52.4)	122 (45.9)	0.360	43 (52.4)	38 (46.3)	0.532
Statin	67 (81.7)	221 (83.1)	0.904	67 (81.7)	69 (84.1)	0.836

Data are presented as mean±standard deviation or number (%).

A+DCB = atherectomy plus DCB; CAD = coronary artery disease; CKD = chronic kidney disease; CLI = chronic limb ischemia; DCB = drug coated balloon; DM = diabetes mellitus; ESRD = end stage renal disease.

treated with DCB without prior atherectomy. Baseline clinical characteristics are summarized in **Table 1**. The A+ DCB group showed less frequent chronic kidney disease (CKD) (22.0% vs. 34.2%,  $p=0.050$ ) and critical limb ischemia (31.7% vs. 52.3%,  $p=0.002$ ) compared with the DCB group. Other characteristics were comparable between the two groups. After PSM, 82 matched pairs of each group were generated. All baseline clinical variables did not differ significantly between the two matched groups. The mean age of the matched study population was  $70.2\pm 10.7$  years. Diabetes and CKD was present in 73.2% and in 22.0%, respectively.

### Lesion and procedural data

Lesion and procedural characteristics and in-hospital outcomes are summarized in **Table 2**. Whereas the A+ DCB group showed more severe calcification (46.3% vs. 17.7%,  $p<0.001$ ) and intravascular ultrasound use (19.5% vs. 6.0%,  $p=0.001$ ), the DCB-only group had more combined treatment of infrapopliteal lesions (31.7% vs. 45.5%,  $p=0.037$ ). After PSM, all lesion variables were comparable between the two groups except intravascular ultrasound usage. For the matched study groups, the mean lesion length was  $172.7\pm 111.2$  mm. TASC II C or D lesion type and severe calcification was present in 49.4% and 43.3%, respectively.

In the A+DCB group, two types of atherectomy devices were used, directional devices (59.8%) and rotational devices (40.2%). Embolization protection filters were used in 65.9% of the A+DCB group. The incidence of arterial dissections was lower in the A+DCB group than in the DCB group (32.9% vs. 52.4%,  $p=0.018$ ). However, the incidence of complex dissection types, including types D, E, and F, was low and showed no difference between the A+DCB and the DCB groups (1.2% vs. 4.9%,  $p=0.367$ ). The provisional stenting rates also did not differ significantly between the two groups (3.7% vs. 6.1%,  $p=0.717$ ). Other procedural characteristics, such as subintimal wiring approach and post-dilation, showed no difference between the two groups.

The technical success rate was higher in the A+DCB group than in the DCB group (80.5% vs. 62.2%,  $p=0.015$ ) (**Table 3**). However, the A+DCB group showed more procedure-related minor complications (37.0% vs. 13.4%,  $p=0.047$ ), including distal embolization and vascular

**Table 2.** Lesion and procedural characteristics

Treatment strategy	Before matching			After matching		
	A+DCB (n=82)	DCB (n=266)	p	A+DCB (n=82)	DCB (n=82)	p
TASC C/D lesion	40 (48.8)	123 (46.2)	0.782	40 (48.8)	41 (50.0)	1.000
Popliteal artery involvement	26 (31.7)	89 (33.5)	0.872	26 (31.7)	26 (31.7)	1.000
Severe calcification	38 (46.3)	47 (17.7)	<0.001	38 (46.3)	32 (39.0)	0.430
Total occlusion	40 (48.8)	121 (45.5)	0.692	40 (48.8)	39 (47.6)	1.000
Lesion length (mm)	176.0±120.9	181.9±100.4	0.685	176.0±120.9	175.9±104.5	0.997
Runoff vessel ≤1	27 (32.9)	96 (36.1)	0.695	27 (32.9)	25 (30.5)	0.867
Combined targets						
Iliac lesion	12 (14.6)	41 (15.4)	1.000	12 (14.6)	7 (8.5)	0.329
BTK lesion	26 (31.7)	121 (45.5)	0.037	26 (31.7)	28 (34.1)	0.590
Subintimal approach	13 (15.9)	69 (25.9)	0.083	13 (15.9)	20 (24.4)	0.243
DCB type			<0.001			0.013
IN.PACT	71 (86.6)	174 (65.4)		71 (86.6)	57 (69.5)	
Lutonix	11 (13.4)	92 (34.6)		11 (13.4)	25 (30.5)	
Atherectomy			-			-
Directional	49 (59.8)	-		49 (59.8)	-	
Rotational	33 (40.2)	-		33 (40.2)	-	
Protection filter	54 (65.9)	1 (0.4)	<0.001	54 (65.9)	0 (0.0)	<0.001
IVUS	16 (19.5)	16 (6.0)	0.001	16 (19.5)	5 (6.1)	0.019
Post-dilation	6 (7.3)	7 (2.6)	0.105	6 (7.3)	2 (2.4)	0.277
Arterial dissection	27 (32.9)	144 (54.1)	0.001	27 (32.9)	43 (52.4)	0.018
Type A-C	26 (31.7)	138 (51.9)	0.002	26 (31.7)	39 (47.6)	0.055
Type D-F	1 (1.2)	16 (6.0)	0.086	1 (1.2)	4 (4.9)	0.367
Provisional stenting	3 (3.7)	20 (7.5)	0.329	3 (3.7)	5 (6.1)	0.717

Data are presented as mean±standard deviation or number (%).

A+DCB = atherectomy plus DCB; BTK = below the knee; DCB = drug coated balloon; TASC = Trans-Atlantic Inter-Society Consensus; IVUS = intravascular ultrasound.

**Table 3.** Immediate procedure outcomes

Treatment strategy	Before matching			After matching		
	A+DCB (n=82)	DCB (n=266)	p	A+DCB (n=82)	DCB (n=82)	p
Technical success*	66 (80.5)	188 (69.2)	0.080	66 (80.5)	52 (63.4)	0.015
Complications						
Total	11 (13.4)	9 (3.4)	0.002	11 (13.4)	3 (3.7)	0.047
Major	0 (0.0)	1 (0.4)	1.000	0 (0.0)	0 (0.0)	-
Minor						
Embolization	6 (7.3)	2 (0.8)	0.002	6 (7.3)	1 (1.2)	0.122
Vascular perforation	5 (6.1)	3 (1.1)	0.028	5 (6.1)	0 (0.0)	0.069
Access complications	0 (0)	5 (1.9)	0.458	0 (0.0)	2 (2.4)	0.363
Pre-ABI	0.51±0.21	0.56±0.27	0.113	0.51±0.21	0.54±0.25	0.424
Post-ABI	0.86±0.16	0.88±0.17	0.528	0.86±0.16	0.89±0.16	0.360

Data are presented as mean ± standard deviation or number (%).

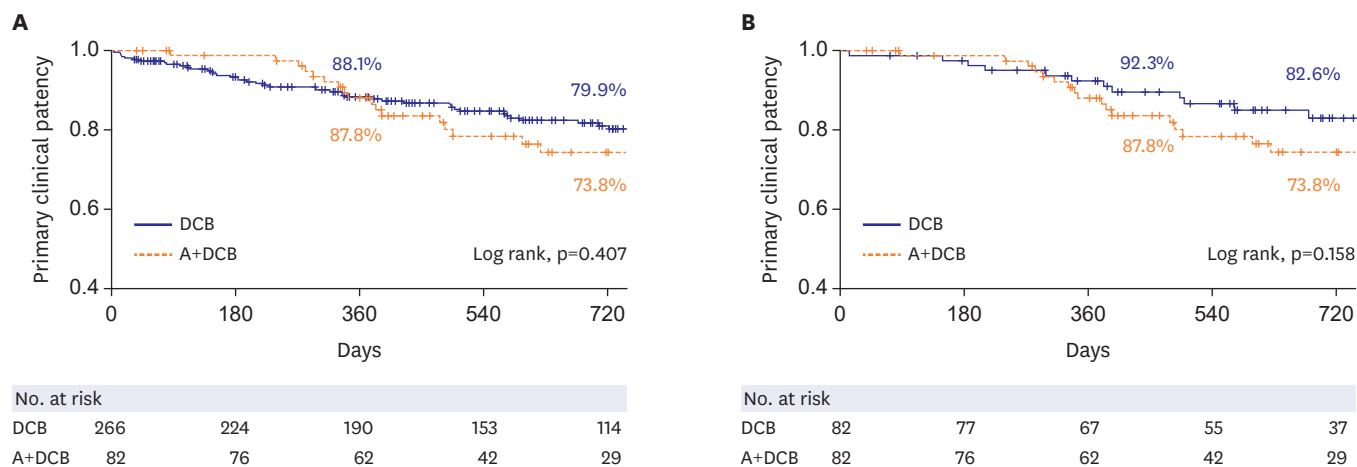
ABI = ankle-brachial index; A+DCB = atherectomy plus DCB; DCB = drug coated balloon.

\*Defined as residual stenosis ≤30%.

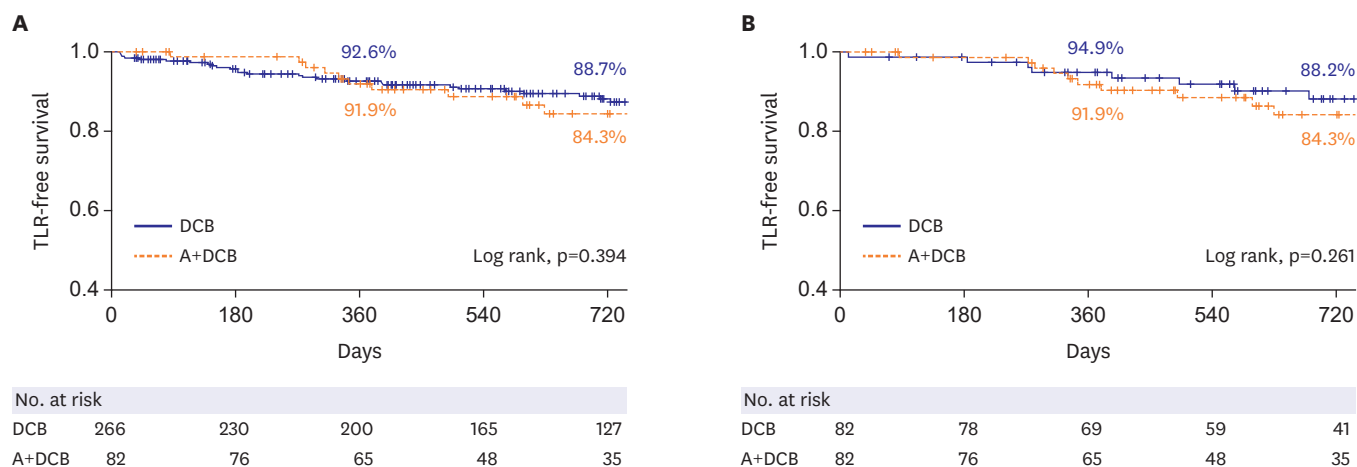
perforation. Regarding the distal embolization rate, there was no difference according to the type of DCB in both groups.

### Mid-term clinical outcomes

Patients were clinically followed for a mean duration of 24.8±14.3 months. The 2-year primary clinical patency did not differ significantly between the A+DCB and the DCB group before the PSM (73.8% vs. 79.9%, p=0.407) or after the PSM (73.8% vs. 82.6%, p=0.158) (**Figure 1** and **Supplementary Table 1**). Similarly, 2-year TLR-free survival was also not different between the two groups before (84.3% vs. 88.7%, p=0.394) and after the PSM (84.3% vs. 88.2%, p=0.261) (**Figure 2** and **Supplementary Table 1**). The rates of mortality (11.8% vs. 18.5%, p=0.385) and the MALE (21.2% vs. 13.2%, p=0.147) at 2 years also showed no difference between the two matched groups (**Supplementary Table 1**).



**Figure 1.** Kaplan-Meier survival analysis for primary clinical patency; unmatched study population (A) and propensity score-matched study population (B). A+DCB = atherectomy plus drug-coated balloon; DCB = drug-coated balloon.



**Figure 2.** Kaplan-Meier survival analysis for target lesion revascularization-free survival; unmatched study population (A) and propensity score-matched study population (B). A+DCB = atherectomy plus drug-coated balloon; DCB = drug-coated balloon; TLR = target lesion revascularization.

Cox proportional hazard regression multivariate analysis was performed to investigate predictors of loss of clinical patency (Table 4). In this analysis, atherectomy showed no impact on the loss of patency (hazard ratio [HR], 1.25; 95% confidence interval [CI], 0.74–2.13;  $p=0.408$ ) and TLR (HR, 1.32; 95% CI, 0.69–2.52;  $p=0.395$ ). Diabetes mellitus (adjusted HR, 0.38; 95% CI, 0.21–0.70;  $p=0.019$ ) and end-stage renal disease (adjusted HR, 2.17; 95% CI, 1.04–4.55;  $p=0.040$ ) were identified as independent predictors for the loss of primary clinical patency.

## DISCUSSION

In this two-center cohort study, the A+DCB achieved a higher technical success rate compared with DCB alone; however, it was associated with more frequent minor procedure-related complications, including distal embolizations and vascular perforations. The primary clinical patency and TLR-free survival showed no significant difference between the two treatment strategies.

**Table 4.** Univariate and multivariate Cox proportional hazard analysis for the predictors of loss of primary clinical patency

Variables	Univariate analysis			Multivariate analysis		
	HR	95% CI	p	HR	95% CI	p
DM	0.56	0.37–0.91	0.019	0.38	0.21–0.70	0.002
CKD	1.64	1.00–2.70	0.049	-	-	-
ESRD	2.14	1.23–3.73	0.007	2.17	1.04–4.55	0.040
History of stroke	1.68	0.94–2.98	0.078	1.62	0.84–3.09	0.149
Lesion length (mm)	1.00	0.99–1.00	0.109	1.00	0.99–1.00	0.468
TASC C/D lesions	1.55	0.96–2.50	0.075	1.17	0.59–2.32	0.646
Severe calcification	1.46	0.86–2.84	0.159	1.17	0.59–2.34	0.649
Distal run off vessel ≤1	1.45	0.895–2.37	0.141	1.33	0.72–2.46	0.361
Atherectomy	1.25	0.74–2.13	0.408	1.34	0.72–2.50	0.351
Directional	0.92	0.35–2.40	0.868	-	-	-
Rotational	1.08	0.42–2.83	0.868	-	-	-
DCB device type						
IN.PACT	0.77	0.47–1.26	0.298	-	-	-
Lutonix	1.30	0.79–2.14	0.298	-	-	-
Post ABI	0.34	0.08–1.42	0.139	0.29	0.06–1.48	0.137
Cilostazol	0.63	0.39–1.02	0.060	0.72	0.41–1.28	0.268

ABI = ankle-brachial index; CI = confidence interval; CKD = chronic kidney disease; DCB = drug coated balloon; DM = diabetes mellitus; ESRD = end-stage renal disease; HR = hazard ratio; TASC = Trans-Atlantic Inter-Society Consensus.

Endovascular atherectomy has been adopted to achieve plaque reduction and modification with lower risk of arterial dissections after adjunctive balloon dilation.<sup>12)</sup> Particularly, the debulking of heavily calcified plaques by atherectomy is considered to improve the vessel response to balloon dilation and the delivery of antiproliferative drug to the vessel wall.<sup>11)17)</sup> In the present study, pretreatment with atherectomy prior to DCB significantly reduced the incidence of arterial dissection (32.9% vs. 48.8%) and residual stenosis >30% (19.5% vs. 36.6%), resulting in improved technical success (80.5% vs. 62.2%) compared with DCB alone. The A+DCB group showed a trend toward less provisional stenting than the DCB group, although the difference was not statistically significant (3.7% vs. 6.1%). Two small randomized controlled trials also reported similar findings.<sup>14)15)</sup> In these studies, vessel preparation with atherectomy prior to DCB significantly reduced the incidence of severe dissections and successfully reduced the need for stenting. Despite these favorable immediate results, these trials did not demonstrate superior outcomes of A+DCB compared with DCB alone in primary patency or TLR-free survival. A meta-analysis of five clinical studies also found no statistically significant advantages of atherectomy in addition to DCB in terms of the primary patency or TLR.<sup>18)</sup> One of the major limitations of these previous trials was the insufficient statistical power due to small study populations. Thus, it remains inconclusive whether atherectomy prior to DCB has clinical benefit in the treatment of FPA disease. Several other factors also need to be considered as reasons why clinical outcomes of atherectomy could not be shown despite theoretical advantages. Firstly, atherectomy in the trials, including the present study, might have not been optimal in the reduction or modification of plaques. It is still unknown how much plaque-volume reduction is required for the optimal late outcomes. On the other hand, excessive atherectomy may induce medial or adventitial injury, which promotes restenosis.<sup>19)</sup> Secondly, atherectomy prior to DCB may be beneficial only in certain complex lesion subsets, such as heavily calcified or long lesions. Fanelli et al. found that severe calcification was a significant risk factor for loss of patency after DCB.<sup>11)</sup> Severe calcification may limit the arterial response to balloon dilation and impede the uptake of antiproliferative drugs by the arterial wall. Cioppa et al.<sup>17)</sup> reported a 1-year primary patency rate of 90% after A+DCB in severely calcified femoropopliteal lesions. In the long-lesion subgroups of the Lutonix and IN.PACT global registries, arterial dissection occurred in 34.3% and 62.1% and provisional stenting was required in 35.7%



and 39.4%, respectively.<sup>7)10)</sup> The incidences of complex type dissections were 14.9–16.7% in these studies. In the present study, the arterial dissection rate was observed in 52.4% of the DCB group, whereas the A+DCB group showed significantly fewer dissections (32.9%). Unlike the previous studies, the complex type dissections were rare and comparable (1.2% vs. 4.9%,  $p=0.367$ ) between the two groups. The provisional stenting rates remained low in both groups (3.7% vs. 6.1%,  $p=0.717$ ). However, in complex lesions such as long or calcified lesions with greater tendency towards arterial dissections, pretreatment with atherectomy has potential to reduce the requirement for stenting. Furthermore, in so-called “no-stenting zones,” such as the common femoral or popliteal artery, use of atherectomy prior to DCB may also help to avoid stenting.<sup>20)21)</sup> Thus, lesion subsets which may benefit from combined atherectomy and DCB need to be in future investigations.

However, there are also disadvantages related to atherectomy. Previous studies reported a high incidence of distal embolization during atherectomy procedures and advocated use of embolic protection devices.<sup>22)23)</sup> In our study, embolic protection filters were used in 65.9% of cases and observed distal embolization in 7.3%. Meanwhile, a recent study reported that association between the different DCB profiles and distal embolic events.<sup>24)</sup> However, our results revealed no difference in distal embolic events regarding the type of DCB in both the A+DCB group and the DCB group. In addition, there were five cases (6.1%) of vascular perforation caused by atherectomy devices. A meta-analysis reported a vascular perforation rate of 2.6%.<sup>18)</sup> Furthermore, use of atherectomy and embolic protection devices is associated with higher medical costs. Therefore, objective cost-effective analysis is also required in the future.

In this study two types of atherectomy devices were used, directional and rotational. The type of atherectomy device showed no impact on the primary patency. In previous studies, male gender, severe calcification, obesity, lesion length, previous ipsilateral revascularization, chronic limb ischemia, and hypercholesterolemia have been reported as risk factors for restenosis after DCB.<sup>25-27)</sup> In the present study, end-stage renal disease was identified as a predictor for loss of primary patency after DCB angioplasty. Interestingly, diabetes was found to be associated with lower risk of restenosis. In a previous study, insulin-dependent diabetes was reported as a predictor of TLR.<sup>26)</sup> However, whereas previous studies enrolled diabetic patients as 40–45% of cases,<sup>5-8)</sup> diabetes was present in more than 70% of enrolled cases in this study. Thus, this finding needs to be understood with regard to study population characteristics.

This study has several limitations. First, this was a retrospective, non-randomized study with inherent limitations, such as differences in the baseline characteristics and potential confounding factors. In particular, detailed reasons for operators' decisions to use one or the other type of atherectomy device could not be fully discerned. Even though we tried to minimize confounding factors using PSM, the bias in the selection of the devices cannot be excluded. Second, this study may be underpowered to assess true differences in late clinical outcomes between the two treatment groups. Third, we defined primary patency based on clinical and hemodynamic status supported by available imaging results. Thus, clinical patency might overestimate target lesion patency rates compared to the primary patency based on the imaging modalities only. Fourth, provisional stenting was performed only in 6.1% of the matched DCB group in this study, despite the suboptimal angiographic results with 52.4% postoperative dissection and 36.6% residual stenosis greater than 30%. Due to this conservative stenting strategy, which deviates from those of previous studies, generalization of the clinical results of the DCB in this study appears to be limited.

In conclusion, the pretreatment with atherectomy improved technical success of DCBs; however, it was associated with increased minor complications. Atherectomy showed no clinical benefit in terms of TLR-free survival or primary patency compared with DCB alone.

## SUPPLEMENTARY MATERIAL

### Supplementary Table 1

Clinical outcome between atherectomy plus drug-coated balloon and drug-coated balloon only

[Click here to view](#)

## REFERENCES

1. Ko YG, Ahn CM, Min PK, et al. Baseline characteristics of a retrospective patient cohort in the Korean Vascular Intervention Society Endovascular Therapy in Lower Limb Artery Diseases (K-VIS ELLA) Registry. *Korean Circ J* 2017;47:469-76.  
[PUBMED](#) | [CROSSREF](#)
2. Poulson W, Kamenskiy A, Seas A, Deegan P, Lomneth C, MacTaggart J. Limb flexion-induced axial compression and bending in human femoropopliteal artery segments. *J Vasc Surg* 2018;67:607-13.  
[PUBMED](#) | [CROSSREF](#)
3. Gerhard-Herman MD, Gornik HL, Barrett C, et al. 2016 AHA/ACC guideline on the management of patients with lower extremity peripheral artery disease: executive summary: a report of the American College of Cardiology/American Heart Association Task Force on Clinical Practice Guidelines. *Circulation* 2017;135:e686-725.  
[PUBMED](#) | [CROSSREF](#)
4. Kudagi VS, White CJ. Endovascular stents: a review of their use in peripheral arterial disease. *Am J Cardiovasc Drugs* 2013;13:199-212.  
[PUBMED](#) | [CROSSREF](#)
5. Tepe G, Laird J, Schneider P, et al. Drug-coated balloon versus standard percutaneous transluminal angioplasty for the treatment of superficial femoral and popliteal peripheral artery disease: 12-month results from the IN.PACT SFA randomized trial. *Circulation* 2015;131:495-502.  
[PUBMED](#) | [CROSSREF](#)
6. Rosenfield K, Jaff MR, White CJ, et al. Trial of a paclitaxel-coated balloon for femoropopliteal artery disease. *N Engl J Med* 2015;373:145-53.  
[PUBMED](#) | [CROSSREF](#)
7. Thieme M, Von Bilderling P, Paetzl C, et al. The 24-month results of the Lutonix Global SFA Registry: worldwide experience with Lutonix drug-coated balloon. *JACC Cardiovasc Interv* 2017;10:1682-90.  
[PUBMED](#) | [CROSSREF](#)
8. Micari A, Brodmann M, Keirse K, et al. Drug-coated balloon treatment of femoropopliteal lesions for patients with intermittent claudication and ischemic rest pain: 2-year results from the IN.PACT global study. *JACC Cardiovasc Interv* 2018;11:945-53.  
[PUBMED](#) | [CROSSREF](#)
9. Aboyans V, Ricco JB, Bartelink ME, et al. Editor's Choice - 2017 ESC Guidelines on the Diagnosis and Treatment of Peripheral Arterial Diseases, in collaboration with the European Society for Vascular Surgery (ESVS). *Eur J Vasc Endovasc Surg* 2018;55:305-68.  
[PUBMED](#) | [CROSSREF](#)
10. Scheinert D, Micari A, Brodmann M, et al. Drug-coated balloon treatment for femoropopliteal artery disease. *Circ Cardiovasc Interv* 2018;11:e005654.  
[PUBMED](#) | [CROSSREF](#)
11. Fanelli F, Cannavale A, Gazzetti M, et al. Calcium burden assessment and impact on drug-eluting balloons in peripheral arterial disease. *Cardiovasc Intervent Radiol* 2014;37:898-907.  
[PUBMED](#) | [CROSSREF](#)
12. Katsanos K, Spiliopoulos S, Reppas L, Karnabatidis D. Debulking atherectomy in the peripheral arteries: is there a role and what is the evidence? *Cardiovasc Intervent Radiol* 2017;40:964-77.  
[PUBMED](#) | [CROSSREF](#)

13. Lee YJ, Ko YG, Ahn CM, et al. Outcomes of adjunctive drug-coated versus uncoated balloon after atherectomy in femoropopliteal artery disease. *Ann Vasc Surg* 2020;68:391-9.  
[PUBMED](#) | [CROSSREF](#)
14. Zeller T, Langhoff R, Rocha-Singh KJ, et al. Directional atherectomy followed by a paclitaxel-coated balloon to inhibit restenosis and maintain vessel patency: twelve-month results of the DEFINITIVE AR study. *Circ Cardiovasc Interv* 2017;10:e004848.  
[PUBMED](#) | [CROSSREF](#)
15. Cai Z, Guo L, Qi L, et al. Midterm outcome of directional atherectomy combined with drug-coated balloon angioplasty versus drug-coated balloon angioplasty alone for femoropopliteal arteriosclerosis obliterans. *Ann Vasc Surg* 2020;64:181-7.  
[PUBMED](#) | [CROSSREF](#)
16. Rocha-Singh KJ, Zeller T, Jaff MR. Peripheral arterial calcification: prevalence, mechanism, detection, and clinical implications. *Catheter Cardiovasc Interv* 2014;83:E212-20.  
[PUBMED](#) | [CROSSREF](#)
17. Cioppa A, Stabile E, Popusoi G, et al. Combined treatment of heavy calcified femoro-popliteal lesions using directional atherectomy and a paclitaxel coated balloon: One-year single centre clinical results. *Cardiovasc Revasc Med* 2012;13:219-23.  
[PUBMED](#) | [CROSSREF](#)
18. Zhen Y, Chang Z, Wang C, Liu Z, Zheng J. Directional atherectomy with antirestenotic therapy for femoropopliteal artery disease: a systematic review and meta-analysis. *J Vasc Interv Radiol* 2019;30:1586-92.  
[PUBMED](#) | [CROSSREF](#)
19. Tarricone A, Ali Z, Rajamanickam A, et al. Histopathological evidence of adventitial or medial injury is a strong predictor of restenosis during directional atherectomy for peripheral artery disease. *J Endovasc Ther* 2015;22:712-5.  
[PUBMED](#) | [CROSSREF](#)
20. Stavroulakis K, Schwindt A, Torsello G, et al. Directional atherectomy with antirestenotic therapy vs drug-coated balloon angioplasty alone for isolated popliteal artery lesions. *J Endovasc Ther* 2017;24:181-8.  
[PUBMED](#) | [CROSSREF](#)
21. Stavroulakis K, Schwindt A, Torsello G, et al. Directional atherectomy with antirestenotic therapy vs drug-coated balloon angioplasty alone for common femoral artery atherosclerotic disease. *J Endovasc Ther* 2018;25:92-9.  
[PUBMED](#) | [CROSSREF](#)
22. Krishnan P, Tarricone A, Purushothaman KR, et al. An algorithm for the use of embolic protection during atherectomy for femoral popliteal lesions. *JACC Cardiovasc Interv* 2017;10:403-10.  
[PUBMED](#) | [CROSSREF](#)
23. Wasty N, Khakwani MZ, Kotev S, et al. Ubiquitous nature of distal athero/thromboembolic events during lower extremity atherectomy procedures involving the superficial femoral artery. *Int J Angiol* 2016;25:252-7.  
[PUBMED](#) | [CROSSREF](#)
24. Boitet A, Grassin-Delyle S, Louedec L, et al. An experimental study of paclitaxel embolisation during drug coated balloon angioplasty. *Eur J Vasc Endovasc Surg* 2019;57:578-86.  
[PUBMED](#) | [CROSSREF](#)
25. Scheinert D, Schmidt A, Zeller T, et al. German center subanalysis of the LEVANT 2 global randomized study of the Lutonix drug-coated balloon in the treatment of femoropopliteal occlusive disease. *J Endovasc Ther* 2016;23:409-16.  
[PUBMED](#) | [CROSSREF](#)
26. Kohi MP, Brodmann M, Zeller T, et al. Sex-related differences in the long-term outcomes of patients with femoropopliteal arterial disease treated with the IN.PACT drug-coated balloon in the IN.PACT SFA randomized controlled trial: a post hoc analysis. *J Vasc Interv Radiol* 2020;31:1410-1418.e10.  
[PUBMED](#) | [CROSSREF](#)
27. Roh JW, Ko YG, Ahn CM, et al. Risk factors for restenosis after drug-coated balloon angioplasty for complex femoropopliteal arterial occlusive disease. *Ann Vasc Surg* 2019;55:45-54.  
[PUBMED](#) | [CROSSREF](#)