

Outcomes of macular buckling with a T-shaped buckle for myopic tractional maculopathies associated with posterior staphyloma: An Indian experience

Pradeep Susvar, Niharika Singh, Pramod Bhende, Chetan Rao

Purpose: To report the anatomic and visual outcomes following macular buckling in patients affected by pathological myopia-associated foveoschisis (FS) and macular detachment with or without macular hole (MH). **Methods:** A retrospective interventional consecutive case series wherein 25 highly myopic eyes (mean axial length 28.46 mm; range, 25–33.8 mm) of 24 patients (16 females and 8 males; mean age 54.1 years; range, 35–74 years) presenting with macular detachment associated with a posterior staphyloma (PS), who underwent macular buckling, were evaluated. Patients with absence or reduction in subretinal fluid by more than 90% during the final follow-up along with inversion of contour of staphyloma were considered to have a successful anatomical outcome and those with improvement or maintenance in visual acuity were considered to have a successful functional outcome. The mean duration of follow-up was 11.2 months. **Results:** At the time of initial presentation, the mean age of the 24 patients was 54.1 ± 10.28 years. Macular detachment along with FS was present in all cases, whereas full-thickness macular hole-related retinal detachment was present in nine cases. Swept-source optical coherence tomography parameters showed reduction of FS with foveal reattachment in all eyes except one at last visit. Mean axial length decreased from 28.5 mm preoperatively (range 26–33.8 mm) to 26.2 mm (range 24–29.3 mm). The mean best-corrected visual acuity changed from 1.16 log MAR to 1.096 Log MAR ($P = 0.165$). Visual acuity improved in 10 eyes (40%), remained stable in 11 eyes (44%) and decreased in 4 eyes (16%). **Conclusion:** Macular buckling is a good surgical technique with encouraging anatomic and visual outcomes in patients with myopic macular detachment associated with PS. Highly selective cases of myopic traction maculopathy can have a viable option of macular buckle surgery in stabilizing the retinal tractional changes, and thereby, vision loss.

Key words: Macular buckle, macular detachment, macular hole, myopic foveoschisis, myopic tractional maculopathy, pathological myopia, posterior staphyloma, vitrectomy

Pathological myopia is one of the leading causes of blindness worldwide and is the most frequent cause of visual impairment in Asian countries.^[1] Various changes occur at macula in eyes having pathological myopia. Greater the axial length, the greater the risk of developing a posterior retinal detachment, due to the inability of the retina to adapt to the progressive axial elongation in eyes with high myopia and posterior staphyloma (PS).^[2] Three vector forces acting at the macula, namely, tangential traction on the inner retinal surface, anteroposterior traction of the vitreous, and PS, are the main reasons for tractional maculopathy.^[3] Myopic traction maculopathy (MTMs) having PS represents a common progressive disease characterized by different stages: macular schisis (MS), macular hole (MH) with or without schisis, and MH with macular detachment (MD). The management of these MTM could be with a different surgical approach, as described by various authors: pars plana vitrectomy (PPV), macular buckling (MB), scleral imbrications, and suprachoroidal injections.^[4–6] Since the introduction of PPV and intravitreal gas, RD with MH in highly myopic eyes were mostly treated

by PPV.^[7] Although PPV releases tangential and centripetal tractions caused by the vitreous cortex, it does not address another major risk factor for MTM, namely, stretching within a PS. Reshaping and providing support to the posterior scleral wall can be achieved by various elements to support macular area. MB has the advantage of reducing anteroposterior traction caused by both PS and vitreous cortex. Surgical planning either to perform MB alone or to combine with vitrectomy would be based on clinical findings as well as the optical coherence tomography (OCT) configuration of the macula.

T-shaped wedge implant was originally devised by Bruno Morin and Francois Devin and used in their series of 14 cases of myopic MH with MD and MS with detachment.^[8] Surgery was performed for persistent MD after failed vitrectomy, and as a novel study, the authors introduced this new buckle with their initial experience limited to its usage in failed vitrectomies. Mura *et al.*^[9] studied the cases of myopic MH that underwent

This is an open access journal, and articles are distributed under the terms of the Creative Commons Attribution-NonCommercial-ShareAlike 4.0 License, which allows others to remix, tweak, and build upon the work non-commercially, as long as appropriate credit is given and the new creations are licensed under the identical terms.

For reprints contact: WKHLRPMedknow_reprints@wolterskluwer.com

Cite this article as: Susvar P, Singh N, Bhende P, Rao C. Outcomes of macular buckling with a T-shaped buckle for myopic tractional maculopathies associated with posterior staphyloma: An Indian experience. Indian J Ophthalmol 2022;70:171-9.

Access this article online

Website:

www.ijo.in

DOI:

10.4103/ijo.IJO_3720_20

Quick Response Code:



Shri Bhagwan Mahavir Vitreoretinal Services, Sankara Nethralaya, Chennai, Tamil Nadu, India

Correspondence to: Dr. Pradeep Susvar, Department of Vitreoretina, Shri Bhagwan Mahavir Vitreoretinal Services, Medical Research Foundation, Sankara Nethralaya, Chennai - 600 006, Tamil Nadu, India. E-mail: psusvar@gmail.com

Received: 19-Dec-2020

Revision: 06-Jun-2021

Accepted: 24-Aug-2021

Published: 23-Dec-2021

T-shaped buckle combined with vitrectomy to report successful closure. We noted lacunae in the literature search on the utility of T-shaped buckle in the South Asian population in which the prevalence of myopia-related maculopathy is noted to be high. We report our experience using this T-shaped macular wedge implant in case series of patients having PS-associated MTM with long follow-up. We used this buckle as a de novo primary procedure and also combined with vitrectomy. We addressed some important parameters, which have not been elaborated till date, to look for in selecting an appropriate case for macular buckle surgery. This study aimed to analyze the anatomic and visual outcomes following MB and help to study the structural changes at macula due to the buckle effect on swept-source optical coherence tomography (SSOCT).

Methods

A retrospective chart review was conducted for all patients diagnosed with myopic MD with or without MH between November 2014 and December 2019 at a single tertiary eye care center. Inclusion criteria for this study were high myopia defined as a refractive error of ≥ 6 D or higher or an axial length greater than 26 mm, myopic macular schisis-associated MD with or without inner MH, progressive visual loss (or loss of reading ability) or progressive metamorphopsia (once other possible causes had been excluded), and minimum postoperative follow-up of 2 months. The study was approved by the institutional review board and adhered to the tenets of the Declaration of Helsinki. An approval from the ethics committee was obtained.

Data collected from charts included gender, age at presentation, prior ocular surgery, medical history, and clinical presentation in each eye. Best-corrected visual acuity (BCVA) was recorded and Snellen's acuity was converted to log MAR for statistical analysis. Visual acuities (VAs) recorded as hand motions, light perception only present, and no light perception were converted to the values of 2.7, 2.8, and 2.9, respectively, as reported previously.^[10] Near vision, preoperative and postoperative axial lengths, anterior segment bio-microscopy, dilated fundus examination, intraocular pressure, color fundus photo, SSOCT (Deep Range Imaging, OCT-1, Atlantis, Topcon, Tokyo, Japan), and postoperative complications were noted. Staphyloma type was characterized, differentiated clinically, and corroborated by fundus photomontage as per the Curtin's classification.^[11] Staphyloma was graded from real-time B-scan as mild (1–2 mm), moderate (2–4 mm), severe (4–6 mm), and very severe (>6 mm).^[12]

Surgical technique

A 360° Conjunctival peritomy was followed by tagging four recti muscles and identification of both oblique muscles. Tenon's space was liberally exposed and inspected. The solid silicone macular plate (Morin wedge) was threaded onto the 2-mm solid silicone band (Devin band) [Fig. 1]. The Devin band is traversed under lateral rectus (temporal), inferior oblique, inferior rectus, superior rectus, and superior oblique muscle. Both ends of the Devin band are positioned on the nasal side of the eyeball on upper and lower sides of medial rectus. A macular wedge was placed under the lateral rectus horizontally. The macular plate was slowly maneuvered (holding the anterior end of the same) along the contour of the globe under the lateral rectus moving toward




Figure 1: Three-dimensional reconstruction of a right eye and a T-shaped macular buckle

the posterior pole. Using a wide-angle viewing system under the operating microscope with 25G chandelier placed in pars plana, the position of the macular plate reaching macula was assessed and titrated to check the height of the buckle and to avoid abutting the optic nerve by the plate. The optic nerve and retina were carefully examined to ensure perfusion. With the optimum positioning at macula, the anterior end of the macular plate was also trimmed and sutured underneath the lateral rectus muscle and both ends of the 2-mm band were trimmed and sutured to the sclera in their respective locations nasally using 5-0 polyester sutures, not connecting to each other. Conjunctiva was pulled over the globe with the Tenon's capsule and sutured meticulously [Fig. 2].

Combined procedures for vitrectomy continued after the placement of the macular buckle with the 23 G infusion (ITQ) and upper sclerotomies. Complete vitrectomy with posterior vitreous detachment (PVD) induction, staining followed by internal limiting membrane (ILM) peeling, and fluid gas exchange was done. Buckle indentation was optimized after the fluid gas exchange and buckle sutures were finalized followed by silicone oil injection and conjunctival closure.

SSOCT imaging

A trained optometrist captured 6-mm radial scans using a light source of 1050 nm. Qualitative details of retina and features of staphyloma were studied. Maximum height of retinal schisis and subretinal fluid (SRF) within the scan were calculated manually by the built-in mapping software. "Absence or reduction in SRF by more than 90% during final follow-up along with inversion of contour of staphyloma" was considered to have a successful anatomical outcome. Those with "improvement or maintenance in visual acuity" were considered to have a successful functional outcome.

All statistical analyses were based on eyes as the unit for ocular factors and patient as a unit for systemic factors. Statistical analysis was performed using a *t*-test for mean VAs, Fisher's exact test for categorical data, and a one-way

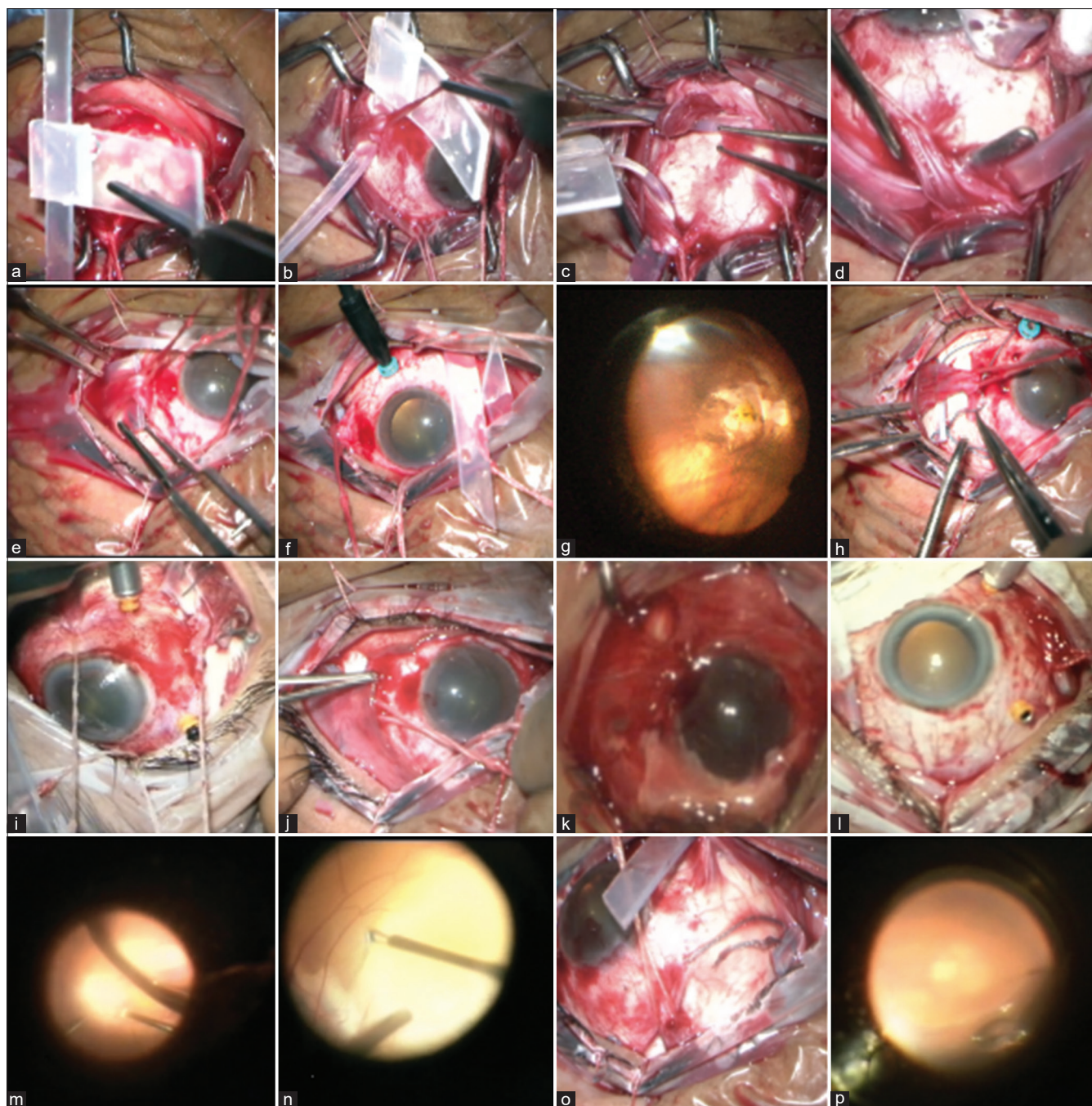


Figure 2: Surgical procedure. (a) Threading of Morin band into Devin's wedge. (b) Passing the band under the lateral rectus. (c) Passing one end of band under inferior rectus and inferior oblique muscle. (d) Tagging the superior rectus and oblique muscle together and passing the other of band underneath it. (e) The flatter end of wedge is adjusted under lateral rectus with wedge toward the macula. (f) Insertion of 25G chandelier light. (g) Adjusting the macular indentation under direct visualization. (h) Finalizing the suture of plate end under lateral rectus on either side. (i) The nasal end of bands are marked on sclera after adjusting the indentation and sutured and the free edges trimmed. (j) Conjunctiva is liberally mobilized. (k) Suturing of conjunctiva and tendons in two layers carefully. Combined cases with vitrectomy the Morin–Devin wedge is passed in similar manner followed by (l) 25G sclerotomies made 3.5 mm from limbus. (m) Vitrectomy is done with posterior vitreous detachment and followed by fluid gas exchange. (n) ILM peeling using forceps. Followed by adjustment of buckle under air and (o) finalizing the sutures of MB. (p) Silicone oil infusion and buckle indent appreciated at posterior pole

analysis of variance (ANOVA) for visual outcomes among surgical management options. Statistical analysis was performed using Stata 14 statistical software (StataCorp) and a *P* value of less than 0.05 was considered to be statistically significant.

Results

A total of 25 eyes of 24 patients diagnosed with MTM were evaluated between November 2014 and December 2019 [Table 1]. At the time of initial presentation, the mean age of the 24 patients

was 54.1 ± 10.28 years (median, 53 years; range, 35–74 years) and 16 (66.6%) were females. Of them, 13 patients had right eye involvement. One patient had bilateral involvement wherein both eyes underwent surgical management. Three patients had a history of vitreoretinal surgeries, two of which were oil filled at presentation.

Mean preoperative BCVA was log MAR 1.16 ± 0.53 . The average refractive error noted was -7.4 D (range -1.5 D to -24 D). The mean axial length was 28.5 mm (range 26–33.8 mm). Preoperative fundus findings of both the eyes of all the cases were noted. Type 1 PS was noted in 12 cases, 8 had type 2, and 5 had type 9. Staphyloma grading was noted and it was mild in 11, moderate in 9, severe in 3, and could not be measured in 2 cases (silicone oil-filled eyes).

Diagnosis was made on clinical and OCT findings as follows: foveoschisis (FS) and MD was present in all cases. Full-thickness macular hole-related retinal detachment (MHRD) was present in 9 cases and only MD was present in the remaining 16 cases.

Anatomical outcomes

Intraoperative and postoperative parameters were recorded. Reduction in FS was noted in all the cases [Fig. 3]. As a primary procedure, MB alone was conducted in 20 (80%) eyes and MB with PPV was performed in 5 (20%) eyes. Out of the 20 eyes that underwent macular buckle alone as primary procedure, 9 eyes had more than 90% and 7 eyes had more than 70%

reduction in SRF at the final visit. Of the four eyes that had persistent or increased SRF ($n = 1$), one underwent silicone oil injection, but macular attachment was not achieved at last visit. Remaining eyes were observed. Mean axial length decreased from 28.5 mm preoperatively (range 26–33.8 mm) to 26.2 mm (range 24–29.3 mm).

Five eyes underwent MB with PPV and oil tamponade, of which four eyes had flat macula at 6 weeks and last visit. One eye had recurrent MD, which subsequently underwent repeat surgery with oil injection and had macular attachment at last visit.

Patients were followed up postoperatively for a mean duration of 12.9 ± 16.1 months, with a range of 2 months to 5 years with five cases followed for more than 3 years. Of five eyes in which silicone oil was used as endo tamponade, silicone oil removal (SOR) was performed in four cases. It was deferred in one case due to hypotony. Of the four cases, one case required repeat oil injection.

Functional outcomes

The preoperative and postoperative VAs were compared in all the cases. Table 2 shows the VAs at presentation and final visit. Of the total eyes, in 10, 11, and 4 eyes, the VA improved, stabilized, and deteriorated, respectively. In the 10 eyes (40%) with visual improvement, the improvement was significant with a mean change of 0.390 units of log MAR ($P < 0.005$). However, in four eyes despite surgical intervention, there was

Table 1: Demographic, clinical characteristics, and details of surgical procedure

No.	Age	Eye	VA pre-op	Preoperative axial length	Surgery	VA final at last visit	Axial length at last visit	Follow-up (months)	Complication
1	52	OS	1.30	Oil filled	MB	1.3	Oil filled	54	Nil
2	64	OS	1.50	26	MB	1.3	25	2	Subretinal hemorrhage
3	59	OD	1.70	26	MB+V+SOI	1.5	24	24	Nil
4	50	OD	2.30	26	MB+V+SOI	1.3	27	48	Nil
5	59	OS	1.00	26.1	MB	1	28.2	14	Nil
6	67	OD	1.50	30	MB+V+SOI	1.5	Oil filled	6	Nil
7	35	OD	1.00	26.2	MB	0.8	25.1	2	Nil
8	48	OS	0.80	28.8	MB	0.9	24.2	2	Choroidal detachment
9	47	OD	1.00	27.7	MB	0.6	24.5	6	Nil
10	43	OD	1.30	29.8	MB	1	27	2	Subretinal hemorrhage
11	48	OS	1.50	26	MB	1.7	25.7	6	Subretinal hemorrhage
12	39	OS	1.70	28.9	MB+V+SOI	1	Oil filled	36	Nil
13	37	OD	1.30	26.5	MB	1.3	24	2	Nil
14	68	OD	0.80	29.9	MB+V+SOI	1.3	29	36	nil
15	65	OS	0.60	27.9	MB	0.5	24.9	2	Nil
16	61	OS	1.40	27.4	MB	1.4	24	2	Nil
17	57	OD	1.30	28	MB	1.3	25	3	Nil
18	50	OD	0.50	30.70	MB	0.50	28	2	Nil
19	54	OS	0.20	27.7	MB	0.2	25.5	2	Nil
20	50	OD	0.50	33.5	MB	2	26	8	Choroidal detachment
21	57	OD	1.00	30	MB	0.8	29.2	30	Angle closure glaucoma
22	66	OD	2.30	Oil filled	MB	2.3	Oil filled	2	nil
23	74	OS	1.30	27.3	MB	0.7	26	3	nil
24	50	OD	0.50	33.8	MB	0.5	29.3	2	nil
25	57	OS	0.70	31.4	MB	0.7	27.8	24	Angle closure glaucoma

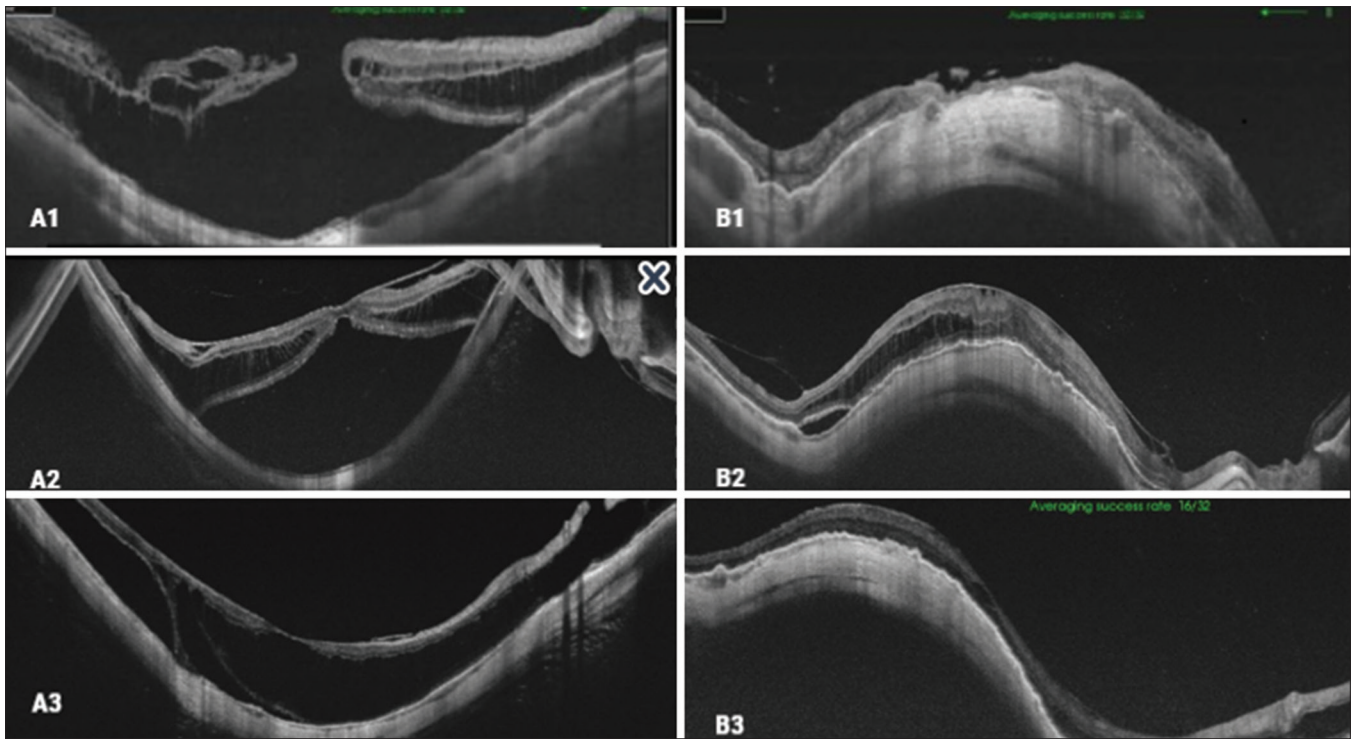


Figure 3: Preoperative (A1, A2, A3) and postoperative OCT (B1, B2, B3). Case 1: Patient having MHRD, after MB. There is closure of hole with good indentation at macular region. Case 2: Patient with isolated macular detachment after surgery. There was good indentation at macula but residual fluid surrounding it, which subsequently absorbed. Case 3: Patient having retinoschisis with foveal retinal detachment after surgery. There was resolution of schisis with retinal reattachment

Table 2: Comparison of preoperative and postoperative best-corrected visual acuity outcomes

	VA. Status	VA. Preop	VA. Postop	Difference	P
Improved	Mean	1.340	0.950	0.390	0.005
	n	10	10	10	
	Std. deviation	0.484	0.331	0.288	
Stable	Mean	1.091	1.091	0.000	0.991
	n	11	11	11	
	Std. deviation	0.592	0.592	0.000	
Worsened	Mean	0.900	1.475	-0.575	0.068
	n	4	4	4	
	Std. deviation	0.424	0.479	0.640	
Total	Mean	1.160	1.096	0.064	0.165
	n	25	25	25	
	Std. deviation	0.532	0.499	0.443	

a significant drop in VA with a mean change of -0.6 units of log MAR units ($P = 0.01$).

Prognostic factors

On analyzing the factors that affect the anatomical outcome, as shown in Table 3 by univariate analysis, we found that fair BCVA, staphyloma type 2, combined macular buckle with vitrectomy, and absence of full-thickness macular hole (FTMH) were associated with favorable anatomical outcome, though the number did not reach statistical significance. Factors related with favorable functional outcome (21 eyes), as

mentioned in Table 4, were shorter axial length and mild grade of staphyloma.

Some operative complications were noted in our series. Of them, one was subretinal discrete hemorrhages at the borders of staphyloma due to maneuvering of the buckle element, noted in three cases. All had spontaneous resolution over 1–2 weeks with no adversities. Other operative complications were hemorrhagic choroidal detachment in two cases of macular buckle alone, one occurred intraoperatively and was managed conservatively with oral steroids and one case, noted on the first postoperative day, needed choroidal drainage with vitrectomy, which eventually had attached retina but retinal pigment epithelium atrophy and poor functional outcome. One patient who had bilateral macular buckle done and was phakic at the time of surgery had peculiar angle shallowing with secondary angle-closure glaucoma in immediate postoperative period in both eyes, which was managed subsequently with topical and oral medications [Table 1].

Discussion

Retinal complications related to high myopia, such as FS and MD, are related to several factors. Myopic FS may remain stable and asymptomatic for years. Surgery is recommended when there is a proven visual loss. Several studies have proven the benefits of vitrectomy for the resolution of FS by removing vitreoretinal traction.^[13] Benhamou *et al.*^[14] performed vitrectomy in eyes with FS and vitreoretinal traction without achieving visual gain or retinal thickness decrease, which leads us to think that other factors may also play an important role. Various episcleral implants are described in the literature

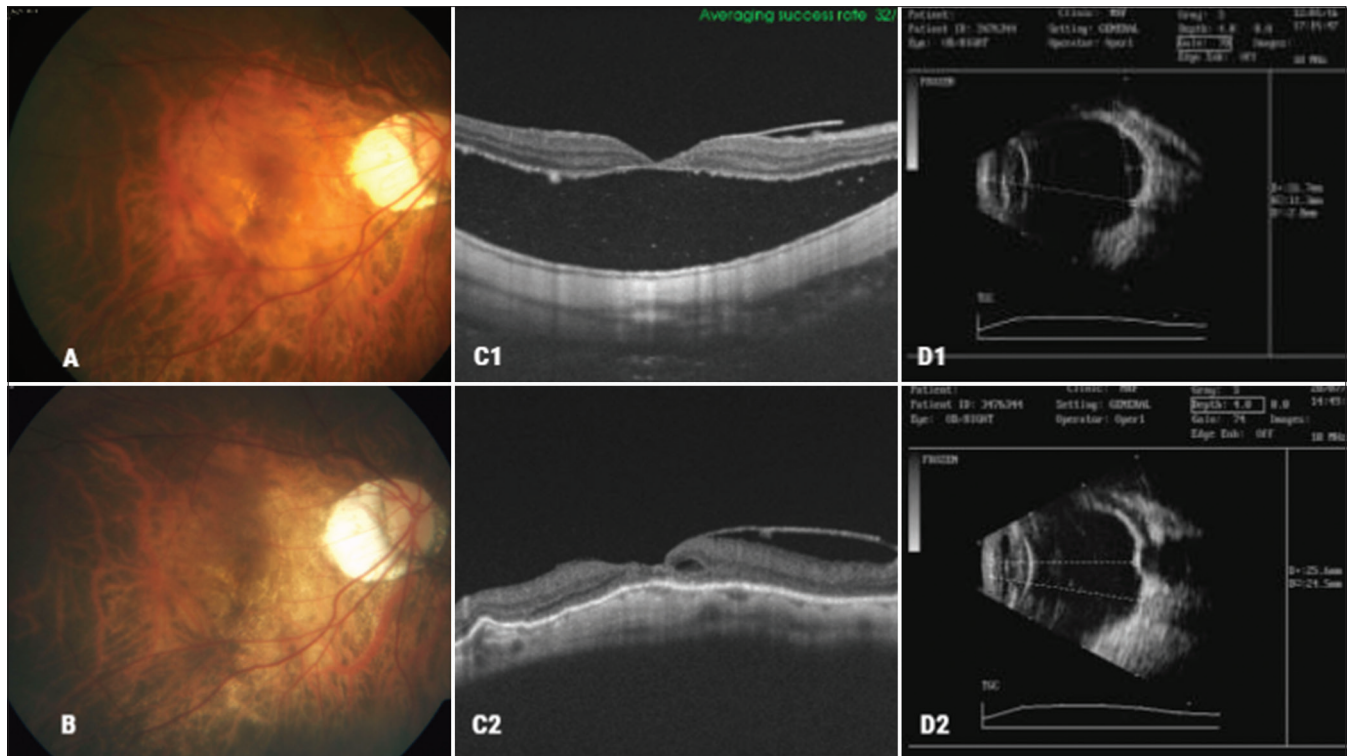


Figure 4: (A) Preoperative fundus photograph with macular retinal detachment (MRD). (B) 24 months postoperative fundus photograph with retina reattachment. (C) Preoperative (C1) and 24 months postoperative (C2) optical coherence tomography examination. (D) Preoperative (D1) and 24 months postoperative (D2) ultrasonography image showing buckle indent and shortening of axial length

Table 3: Potential factors affecting anatomical outcome

Factors	Anatomical success		
	Favorable (n=14)	Unfavorable (n=11)	P:t-test
Age	52.36±10.04	56.7±10.6	0.341
Duration of symptoms (weeks)	20.14±40.1	16.86±18.53	0.536
VR surgery-absent	13 (92.86%)	9 (81.82%)	0.42
VR surgery-present	1 (7.14%)	2 (18.18%)	
Initial BCVA	1.1±0.59	1.24±0.47	0.609
Final BCVA	1.07±0.51	1.13±0.51	0.979
Axial length	28.6±2.32	28.24±2.63	0.688
Staphyloma type - 1	6 (42.86%)	6 (54.55%)	0.393
Staphyloma type -2	6 (42.86%)	2 (18.18%)	
Staphyloma-9	2 (14.29%)	3 (27.27%)	
Staphyloma grade 1	7 (50%)	4 (36.36%)	0.495
Staphyloma grade >1	7 (50%)	7 (63.64%)	
Only PMB	9 (64.29%)	11 (100%)	0.027
PMB+Vit	5 (35.71%)	0 (0%)	
SRF. Preop	1209.21±1487.86	992.18±563.02	0.893
Change in SRF	1207±1488.72	399.18±717.18	0.134
Preoperative height of retinoschitic cavity	410.86±338.88	296.09±159.92	0.647
Change in retinoschitic height	357.21±356.97	134.36±164.09	0.058
FTMH-No	14 (61.9%)	2 (50%)	0.656
FTMH-Yes	7 (38.1%)	2 (50%)	
LMH-No	13 (61.9%)	2 (50%)	0.656
LMH-Yes	8 (38.1%)	2 (50%)	

Table 4: Potential factors affecting functional outcome

Factors	Functional success		
	Favorable (n=21)	Unfavorable (n=4)	P:t-test
Age	54.3±10.63	53.5±9.71	0.737
Duration of symptoms (weeks)	13.79±15.02	44.5±74.66	0.915
Previous VR surgery			
Absent	18 (85.71%)	4 (100%)	0.42
Present	3 (14.29%)	0 (0%)	
Initial BCVA	1.21±0.54	0.9±0.42	0.331
Final BCVA	1.02±0.48	1.48±0.48	0.113
Axial length	28.22±2.25	29.6±3.09	0.456
Staphyloma type 1	10 (47.62%)	2 (50%)	0.934
Staphyloma type 2	7 (33.33%)	1 (25%)	
Staphyloma 9	4 (19.05%)	1 (25%)	
Staphyloma grade-1	10 (47.62%)	1 (25%)	0.404
Staphyloma grade >1	11 (52.38%)	3 (75%)	
Only PMB	17 (80.95%)	3 (75%)	0.785
PMB+Vit	4 (19.05%)	1 (25%)	
Preoperative height of SRF	1189.67±1224.8	715±702.11	0.452
Change in SRF	877.57±1349.21	715±702.11	0.858
Preoperative height of retinoschitic cavity	364.29±300.32	339.75±89.38	0.971
Change in retinoschitic height	261.48±332.57	247±79.39	0.642
FTMH-No	14 (61.9%)	2 (50%)	0.656
FTMH-Yes	7 (38.1%)	2 (50%)	
LMH-No	13 (61.9%)	2 (50%)	0.656
LMH-Yes	8 (38.1%)	2 (50%)	

with good anatomical and visual success.^[15-17] These implants may be of Silastic rods, Ando plombe, L-shaped buckle, adjustable buckles, AJL buckle, and wire-strengthened sponge implant.^[15-21] Each of these is being used to serve the same purpose of macular support and each one has its inherent merits and demerits.^[21] T-shaped Morin–Devin solid silicone implants have been used elsewhere and noted to have certain advantages over the other macular buckles. Its flexible design provides better maneuverability and better indentation judgment and does not require any muscle disinsertion or passing sutures near fovea.^[6] We have used this implant in our case series and found it to be safe in our follow-up of 5 years. The solid plate gives an adequate indentation at the macula with no slippage, and the second transverse band secures the buckle more compactly to the globe contour. Indentation could be titrated better by maneuvering the bands, avoiding too high buckle effect.

Comparing the demographical features, most of our patients were females, similar to other studies, although the mean age was younger compared to studies from Western countries.^[22] Our anatomical success rates in terms of MH closure (7/9) was comparable to similar studies.^[17,19,21,22] We also calculated reduction in SRF and quantified the same. Reduction of SRF by more than 90%, which was criteria for anatomical success in our series, was seen in 14 eyes (56%). Seven eyes (28%) had about 70% reduction in SRF with maintenance of vision. Of four eyes that had anatomical failure, one eye was silicone-filled with a history of pars plana surgeries having a belt buckle. Macular attachment was achieved after MB but detachment occurred after

SOR. Other three cases had paramacular indent with persistent SRF. The possibility of adjusting the tension at the macula with direct visualization by pulling the free extremity of the buckle allows a more reshaping of the PS [Fig. 4]. Nevertheless, slight misalignment still could relieve anteroposterior traction and help in reduction of SRF. Distant BCVA was a functional outcome although the final visual function was not always indicative of surgical success as wide zones of myopic macular atrophy often precluded the visual gain. Still, a clinically significant visual gain was noticed both in the combined group and in the buckle group for each form of MTM. Twenty-one (84%) patients had functional success in terms of improvement/maintenance of vision. Four patients had deterioration of vision owing to surgical failure and anatomical distortion.

Univariate analysis showed some parameters (mentioned in results) related to better anatomical and functional outcomes, but they were not statistically significant. This point may give an insight for surgeon to choose cases appropriately.

Of the complications and their management enumerated in the results, subretinal discrete hemorrhages at the staphyloma border were innocuous and had spontaneous resolution in 1-2 weeks. Secondary angle-closure glaucoma in one patient (2 eyes) was also managed by medical management. This could be possibly due to the sudden indentation induced compression of vitreous volume or rotation of ciliary ring due to inflammation, which necessitates watchful post-operative recognition. Threatening complication like hemorrhagic CDs (2 cases) were managed conservatively with oral steroids. One case, noted on

the first postoperative day, needed choroidal drainage with vitrectomy, which eventually had attached retina but retinal pigment epithelium atrophy and poor functional outcome. We do consider hemorrhagic CDs as an intraoperative complication noted while operating pathological myopia eyes. One must keep in mind and explain this potential but rare threat to the patients in preoperative counseling.

Case selection for macular buckle

Our study also analyzed the parameters that could help in appropriate choice of surgery for MTMs. Cases were selected for surgery only if there was recent progression of visual symptoms or changes were noted on OCT scans, more specific at the foveal area. Worsening near-vision symptoms, progressive schisis, recent onset neurosensory detachment, recent MH formation, and/or progression of MD documented on serial OCT were important parameters considered to benefit from surgery. A detailed PS evaluation would be necessary to decide to go for either conventional vitrectomy technique or MB. Cases of MTM having mild staphyloma (<2 mm on measurement on B-scan) and a shallow contour noted on clinical examination or fundus photograph were still managed by vitrectomy and ILM peeling techniques to address the pathology, be it an MH or MD. MTMs having moderate-to-severe staphylomas (>2 mm on B-scan) and Curtin's types 1, 2, and 9 PSs having a deep contour on clinical examination were addressed by MB technique.

We also took into account the profoundness of refractive error, amblyopia component of either eye, prior refractive surgeries, status of the lens, and any associated glaucoma to decide for the appropriate case selection for surgery. We noted these factors are equally important apart from OCT findings alone, for deciding MB surgery. We believe they are important because a moderate-to-gross hypermetropic shift is likely to occur, especially in post Lasik and pseudophakic eyes. Future cataract surgery and so the intraocular lens (IOL) determination will be a challenge again, with other eye having a high myopia and a clear lens. Baseline Digital biometric Record as a routine preoperative tool would be a better guide to compare post buckle calculations on repeat biometry toward accurate IOL power. Proper presurgery counselling to patients is required, regarding issues pertaining to these abovementioned refractive changes after MB.

Gross thinning of retinal layers at the macula, shortening of the retina in relation to the staphyloma contour both clinically and on OCT scans, and only MD without MH were the cases in which macular buckle alone was planned. Posterior pole detachment with FTMH having an internal tout and shortened ILM surface and a large and deep staphyloma (assessed clinically as well as by OCT and B scan) and normal thickness retina were preferably managed with MB + vitrectomy.

We looked into the factor of "bias in our case selection" for MB alone or combined surgery, which could have affected anatomical and visual outcomes of the surgery. We observed that reshaping staphyloma was achieved in all except two cases. These two were the initial cases of the surgeon, attributable to slope of the learning curve and possible lesser indentation. The primary purpose of buckle placement to change the contour of posterior globe thereby proximate retina toward choroid scleral surface was achieved in most of the cases in this case series. We did not note decrease or increase in the indentation effect over time in our longest follow-up cases (5 years).

Additional investigation in this regard is the use of preoperative magnetic resonance imaging to assess the exact shape and grade of staphyloma^[20,23] and development of OCT-assisted surgery. Intraoperative real-time OCT (iOCT) may improve identification and removal of premacular tractions during PPV and facilitate placement of MB under the macular region in terms of height and position.^[21]

Our study limitation was of retrospective case series. Decision to go for buckle-alone versus combined with vitrectomy was biased based on clinical profile and not randomized. This bias would make it difficult to opine the superiority of one procedure over the other. Also we did not have long enough follow-up for this very complex surgery in a very difficult disease in all patients. Studying the detail of the changes at choroidal layers was one of the unmet needs in our series which would give an insight to the buckle effect on the choroidal thickness.

Conclusion

Analyzing the utility of the T-shaped buckle in MTM cases for the first time in Asian eyes, our study on Indian population with large series of 25 cases has shown encouraging anatomical and functional results. Factors to look into case selection to decide for type of surgery are clarified in our study, to ease surgeon for appropriate case selection. The study had a reasonably good follow-up (5 years) with no significant complications and functional deterioration. Given the favorable results, this can be a viable surgical approach to consider in both new and recurrent detachment cases of MTM.

Acknowledgments

The authors thank Dr. Van J Meurs, Director, VR Services, The Rotterdam Eye Hospital, Rotterdam, the Netherlands for inspiring and supporting this study.

Financial support and sponsorship

Nil.

Conflicts of interest

There are no conflicts of interest.

References

- Liu HH, Xu L, Wang XR, Wand S, You QS, Jonas JB. Prevalence and progression of myopic retinopathy in Chinese adults: The Beijing Eye Study. *Ophthalmology* 2010;117:1763–8.
- Takano M, Kishi S. Foveal retinoschisis and retinal detachment in severely myopic eyes with posterior staphyloma. *Am J Ophthalmol* 1999;128:472–6.
- Kanda S, Uemura A, Sakamoto Y, Kita H. Vitrectomy with internal limiting membrane peeling for macular retinoschisis and retinal detachment without macular hole in highly myopic eyes. *Am J Ophthalmol* 2003;136:177–80.
- Schepens CL, Okamura ID, Brockhurst RJ. The scleral buckling procedures. I. Surgical techniques and management. *AMA Arch Ophthalmol* 1957;58:797–811.
- Nakagawa N, Parel JM, Murray TG, Oshima K. Effect of scleral shortening on axial length. *Arch Ophthalmol* 2000;118:965–8.
- Poole TA, Sudarsky D. Suprachoroidal implantation for treatment of retinal detachment. *Ophthalmology* 1986;93:1408–12.
- Aaberg TM, Blair CJ, Gass JD. Macular holes. *Am J Ophthalmol* 1970;69:555–62.
- Devin F, Tsui I, Morin B, Duprat JP, Hubschman JP. T-shaped scleral buckle for macular detachments in high myopes. *Retina* 2011;31:177–80.
- Mura M, Lannetta D, Buschini E, de Smet MD. T-shaped macular buckling combined with 25G pars plana vitrectomy for macular

- hole, macular schisis, and macular detachment in highly myopic eyes. *Br J Ophthalmol* 2017;101:383–8.
10. Schulze-Bonsel K, Feltgen N, Burau H, Hansen L, Bach M. Visual acuities “hand motion” and “counting fingers” can be quantified with the Freiburg visual acuity test. *Invest Ophthalmol Vis Sci* 2006;47:1236–40.
 11. Curtin BJ. The posterior staphyloma of pathologic myopia. *Trans Am Ophthalmol Soc* 1977;75:67–86.
 12. Steidl SM, Pruett RC. Macular complications associated with posterior staphyloma. *Am J Ophthalmol* 1997;123:181–7.
 13. Ikuno Y, Sayanagi K, Soga K, Oshima Y, Ohji M, Tano Y. Foveal anatomical status and surgical results in vitrectomy for myopic foveoschisis. *Jpn J Ophthalmol* 2008;52:269–76.
 14. Benhamou N, Massin P, Haouchine B, Erginay A, Gaudric A. Macular retinoschisis in highly myopic eyes. *Am J Ophthalmol* 2002;133:794–800.
 15. Ando F, Ohba N, Touura K, Hirose H. Anatomical and visual outcomes after episcleral macular buckling compared with those after pars plana vitrectomy for retinal detachment caused by macular hole in highly myopic eyes. *Retina* 2007;27:37–44.
 16. Parolini B, Frisina R, Pinackatt S, Gasparotti R, Gatti E, Baldi A, *et al.* Indications and results of a new I-shaped macular buckle to support a posterior staphyloma in high myopia. *Retina* 2015;35:2469–82.
 17. Cacciamani A, Lazzeri S, Rossi T, Scarinci F, Parravano M, Ripandelli G, *et al.* Adjustable macular buckling for full-thickness macular hole with foveoschisis in highly myopic eyes: Long-term anatomical and functional results. *Retina* 2016;36:709–16.
 18. Zhu Z, Xueying J, Zhang J, Ke G. Posterior scleral reinforcement in the treatment of macular retinoschisis in highly myopic patients. *Clin Exp Ophthalmol* 2009;37:660–3.
 19. Mortada HA. A novel episcleral macular buckling: Wire-strengthened sponge explant for recurrent macular hole and retinal detachment in high myopic eyes. *Med Hypothesis Discov Innov Ophthalmol* 2013;2:14–9.
 20. Susvar P, Sood G. Current concepts of macular buckle in myopic traction maculopathy. *Indian J Ophthalmol* 2018;66:1772–84.
 21. Alkabes M, Mateo C. Macular buckle technique in myopic traction maculopathy: A 16-year review of the literature and a comparison with vitreous surgery. *Graefes Arch Clin Exp Ophthalmol* 2018;256:863–77.
 22. Perez RN, Phelps CD, Burton TC. Angle-closure glaucoma following scleral buckling operations. *Trans Sect Ophthalmol Am Acad Ophthalmol Otolaryngol* 1976;81:247–52.
 23. Ohno-Matsui K. Proposed classification of posterior staphylomas based on analyses of eye shape by three-dimensional magnetic resonance imaging and wide-field fundus imaging. *Ophthalmology* 2014;121:1798–809.