

# Coronary aspiration thrombectomy after using intravenous recombinant tissue plasminogen activator in a patient with acute ischemic stroke: a case report

Journal of International Medical Research

2019, Vol. 47(9) 4551–4556

© The Author(s) 2019

Article reuse guidelines:

[sagepub.com/journals-permissions](http://sagepub.com/journals-permissions)

DOI: 10.1177/0300060519865626

[journals.sagepub.com/home/imr](http://journals.sagepub.com/home/imr)



Ton Mai Duy<sup>1</sup>, Phuong DaoViet<sup>1</sup>,  
Dung Nguyen Tien<sup>1</sup>, Quang-Anh Nguyen<sup>2,3</sup>,  
Thien Nguyen Tat<sup>2</sup>, Viet Anh Hoang<sup>4</sup>,  
Trung Le Hong<sup>5</sup>, Huy Nguyen Van<sup>5</sup>,  
Dat Anh Nguyen<sup>1</sup>, Chi Nguyen Van<sup>1</sup>,  
Nguyen Vu Thai Lien<sup>6</sup>, Vu Thi Nga<sup>7,\*</sup> and  
Dinh-Toi Chu<sup>8,\*</sup> 

## Abstract

The complication of myocardial infarction after using intravenous recombinant tissue plasminogen activator (rt-PA) in patients with acute ischemic stroke is rare. Several of these cases have been reported in the first 3 hours after infusion of rt-PA. There is controversy on how to manage treatment of the coronary artery, such as intravenous anticoagulants and antiplatelets, at the same time. We introduce a new strategy for treatment of a patient who had ischemic stroke and developed myocardial infarction after intravenous rt-PA therapy. Our case had coronary and cerebral intervention in combination with low-dose intravenous rt-PA. He was successfully treated for coronary occlusion with aspiration thrombectomy.

<sup>1</sup>Emergency Department, Bach Mai Hospital, Hanoi, Vietnam

<sup>2</sup>Radiology Center, Bach Mai Hospital, Hanoi, Vietnam

<sup>3</sup>Faculty of Radiology, Hanoi Medical University, Hanoi, Vietnam

<sup>4</sup>Vietnam National Heart Institute, Bach Mai Hospital, Hanoi, Vietnam

<sup>5</sup>Vinh Phuc General Hospital, Vinh Phuc, Vietnam

<sup>6</sup>School of Odonto Stomatology, Hanoi Medical University, Hanoi, Vietnam

<sup>7</sup>Institute for Research and Development, Duy Tan University, Danang, Vietnam

<sup>8</sup>Faculty of Biology, Hanoi National University of Education, Hanoi, Vietnam

\*These authors contributed equally to this work.

## Corresponding author:

Dinh Toi Chu, Faculty of Biology, Hanoi National University of Education, Hanoi, Vietnam.

Emails: [chudinhtoi.hnue@gmail.com](mailto:chudinhtoi.hnue@gmail.com); [dinhhtc@ncmm.uio.no](mailto:dinhhtc@ncmm.uio.no)



**Keywords**

Myocardial infarction, acute ischemic stroke, aspiration thrombectomy, recombinant tissue plasminogen activator, thrombus, coronary artery

Date received: 20 March 2019; accepted: 3 July 2019

**Introduction**

Myocardial infarction rarely occurs after using intravenous (IV) recombinant tissue plasminogen activator (rt-PA) in the case of an acute ischemic stroke (AIS). Some mechanisms have been proposed to explain this situation as follows: (1) previous thrombi located inside the cardiac chamber are shattered because of IV rt-PA use; (2) activated platelet adhesion results in cardiac thrombus; and (3) a reduction in plasminogen leads to abnormal hypercoagulability in the coronary arteries.<sup>1</sup> Another frequent mechanism of myocardial infarction after IV rt-PA is atrial fibrillation. Atrial fibrillation causes vascular accidents, including cerebral, coronary, and peripheral vessels, especially in the case of previous stenosis. Some examinations should be performed for further diagnosis in this situation, including cardiac ultrasound, aortic multi-slice computed tomography (CT), and other tests of anticoagulants.

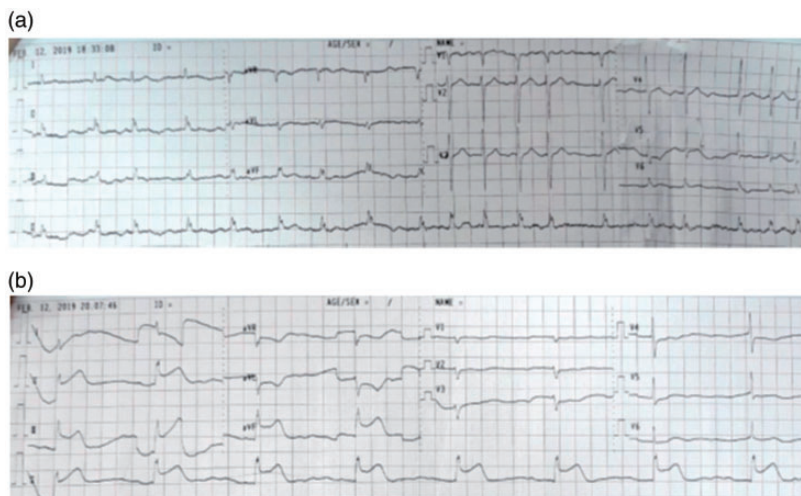
In some previously published case series, myocardial complications normally led to mortality and immediately occurred after IV rt-PA not only in patients with AIS, but also in patients who were treated with an anticoagulant, antiplatelets, or subcutaneous coronary intervention.<sup>2</sup> Among patients who used antiplatelet and/or anticoagulant therapy for cardiac stent intervention, the patients still survived.

In this report, we introduce a new strategy for treatment of a patient who had myocardial infarction and ischemic stroke after using IV rt-PA. He was successfully treated

for coronary occlusion with aspiration thrombectomy. This choice had more advantages compared with stent deployment in that it helped to reduce the risk of hemorrhage after rt-PA. Only 20 mg of Lovenox (enoxaparin sodium) was used for post-intervention. After 24 hours, we evaluated brain lesions and performed preventative treatment level II for the myocardial infarction and ischemic stroke by following recent recommendations and guidelines.

**Case report**

A 79-year-old male patient with a medical history of hypertension for 10 years without frequent control was admitted to our hospital at 18:20 hours on 12 February 2019. His initial symptoms, right hemiplegia, slurred speech and facial droop, had appeared at 17:50 hours. A clinical examination showed the following findings: (1) the Glasgow coma score was 14, (2) there was right hemiplegia in the hand of 1/5 and in the leg of 2/5 (muscle strength), (3) there was dysarthria, (4) the baseline National Institute of Health Stroke Scale score was 16, (5) blood pressure was 170/90 mmHg, (6) heart rate was 80 beats/minute, and (7) there was atrial fibrillation (Figure 1a). After undergoing a non-contrast CT scan and CT angiography (Figure 2a, b), neither signs of acute ischemic stroke nor hemorrhage were found without evidence of large vessel occlusion. Therefore, there was no contraindication of IV rt-PA uses.

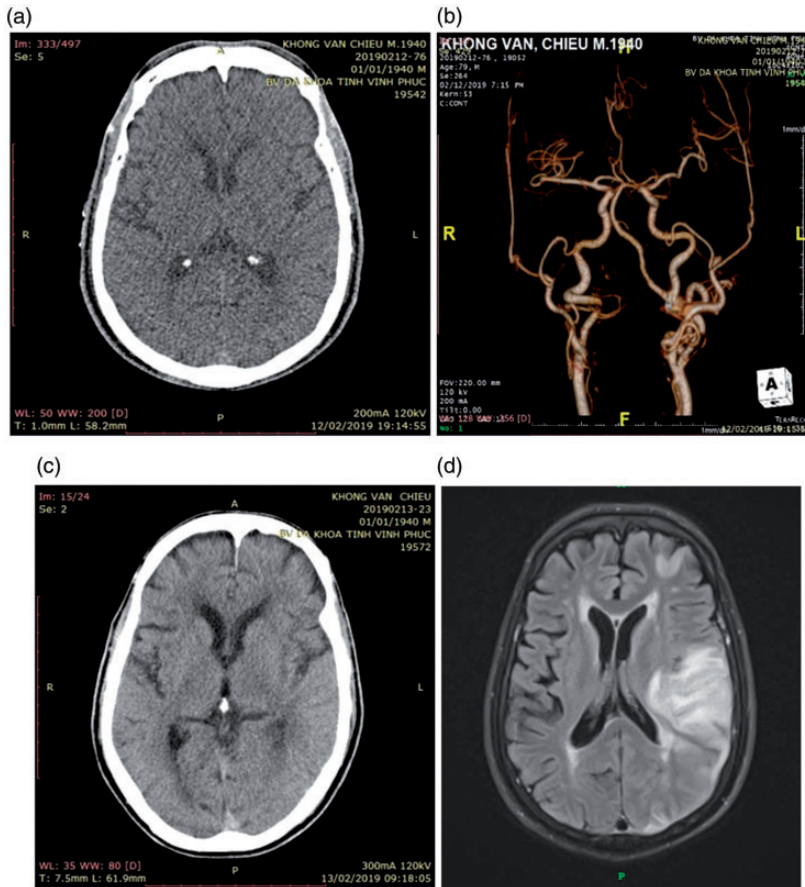


**Figure 1.** Electrocardiogram before (a) and after (b) recombinant tissue plasminogen activator infusion.

The patient was then treated with Actilyse (rt-PA) at 19:00 hours at a dosage of 0.6 mg/kg and a total transfusion time of 60 minutes with a 15% bolus injection in the first minute. This procedure was finished at 20:00 hours. Five minutes later, the patient had symptoms of shock, which were unstable, the patient was cold and pale, and he had a low heart rate of 40 to 50 beats/minute and a blood pressure of 60/40 mmHg. He then was provided an oxygen mask with 2 L/minute and dobutamine 10 µg/kg/minute to maintain blood pressure. An electrocardiogram at this moment suggested early signs of myocardial infarction (Figure 1b) with ST-segment elevation at DII, DIII, and augmented voltage foot, and third-degree atrioventricular block. No cardiac effusion was observed in echocardiography, as well as no thrombus in the four heart chambers. Subsequently, the patient underwent endotracheal intubation and IV atropine injection before being transferred to the digital subtraction angiography room for coronary intervention at 22:00 hours. Digital subtraction angiography images (Figure 3a, b) showed complete occlusion of the right

coronary artery (RCA) (segment III) and 60% stenosis of the left anterior descending artery (segment II) at the systolic phase due to a myocardial bridge. Aspiration thrombectomy in the RCA was performed. TIMI III flow was observed (Figure 3c) and many red thrombi were removed. This led us to consider etiology from the heart. Therefore, we decided not to deploy a stent in this acute stage. A total of 20 mg of IV Lovenox was additionally injected post-procedure. The patient then became stable (blood pressure was 120/80 mmHg) and dobutamine was stopped. After 1 day, a non-contrast CT scan showed no hemorrhagic lesions (Figure 2c). We continuously treated the patient with 100 mg of aspirin in combination with 90 mg Brilinta (Ticagrelor) (2 tablets/day) 24 hours after thrombolysis and Lipitor (atorvastatin calcium) 20 mg/day.

Three days after admission, on 15 February 2019, the patient was conscious with improvement of right muscle strength (4/5). On 16 February 2019, brain magnetic resonance imaging was performed (Figure 2d). This imaging showed a cortical lesion, which was equivalent to his admitted



**Figure 2.** Imaging at baseline and follow-up post-recombinant tissue plasminogen activator infusion. Computed tomographic image of brain parenchyma (a) and cerebral angiography (b) before treatment. Imaging follow-up 24 hours after recombinant tissue plasminogen activator with non-contrast computed tomography (c) and brain magnetic resonance imaging (d).

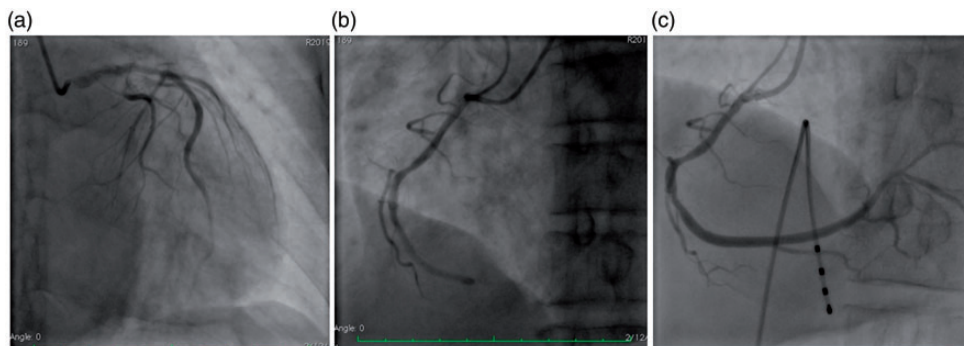
symptoms, and no large vessel occlusion was identified. The endotracheal tube was then removed and he gradually rehabilitated. After 15 days, the patient was discharged with a modified Rankin score of 2 and he continued his recovery at home.

The research was approved by the Ethics Committee of Hanoi Medical University (No. 602/QĐ-ĐHYHN on 12 February 2014). Informed consent was obtained from the patient's children (aged >18 years old) to allow our research

group to use the patient's images, data, and information for publication.

## Discussion

This was our first experience of myocardial infarction after rt-PA infusion for treatment of AIS. Using rt-PA in patients with AIS might lead to hemorrhagic complications, including intracranial bleeding and Quincke's edema. However, the complication of vessel occlusion is uncommon in



**Figure 3.** Coronary angiography before and after the aspiration procedure. A total of 60% stenosis of the left anterior descending artery (LAD) due to myocardial bridging was observed (a). Total occlusion of the distal part of the right coronary artery due to thrombus (b). Total recanalization of the right coronary artery post-aspiration (c).

this situation, especially myocardial infarction, which has only been described in some published cases.<sup>3–5</sup> There is still controversy regarding the strategy of treatment for rt-PA use. Our patient had contraindications to anticoagulants and antiplatelets for up to 24 hours. In several reported clinical cases, there were three methods of treatment for myocardial infarction after rt-PA infusion for treating AIS. The first therapy was use of a normal drug that was not a contraindication to anticoagulants or antiplatelets. Four cases had this treatment, which resulted in mortality in all cases.<sup>6–8</sup> The second therapy was subcutaneous coronary intervention with use of neither an antiplatelet nor anticoagulant. Two patients who had this treatment were reported, but the outcome was still death.<sup>7,9</sup> The third therapy was subcutaneous coronary intervention in addition to antiplatelet and/or anticoagulant use. This choice increased the risk of intracranial bleeding after treatment, but prioritized the heart more than the brain. Three patients who had this therapy were reported, and fortunately, they all survived without intracranial hemorrhagic complications.<sup>2,3,10</sup> This finding indicates the importance of antiplatelets/anticoagulants for

preserving the patient's life to keep their stents from re-occlusion. In our patient, we performed an emergency coronary intervention with the strategy of aspiration thrombectomy without a coronary stent. We performed this procedure on the basis of the theory that thrombi were coming from the heart chamber. After successful aspiration, we removed many red thrombi. This was the reason why no antiplatelet was used after rt-PA infusion (for AIS), but we were still wary about any re-occlusion of the RCA. Therefore, we decided to use low-molecular weight heparin (Lovenox) instead, even though this could slightly increase the risk of intracranial bleeding. During follow-up post-treatment, no re-occlusion of the coronary artery and no cerebral hemorrhage were observed. Manea et al.<sup>4</sup> also directly performed aspiration in a patient with myocardial infarction after thrombolytic therapy, but this resulted in vessel re-occlusion after a few minutes. Therefore, they had to deploy a coronary stent in the acute stage. This suggested that their patient could have suffered from white thrombus (calcification, plaque) more than red thrombus. Therefore, we consider that coronary aspiration should



be performed in the patient with evidence of red thrombus without using a stent in the acute stage.

## Conclusion

We experienced a rare case of myocardial infarction immediately after using rt-PA for treatment of AIS. Subsequently, the patient's RCA was successfully recanalized by aspiration thrombectomy without a coronary stent to avoid using an anticoagulant after IV rt-PA infusion. The finding of thrombi (red) in the heart chamber could be a reason for achieving a good outcome without a stent in this procedure, but more trials are required to determine this possibility in the future. This procedure without a stent helped to not only recanalize the vessel effectively, but also reduced the risk of hemorrhage and other complications of post-AIS treatment.

## Acknowledgement

We would like to thank Phuong Linh Nguyen, MSc (an English editor), for critically reading and checking the manuscript.

## Declaration of conflicting interest

The authors declare that there is no conflict of interest.

## Funding

This research received no specific grant from any funding agency in the public, commercial, or not-for-profit sectors.

## ORCID iD

Dinh-Toi Chu  <https://orcid.org/0000-0002-4596-2022>

## References

1. Fitzgerald DJ, Catella F, Roy L, et al. Marked platelet activation in vivo after intravenous streptokinase in patients with acute myocardial infarction. *Circulation* 1988; 77: 142–150.
2. Yang CJ, Chen PC, Lin CS, et al. Thrombolytic therapy-associated acute myocardial infarction in patients with acute ischemic stroke: a treatment dilemma. *Am J Emerg Med* 2017; 35: 804.e801–804.e803.
3. Almasi M, Razmeh S, Habibi AH, et al. Does intravenous administration of recombinant tissue plasminogen activator for ischemic stroke can cause inferior myocardial infarction? *Neurol Int* 2016; 8: 6617.
4. Manea MM, Dragos D, Stoica E, et al. Early ST-segment elevation acute myocardial infarction after thrombolytic therapy for acute ischemic stroke: a case report. *Medicine (Baltimore)* 2018; 97: e13347.
5. Yamaguchi J, Kinoshita K, Hirabayashi M, et al. Thromboembolic complications following tissue plasminogen activator therapy in patients of acute ischemic stroke - case report and possibility for detection of cardiac thrombi. *Open Med (Wars)* 2018; 13: 551–555.
6. Fitzek S and Fitzek C. A myocardial infarction during intravenous recombinant tissue plasminogen activator infusion for evolving ischemic stroke. *Neurologist* 2015; 20: 46–47.
7. Mehdiratta M, Murphy C, Al-Harathi A, et al. Myocardial infarction following t-PA for acute stroke. *Can J Neurol Sci* 2007; 34: 417–420.
8. Sweta A, Sejal S, Prakash S, et al. Acute myocardial infarction following intravenous tissue plasminogen activator for acute ischemic stroke: an unknown danger. *Ann Indian Acad Neurol* 2010; 13: 64–66.
9. Meissner W, Lempert T, Saeuberlich-Knigge S, et al. Fatal embolic myocardial infarction after systemic thrombolysis for stroke. *Cerebrovasc Dis* 2006; 22: 213–214.
10. Wallace EL and Smyth SS. Spontaneous coronary thrombosis following thrombolytic therapy for acute cardiovascular accident and stroke: a case study. *J Thromb Thrombolysis* 2012; 34: 548–551.