

## Sectional Anatomy Quiz – VIII

Geoffrey T Murphy, Muhammad Azaan Khan, Rashid Hashmi\*

Rural Medical School, University of New South Wales (UNSW), Wagga Wagga, NSW, Australia

### ARTICLE INFO

Article type:  
Quiz

Article history:  
Received: 27 Jan 2021  
Revised: 25 Jan 2022  
Accepted: 25 Jan 2022

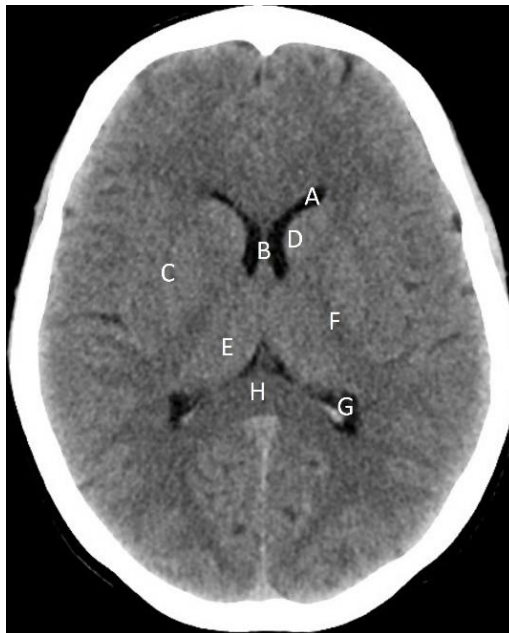
Keywords:  
Anatomy  
Brain  
Basal Ganglia

### ABSTRACT

This series lists a pictorial quiz pertaining to identification of normal and abnormal anatomical structures and landmarks at a given level on computed tomography (CT). Readers are expected to identify and appreciate the changes from normal anatomy and variations of a given pathology. It is anticipated that this series will enhance the understanding of sectional anatomy of the brain to aid in brain CT interpretation.

► Please cite this paper as:

Murphy GT, Azaan Khan M, Hashmi R. Sectional Anatomy Quiz – VIII. Asia Ocean J Nucl Med Biol. 2022; 10(2):161-165. doi: 10.22038/AOJNMB.2022.55234.1383



**Figure 1.** Identify the normal anatomical structures labelled A to H on a non-contrast axial CT brain of a 43 years-old male

### Answers

A: Frontal (anterior) horn of left lateral ventricle  
B Septum pellucidum  
C: Right lentiform nucleus  
D: Head of left caudate nucleus

E: Right thalamus  
F: Posterior limb of the left internal capsule  
G: Occipital (posterior) horn of the left lateral ventricle  
H: Splenium of corpus callosum

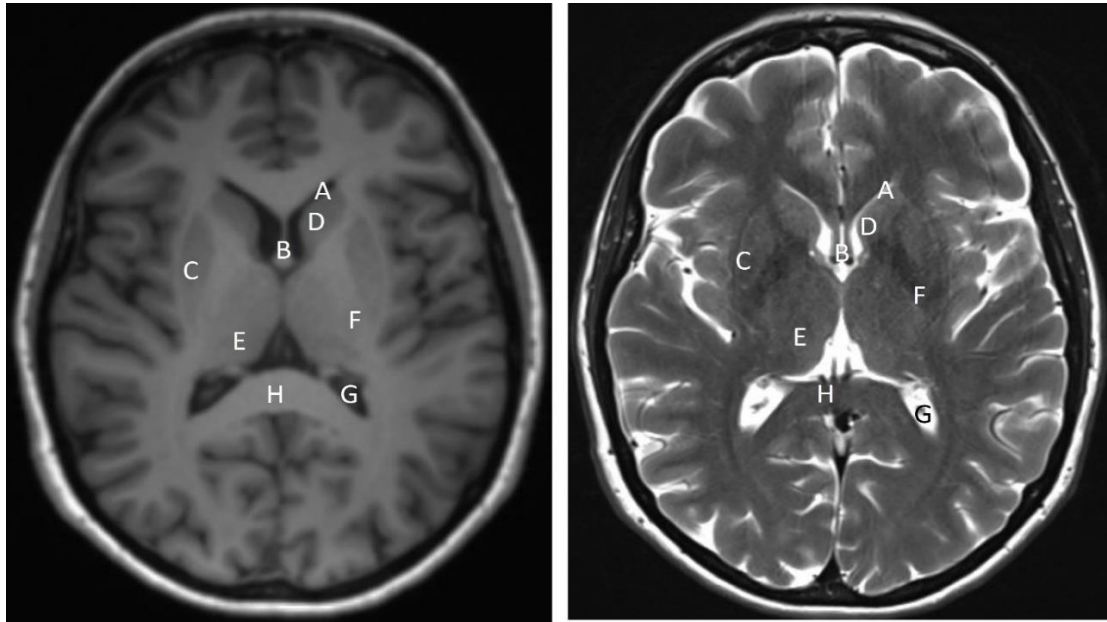
\* Corresponding author: Rashid Hashmi, Harvey House, Docker Street, Wagga Wagga, NSW 2650, Australia. Tel: +61417444228; Email address: r.hashmi@unsw.edu.au

© 2022 mums.ac.ir All rights reserved.

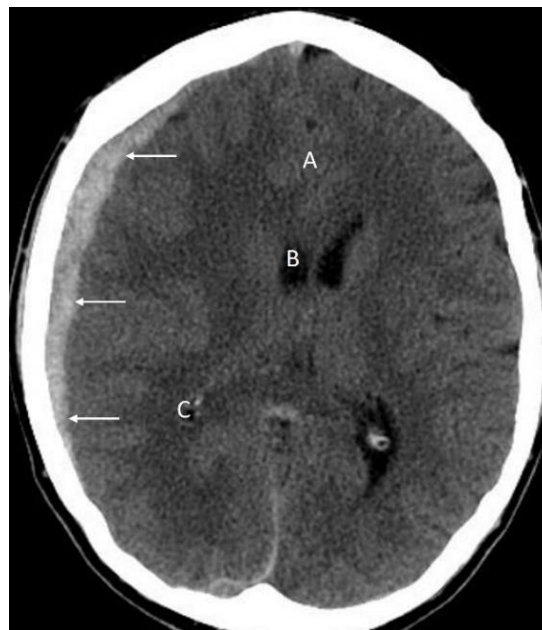This is an Open Access article distributed under the terms of the Creative Commons Attribution License (<http://creativecommons.org/licenses/by/3.0>), which permits unrestricted use, distribution, and reproduction in any medium, provided the original work is properly cited.

The image is at the level of level of the basal ganglia which is group of paired deep grey matter nuclei including caudate and lentiform

nucleus. Thin linear high density seen in the occipital horns of the lateral ventricles is due to calcification of the choroid plexus.



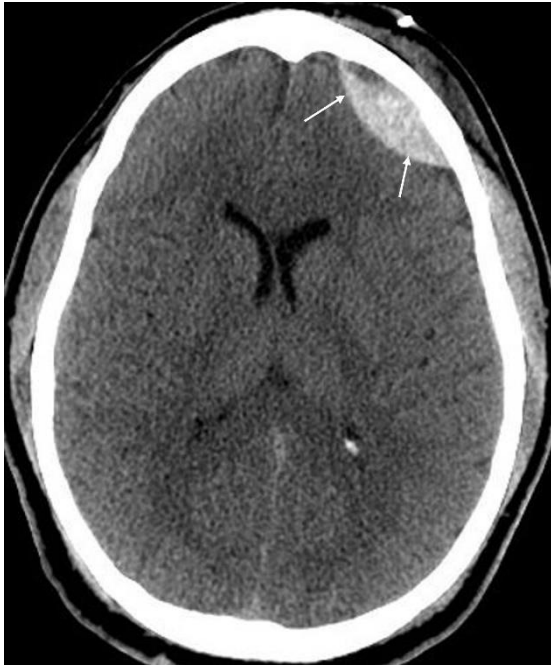**Figure 2.** T1 (left) and T2 (right) weighted axial MR images of the brain of a 45 years-old female at the level of the basal ganglia shows normal anatomy. Cerebrospinal fluid (and fluid elsewhere in body) appears hypointense (black) on T1 and hyperintense (white) on T2 weighted images respectively. Fat appears hyperintense on both T1 and T2 weighted images. It is to be noted that signal intensity of a given structure changes on various sequences used during MR imaging. Comparison with Figure 1 will help appreciating difference in appearance of normal structures on MR and CT images (A-H)



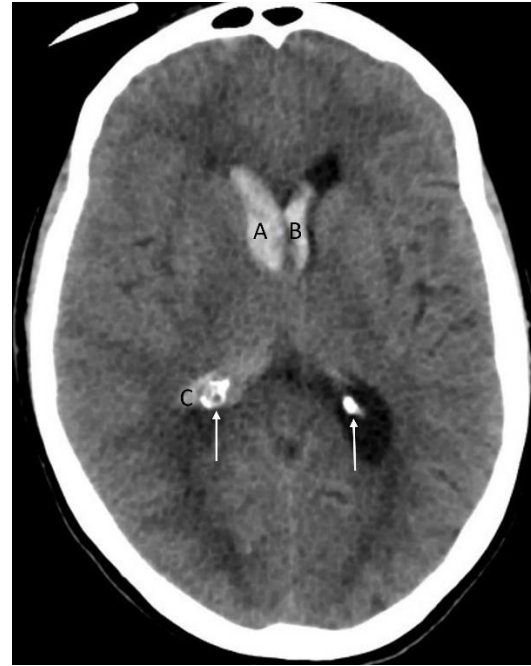**Figure 3.** Non-contrast axial CT brain of a 31 years-old male with an acute subdural hematoma (arrows) following a road traffic accident. Note the midline shift (A) and compression of the frontal (B) and occipital (C) horns of the lateral ventricle suggesting mass effect

Acute subdural hematoma characteristically appears as a crescent shaped high density area. Sub-acute subdural hematoma can be isodense to the normal brain parenchyma making its

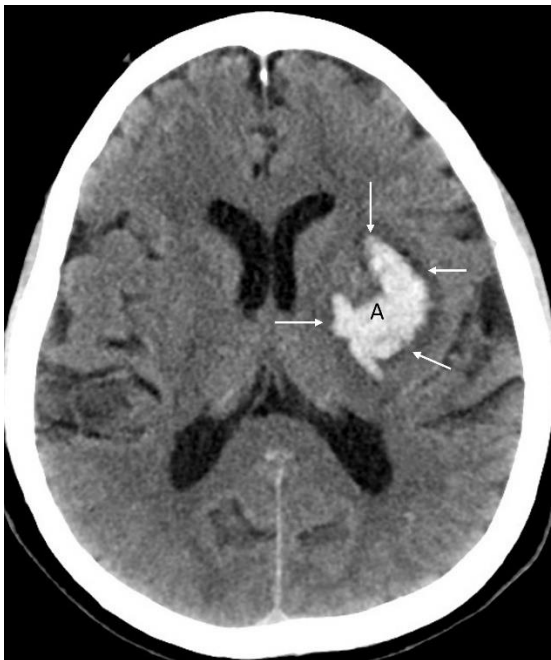
detection difficult on CT. Chronic subdural hematoma is lower in density compared to the brain parenchyma.



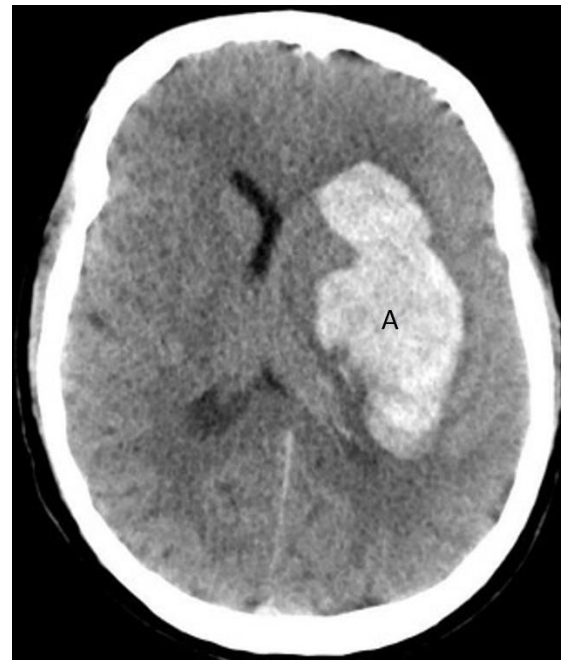**Figure 4.** Non-contrast axial CT brain of a 31 years-old male with an epidural (extra-dural) hematoma (**arrows**) shows a bi-convex hyperdense area in the left frontal region. Typically, an epidural hematoma is lentiform (bi-convex, lens shaped, lemon shaped etc.) and does not cross the sutures. In comparison, a subdural hematoma is cresenteric (moon shaped, sickle shaped, banana shaped etc.) and can cross the suture or midline



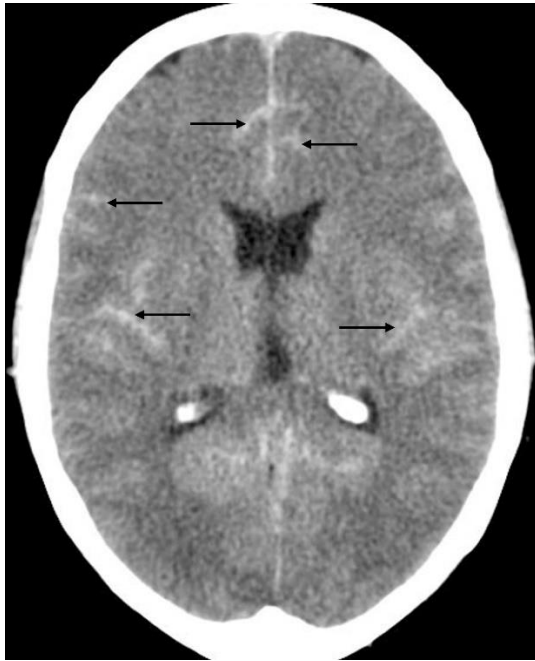
**Figure 6.** Non-contrast axial CT brain of a 78 years-old female with an intracerebral bleed showing intraventricular extension of bleed in the lateral ventricles (**A-C**). Note difference in the density of an acute bleed with that of calcification (**arrows**) of the choroid plexus. It is important to appreciate that, unlike acute bleed, density of calcification parallels that of the calvarium



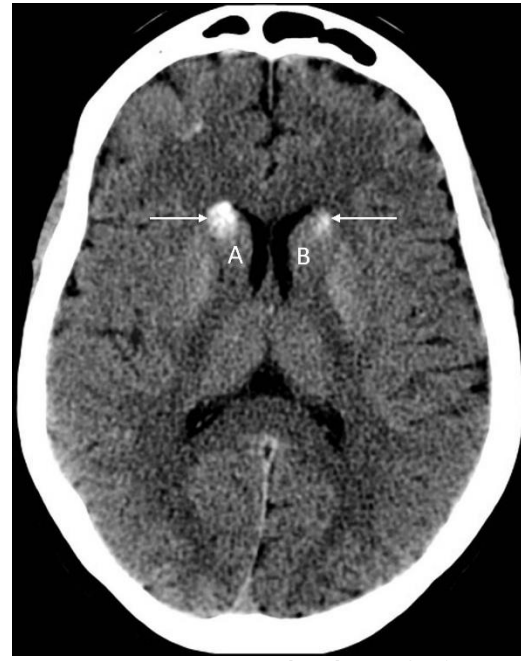**Figure 5.** Non-contrast axial CT brain of a 79 years-old male with uncontrolled hypertension shows an intracerebral hemorrhage (**A**). Hemorrhage is centered over the left sided lentiform nucleus. Low density area surrounding the hemorrhage (**arrows**) represent peri-focal oedema. No significant mass effect on surrounding structures is noted on this image



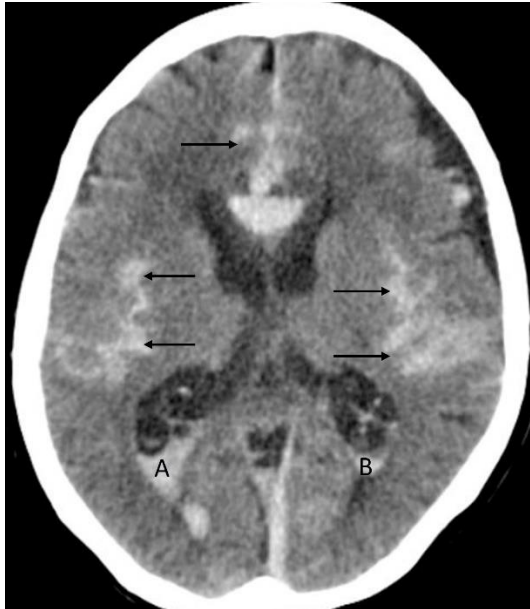
**Figure 7.** Non-contrast axial CT brain of a 51 years-old female with uncontrolled hypertension shows an intracerebral hemorrhage involving the left basal ganglia (**A**). Note the compression of the ipsilateral ventricle and midline shift



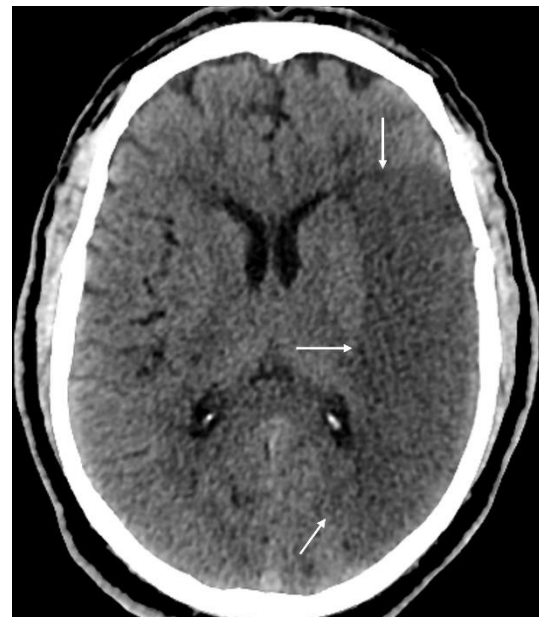**Figure 8.** Non-contrast axial brain of a 72 years-old female with a subarachnoid hemorrhage shows linear high density areas involving the cerebral sulci (**arrows**). Note prominent calcification of the choroid plexus in the occipital horns of the lateral ventricle bilaterally



**Figure 10.** Non-contrast axial CT brain of a 56 years-old male shows calcification (**arrows**) of the head of caudate nucleus bilaterally (**A-B**). Calcification in this location and other part of basal ganglia can be seen incidentally in older individuals and generally considered to be of no clinical significance. However, entities like Fahr disease, lead and carbon monoxide poisoning, tuberculosis, neurocysticercosis, toxoplasmosis and some metabolic disorders (e.g. hypo and hyperparathyroidism etc.) can also result in calcification

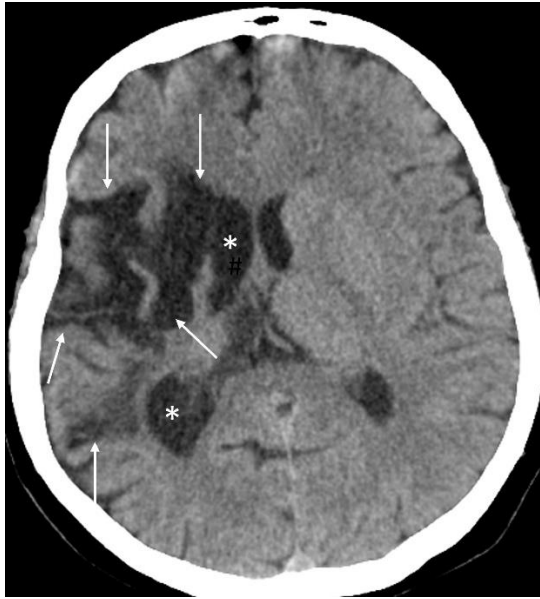

**Figure 9.** Non-contrast axial CT brain of a 67 years-old female with subarachnoid hemorrhage (**arrows**) and intraventricular extension in the occipital horns of the lateral ventricle bilaterally (**A-B**)



**Figure 11.** Non-contrast axial CT brain of a 55 years-old female with acute ischemic infarction involving the left middle cerebral artery territory. Patient presented with right hemiplegia that evolved over past 9 hours. Large ill-defined low density area (**arrows**) involving the left parietal lobe and causing effacement of the adjacent sulci is the characteristic finding of an acute ischemic infarction on non-contrast CT. Note absence of any significant mass effect





**Figure 12.** Non-contrast axial CT brain of an 82 years-old female with a history of a prior stroke shows an old infarction in the right middle cerebral artery territory (arrows). Note the dilatation of the ipsilateral ventricle (asterisks) due to loss of brain volume

### Points to remember

- The internal capsule is an important deep subcortical structure that carries afferent and efferent nerve fibres. It can be broken up into three distinct areas: the anterior limb, genu and the posterior limb. Each contains different white matter tracts. The anterior limb lies between the head of the caudate medially and the lentiform nucleus laterally and contains the anterior thalamic radiation and the frontopontine tracts. The genu is located medial to the apex of the lentiform nucleus and contains the corticobulbar tract fibres. The posterior limb lies between the thalamus medially and the lentiform nucleus posteriorly and contains the corticospinal tract in the anterior two-thirds with the middle thalamic radiation in the posterior third.
- The corpus callosum is the largest comm-

issural fibre, connecting the left and right cerebral hemispheres. It is a C shaped structure that lies superior to the thalamus and can be divided from anterior to posterior into four parts: the rostrum, genu, body and splenium. The septum pellucidum is attached to the concave under surface of the corpus callosum and separates the bodies and anterior horns of the lateral ventricles.

- The lateral ventricles are paired cerebrospinal fluid contained structures that have a body, trigone and 3 horns, each named after the lobe they project into frontal, temporal and occipital. Cerebrospinal fluid is produced in the choroid plexus which is often calcified in adults. The volume of the lateral ventricles increases with age but can also be enlarged in conditions such as schizophrenia or hydrocephalus.
- The basal ganglia are a group of deep subcortical grey matter nuclei that are important in regulating movement. It anatomically consists of the caudate nucleus, located lateral to the lateral ventricle and the lentiform nucleus which is broken up into the putamen and globus pallidus. The basal ganglia are normally isodense to the cortex but can be calcified as a normal finding, especially the globus pallidus.

### Recommendations for Further Readings

1. Ryan S, McNicholas M, Eustace SJ. Anatomy for diagnostic imaging e-book. 3<sup>rd</sup> Ed. New York: Elsevier Health Sciences; 2011.
2. Currie S, Kennish S, Flood K. Essential Radiological Anatomy for the MRCS. Cambridge University Press. 2009.
3. Moeller T, Reif E. Pocket atlas of sectional anatomy. Computed tomography and magnetic resonance imaging. Vol. 1 Head and neck. Stuttgart: Thieme; 2013.