

CASE REPORT

Open Access



Perineal stapled prolapse resection in combination with Thiersch operation for relapsed rectal prolapse: a case report

Tepei Kamada^{1*}, Hironori Ohdaira¹, Junji Takahashi¹, Yoshinobu Fuse¹, Wataru Kai¹, Keigo Nakashima¹, Yuichi Nakaseko¹, Norihiko Suzuki¹, Masashi Yoshida¹, Takeo Usui² and Yutaka Suzuki¹

Abstract

Background: Treatment options for complete rectal prolapse include over 100 procedures. In previous reports, operative rectal prolapse repair, regardless of the technique by perineal approach, was associated with high recurrence rates. However, there is no consensus on the optimal surgical procedure for relapsed rectal prolapse.

Case presentation: A 97-year-old woman was admitted to our hospital with a chief complaint of complete rectal prolapse measuring > 5 cm. The patient had a history of laparoscopic anterior suture rectopexy without sigmoid resection under general anesthesia for complete rectal prolapse one year prior. The patient's postoperative course was uneventful. However, her dementia worsened (Hasegawa's dementia scale: 5/30 points) after the first operation. Further, moderate-to-severe aortic valve stenosis was first diagnosed with heart failure 6 months after the operation. Nine months after the initial surgery, she experienced a recurrence of complete rectal prolapse measuring approximately 5 cm. Considering the coexistence of advanced age, severe dementia, and aortic valve stenosis, surgery under general anesthesia was not indicated. Perineal stapled prolapse resection in combination with the t operation was planned because of its minimal invasiveness and shortened hospital stay. The procedure was performed by a team of two surgeons in the jack knife position, under spinal anesthesia.

The prolapse was cut along the long-axis direction with three linear staplers and resected along the short-axis direction with four linear staplers. The cross-section of the linear stapler was reinforced with 3-0 Vicryl sutures. After rectal resection, the Thiersch operation using 1-0 nylon thread 1 cm away from the anal verge was additionally performed. The operative time was 24 min, and intraoperative blood loss was 1 mL. The postoperative course was uneventful. Three months after the operation, no recurrence was observed, and defecation function was good with improvements of Wexner score.

Conclusions: Perineal stapled prolapse resection in combination with the Thiersch operation could be a useful option for patients with relapsed rectal prolapse and with poor general condition, who are not indicated for other surgical procedures.

Keywords: High-risk surgery, Perineal stapled prolapse resection, Rectal prolapse, Surgical repair, Thiersch operation

Background

Patients with complete rectal prolapse are often impaired regarding surgical tolerance because a large number of these patients are elderly and have high risks from underlying diseases [1, 2]. Therefore, treatment plans require both curative and palliative options.

*Correspondence: teppei0911show@yahoo.co.jp

¹ Department of Surgery, International University of Health and Welfare Hospital, 537-3, Iguchi, Nasushiobara, Tochigi 329-2763, Japan
Full list of author information is available at the end of the article

Surgery for complete rectal prolapse is roughly divided into abdominal and perineal procedures. According to the American Society for Colon and Rectal Surgeons guidelines [3], surgical treatment should be tailored to a patient's comorbidities, age, and bowel function and the surgeon's preference and experience. There is no consensus regarding which procedure is better.

In general, when a patient has low surgical tolerance, a perineal operation is often performed, but the recurrence rate is high. Conversely, when a patient's surgical tolerance is sufficient, laparotomy or a laparoscopic abdominal operation is performed, but this requires a longer operation time, is more invasive, and has a higher complication rate than perineal operations. Although operative rectal prolapse repair has been associated with high recurrence rates in previous reports [3], there have been no recommended surgical procedures for relapsed rectal prolapse. We report a favorable course of relapsed rectal prolapse with successful perineal stapled prolapse resection in combination with the Thiersch operation in a 97-year old super-elderly patient after anterior suture rectopexy without sigmoid resection.

Case presentation

A 97-year-old woman was admitted to our hospital with a chief complaint of complete rectal prolapse measuring > 5 cm. The patient had no significant medical history.

The patient had no problem regarding surgical tolerance and had a history of undergoing laparoscopic anterior suture rectopexy without sigmoid resection under general anesthesia for complete rectal prolapse one year prior. The postoperative course was uneventful, and the patient was discharged 1 week postoperatively. However, her dementia worsened (Hasegawa's dementia scale: 5/30 points) after the operation, and moderate-to-severe aortic valve stenosis was first diagnosed with heart failure 6 months after the operation. The ejection fraction was 65.4%, and echocardiography revealed diffuse thickening of the left ventricular wall.

Nine months after the initial surgery, she experienced a recurrence of complete rectal prolapse measuring approximately 5 cm. Considering the coexistence of advanced age, severe dementia, and aortic valve stenosis, surgery under general anesthesia was not indicated. Perineal stapled prolapse resection in combination with the Thiersch operation was planned because of its minimal invasiveness and shortened hospital stay. The procedure was performed by a team of two surgeons in the jackknife position under spinal anesthesia. The jackknife position was selected instead of the lithotomy position due to serious hip joint contracture.

The prolapse was completely pulled out and fixed using Allis clamps (Fig. 1a), then cut along its long axis

with three linear staplers ($\times 2$ cartridges in the 0 o'clock direction, $\times 1$ cartridge in the 6 o'clock direction) (Powered Echelon Flex gold 60 mm) (Fig. 1b, c), and resected along its short-axis direction with four linear staplers (Fig. 1d). The cross-section of the linear staples was reinforced with 3-0 Vicryl suturing. After rectal resection, the Thiersch operation using 1-0 nylon thread 1 cm away from the anal verge was additionally performed (Fig. 2a). The operative time was 24 min and the intraoperative blood loss was 1 mL. The postoperative course was uneventful, and the patient was discharged two days postoperatively without any postoperative complications. Three months after the operation, no recurrence was observed and defecation function was good with improvements of Wexner score (18 \rightarrow 5) (Fig. 2b).

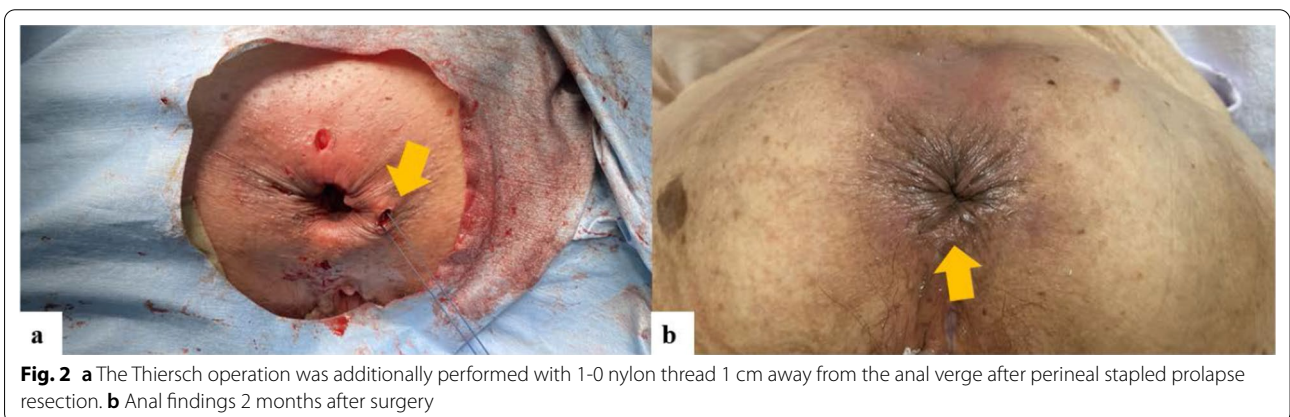
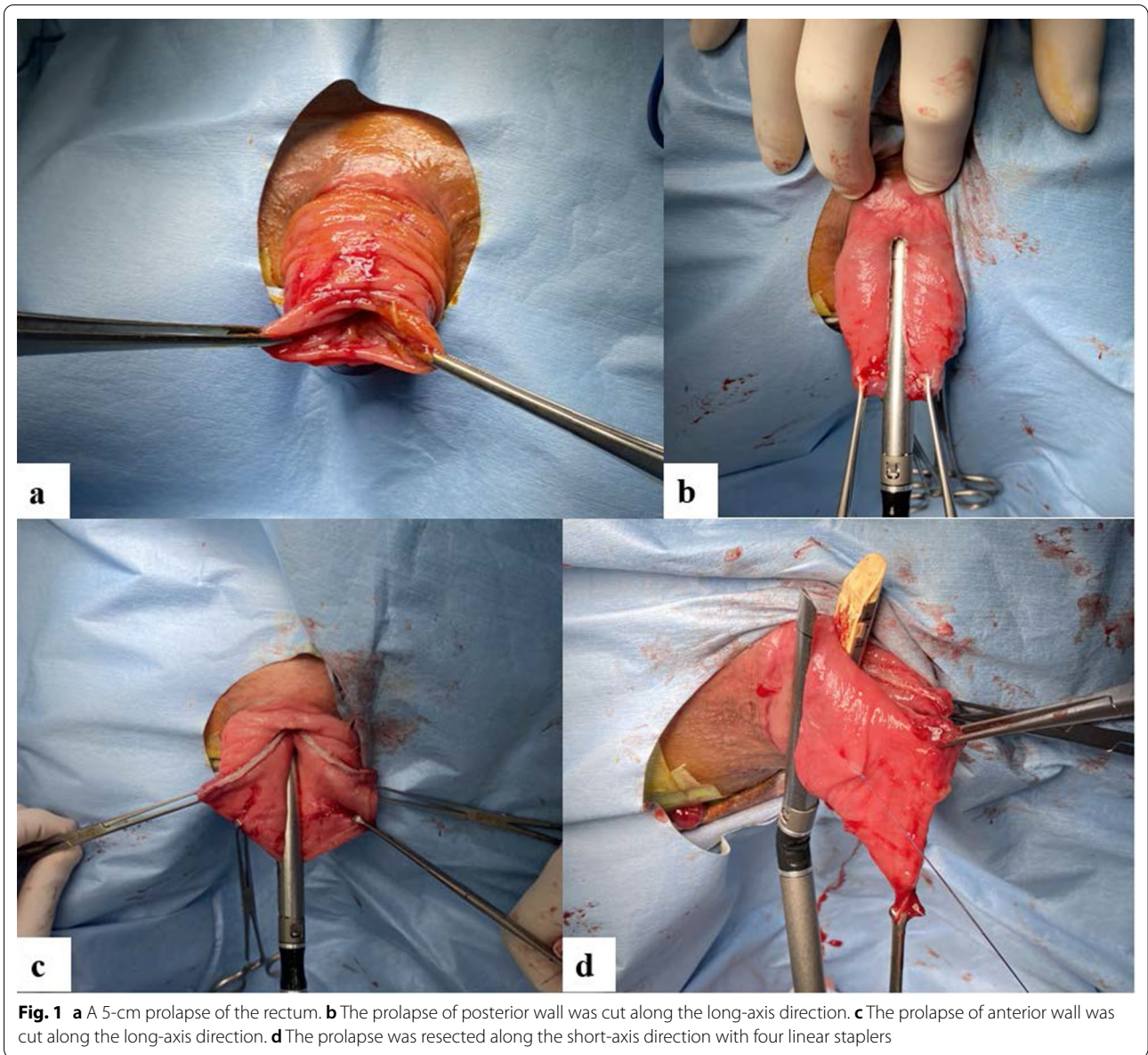
Discussion

Several mechanisms have been reported for rectal prolapse, including a spectrum of coexisting anatomic abnormalities, such as diastasis of the levator ani muscle, an abnormally deep cul-de-sac, a redundant sigmoid colon, a patulous anal sphincter, and loss or attenuation of the rectal sacral attachments [4]. The choice of treatment is important because the involvement of the pathogenesis varies from case to case.

If patient surgical tolerance is sufficient, anterior or posterior rectopexy is recommended for complete rectal prolapses measuring ≥ 5 cm accompanied by prolapse of the rectosigmoid junction [3].

Conventionally, the Delorme procedure or the Altemeier procedure has been recommended as a perineal operative option for rectal prolapse in patients with poor general condition. Previous studies reported that recurrence rates of the Altemeier procedure were within the range of 16 to 30% [5–7], and that of the Delorme procedure was within the range of 10 to 15% [7–9]. According to guidelines [3], the Altemeier procedure is appropriate for patients with a long (> 5 cm) full-thickness rectal prolapse. However, the Altemeier procedure requires transanal excision and hand-sewn anastomosis of the colon. Furthermore, the surgical technique is complicated and requires sufficient experience of the surgeons. Approximately 9–22% of patients experience complications, such as anastomotic leakage, anastomotic stenosis, pelvic hematoma, sigmoid colon perforation, pararectal abscess, and rectal–vaginal fistula. In particular, stoma creation may be required for severe anastomotic complications [5, 10]. Moreover, in cases of relapse rectal prolapse after the first Altemeier procedure, it is difficult to re-operate the same procedure because of severe adhesions caused by the primary operation.

In this case, the patient experienced relapsed rectal prolapse after anterior suture rectopexy. Since her



surgical tolerance was decreased due to age and comorbidity (aortic valve stenosis, dementia), a lower invasive procedure and shorter operation time and postoperative hospital stay were necessary. Therefore, we performed perineal stapled prolapse resection in combination with the Thiersch operation.

Perineal stapled prolapse resection is a procedure that was first reported by Scherer *et al.* in 2008 and is known as a simple technique with a low complication rate [11]. Scherer *et al.* reported that, in 14 of 15 patients (93%), perineal stapled prolapse resection was successfully performed without complications, and the median operating time was 33 min (range: 22–52 min) [11]. Fan *et al.* reported that, in a systematic review of 408 patients who underwent perineal stapled prolapse resection, bleeding was the most common complication, and the total complication rate was 14.5% (51/350) [12]. However, in a recent systematic review, the median incidence of recurrence was 13.9% for perineal stapled prolapse resection, which was higher than that of the Altemeier procedure (11.4%) [10].

In this case, the pelvic floor muscles were weakened and the anal sphincter was relaxed with fecal incontinence preoperatively. We considered that performing the perineal stapled prolapse resection alone was not sufficient. Furthermore, in addition to the recurrence of rectal prolapse, improvement in bowel function was also an important parameter for the postoperative effectiveness of the procedure [10].

In this case, the Thiersch operation was additionally performed to reinforce the anal sphincter and to improve fecal incontinence. The Thiersch operation [13, 14], which was first described in 1943, is a simple surgical procedure that encircles the anus with a thread or silver wire. The Thiersch operation has been widely used for rectal prolapse or fecal incontinence [13, 14]. However, the recurrence rate following the Thiersch operation alone for rectal prolapse is reported to 15–67% [15–17]. For this reason, the Thiersch operation is usually performed in addition to other surgical procedures. A modified Gant–Miwa–Thiersch procedure [18] and the Delorme–Thiersch operation [19] for rectal prolapse were reported with recurrence rates of 7.5% and 7.8%, respectively. Therefore, an additional Thiersch operation, among other procedures, is effective for both decreasing the incidence of recurrence for rectal prolapse and improving fecal incontinence. To our knowledge, there have been no reports of the combination of perineal stapled prolapse resection and the Thiersch operation for complete rectal prolapse.

Our modified technique of perineal stapled prolapse resection included resection of the prolapse using only linear staplers instead of curbed cutter devices. In the

original study [11], the prolapse was first cut open at three o'clock with a linear stapler along its long-axis direction, and then resected along its short-axis direction with curbed cutter devices. The curbed cutter device has a staple line length of 40 mm; in contrast, the linear stapler (Powered Echelon Flex gold) has a staple line length of 60 mm. Considering the medical cost and risk of anastomotic leakage at cross-section, we selected the linear stapler because it uses fewer cartridges. Furthermore, since a curbed cutter device was not used for resection in the short-axis direction, we considered making the excision line straighter from the curve, and two long-axis cuts using three cartridges were performed on the anterior and posterior walls (at 0 o'clock and 6 o'clock).

An important aspect of this procedure is that the number of cartridges required for intestinal resection is not constant. Rather, it is dependent on the length and thickness of the prolapsed rectum. As the cross-section between the resection stump becomes fragile, with a subsequent risk of stapling failure [20], we believe that it is important to reinforce the cross-section with absorbable threads. In addition, it is thought that staple line bleeding can be avoided by performing stapling over time and applying compression. For the Thiersch operation, a nylon thread with a low risk of wound infection was used.

As for preoperative preparation, since rectal prolapse causes marked edema due to changes in osmotic pressure, edema, and erosion, it is important to fully reposition the rectum just before surgery in preparation for a secure excision in order to reduce the risk of stapling failure.

A principal advantage of this procedure is that it can be easily performed even for relapsed cases because of its simplicity and minimal invasiveness. Another advantage of our procedure is that it can be performed regardless of the length of the prolapsed tract.

We have no data to substantiate the long-term outcomes of this treatment. This case had a short follow-up period, and careful follow-up is required in the future. Another limitation of this procedure was the high medical cost of the stapling devices. However, taking into account the shortened operation time as well as the short length of hospital stay with perineal stapled prolapse resection compared to other procedures, the higher medical costs might be compensated. Furthermore, perineal stapled prolapse resection had a theoretical possibility of blood flow insufficiency in the residual anal intestinal tract due to resecting together with the mesentery. However, but there have been no reports of this complication in past systematic reviews [10]. Further case accumulations are necessary to estimate the safety of this procedure.

Conclusions

In conclusion, perineal stapled prolapse resection in combination with the Thiersch operation could be a useful option for patients with relapsed rectal prolapse and with poor general condition who are not indicated for other surgical procedures.

Acknowledgements

Not applicable.

Authors' contributions

TK: study design, data collection, data analysis, writing. HO: critical revision. YS: final approval of the article. All other authors: data collection. All authors read and approved the final manuscript.

Funding

The authors declare that they have not received any funding for this research.

Availability of data and materials

Data sharing is not applicable to this article as no datasets were generated or analyzed during the current study.

Declarations

Ethics approval and consent to participate

Not applicable.

Consent for publication

Written informed consent was obtained from the patient for publication of this case report and any accompanying images.

Competing interests

The authors declare that they have no competing interests.

Author details

¹Department of Surgery, International University of Health and Welfare Hospital, 537-3, Iguchi, Nasushiobara, Tochigi 329-2763, Japan. ²Department of Orthopedics, Nasu Central Hospital, 1453, Shimoishigami, Otawara, Tochigi 324-0036, Japan.

Received: 2 July 2021 Accepted: 30 August 2021

Published online: 03 September 2021

References

- Gourgiotis S, Baratsis S. Rectal prolapse. *Int J Colorectal Dis.* 2007;22:231–43.
- Madiba TE, Baig MK, Wexner SD. Surgical management of rectal prolapse. *Arch Surg.* 2005;140:63–73.
- Bordeianou L, Paquette I, Johnson E, Holubar SD, Gaertner W, Feingold DL, et al. Clinical practice guidelines for the treatment of rectal prolapse. *Dis Colon Rectum.* 2017;60:1121–31.
- Tou S, Brown SR, Nelson RL. Surgery for complete (full-thickness) rectal prolapse in adults. *Cochrane Database Syst Rev.* 2015;24:001758.
- Altomare DF, Binda G, Ganio E, De Nardi P, Giamundo P, Pescatori M, et al. Long-term outcome of Altemeier's procedure for rectal prolapse. *Dis Colon Rectum.* 2009;52:698–703.
- Azimuddin K, Khubchandani IT, Rosen L, Stasik JJ, Riether RD, Reed JF. Rectal prolapse: a search for the "best" operation. *Am Surg.* 2001;67:622–7.
- Pescatori M, Zbar AP. Tailored surgery for internal and external rectal prolapse: functional results of 268 patients operated upon by a single surgeon over a 21-year period*. *Colorectal Dis.* 2009;11:410–9.
- Lieberth M, Kondylis LA, Reilly JC, Kondylis PD. The Delorme repair for full-thickness rectal prolapse: a retrospective review. *Am J Surg.* 2009;197:418–23.
- Senapati A, Nicholls RJ, Thomson JP, Phillips RK. Results of Delorme's procedure for rectal prolapse. *Dis Colon Rectum.* 1994;37:456–60.
- Emile SH, Elfeki H, Shalaby M, Sakr A, Sileri P, Wexner SD, et al. Perineal resection procedures for the treatment of complete rectal prolapse: a systematic review of the literature. *Int J Surg.* 2017;46:146–54.
- Scherer R, Marti L, Hetzer FH. Perineal stapled prolapse resection: a new procedure for external rectal prolapse. *Dis Colon Rectum.* 2008;51:1727–30.
- Fan K, Cao AM, Barto W, De Lacavalerie P. Perineal stapled prolapse resection for external rectal prolapse: a systematic review and meta-analysis. *Colorectal Dis.* 2020;22:1850–61.
- Lim CH, Kang WH, Lee YC, Ko YT, Yoo BE, Yang HK. Standardized method of the Thiersch operation for the treatment of fecal incontinence. *World J Surg.* 2020;44:3141–8.
- Thiersch CA (1943) Contribution a l'étude du Prolapsus du Rectum. Masson, Paris. Quoted in Carrasco AB
- Porter NH. Collective results of operation for rectal prolapse. *Proc R Soc Med.* 1962;55:1087–91.
- Vongsangnak V, Varma JS, Smith AN. Reappraisal of Thiersch's operation for complete rectal prolapse. *J R Coll Surg Edinb.* 1985;30:185–7.
- Jackman FR, Francis JN, Hopkinson BR. Silicone rubber band treatment of rectal prolapse. *Ann R Coll Surg Engl.* 1980;62:385–7.
- Iida Y, Honda K, Saitou H, Munemoto Y, Tanaka H. Modified Gant-Miwa-Thiersch procedure (mucosal plication with anal encircling) for rectal prolapse. *Colorectal Dis.* 2019;21:588–94.
- Hyun K, Yoon SG. Comparison of Delorme-Thiersch operation outcomes in men and women with rectal prolapse. *Ann Coloproctol.* 2019;35:262–7.
- Kim JS, Cho SY, Min BS, Kim NK. Risk factors for anastomotic leakage after laparoscopic intracorporeal colorectal anastomosis with a double stapling technique. *J Am Coll Surg.* 2009;209:694–701.

Publisher's Note

Springer Nature remains neutral with regard to jurisdictional claims in published maps and institutional affiliations.

Submit your manuscript to a SpringerOpen® journal and benefit from:

- Convenient online submission
- Rigorous peer review
- Open access: articles freely available online
- High visibility within the field
- Retaining the copyright to your article

Submit your next manuscript at ► [springeropen.com](https://www.springeropen.com)