

# A novel surgical correction and innovative splint for swan neck deformity in hypermobility syndrome

Karthik Vishwanathan<sup>1</sup>, Deepak Ganjiwale<sup>2</sup>

<sup>1</sup>Department of Orthopaedic, PSMC, Shree Krishna Hospital, <sup>2</sup>Department of Physiotherapy, KMPIP, Shree Krishna Hospital, Anand, Gujarat, India

### ABSTRACT

Splinting is a great domain of occupational therapy profession. Making a splint for the patient would depend on the need or requirement of the problems and deformities. Swan neck deformity is an uncommon condition, and it can be seen in rheumatoid arthritis, cerebral palsy, and after trauma. Conservative treatment of the swan neck deformity is available by different static splints only. There are very few reports of surgical correction of swan-neck deformity in benign hypermobility syndrome. This case report describes the result of novel surgical intervention and an innovative hand splint in a 20-year-old female with a history of cardiovascular stroke with no residual neurological deficit. She presented with correctable swan neck deformity and failed to improve with static ring splints to correct the deformity. She underwent volar plate plication of the proximal interphalangeal joint of the left ring finger along with hemitenodesis of ulnar slip of flexor digitorum superficialis (FDS) tendon whereby, the ulnar slip of FDS was passed through a small surgically created rent in A2 pulley and sutured back to itself. Postoperatively, the patient was referred to occupational therapy for splinting with the instruction that the splint would work sometimes for as static and some time as dynamic for positional and correction of the finger. After occupational therapy intervention and splinting, the patient had a full correction of the swan-neck deformity with near full flexion of the operated finger and can work independently.

**Keywords:** Deformity, finger, hypermobility, splint, swan neck

### Introduction

Swan-neck deformity refers to a condition wherein the finger is hyperextended at the proximal interphalangeal (PIP) joint and is flexed at the distal interphalangeal (DIP) joint. This deformity is most commonly seen in rheumatoid arthritis, however, it has also been reported in Ehler Danlos syndrome<sup>[1]</sup> and benign hypermobility syndrome.<sup>[2]</sup>

### Case Report

A 22-year-old college student presented with swan neck deformity affecting the left ring finger subsequent to a cerebrovascular stroke leading to left hemiparesis 4 years ago. Although she regained good motor function in the left upper and

lower extremity in two-year but noticed gradual development of swan neck deformity. She was prescribed static splint and figure of 8 static rings to correct the swan neck deformity at the PIP joint. Static splint prevented her from flexing the PIP joint during hair washing. She presented to the orthopedic surgeon with the expectation of deformity correction and have the functional ability to use her left ring finger without splint.

Clinical examination showed grade 1 swan neck deformity as per Nalebuff classification affecting the left ring and middle fingers [Figures 1 and 2]. Littler-Bunnell test showed no tightness of finger intrinsic muscles. She demonstrated hypermobility syndrome as she scored five out of nine points as per Beighton criteria.<sup>[3]</sup>

### Operative technique

A Brunner type incision was made extending distally from the distal palmar crease to the distal digital crease to expose the

This is an open access journal, and articles are distributed under the terms of the Creative Commons Attribution-NonCommercial-ShareAlike 4.0 License, which allows others to remix, tweak, and build upon the work non-commercially, as long as appropriate credit is given and the new creations are licensed under the identical terms.

For reprints contact: [reprints@medknow.com](mailto:reprints@medknow.com)

**How to cite this article:** Vishwanathan K, Ganjiwale D. A novel surgical correction and innovative splint for swan neck deformity in hypermobility syndrome. *J Family Med Prim Care* 2018;7:242-5.

**Address for correspondence:** Dr. Deepak Ganjiwale, KMPIP, Shree Krishan Hospital, Karamsad, Anand, Gujarat, India. E-mail: [deepakg@charutarhealth.org](mailto:deepakg@charutarhealth.org)

#### Access this article online

##### Quick Response Code:



Website:  
[www.jfmpc.com](http://www.jfmpc.com)

DOI:  
10.4103/jfmpc.jfmpc\_14\_17

A1 pulley and the A3 pulley. The cruciate pulley was incised to visualize the flexor digitorum superficialis (FDS) and the flexor digitorum profundus.

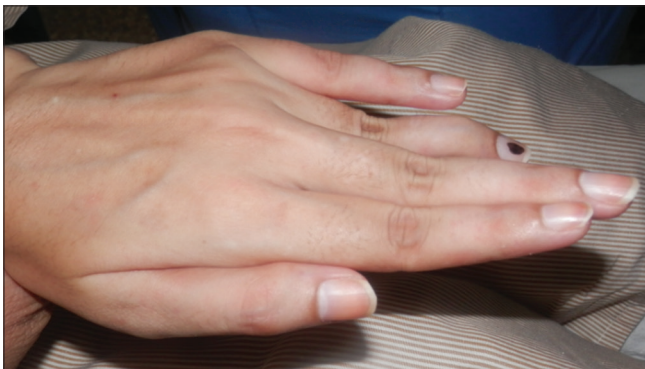Intraoperatively, the volar plate was lax, and decision was taken to perform plication of the volar plate using absorbable sutures. To achieve this single number 2-0 Vicryl were passed longitudinally on the radial side of the volar plate. The Vicryl suture was passed from distal to proximal direction taking bites of approximate 5 mm of the volar plate twice [Figure 2]. Similarly, another number 2-0 Vicryl was passed longitudinally on the ulnar side of the volar plate taking bites of the volar plate twice. When the sutures were tied, it led to shrinking of the volar part of the PIP joint [Figure 3] keeping the PIP joint in 30° flexion.

After satisfactory completion of the volar plate plication, additional restraint was created by performing a hemitenodesis using ulnar slip of the FDS.<sup>[4]</sup> A transverse rent was surgically created in the central part of the volar aspect of the A2 pulley and the incised ulnar slip of FDS was passed through the rent in the A2 pulley from dorsal to volar side and sutured back to the dorsal lying ulnar slip of the FDS using nonabsorbable Number 3-0 prolene suture. Before final tightening of the non-absorbable

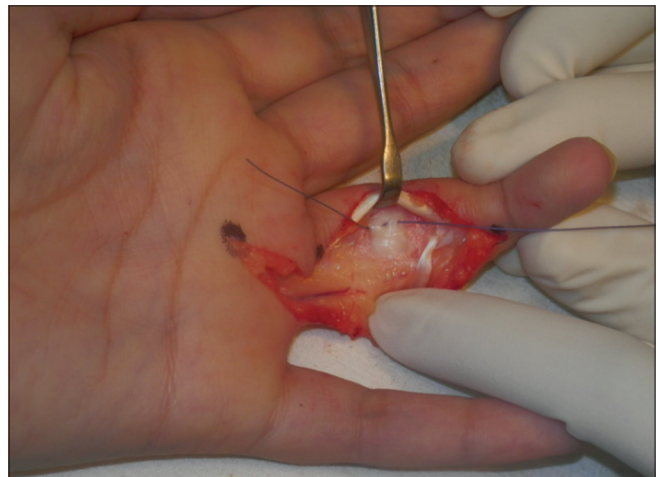
suture, the digit was maintained in flexion of 30° at the PIP joint to ensure correct tension of the hemitenodesis repair of the FDS tendon. Multiple sutures using nonabsorbable Number 3-0 prolene suture were taken to tie the FDS tendon and also to secure the FDS tendon to A2 pulley [Figure 4]. Routine closure of subcutaneous fat and skin was performed. Suture removal was performed after 2 weeks.

### Postoperative novel splint and rehabilitation

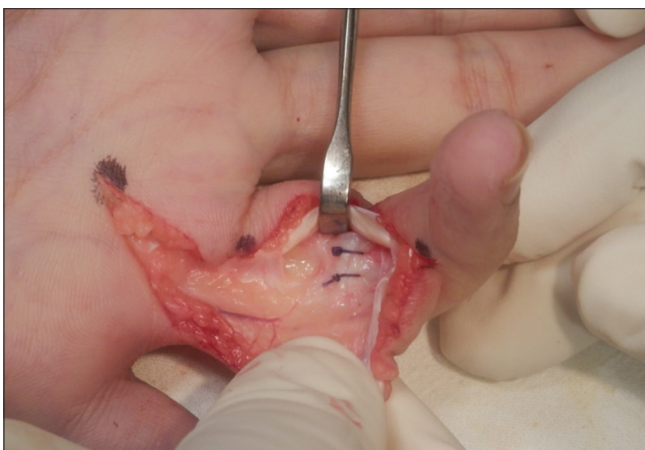
For protecting the surgical repair, static splintage was required and for early mobilization and preventing the formation of adhesions in flexor tendon system; dynamic splintage was deemed necessary. To achieve both these diverse aims, we designed a novel splint which helped us achieve both static and dynamic functions. Dynamic traction was provided by rubber band between fingertips and volar aspect of the wrist to maintain the involved digits' flexion to further relax and also to prevent inadvertent active flexion of the tendon [Figure 5].



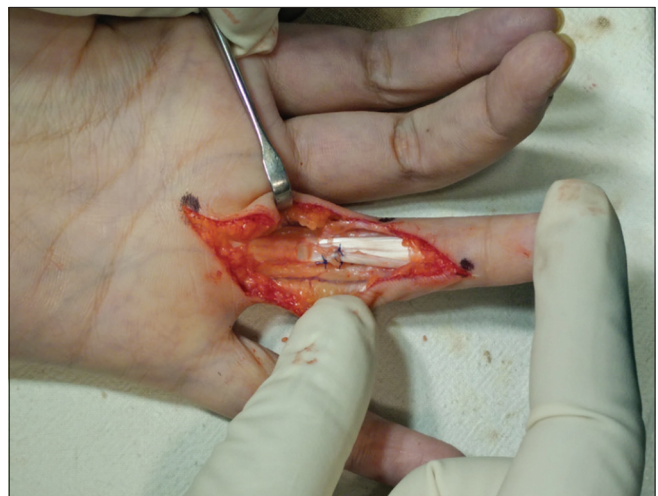**Figure 1:** Swan neck deformity affecting ring finger more than the middle finger




**Figure 2:** Vicryl suture passed twice with intervening soft tissue. Figure shows lax volar plate



**Figure 3:** Transverse furrow can be seen in the middle part of the volar plate due to volar plate shrinkage subsequent to tying of both vicryl suture knots. Flexor digitorum superficialis and flexor digitorum profundus have been retracted towards the radial side



**Figure 4:** Ulnar slip of flexor digitorum superficialis has been passed through substance of A2 pulley and tied using multiple prolene suture knots



**Figure 5:** The novel splint immobilizing the operated ring finger but aiding mobilization of the nonoperated middle finger

Initially, the ring finger was immobilized for two weeks and simultaneously mobilization and strengthening of the uninvolved digits were commenced using the same splint. The patients were instructed to actively extend the involved digits against the tension of the rubber band 10 times/h.

Care was taken to maintain PIP joint in 30° flexion till six weeks after the surgical procedure. Initially, we stabilized the PIP joint at 30° flexion and moved only the DIP joint so again we did some correction in the splint to move the splint in such a way that DIP joint moved 20° only, gradually we increased it up to 40° and also started to strengthen the ring finger muscles to make the patient independent for performing activities of daily living.

Final follow-up was at nine months after the surgical procedure where the patient was satisfied with both the cosmetic appearance of the digit and the functional outcome [Figure 6].

## Discussion

It has been reported that benign hypermobility syndrome is common in the Indian population<sup>[5]</sup> but it is unrecognized and less often reported.<sup>[6]</sup>

To the best of our knowledge, there has been only one previously reported a study on treatment of swan neck deformity in patient with hypermobility syndrome.<sup>[1]</sup> Moreover, this unique combined method of volar plate plication with FDS hemitenodesis has not been previously reported. Predictable and satisfactory outcomes have been reported after FDS hemitenodesis in correctable swan neck deformities in rheumatoid arthritis<sup>[7]</sup> and swan neck deformities occurring subsequent to unconstrained type PIP joint replacement.<sup>[8]</sup>

Ehler-Danlos syndrome leads to laxity of capsular structures and ligamentous structures around various joints. Options of dealing with hyperlaxity include capsular shrinkage, incising the volar plate of the PIP joint and performing Mayo “vest-over-pant” repair. Incising the volar plate transversely and doing the repair is likely to cause inflammatory reaction and thereby risks



**Figure 6:** Complete deformity correction of the ring finger

development of permanent PIP joint stiffness. Hence, a decision was taken to cause capsular shrinkage using delayed absorbable sutures. The use of absorbable sutures guarded against the development of permanent overcorrection.

The advantages of our surgical technique are achieving and sustaining good correction of the swan neck deformity and the ability to start early flexion exercises of metacarpophalangeal, PIP, and DIP joints. The dual checkrein mechanism employed in our surgical technique obviated the need for Kirschner wire fixation of PIP joint to maintain postoperative correction. Some authors have described the use of trans-articular PIP joint transfixing kirschner wire after correction of swan neck deformity using other surgical techniques.<sup>[9,10]</sup> Another main advantage of the hand splint includes the ability to take the splint off for doing passive and active flexion of the digits soon after the first wound check on the third postoperative day.

## Declaration of patient consent

The authors certify that they have obtained all appropriate patient consent forms. In the form the patient(s) has/have given his/her/their consent for his/her/their images and other clinical information to be reported in the journal. The patients understand that their names and initials will not be published and due efforts will be made to conceal their identity, but anonymity cannot be guaranteed.

## Financial support and sponsorship

Nil.

## Conflicts of interest

There are no conflicts of interest.

## References

1. Erçöçen AR, Yenidünya MO, Yılmaz S, Ozbek MR. Dynamic swan neck deformity in a patient with Ehlers-Danlos syndrome. *J Hand Surg Br* 1997;22:128-30.
2. Lawrence A. Benign hypermobility syndrome. *J Indian Rheumatol Assoc* 2005;13:150-5.

3. Christophersen C, Adams JE. Ehlers-Danlos syndrome. *J Hand Surg Am* 2014;39:2542-4.
4. Wei DH, Terrono AL. Superficialis sling (Flexor Digitorum Superficialis Tenodesis) for swan neck reconstruction. *J Hand Surg Am* 2015;40:2068-74.
5. Kumar A, Wadhwa S, Acharya P, Seth S, Kokhar S, Singh RV, *et al.* Benign joint hypermobility syndrome: A hospital-based study from Northern India. *Indian J Rheumatol* 2006;1:8-12.
6. Mullick G, Bhakuni DS, Shanmuganandan K, Garg MK, Vasdev V, Kartik S, *et al.* Clinical profile of benign joint hypermobility syndrome from a tertiary care military hospital in India. *Int J Rheum Dis* 2013;16:590-4.
7. Brulard C, Sauvage A, Mares O, Wavreille G, Fontaine C. Treatment of rheumatoid swan neck deformity by tenodesis of proximal interphalangeal joint with a half flexor digitorum superficialis tendon. About 23 fingers at 61 months follow-up. *Chir Main* 2012;31:118-27.
8. Froelich JM, Rizzo M. Reconstruction of swan neck deformities after proximal interphalangeal joint arthroplasty. *Hand (N Y)* 2014;9:93-8.
9. Borisch N, Siemon B, Heers G, Döbler A. Littler tenodesis for correction of swan neck deformity in rheumatoid arthritis. *Handchir Mikrochir Plast Chir* 2010;42:65-70.
10. Ozturk S, Zor F, Sengezer M, Isik S. Correction of bilateral congenital swan-neck deformity by use of Mitek mini anchor: A new technique. *Br J Plast Surg* 2005;58:822-5.