

ORIGINAL ARTICLE

A Retrospective Comparison of ACL Tear and Mucoïd Degeneration MRI Findings and an Emphasis on Evaluating of ACL, Blumensaat, and PCL Angles

Fatih Celikyay, Ruken Yuksekkaya and Erkal Bilgic

Objective: To determine MRI findings that can differentiate anterior cruciate ligament (ACL) tears from mucoïd degeneration.

Material and Methods: Thirty-seven patients with complete ACL tears and 43 with ACL mucoïd degeneration were included in this study. Discontinuity, the abnormal signal intensity of the ACL on fat-saturated-PD weighted images, contusions, a deep lateral femoral notch, anterior tibial translation, uncovered posterior horn of the lateral meniscus, a celery stalk appearance, thickening, ganglion cysts, intraosseous cysts, the ACL, Blumensaat, and posterior cruciate ligament (PCL) angles were evaluated. Optimum threshold values, sensitivity, specificity, and 95% CIs for the angles were calculated to predict the tear.

Results: The prevalence of the significant findings in a tear versus mucoïd degeneration, respectively, was as follows: discontinuity (97% vs. 0%, $p < 0.001$), contusions (65% vs. 2%, $p < 0.001$), the deep lateral femoral notch (22% vs. 0%, $p = 0.001$), anterior tibial translation (70% vs. 14%, $p < 0.001$), uncovered the lateral meniscus (46% vs. 7%, $p < 0.001$), a celery stalk appearance (0% vs. 66%, $p < 0.001$), thickening (19% vs. 100%, $p < 0.001$), ganglion cysts (14% vs. 70%, $p < 0.001$), and intraosseous cysts (8% vs. 63%, $p < 0.001$). Threshold values of ACL, Blumensaat, and PCL angles to predict the tear were $\leq 36^\circ$ (78% sensitivity, 91% specificity), $> 11^\circ$ (84%, 81%), and $\leq 96^\circ$ (65%, 91%), respectively.

Conclusion: A celery stalk appearance in the mucoïd degeneration and discontinuity in an ACL tear are important in the differential diagnosis. ACL, Blumensaat, and PCL angles can be helpful in settings of diagnostic uncertainty.

Keywords: ACL; tear; mucoïd degeneration

Introduction

Anterior cruciate ligament (ACL) tears are one of the common injuries of the knee and can lead to substantial disability [1]. Multiple primary and secondary signs of an ACL injury on magnetic resonance imaging (MRI) have been described. Primary signs of ACL tears usually include focal or diffuse discontinuity, abnormal signal intensity, and abnormal orientation or bowing of the ACL [1, 2–12]. While the abnormal orientation may be visually appreciated, measurement of the ACL and Blumensaat angles can be required to detect subtle changes and improve the accuracy of the MRI [1, 3, 7, 10, 11]. Commonly used secondary MRI signs include bone contusions in the lateral femoral condyle and posterolateral tibial plateau, anterior translation of the tibia, uncovered posterior horn of the lateral meniscus, decreased posterior cruciate ligament (PCL) angle, and Segond fracture [1, 2, 6–17]. Although there is no cutoff age for surgery, the treatment of ACL

tears in patients younger than 40–50 years of age with high-grade injury is usually reconstruction [18, 19].

In contrast to the tear, mucoïd degeneration of the ACL characteristically does not cause knee instability [20–22]. Recent studies have reported that the prevalence of ACL mucoïd degeneration is approximately 2–14% [20, 23–25]. The main MRI finding of ACL mucoïd degeneration is a celery stalk appearance [26, 27]. An ill-defined contour, thickening, intraosseous cysts, and ganglia associated with the ACL can also be seen [20–23, 25–27]. The treatment is usually based on clinical features [28].

On MRI, increased signal intensity and poor visualization of the ACL do not always correspond to a tear, as mucoïd degeneration also has an increased signal on fluid-sensitive images and indistinct margins. It has been suggested that the secondary signs of ACL tear may be helpful in differentiating the tear from ACL mucoïd degeneration [21, 23]. However, to the best of our knowledge, MRI findings have not been compared between both groups in a large study. Additionally, ACL, Blumensaat, and PCL angles have not yet been tested for differentiation of a torn ACL from mucoïd degeneration. Therefore, the purpose of the present study was to elucidate MRI findings that

can distinguish between complete ACL tears and mucoïd degeneration.

Material and Methods

Patient Groups

Local ethics committee approval was obtained for the review of patient records and MRI examinations. We retrospectively reviewed consecutive 3756 knee MRI examinations performed between March 2012 and May 2015 at our institution. Forty-two patients (43 knees) (11 males, 31 females; mean age 54.6 ± 10.7 years; range 30 to 73) (1.15% of 3756 knees MRIs) interpreted as mucoïd degeneration of the ACL by the investigator radiologists were included diagnosed in the study. The inclusion criteria for the mucoïd degeneration group were the following: available medical record with the relevant history and physical examination; no history of knee surgery and/or known inflammatory arthritis and/or severe osteoarthritis. Patients with ACL instability at the physical examination were not included in the mucoïd degeneration group. Thirty-seven patients (34 males, 3 females; mean age 29.4 ± 9.1 years; range 16 to 51), (0.99% of 3756 MRIs) with arthroscopically confirmed complete ACL tears were included in the tear group. The inclusion criterion for the tear group was that the time between the MRI exams and arthroscopy was less than 12 months. We did not include patients with partial ACL tear because the angles will not be so different compared to mucoïd degeneration. Data on patient age and gender were recorded. Physical examination, history, and arthroscopy records of the patients were obtained from the hospital electronic medical records.

MRI Protocol

All imaging studies were performed on a Signa 1.5 T Excite HD MRI system (GE Healthcare, Milwaukee, WI, USA) and

a dedicated phased array knee coil with four-channel. The knee was placed in an extended position (0°) while the patient was the supine situation without any rotation at the hip and additional padding to accentuate anterior translation of the tibia. All knee MRI exams included axial, sagittal, and coronal fat-suppressed fast spin-echo proton density (PD) images (echo time [TE]: 30–42, repetition time [TR]: 2100–2800), sagittal T1-weighted images (TE: 9–12, TR: 600–800), and sagittal gradient-echo images (TE: 10–11, TR: 350–400, flip angle: 25°). The number of excitations for sequences was 1–2. A slice thickness of 4 mm with a 0.4–1 mm interslice gap was used. The field of view was 16–18 cm and the matrix size was 384–320 \times 320–224.

Analysis of MR images

Analysis of MR images was performed using the patient archive at our facility and the Centricity RA 1000 picture archiving and communication system (PACS) workstation (GE Healthcare, Milwaukee, WI, USA). All knee MRI examinations were randomly assigned to a list without patients' history. To avoid any bias, the MRIs were re-assessed by a musculoskeletal radiologist with 13 years of experience one month after completion of the initial assessment. The MRI findings evaluated were the primary and secondary findings of an ACL tear, a celery stalk appearance, ACL thickening, an ill-defined ACL, presence of ganglion cysts associated with the ACL, and intraosseous cysts and bone marrow edema at the femoral and/or tibial attachments.

Primary MRI signs of the tear included focal or diffuse discontinuity, abnormal high-signal intensity on fat-saturated PD-weighted images (diffuse or focal), and an abnormal orientation. Discontinuity (**Figure 1a**) was defined as a focal gap within the ligament or diffuse disruption of all of its fibers in any imaging plane [11]. The abnormal orientation of the ligament was evaluated by measurement of the ACL (**Figure 1b**) and Blumensaat angles (**Figure 1c**). The ACL

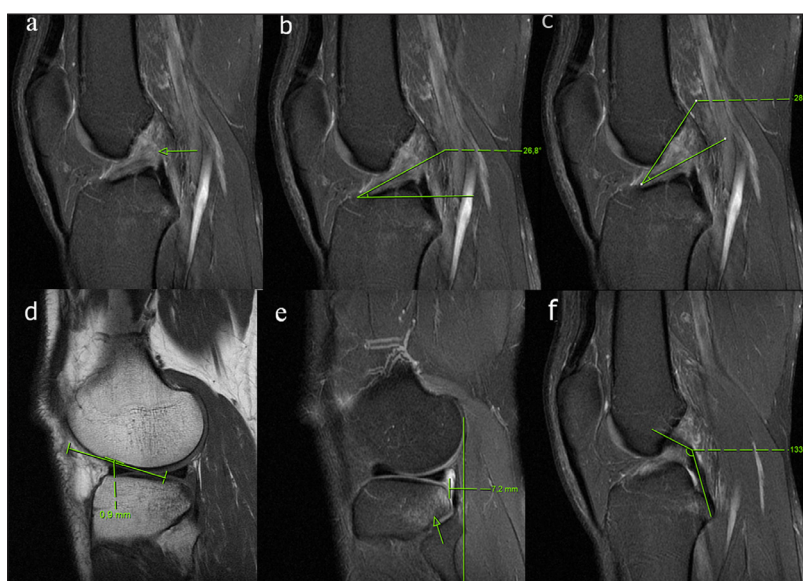


Figure 1: A 33-year-old male patient with a torn ACL, arthroscopically proven. **(a)** Sagittal PD-weighted image demonstrating discontinuity of the ACL (arrow). The ACL angle is decreased **(b)**, consistent with a tear. The apex of Blumensaat angle **(c)** formed distally with a positive value. **(d)** There is no deep the lateral femoral notch sign on the T1 weighted image. **(e)** There is a significant anterior translation of the tibia on the lateral midsagittal PD weighted image. The PCL angle **(f)** is normal.

angle was formed by the intersection of a parallel line to the distal portion of the ACL and a tangential line to the most anterior aspect of the intercondylar eminence which is perpendicular to the long axis of the tibia on a midsagittal MRI image [11]. The Blumensaat angle was formed by the intersection of lines drawn through the distal portion of the ACL and the intercondylar roof. The Blumensaat angles that formed proximally considered negative, while those that formed distally were considered positive [3, 7, 11].

Secondary MRI signs of the tear included bone contusions in the lateral femoral condyle and/or posterolateral tibial plateau, a deep lateral femoral notch greater than 1.5 mm, an anterior tibial translation greater than 5 mm, uncovered posterior horn of the lateral meniscus, reduction of the PCL angle, Segond fracture, and effusion. The contusion was defined as bone marrow edema more than 5 mm in the anterior femoral condyle and/or posterolateral tibial plateau. The deep lateral femoral notch (**Figure 1d**) was measured on the lateral femoral condyle at the adjunction of the weight-bearing tibial and patellar articular surfaces of the femoral condyle [13]. Anterior tibial translation (**Figure 1e**) was quantified by measuring the distance between two parallel lines drawn a tangent to the posterior of the lateral femoral condyle and the tibial plateau on the midsagittal image through the lateral compartment of

the knee [1, 6]. The anterior position of the tibia relative to the femoral condyle had a positive value. An uncovered posterior horn of the lateral meniscus was defined as the posterior displacement of the lateral meniscus relative to the posterior vertical margin of the mid-lateral tibial plateau [7, 16, 17]. The PCL angle (**Figure 1f**) was the angle formed between the lines tangential to the proximal and distal parts of the PCL [7, 11, 17].

A celery stalk (**Figures 2a** and **3a**) sign was described the appearance of intact fibers with low signal separated from each other by a prominent high signal within thickened ACL on fat-saturated PD-weighted images [26, 27]. The ACL thickening was defined when the thickness was not uniform and 7 mm or greater [11]. The criterion for ill-defined ACL was contour of the ligament poorly seen on T1-weighted and fat-saturated PD-weighted images. Ganglion cysts associated with the ACL were defined as fluid signal adjacent to or within the ligament having the following criteria: mass effect on anterior cruciate ligament fibers and lobulated margin (**Figure 3b**) [20].

Data analysis

All MRI findings were compared between the groups. Statistical analysis was performed using SPSS version 18.0 for Windows software package (SPSS Inc., Chicago, IL, USA).

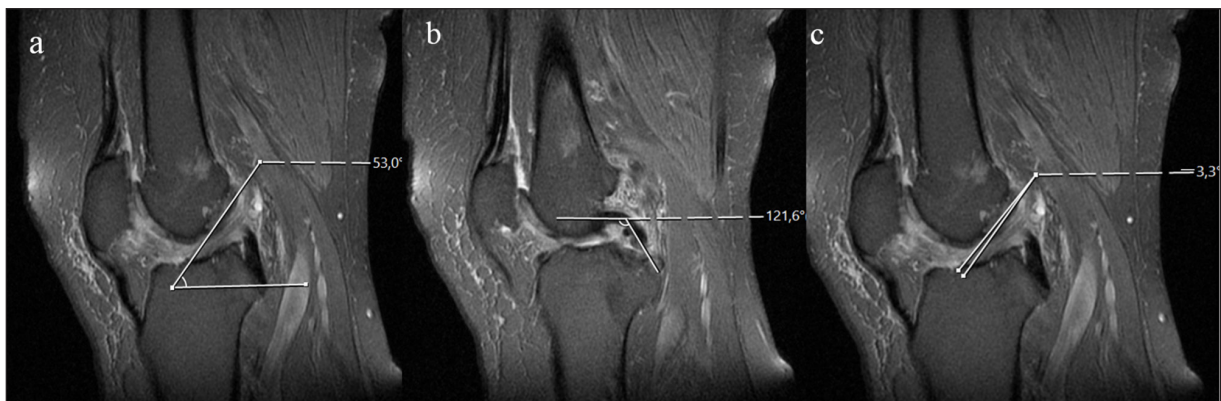


Figure 2: A 50-year-old female patient with mucoïd degeneration. Sagittal PD-weighted images show the ACL (**a**) and PCL angles (**b**) are in the normal range. The ACL (**a**) also has a celery stalk appearance. The apex of Blumensaat angle (**c**) formed proximally with a negative value, which does not indicate a tear.

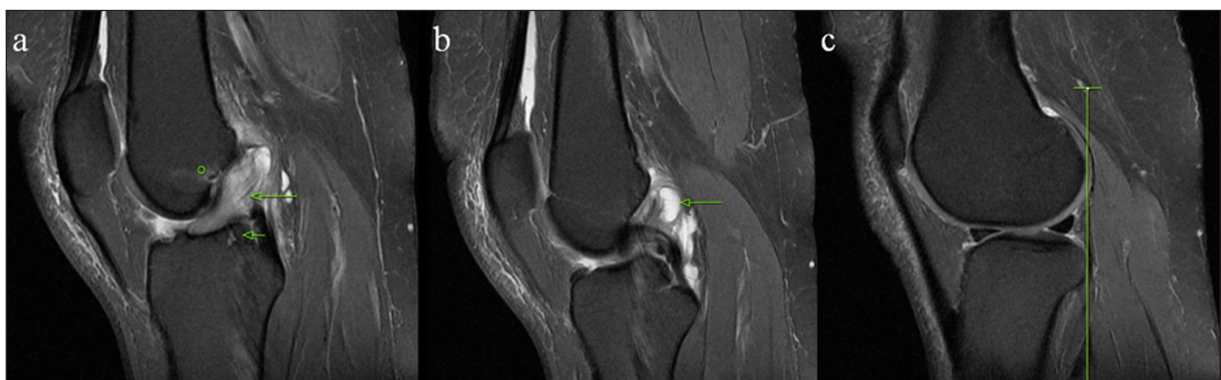

Figure 3: A 47-year-old female patient with mucoïd degeneration. (**a**) Sagittal PD-weighted image demonstrating increased signal and poor visualization of the thickened ligament, consistent with a celery stalk appearance (long arrow), bone marrow edema at the femoral origin (circle), and an intraosseous cyst at the tibia insertion (short arrow). Consecutive images show a ganglion cyst (arrow) (**b**) associated with the ACL and lack of anterior tibial translation (**c**).

A nonparametric Wilcoxon 2-sample *t*-test was used to compare continuous variables, while categorical variables were compared using a chi-square test. Continuous data were expressed as means ± standard deviations, and categorical data were expressed as numbers (*n*) with related percentages. Statistical significance was set at an alpha of 0.05. The most appropriate threshold values for the ACL, Blumensaat, and PCL angles were calculated with univariate logistic regression analysis. The sensitivity and specificity of the angles were determined and obtained receiver operating characteristic (ROC) curves. Odds ratios and 95% confidence intervals (CI) were calculated using logistic regression analysis.

Results

Tables 1–2 list results of all MRI findings evaluated. The following is a summary of the MRI findings. Discontinuity of the ACL was observed in almost all tear cases but was absent in the mucoïd degeneration group (97% vs.0%, respectively; *P* < 0.001). The bone contusions were significantly more frequently observed with an ACL tear, but rare with mucoïd degeneration (65% vs. 2%, respectively; *P* < 0.001). An anterior tibial translation greater

than 5 mm was more common in the ACL tear group than the mucoïd degeneration group (70% vs.14%, respectively; *P* < 0.001). A celery stalk appearance was only seen in the mucoïd degeneration group (66% vs. 0%; *P* < 0.001). Ganglion cysts associated with the ACL (70% vs. 14%; *P* < 0.001) and intraosseous cysts at the sites of the ligament attachment to the bones (63% vs. 8%; *P* < 0.001) were significantly more common in the mucoïd degeneration versus the tear group, respectively. ACL thickening was found in all knees with mucoïd degeneration, however was uncommon in patients with the tear (100% vs.14%; *P* < 0.001) (**Table 1**). The mean values, optimum thresholds, and ROC analysis results of the angles can be found in **Table 2** and **Figure 4**.

Discussion

In the present study, discontinuity of the ACL was a useful finding for differentiating a tear from mucoïd degeneration. The high signal intensity on fat-suppressed PD-weighted images was seen in all tear and mucoïd degeneration cases in our study. ACL and Blumensaat angles are objective tests for evaluating the horizontal displacement of the distal ligament. It has been reported the mean ACL

Table 1: The MR findings in ACL tear and mucoïd degeneration groups.

	ACL tear group (n = 37) (%)	ACL mucoïd degeneration group (n = 43) (%)	<i>P</i> value
Discontinuity	36 (97)	0 (0)	<0.001
ACL with high signal on fat-sat PDW images	37 (100)	43 (100)	–
The lateral bone contusions	24 (65)	1 (2)	<0.001
>1.5 mm of deep lateral femoral notch	8 (22)	0 (0)	0.001
>5 mm of anterior tibial translation	26 (70)	6 (14)	<0.001
Uncovered meniscus sign	17 (46)	3 (7)	<0.001
Effusion	25 (68)	23 (54)	0.292
Segond fracture	0 (0)	0 (0)	–
Celery stalk appearance	0 (0)	28 (66)	<0.001
Thickening	7 (19)	43 (100)	<0.001
Ill-defined ACL	20 (54)	43(100)	<0.001
Ganglion cyst associated with the ACL	5 (14)	30 (70)	<0.001
Intraosseous cyst	3 (8)	27 (63)	<0.001
Bone marrow edema at the ACL attachment	6 (17)	10 (23)	0.657

Table 2: Results of the ACL, Blumensaat, and PCL angles.

	ACL mucoïd degeneration (mean ± SD)	ACL tear (mean ± SD)	The optimum Cutoff*	Sensitivity*% (95% CI)	Specificity*% (95% CI)
ACL angle	45.1° ± 7.9°	32° ± 7.1°	≤36°	78.3 (61.8–90.2)	90.7 (77.9–97.4)
Blumensaat angle	6.4° ± 8.5°	19.8° ± 9.4°	>11°	83.8 (68–93.8)	81.4 (66.6–91.6)
PCL angle	111.9° ± 12.5°	92.3° ± 21°	≤96°	64.8 (47.5–79.8)	90.7 (77.9–97.4)

* To predict torn ACL.

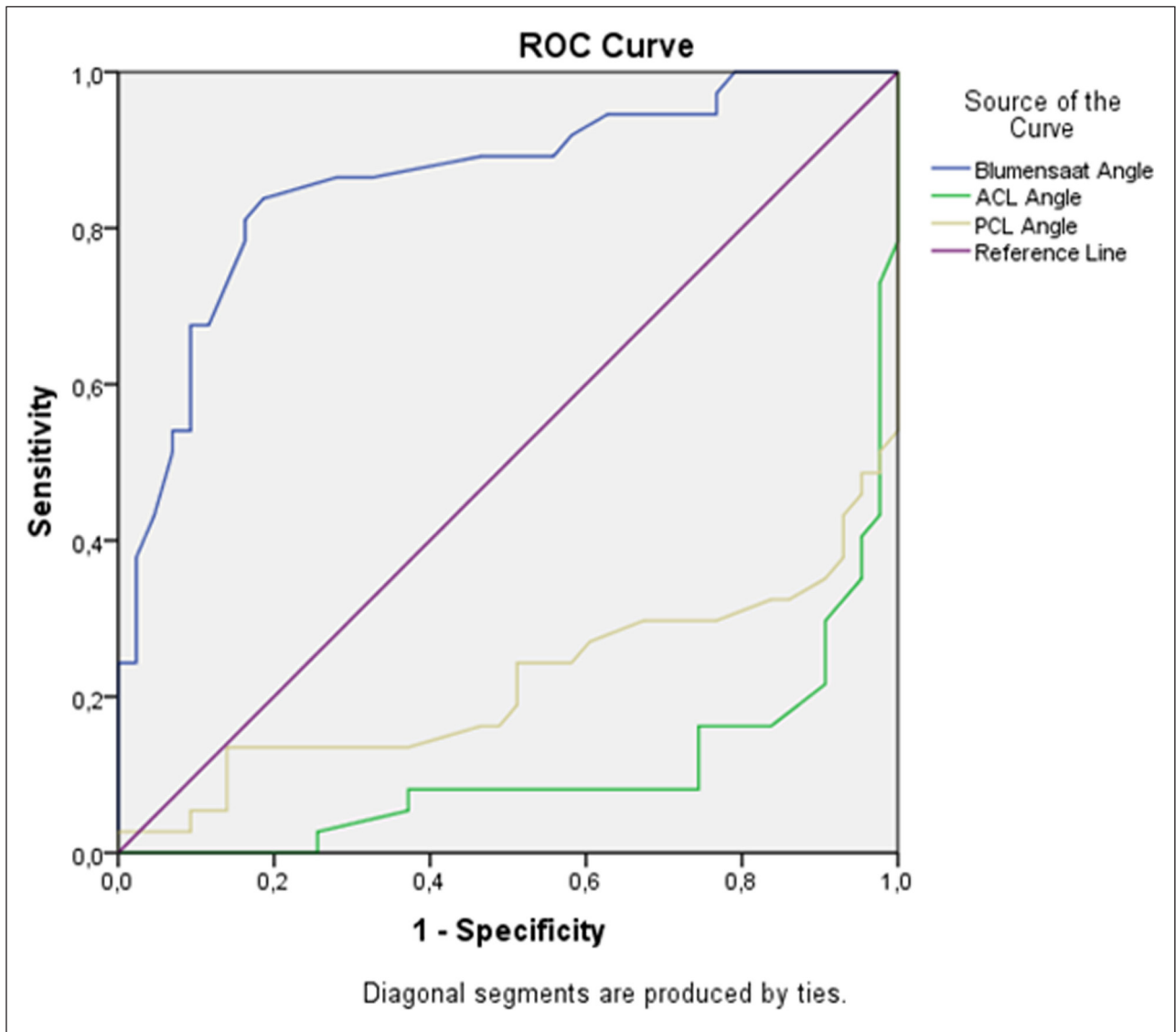


Figure 4: ROC curves for ACL, Blumensaat, and PCL angles. Areas under the curves (AUC) were 0.894 for the ACL angle, 0.861 for the Blumensaat angle, and 0.784 for the PCL angle.

and Blumensaat angles in patients with a torn ACL were 23.9°–33.9° and 21.4°–25.8°, respectively (Table 3) [3, 7, 10, 11]. In our study, the mean ACL and Blumensaat angles in the tear group were, respectively, 32° ± 7.1° and 19.8° ± 9.4°. These results were consistent with the previous studies. However, we observed that the mean ACL angle (45.1° ± 7.9°) in the mucoïd degeneration group was lower than that (52.3°–55.6°) in individuals with normal ACLs when compared with the previous studies (Table 3). Additionally, we found the mean Blumensaat angle in the mucoïd degeneration group was 6.4° ± 8.5°, although this angle has been reported to have slightly negative values in healthy individuals (Table 3). These results may be secondary to changes in the orientation due to mucoïd content within the ACL with mucoïd degeneration.

The previous studies have also indicated that an ACL angle less than 45° and Blumensaat angle greater than 0–9° were strongly associated with a tear (Table 3) [3, 7, 10, 11]. In the current study, there was some overlap in the reported threshold angles for the groups. We found that an ACL threshold angle of 36° or less produced 78.3%

sensitivity (95% CI: 61.8–90.2%) and 90.7% specificity (95% CI: 77.9–97.4%). Moreover, using a Blumensaat angle greater than 11° resulted in a sensitivity of 83.8% (95% CI: 68.0–93.8%) and 81.4% specificity (95% CI: 66.6–91.6%) in the differentiation of tears from mucoïd degeneration. They were useful for the differentiation in our study. However, the sensitivity and specificity observed for the ACL and Blumensaat angles were usually some lower than that reported for differentiating torn from normal ACLs (Table 3).

In the literature, the highest specificities of the secondary findings for ACL tears have been noted as a deep lateral femoral notch, bone contusions, an anterior tibial translation of 5 mm or more, and uncovering of the posterior horn of the lateral meniscus [2, 11, 15–17]. In our study, these signs were found to be useful for distinguishing tears from mucoïd degeneration. The PCL angle has been reported to be decreased in knees with a torn ACL [3, 7, 11, 17]. Results from those studies also indicate that using a threshold value of 105–115° for the PCL angle may be useful as a prediction of an ACL tear. The present

Table 3: Review of the literature for ACL, Blumensaat, and PCL angles.

	Gentili et al. (3)*	Lee et al. (7)*	Murao et al. (10)*	Mellado et al. (11)*	The current study ^a
Position of the knee on MRI examination	Full extension	Full extension	Full extension or slight flexion	—	Full extension
ACL angle					
Intact ACL	55.6°	—	52.3°	53.5°	45.1°
Torn ACL	29.9°	—	33.9°	25.9°	32°
Cutoff	<45°	—	≤45°	≤45°	≤36°
Sensitivity% (95% CI)	91	—	93	100 (92–100)	78 (62–90)
Specificity% (95% CI)	97	—	84	100 (92–100)	91 (78–97)
Blumensaat angle					
Intact ACL	−1.6°	−4.1°	—	−8.2°	6.4°
Torn ACL	25.8°	27.9°	—	21.4°	19.8°
Cutoff	>9°	>9°	—	>0°	>11°
Sensitivity% (95% CI)	91	94 (70–100)	—	90 (78–96)	84 (68–94)
Specificity% (95% CI)	86	96 (75–100)	—	98 (89–99)	81 (67–92)
PCL angle					
Intact ACL	123°	122°	—	128.9°	111.9°
Torn ACL	106°	105.7°	—	111.5°	92.3°
Cutoff	<107°	<114°	—	<115°	≤96°
Sensitivity% (95% CI)	52	74 (51–96)	—	70 (55–82)	65 (48–80)
Specificity% (95% CI)	94	71 (51–91)	—	82 (68–91)	91 (78–97)

* The studies about the distinction of ACL tear from intact ACL. Intact ACL refers to normal ACL.

^aThe current study. Intact ACL refers to mucoïd degeneration of the ACL.

— Not calculated or not available.

study determined that the optimum threshold PCL angle for differentiating ACL tears from mucoïd degeneration was 96° or less with 64.8% sensitivity (95% CI: 47.5–79.8%) and 90.7% specificity (95% CI: 77.9–97.4%) (Tables 2 and 3). However, the diagnostic performance of the PCL angle measurement was lower than that of the ACL angle.

The present study showed that a celery stalk appearance, ill-defined ACL, thickening, the ganglion cysts, and intraosseous cysts could be reliable MRI findings for distinguishing the mucoïd degeneration from the tear. This outcome was coherent with previous studies involving only cases of the mucoïd degeneration [20–23]. On the other hand, some studies have reported that diffuse thickening of the ACL is also an MRI finding suggestive of the tear [4, 5]. Herein, ACL thickening was rare in patients with the tear and more frequent with mucoïd degeneration (14% vs. 70%, respectively).

Our study had some limitations. First, this study was retrospective. Also, ACL mucoïd degeneration diagnoses were not confirmed arthroscopically or histologically. However, patients who had any suspicion of the ACL insufficiency at the physical examination in the hospital electronic medical records not included in the degeneration group. Another limitation is the knee joint position

in the MRI examination, which can affect the angle measurements, as mentioned by Guenoun et al. [29]. However, we routinely obtained all knee MRI examinations during full extension of the knee similar to most of the studies compared [3, 7, 10], but the position of the knee in the study by performed Mellado et al. [11] was not exactly stated. Finally, we did not evaluate intra- and interobserver variability.

Conclusion

In summary, the anterior tibial translation, uncovering of the lateral meniscus, and particularly the lateral bone contusions, a deep femoral notch can suggest a complete ACL tear, while ACL thickening, ill-defined ACL, ganglion cysts and intraosseous cysts at the ligament attachments can be helpful for the diagnosis of ACL mucoïd degeneration. More importantly, radiologists should be familiar with the celery stalk appearance in mucoïd degeneration of ACL and discontinuity in a torn ACL for differentiation. Measurement of the ACL angle, as well as Blumensaat and PCL angles, can be helpful in settings of diagnostic uncertainty.

Competing Interests

The authors have no competing interests to declare.

References

1. **Naraghi A, White LM.** MR Imaging of Cruciate Ligaments. *Magn Reson Imaging Clin N Am.* 2014; 22(4): 557–580. DOI: <https://doi.org/10.1016/j.mric.2014.07.003>
2. **Mohankumar R, Naraghi AM.** Magnetic Resonance Imaging for the Diagnosis and Treatment of Anterior Cruciate Ligament Tears. In: Prodromos C (ed.), *The Anterior Cruciate Ligament: Reconstruction and Basic Science.* 2nd ed. Elsevier; 2018. DOI: <https://doi.org/10.1016/B978-0-323-38962-4.00010-2>
3. **Gentili A, Seeger LL, Yao L, Do HM.** Anterior cruciate ligament tear: indirect signs at MR imaging. *Radiology.* 1994; 193(3): 835–840. DOI: <https://doi.org/10.1148/radiology.193.3.7972834>
4. **Robertson PL, Schweitzer ME, Bartolozzi AR, Ugoni A.** Anterior cruciate ligament tears: Evaluation of multiple signs with MR imaging. *Radiology.* 1994; 193(3): 829–834. DOI: <https://doi.org/10.1148/radiology.193.3.7972833>
5. **Barry KP, Mesgarzadeh M, Triolo J, Moyer R, Tehranzadeh J, Bonakdarpour A.** Accuracy of MRI patterns in evaluating anterior cruciate ligament tears. *Skeletal Radiol.* 1996; 25(4): 365–370. DOI: <https://doi.org/10.1007/s002560050096>
6. **Vahey TN, Meyer SF, Shelbourne KD, Klootwyk TE.** MR imaging of anterior cruciate ligament injuries. *Magn Reson Imaging Clin N Am.* 1994; 2(3): 365–380.
7. **Lee K, Siegel MJ, Lau DM, Hildebolt CF, Matava MJ.** Anterior cruciate ligament tears: MR imaging-based diagnosis in a pediatric population. *Radiology.* 1999; 213(3): 697–704. DOI: <https://doi.org/10.1148/radiology.213.3.r99dc26697>
8. **Klass D, Toms AP, Greenwood R, Hoppgood P.** MR imaging of acute anterior cruciate ligament injuries. *Knee.* 2007; 14(5): 339–347. DOI: <https://doi.org/10.1016/j.knee.2007.04.008>
9. **Chen WT, Shih TT, Tu HY, Chen RC, Shau WY.** Partial and complete tear of the anterior cruciate ligament. *Acta Radiol.* 2002; 43(5): 511–516. DOI: <https://doi.org/10.1258/rsmacta.43.5.511>
10. **Murao H, Morishita S, Nakajima M, Abe M.** Magnetic resonance imaging of anterior cruciate ligament (ACL) tears: Diagnostic value of ACL-tibial plateau angle. *J Orthop Sci.* 1998; 3(1): 10–17. DOI: <https://doi.org/10.1007/s007760050016>
11. **Mellado JM, Calmet J, Olona M, Gine J, Sauri A.** Magnetic resonance imaging of anterior cruciate ligament tears: Reevaluation of quantitative parameters and imaging findings including a simplified method for measuring the anterior cruciate ligament angle. *Knee Surg Sports Traumatol Arthrosc.* 2004; 12(3): 217–224. DOI: <https://doi.org/10.1007/s00167-003-0431-2>
12. **Schweitzer ME, Cervilla V, Kursunoglu-Brahme S, Resnick D.** The PCL line: An indirect sign of anterior cruciate ligament injury. *Clin Imaging.* 1992; 16(1): 43–48. DOI: [https://doi.org/10.1016/0899-7071\(92\)90090-V](https://doi.org/10.1016/0899-7071(92)90090-V)
13. **Cobby MJ, Schweitzer ME, Resnick D.** The deep lateral femoral notch: An indirect sign of a torn anterior cruciate ligament. *Radiology.* 1992; 184(3): 855–858. DOI: <https://doi.org/10.1148/radiology.184.3.1509079>
14. **Vahey TN, Hunt JE, Shelbourne KD.** Anterior translocation of the tibia at MR imaging: a secondary sign of anterior cruciate ligament tear. *Radiology.* 1993; 187(3): 817–819. DOI: <https://doi.org/10.1148/radiology.187.3.8497637>
15. **Chan WP, Peterfy C, Fritz RC, Genant HK.** MR diagnosis of complete tears of the anterior cruciate ligament of the knee: Importance of anterior subluxation of the tibia. *AJR Am J Roentgenol.* 1994; 162(2): 355–360. DOI: <https://doi.org/10.2214/ajr.162.2.8310927>
16. **Tung GA, Davis LM, Wiggins ME, Fadale PD.** Tears of the anterior cruciate ligament: Primary and secondary signs at MR imaging. *Radiology.* 1993; 188(3): 661–667. DOI: <https://doi.org/10.1148/radiology.188.3.8351329>
17. **McCauley TR, Moses M, Kier R, Lynch JK, Barton JW, Jokl P.** MR diagnosis of tears of anterior cruciate ligament of the knee: Importance of ancillary findings. *AJR Am J Roentgenol.* 1994; 162(1): 115–119. DOI: <https://doi.org/10.2214/ajr.162.1.8273648>
18. **Barrett G, Stokes D, White M.** Anterior cruciate ligament reconstruction in patients older than 40 years: Allograft versus autograft patellar tendon. *Am J Sports Med.* 2005; 33(10): 1505–1512. DOI: <https://doi.org/10.1177/0363546504274202>
19. **Legnani C, Terzaghi C, Borgo E, Ventura A.** Management of anterior cruciate ligament rupture in patients aged 40 years and older. *J Orthop Traumatol.* 2011; 12(4): 177–184. DOI: <https://doi.org/10.1007/s10195-011-0167-6>
20. **Bergin D, Morrison WB, Carrino JA, Nallamshetty SN, Bartolozzi AR.** Anterior cruciate ligament ganglia and mucoïd degeneration: Coexistence and clinical correlation. *AJR Am J Roentgenol.* 2004; 182(5): 1283–1287. DOI: <https://doi.org/10.2214/ajr.182.5.1821283>
21. **Fernandes JL, Viana SL, Mendonca JL, et al.** Mucoïd degeneration of the anterior cruciate ligament: Magnetic resonance imaging findings of an underdiagnosed entity. *Acta Radiol.* 2008; 01; 49(1): 75–79. DOI: <https://doi.org/10.1080/02841850701660497>
22. **Makino A, Pascual-Garrido C, Rolon A, Isola M, Muscolo DL.** Mucoïd degeneration of the anterior cruciate ligament: MRI, clinical, intraoperative, and histological findings. *Knee Surg Sports Traumatol Arthrosc.* 2011; 19(3): 408–411. DOI: <https://doi.org/10.1007/s00167-010-1239-5>
23. **Matrawy KA, El-Nekeidy AM, Al-Dawody A.** Mucoïd degeneration of the anterior cruciate ligament: Frequently under-diagnosed entity in MRI.

- Egypt J Radiol Nucl Med.* 2012; 43: 227–233. DOI: <https://doi.org/10.1016/j.ejnm.2012.03.002>
24. **Hovis KK, Alizai H, Tham SC**, et al. Non-traumatic anterior cruciate ligament abnormalities and their relationship to osteoarthritis using morphological grading and cartilage T2 relaxation times: Data from the Osteoarthritis Initiative (OAI). *Skeletal Radiol.* 2012; 41(11): 1435–1443. DOI: <https://doi.org/10.1007/s00256-012-1379-4>
25. **Kwee RM, Hafezi-Nejad N, Roemer FW**, et al. Association of Mucoïd Degeneration of the Anterior Cruciate Ligament at MR Imaging with Medial Tibiofemoral Osteoarthritis Progression at Radiography: Data from the Osteoarthritis Initiative. *Radiology.* 2018; 21: 171565. DOI: <https://doi.org/10.1148/radiol.2018171565>
26. **McIntyre J, Moelleken S, Tirman P.** Mucoïd degeneration of the anterior cruciate ligament mistaken for ligamentous tears. *Skeletal Radiol.* 2001; 30(6): 312–315. DOI: <https://doi.org/10.1007/s002560100336>
27. **Papadopoulou P.** The celery stalk sign. *Radiology.* 2007; 245(3): 916–917. DOI: <https://doi.org/10.1148/radiol.2453050159>
28. **Lintz F, Pujol N, Boisrenoult P, Bargoin K, Beaufls P, Dejour D.** Anterior cruciate ligament mucoïd degeneration: A review of the literature and management guidelines. *Knee Surg Sports Traumatol Arthrosc.* 2011; 19(8): 1326–1333. DOI: <https://doi.org/10.1007/s00167-011-1433-0>
29. **Guenoun D, Vaccaro J, Corroller T**, et al. A dynamic study of the anterior cruciate ligament of the knee using an open MRI. *Surg Radiol Anat.* 2017; 39: 307–314. DOI: <https://doi.org/10.1007/s00276-016-1730-x>

How to cite this article: Celikyay F, Yuksekkaya R, Bilgic E. A Retrospective Comparison of ACL Tear and Mucoïd Degeneration MRI Findings and an Emphasis on Evaluating of ACL, Blumensaat, and PCL Angles. *Journal of the Belgian Society of Radiology.* 2020; 104(1): 36, 1–8. DOI: <https://doi.org/10.5334/jbsr.1654>

Submitted: 16 September 2018

Accepted: 16 June 2020

Published: 03 July 2020

Copyright: © 2020 The Author(s). This is an open-access article distributed under the terms of the Creative Commons Attribution 4.0 International License (CC-BY 4.0), which permits unrestricted use, distribution, and reproduction in any medium, provided the original author and source are credited. See <http://creativecommons.org/licenses/by/4.0/>.



Journal of the Belgian Society of Radiology is a peer-reviewed open access journal published by Ubiquity Press.

OPEN ACCESS