




Wrist Arthroscopy in Athletes*

Artroscopia de punho em atletas

Edgard Novaes França Bisneto¹  Emygdio José Leomil de Paula¹ Rames Mattar Junior¹

¹ Orthopedics and Traumatology Department, Hospital das Clínicas, Faculdade de Medicina, Universidade de São Paulo, São Paulo, SP, Brazil

Address for correspondence Edgard de Novaes França Bisneto, MD, Departamento de Ortopedia e Traumatologia, Hospital das Clínicas, Faculdade de Medicina, Universidade de São Paulo (HCFMUSP), São Paulo, SP 01246-903, Brasil (e-mail: edgard.bisneto@hc.fm.usp.br).

Rev Bras Ortop 2020;55(1):1–7.

Abstract

Keywords

- ▶ arthroscopy/methods
- ▶ hand injuries/ diagnosis
- ▶ wrist injuries/ diagnosis
- ▶ athletic injuries

Arthroscopy is a surgical technique whose indication for wrist injuries has grown in recent years. Athletes are subject to traumatic injury to the wrist due to training overload or the intensity of the activity during competition.

The need of a quick return to sports practice makes arthroscopy a very useful minimally invasive technique in these situations. The authors present indications of sports-related injuries to the wrist that can be treated by arthroscopy. A literature review is also presented.

Resumo

Palavras-chave

- ▶ artroscopia/métodos
- ▶ traumatismos da mão/diagnóstico
- ▶ traumatismos do punho/diagnóstico
- ▶ traumatismos em atletas

A artroscopia é uma técnica cirúrgica que tem sido cada vez mais usada para a abordagem de lesões no punho. Atletas estão sujeitos a lesões traumáticas no punho devido à sobrecarga de treinamento ou à intensidade da atividade em competição.

A necessidade de retornar o mais breve possível à prática esportiva faz da artroscopia uma técnica minimamente invasiva muito útil nessas situações. Os autores apresentam as principais indicações de tratamento de lesões esportivas por artroscopia. Foi feita uma revisão da literatura.

Introduction

Traumatic wrist and hand injuries account for 3 to 9% of sports injuries; their incidence may reach 25%, depending on the sport practiced.^{1,2} These numbers refer not only to increased training intensity, but also to the increase of practitioners of higher impact sports activities.²

For athletes, the treatment of the injury is as important as the time to return to training, for which the decision-making process relies on the sport modality, injury, and individual health conditions.³ In injuries affecting professional athletes, ethical considerations, career duration and individual safety are also assessed.³

There are several painful syndromes affecting the wrist of athletes, including the following^{4–7}:

- fractures of the distal end of the radius, the scaphoid, the hamate, and the pisiform;
- transient or permanent traumatic epiphysiodesis;

* Study developed at the Orthopedics and Traumatology Department, Hospital das Clínicas, Faculdade de Medicina, Universidade de São Paulo (HCFMUSP), São Paulo, SP, Brazil. Originally Published by Elsevier Editora Ltda.

received
November 10, 2017
accepted
December 7, 2017

DOI <https://doi.org/10.1016/j.rbo.2017.12.022>.
ISSN 0102-3616.

Copyright © 2020 by Sociedade Brasileira de Ortopedia e Traumatologia. Published by Thieme Revinter Publicações Ltda, Rio de Janeiro, Brazil

License terms



- post-traumatic chondral lesions;
- synovitis (dorsal wrist impingement syndrome);
- ligament, scapho-lunate ligament and triangular fibrocartilage complex injuries;
- hamate hook pseudoarthrosis;
- tendinopathy or dislocations of the extensor carpi ulnaris tendon;
- degeneration of the triangular fibrocartilage complex due to impingement.

Wrist arthroscopy is increasingly used both in the diagnosis and in the treatment of sports-related traumatic wrist injuries, including in children and adolescents.⁸⁻¹²

The arthroscopic technique allows the diagnosis of various wrist changes not only by visualization, but also by palpation of the structures.

Arthroscopic treatment of these lesions is considered a minimally invasive technique with less damage to adjacent soft tissues.¹²

The present paper reviews some of these arthroscopically-treated traumatic wrist injuries.

Ligament Lesions

Intrinsic scapholunate ligament (SLIL) injuries occur within a range of severity following wrist hyperextension trauma associated with ulnar deviation and wrist supination.² Incomplete lesions are especially difficult to diagnose by imaging. Pain during dorsal palpation between the third and fourth extensor compartments, on SLIL projection, is a suggestive sign of injury.² The stability between the scaphoid and lunate ligaments is conferred by SLIL and a structural complex including the volar and dorsal extrinsic ligaments and the joint capsule, also referred to as the scapholunate ligament complex.¹³

Since incomplete ligament injuries do not change the carpal kinematics, image evaluation is difficult. Magnetic resonance imaging may demonstrate the lesion, but its sensitivity ranges from 86 to 91%, with 88 to 100% specificity.⁹ The European Wrist Arthroscopy Society (EWAS) proposes an arthroscopic classification for ligament injuries based on the Geissler classification.¹⁴⁻¹⁶ Both classifications use parameters from the midcarpal portals to evaluate scapholunate interosseous ligament injuries (►Table 1).

Although the Geissler classification is more widespread, the EWAS classification subdivides type III lesions and proposes a differentiated treatment for each subtype; type IIIA is a lesion of the volar portion of the scapholunate ligament, whereas IIIB refers to the dorsal portion, and IIIC, to both portions.¹⁴ Types I, II and IV are equally correspondent to the Geissler classification, and type V is a complex static ligament injury with dorsiflexed instability of the intercalated segment (DISI) deformity.¹⁴

This author reports that pain arises only in loading or strengthening activities, which, for athletes, are their training or competitions. There is little or no pain in daily living activities.

Arthroscopic treatment, based on the Geissler classification, is indicated for types II and III, and consists of SLIL volar and dorsal debridement and subsequent fixation with

Table 1 Arthroscopic classification of ligament injuries¹⁶

Grade	Description
I	Attenuation or hemorrhage of the interosseous ligament seen from the radiocarpal space. There is no carpal alignment incongruence in the midcarpal space
II	Attenuation or hemorrhage of the interosseous ligament seen from the radiocarpal space. Carpal incongruence or step-off. A slight gap (smaller than the probe width) can be seen between the carpal bones
III	Carpal alignment incongruence or step-off seen from the radiocarpal and midcarpal space. The probe can be passed and rotated at a gap between the carpal bones
IV	Carpal alignment incongruence or step-off seen from the radiocarpal and midcarpal space. Gross instability with manipulation is noted. A 2.7-mm arthroscope can be seen through a gap between the carpal bones

Kirschner wires.^{15,16} Conservative treatment is recommended for type I lesions; for type IV lesions (complete ligament injury), although an arthroscopic treatment is described,^{17,18} several authors still recommend an open reconstruction (►Fig. 1).^{16,18,19}

Considering the EWAS classification, types IIIA and IIIB injuries can be respectively treated with volar ligament reinforcements or dorsal arthroscopic capsulodesis.¹¹

Literature on the clinical relevance of partial extrinsic ligaments injuries are lacking. ►Fig. 2 shows an acute partial lesion of the short radiolunate ligament treated with debridement and immobilization for 6 weeks in a male patient with a concomitant LIES lesion that warranted arthroscopy.

Radiocarpal joint visualized through the 3-4 portal. A) intact radioscapophcapitate (RSC) and long radiolunate (LRL) ligaments; B) partial lesion of the short radiolunate ligament; C) ligament after debridement.

Partial lesions of the lunotriquetral interosseous ligament are treated following the same principles applied in LIES injuries.¹²

Scaphoid Fracture and Pseudoarthrosis

Scaphoid fractures are the most common carpal fractures,² usually associated with falls over the extended hand. Scaphoid stress fractures may also result from repetitive wrist strain.²⁰⁻²³

Treatment of scaphoid fractures is still debatable.^{1,24} The literature shows no difference in surgical and conservative treatment outcomes for nondeviated or minimally deviated fractures.^{24,25} It is important to consider the evidence on scaphoid-trapezium or radiocarpal arthrosis in surgical cases undergoing retrograde or anterograde fixation with screws, respectively.^{24,25}

Recovery time is an important point for athletes. Some authors recommend surgical treatment to decrease immobilization time, leading to a faster return of wrist range of motion, even in fractures with no deviation.^{12,26,27} Other

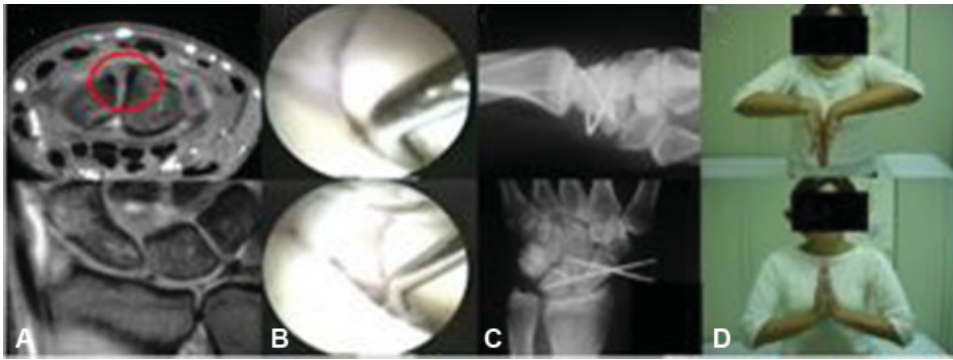


Fig. 1 Incomplete scapholunate ligament lesion (SLIL). (A) Nuclear magnetic resonance imaging shows the lesion at the dorsal region of SLIL; (B) Geissler type III lesion classified by probe-scope rotation at the radial midcarpal portal (MCR) and probe at the midcarpal ulnar portal (MCU); (C) carpus fixation for 6 weeks; (D) functional outcome.

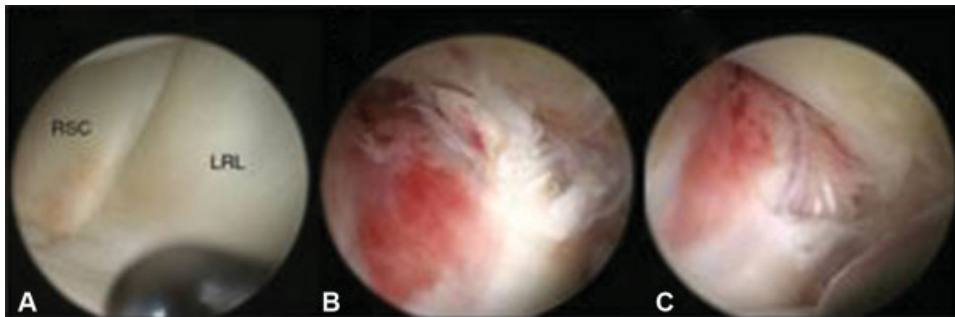


Fig. 2 Partial lesion of the short radiolunate ligament.

authors condition the type of treatment and return to training to the athletic modality involved.²⁸

The use of arthroscopy in the treatment of both acute fractures and pseudarthrosis has the advantage of less soft tissue aggression; in addition, it allows the assessment for concomitant wrist injuries (► **Fig. 3**).^{27,29-31}

Triangular Fibrocartilage Complex Lesions

Triangular fibrocartilage complex (TFCC) lesions are common in athletes and result from both acute trauma and overload.^{1,2,21,32} Triangular fibrocartilage complex lesions may or may not be associated with distal radioulnar (DRUJ)

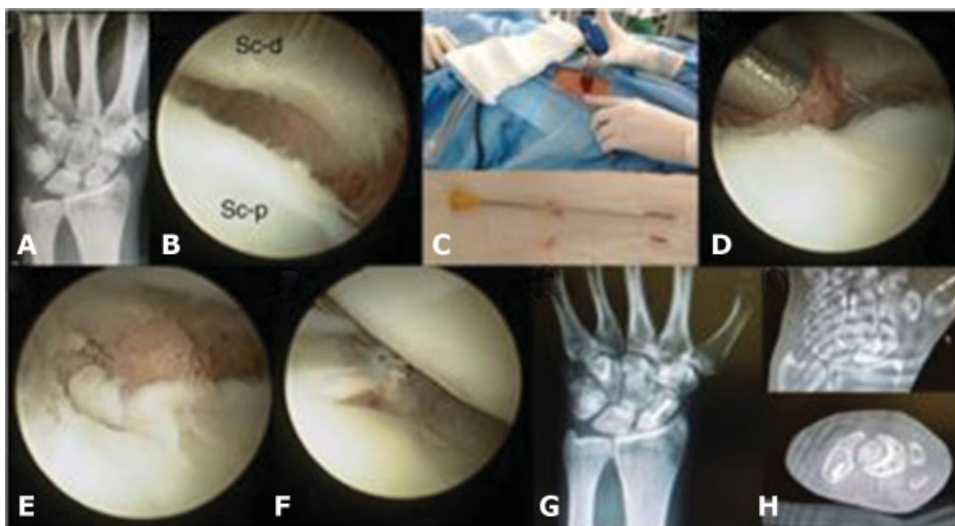


Fig. 3 Scaphoid pseudarthrosis. (A) Radiography showing scaphoid pseudarthrosis; (B), pseudarthrosis focus viewed through the radial midcarpal portal; (C) iliac graft removed with a biopsy needle; (D) graft placement through the radial midcarpal portal, with the scope at the midcarpal ulnar portal; (E) grafted pseudarthrosis focus; (F) view of the pseudarthrosis focus, impaction after placement of a cannulated screw through the radial midcarpal portal; (G) radiography performed 2 months after the procedure; (H) computed tomography performed 4 months after the procedure, showing consolidation. Abbreviations: Sc-d, distal scaphoid; Sc-p, proximal scaphoid.

	Class 1 = Repairable distal tear	Class 2 = Repairable complete tear	Class 3 = Repairable proximal tear	Class 4 = Non-repairable tear	Class 5 = Arthritic DRUJ
Clinical DRUJ instability	None/slight	Mild/severe	Intact	Severe	Mild/severe
Appearance of TFCC distal component (RC arthroscopy)	Torn	Torn	Intact	Torn	Variable
Status of TFCC proximal component (hook test/ DRUJ arthroscopy)	Intact	Torn	Torn	Torn	
Healing potential of TFCC tear's margins	Good	Good	Good	Poor	
Status of DRUJ cartilage	Good	Good	Good	Good	Poor
Treatment	Repair Suture (lig-to-capsule)	Repair Foveal refixation	Good	Reconstruction Tendon graft	Salvage Arthroplasty or joint replacement

Fig. 4 Atzei classification for Palmer type 1B triangular fibrocartilage complex lesions.³⁵

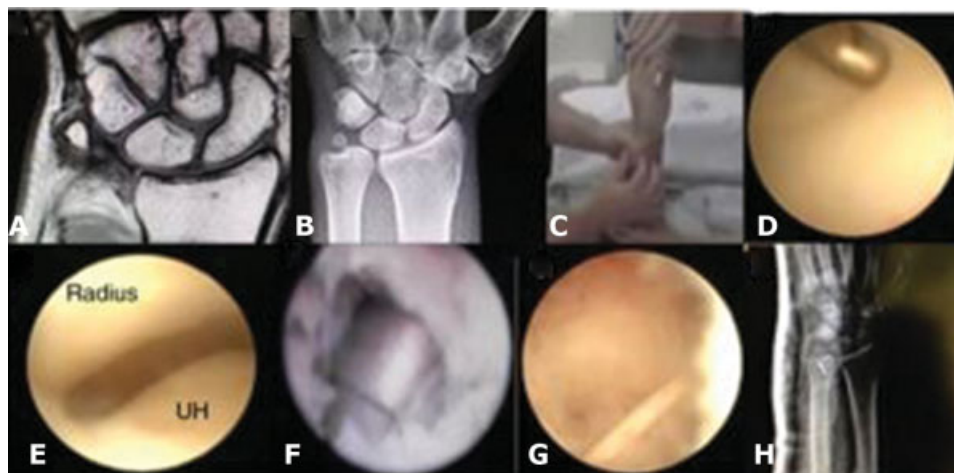


Fig. 5 Patient with an Atzei class 3 lesion. (A) Nuclear magnetic resonance imaging shows a lesion at the deep portion of the triangular fibrocartilage complex (TFCC); (B) radiography; (C) clinical assessment of distal radioulnar joint (DRUJ) instability; (D) the superficial portion of TFCC is intact when viewed at the 4-5 portal; (E) DRUJ instability evaluated through the distal dorsal radioulnar portal; (F) anchor placed at the ulnar head through the direct foveal portal; G, fibrocartilage suture viewed through the 4-5 portal; (H), postoperative radiography.

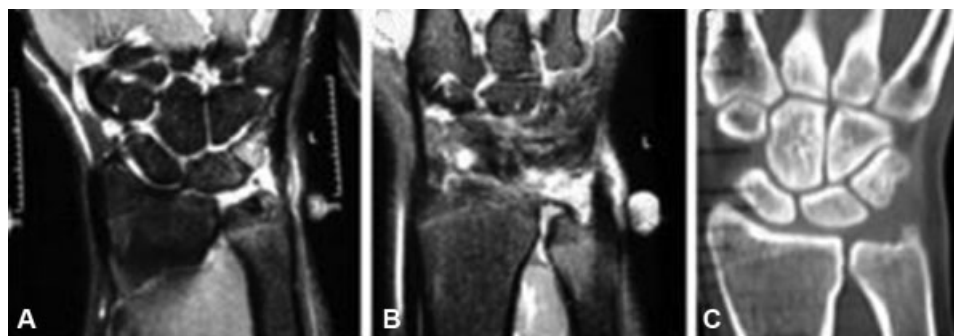


Fig. 6 Magnetic resonance and computed tomography imaging from a female patient previously submitted to a surgery at the triangular fibrocartilage complex (TFCC). She still complains of pain the ulnar border of the carpus.⁴¹ (A) magnetic resonance imaging shows synovitis and lunate and triquetrum edema; (B) the lesion affects only the distal portion of the triangular fibrocartilage; (C) computed tomography scan shows a neutral ulna.

joint instability.³² Distal radioulnar instability is related to TFCC avulsion from the radius or fovea, respectively classified as Palmer types ID or IB.¹² Type IB was subdivided into superficial and deep regions; DRUJ instabilities are

associated with the disinsertion of the deep foveal portion.^{33,34}

Triangular fibrocartilage complex lesions associated with DRUJ instability are surgically treated, whereas lesions of

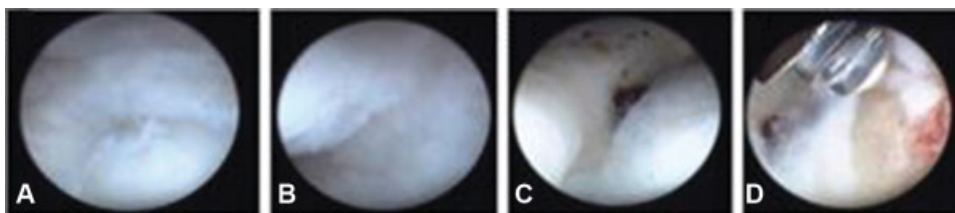


Fig. 7 Arthroscopic treatment of dynamic ulnocarpal impaction syndrome.⁴¹ (A) fibrocartilage lesion with ulna head exposure; (B) lunate chondral lesion; (C) during pronation, the ulnar head protrudes above the radial articular line; (D) arthroscopic wafer.

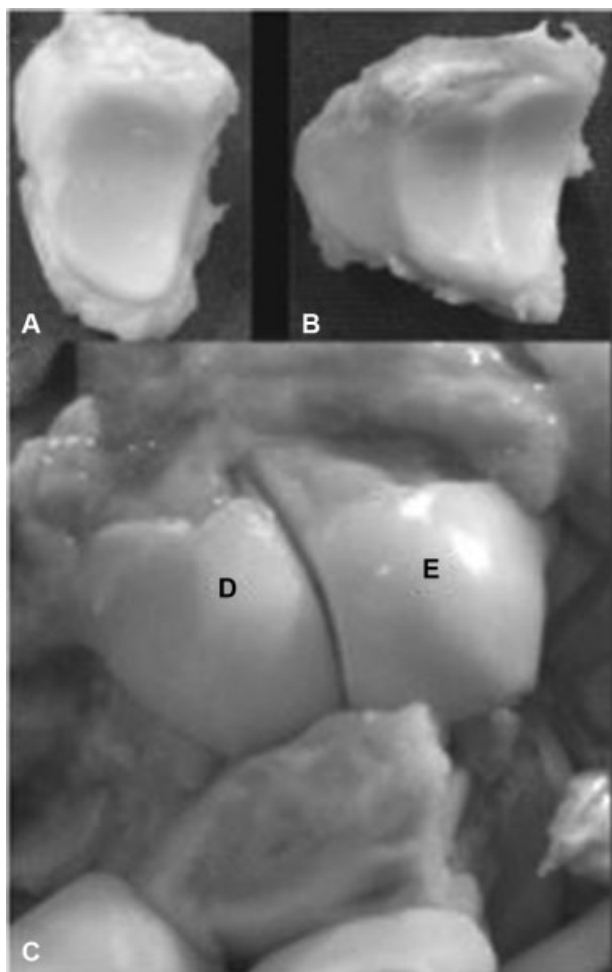


Fig. 8 Anatomical specimens show the difference between type I and type II lunate bones.⁴³ (A) type I lunate; (B) type II lunate, with two articular facets, one for capitate (D) and one for the hamate bone (E). C, type II lunate articulated with capitate (D) and hamate bones (E).

the distal/superficial portion, Atzei class 1, may initially be conservatively or surgically treated according to the symptomatology of the patient (►Fig. 4).^{1,2,21}

Several techniques for the arthroscopic treatment of TFCC lesions have been described, including fixation by a foveal bone tunnel,^{34,36} insertion with anchor³³ or suture at peripheral/superficial lesions.³⁷

►Figure 5 shows a case of distal radioulnar joint instability treated by arthroscopy using portals at this joint.

Dynamic Ulnocarpal Impaction

Ulnar Impaction Syndrome (UIS) is a degenerative lesion characterized by compression, or impaction, of the ulna head against the lunate and/or triquetrum, accompanied or not by a lesion at the triangular fibrocartilage complex.^{38–40}

It is usually associated with the presence of an ulnar-plus variant; however, UIS may also occur with ulnar-neutral or minus variants.⁴ Pronation relatively shortens the space between the radius and the ulna; in ulnar-neutral or minus variants with < 2 mm, the carpus and ulna head may collide, in a condition referred to as dynamic ulnocarpal impaction syndrome (DUIS).⁴

DUIS in ulnar-neutral or minus is described in pronation situations associated with grip strength, which is common in sports activities such as tennis or baseball.⁵

►Figures 6 and 7 show a case of arthroscopically treated DUIS.

Hamatolunate Impingement Syndrome

The association between the presence of this joint and the onset of midcarpal arthrosis in some patients has been referred to hamatolunate impingement syndrome (SISH).⁴² It is characterized by:

- Presence of a joint between the lunate and the hamate, a medial facet or a hamatolunate facet (FSH); (►Fig. 8)
- Cartilage erosion with subchondral bone exposure at the hamate proximal pole

Isolated arthrosis of the hamate proximal pole is related to the presence of a lunate medial facet.⁴³

►Figure 9 exemplifies a case of SISH.

Final Considerations

In athletes, whether professional or amateur, both traumatic and overtraining-related injuries are very common. These injuries prevent the practice of sports activities and should be individually assessed to indicate the best treatment, considering the age of the patient, the modality practiced and the intensity of this activity.

Although conservative treatment is indicated in several situations, surgery should be indicated in more severe injuries and/or failures; wrist arthroscopy provides a less aggressive approach to these conditions and may shorten the recovery time of these patients.

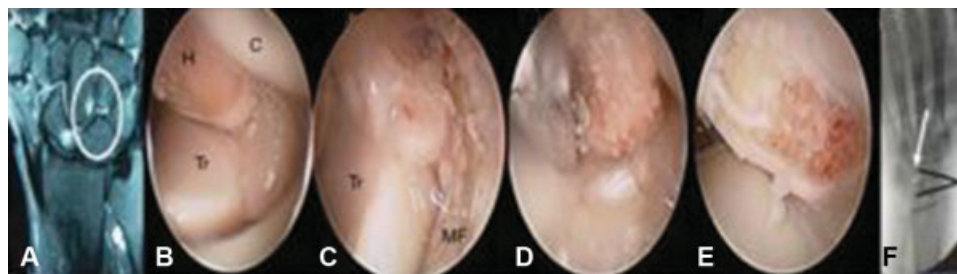


Fig. 9 Patient with hamatolunate impingement syndrome (SISH) submitted to arthroscopic debridement. (A) The circle shows; (B) lesion at the proximal hamate pole viewed through the radial midcarpal portal (MCR); (C) lunate medial facet with cartilage loss viewed through the MCR portal; (D) proximal hamate pole debridement; (E) view after debridement; (F) immediate postoperative period. The arrow shows the debridement site (note: the patient was also treated for a lesion at the intrinsic scapholunate ligament, which explains the presence of the Kirschner wires). H, hamate; Tr, triquetrum; C, capitate; MF, medial facet.

Conflict of Interests

The authors have no conflict of interests to declare.

References

- Fufa DT, Goldfarb CA. Sports injuries of the wrist. *Curr Rev Musculoskelet Med* 2013;6(01):35–40
- Avery DM 3rd, Rodner CM, Edgar CM. Sports-related wrist and hand injuries: a review. *J Orthop Surg Res* 2016;11(01):99
- Coppage JM, Carlson MG. Expediting professional athletes' return to competition. *Hand Clin* 2017;33(01):9–18
- Tomaino MM. Ulnar impaction syndrome in the ulnar negative and neutral wrist. Diagnosis and pathoanatomy. *J Hand Surg [Br]* 1998;23(06):754–757
- Baer DJ. Dynamic ulnar impaction syndrome in a collegiate baseball player. *IJATT* 2014;19(03):15–19
- Cornwall R. The painful wrist in the pediatric athlete. *J Pediatr Orthop* 2010;30(2, Suppl):S13–S16
- del Piñal F, Klausmeyer M, Thams C, Moraleda E, Galindo C. Arthroscopic resection arthroplasty for malunited intra-articular distal radius fractures. *J Hand Surg Am* 2012;37(12):2447–2455
- Jang E, Danoff JR, Rajfer RA, Rosenwasser MP. Revision wrist arthroscopy after failed primary arthroscopic treatment. *J Wrist Surg* 2014;3(01):30–36
- Obdeijn MC, Tuijthof GJ, van der Horst CM, Mathoulin C, Liverneaux P. Trends in wrist arthroscopy. *J Wrist Surg* 2013;2(03):239–246
- Farr S, Grill F, Girsch W. Wrist arthroscopy in children and adolescents: a single surgeon experience of thirty-four cases. *Int Orthop* 2012;36(06):1215–1220
- Slutsky DJ. Current innovations in wrist arthroscopy. *J Hand Surg Am* 2012;37(09):1932–1941
- Tosti R, Shin E. Wrist arthroscopy for athletic injuries. *Hand Clin* 2017;33(01):107–117
- Slutsky DJ. The scapholunate ligament complex (SLLC). *J Wrist Surg* 2013;2(02):97
- Messina JC, Van Overstraeten L, Luchetti R, Fairplay T, Mathoulin CL. The EWAS classification of scapholunate tears: an anatomical arthroscopic study. *J Wrist Surg* 2013;2(02):105–109
- Bednar JM. Acute scapholunate ligament injuries arthroscopic treatment. *Hand Clin* 2015;31(03):417–423
- Pappou IP, Basel J, Deal DN. Scapholunate ligament injuries: a review of current concepts. *Hand (N Y)* 2013;8(02):146–156
- Corella F, Del Cerro M, Ocampos M, Larrainzar-Garjito R. Arthroscopic ligamentoplasty of the dorsal and volar portions of the scapholunate ligament. *J Hand Surg Am* 2013;38(12):2466–2477
- Yao J, Zlotolow DA, Lee SK. ScaphoLunate axis method. *J Wrist Surg* 2016;5(01):59–66
- Morrell NT, Moyer A, Quinlan N, Shafritz AB. Scapholunate and perilunate injuries in the athlete. *Curr Rev Musculoskelet Med* 2017;10(01):45–52
- Kohring JM, Curtiss HM, Tyser AR. A scaphoid stress fracture in a female collegiate-level shot-putter and review of the literature. *Case Rep Orthop* 2016;2016:8098657
- Chen NC, Jupiter JB, Jebson PJJ. Sports-related wrist injuries in adults. *Sports Health* 2009;1(06):469–477
- Kohyama S, Kanamori A, Tanaka T, Hara Y, Yamazaki M. Stress fracture of the scaphoid in an elite junior tennis player: a case report and review of the literature. *J Med Case Reports* 2016;10:8
- Johnson MR, Fogarty BT, Alitz C, Gerber JP. Non-FOOSH scaphoid fractures in young athletes: a case series and short clinical review. *Sports Health* 2013;5(02):183–185
- Jakabfy BI, Jaén TF. Acute fractures of the carpal scaphoid – Literature review. *MOJ Orthop Rheumatol* 2016;5(05):1–9
- Clementson M, Jørgsholm P, Besjakov J, Thomsen N, Björkman A. Conservative treatment versus arthroscopic – Assisted screw fixation of scaphoid waist fractures – A randomized trial with minimum 4-year follow-up. *J Hand Surg Am* 2015;40(07):1341–1348
- Arsalan-Werner A, Sauerbier M, Mehling IM. Current concepts for the treatment of acute scaphoid fractures. *Eur J Trauma Emerg Surg* 2016;42(01):3–10
- Geissler WB. Arthroscopic management of scaphoid fractures in athletes. *Hand Clin* 2009;25(03):359–369
- Winston MJ, Weiland AJ. Scaphoid fractures in the athlete. *Curr Rev Musculoskelet Med* 2017;10(01):38–44
- Fallah Y, Kamrani RS, Zanjani LO. Arthroscopic treatment of stable scaphoid nonunion. *J Orthop Spine Trauma*. 2015;1(01):e1774
- Cognet JM, Louis P, Martinache X, Schernberg F. Arthroscopic grafting of scaphoid nonunion - surgical technique and preliminary findings from 23 cases. *Hand Surg Rehabil* 2017;36(01):17–23
- Kim JP, Seo JB, Yoo JY, Lee JY. Arthroscopic management of chronic unstable scaphoid nonunions: effects on restoration of carpal alignment and recovery of wrist function. *Arthroscopy* 2015;31(03):460–469
- Henderson CJ, Kobayashi KM. Ulnar-sided wrist pain in the athlete. *Orthop Clin North Am* 2016;47(04):789–798
- Atzei A, Luchetti R, Braidotti F. Arthroscopic foveal repair of the triangular fibrocartilage complex. *J Wrist Surg* 2015;4(01):22–30
- Nakamura T, Sato K, Okazaki M, Toyama Y, Ikegami H. Repair of foveal detachment of the triangular fibrocartilage complex: open and arthroscopic transosseous techniques. *Hand Clin* 2011;27(03):281–290
- Kirchberger MC, Unglaub F, Mühldorfer-Fodor M, et al. Update TFCC: histology and pathology, classification, examination and diagnostics. *Arch Orthop Trauma Surg* 2015;135(03):427–437
- Tse WL, Lau SW, Wong WY, et al. Arthroscopic reconstruction of triangular fibrocartilage complex (TFCC) with tendon graft for chronic DRUJ instability. *Injury* 2013;44(03):386–390
- Wysocki RW, Richard MJ, Crowe MM, Leversedge FJ, Ruch DS. Arthroscopic treatment of peripheral triangular fibrocartilage

- complex tears with the deep fibers intact. *J Hand Surg Am* 2012; 37(03):509–516
- 38 Iwasaki N, Ishikawa J, Kato H, Minami M, Minami A. Factors affecting results of ulnar shortening for ulnar impaction syndrome. *Clin Orthop Relat Res* 2007;465(465):215–219
- 39 Loh YC, Van Den Abbeele K, Stanley JK, Trail IA. The results of ulnar shortening for ulnar impaction syndrome. *J Hand Surg [Br]* 1999; 24(03):316–320
- 40 Coggins CA. Imaging of ulnar-sided wrist pain. *Clin Sports Med* 2006;25(03):505–526
- 41 França Bisneto EN. Dynamic ulnar impaction syndrome in tennis players: report of two cases. *Rev Bras Ortop* 2017;52(05): 621–624
- 42 Thurston AJ, Stanley JK. Hamato-lunate impingement: an uncommon cause of ulnar-sided wrist pain. *Arthroscopy* 2000;16(05): 540–544
- 43 França Bisneto EN, Sousa BB, de Paula EJ, Mattar Júnior R, Zumiotti AV. Arthroscopic and macroscopic evaluation of the lunate medial facet. *Acta Ortop Bras* 2011;19(06):353–355