



Contents lists available at ScienceDirect

International Journal of Surgery Case Reports

journal homepage: www.casereports.com

A case of Right Hepatic Artery anterior to the common hepatic duct: A not so rare variation

Hani Bendib^{a,b,*}, Abdelkrim Anou^{a,b}

^a Department of General Surgery, Batna University Hospital, Algeria

^b Faculty of Medicine, Batna2 University, Algeria

ARTICLE INFO

Article history:

Received 22 January 2021

Received in revised form 15 February 2021

Accepted 15 February 2021

Available online 23 February 2021

Keywords:

Anatomic variations

Anterior course

Case report

Liver blood supply

Right hepatic artery

ABSTRACT

INTRODUCTION AND IMPORTANCE: The hepatic arteries may be subject to anatomical variations that can cause operating difficulties with a risk of iatrogenic vascular injuries. A perfect knowledge of anatomy is an essential prerequisite for both surgeons and interventional radiologists.

CASE PRESENTATION: During a duodenopancreatectomy for a pancreatic head tumor in a 46-year-old man, we observed an anatomical variation regarding the course of the right hepatic artery (RHA). Indeed, RHA arose from the proper hepatic artery (PHA) at the left edge of the hepatoduodenal ligament and instead of crossing the common hepatic duct (CHD) posteriorly which is the usual course, it passed overhead before ascending and finishing its course in the liver hilum.

CLINICAL DISCUSSION: Anatomical variations of the hepatic arteries can be explained by the partial or complete persistence of the fetal model. Variations in the RHA may concern its number, origin or route. A prebiliary course of the RHA has been described with a prevalence ranging from 15 to 25% depending on series. The high sensitivity of Multidetector Computed Tomographic Angiography (MCTA) allows performing a complete vascular mapping, which remains essential before any Hepato-Pancreato-Biliary (HPB) surgery.

CONCLUSION: This case confirms once again the frequency of anatomical variations of the hepatic arteries, and underlines the value of CT Angiography to detect them in order to best plan any HPB surgery, where RHA remains an essential anatomical landmark that all surgeons must keep in mind in order to avoid any unfortunate incidents.

© 2021 The Authors. Published by Elsevier Ltd on behalf of IJS Publishing Group Ltd. This is an open access article under the CC BY-NC-ND license (<http://creativecommons.org/licenses/by-nc-nd/4.0/>).

1. Introduction and importance

Modern surgery requires a good knowledge of anatomy; this is especially true when it comes to the liver and its vascularization [1]. Anatomical variations of the hepatic arteries within the small omentum can be a source of operating difficulties, and any ignorance about them can have serious consequences, particularly in HPB surgery [1]. The liver is a highly vascularized organ with a dual vascularization. The portal vein (PV) is responsible for 70% of the blood supply to the liver while the remaining 30% is delivered by the proper hepatic artery (PHA) [2]. Knowledge of this vascularization is all the more necessary since variations in the hepatic artery and its branches are not so rare [3]. Precisely, the development of liver transplantation has provided an ideal study model for liver's vascularization [4]. In 75% of cases, the common hepatic artery (CHA) arises from the celiac trunk (CT) by trifurcation, continues on the left edge of the hepatoduodenal ligament through the

PHA after giving rise to the gastroduodenal artery (GDA); distally, the PHA divides into right and left hepatic branches [4]. Usually, the RHA reaches the right edge of the hepatoduodenal ligament, crossing the common hepatic duct (CHD) posteriorly to finish its course in the liver hilum [4]. Contrary to the distribution of the different hepatic arteries, which were described in detail by Michels in 1955, their trajectory in relation to the extrahepatic biliary tract has been less so [5]. This paper reports a case of an unusual route of the RHA and highlights the importance of keeping this type of variation in mind. The work has been reported in line with the SCARE 2020 criteria [6].

2. Case presentation

A 46-year-old man without any particular history, was referred to our department for the management of a pancreatic tumor revealed by cholestatic jaundice. Contrast-enhanced computed tomography revealed a low-density tumor of 28 mm in diameter located in the pancreatic head. In addition, by performing a vascular mapping, we have noted anterior course of the RHA (Figs. 1, 2). The vascular reconstruction images did not show any other

* Corresponding author at: Department of General Surgery, Batna University Hospital, Faculty of Medicine, Batna2 University, Batna 05000, Algeria.
E-mail address: hanibendib@gmail.com (H. Bendib).

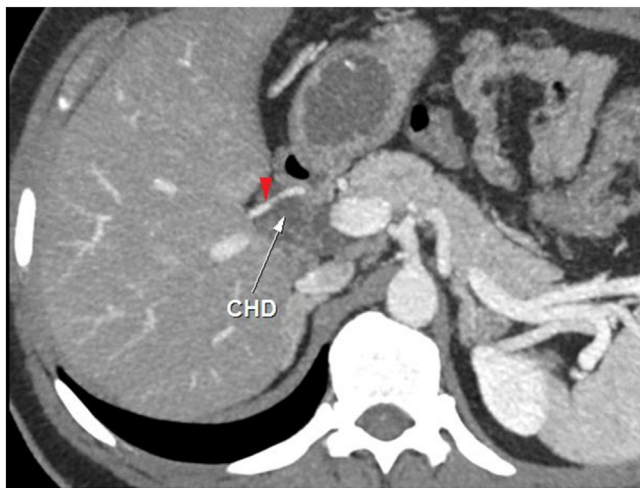


Fig. 1. CT Angiography: Axial cross-section showing RHA (red arrowhead) crossing the CHD anteriorly.

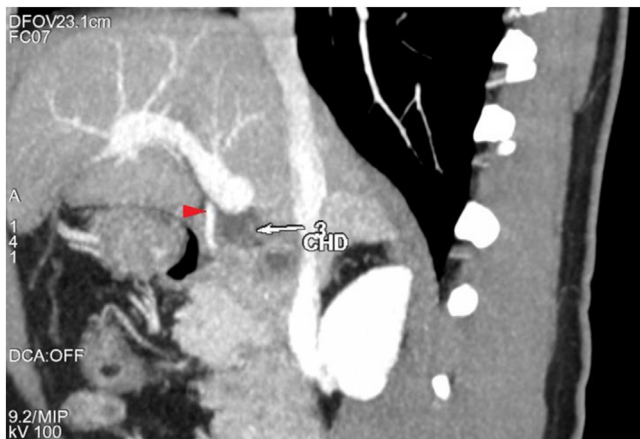


Fig. 2. CT Angiography: Sagittal cross-section showing RHA (red arrowhead) passing in front of the CHD.

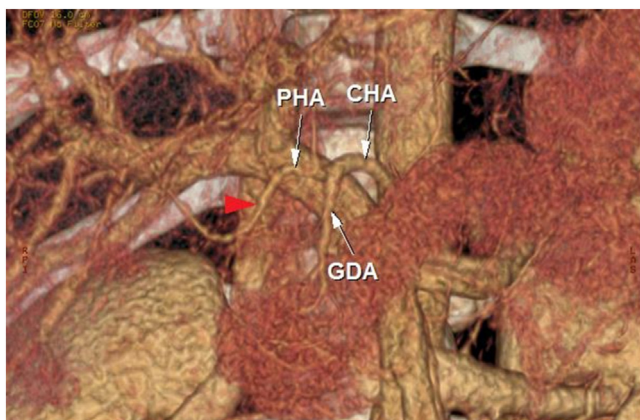


Fig. 3. Arterial reconstruction: RHA (red arrowhead) arising from a celiac PHA.

variations (Fig. 3). Pancreatoduodenectomy was planned; during lymph node dissection, we found celiac trunk (CT) trifurcated into left gastric artery (LGA), splenic artery (SA) and finally CHA. The latter continued by PHA and divided into right and left branches. The RHA, as described on the CT scan, then crossed the CHD anteriorly above the cystic duct junction to ascend along its right edge towards the hepatic hilum (Fig. 4). The dissection of the RHA was

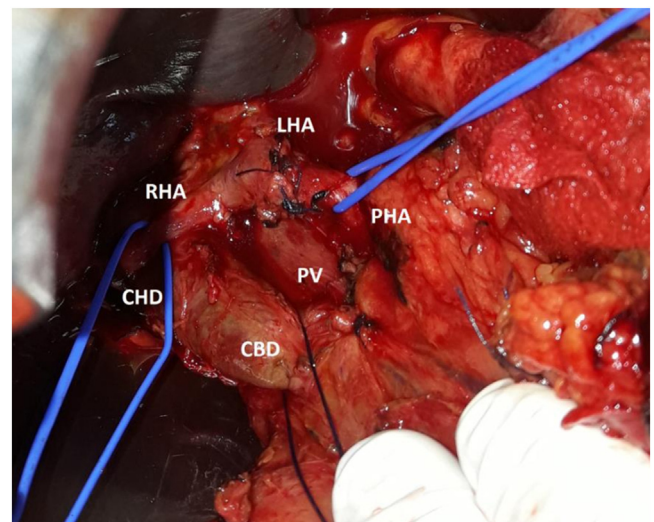


Fig. 4. Operative view showing the anterior course of the RHA.

safely completed without injury, allowing the section of the CHD; and subsequently, the hepatico-jejunal anastomosis. No other vascular abnormalities were noted and only RHA and LHA irrigated the liver. The postoperative follow-up was uneventful and the patient was discharged on the 8th postoperative day. The histological study revealed a pancreatic ductal adenocarcinoma.

3. Clinical discussion

Hepatic arteries and RHA in particular, can be subject to anatomical variations whose study is far from being abstract, knowing their impact on the risk of iatrogenic vascular injuries [2]. Therefore, a perfect knowledge of anatomy is an essential prerequisite for both HPB surgeons and interventional radiologists who have to practice new therapeutic approaches in liver malignancy, such as Transhepatic Arterial Chemoembolization and Hepatic Arterial Infusion Chemotherapy [3,7]. The variations in the hepatic artery are explained by the partial or complete persistence of the fetal model. Indeed, during the fetal period, the blood supply to the liver is mainly ensured by three arteries: CHA from the CT, LHA from left gastric artery (LGA) and RHA from superior mesenteric artery (SMA). The latter two atrophy progressively, and only the CHA with its branches will persist [8]. It is to Michels that we owe the first detailed description of the anatomical variations of the hepatic arteries based on 200 cadaveric dissections; published in 1966, this classification served as a reference for subsequent work [9]. In 1994, Hiatt et al. [4] published a new classification; less complex than the previous one, describing six types from a series of 1000 Orthotopic liver transplants (Appendix A).

Variations in the RHA can be related to its number, origin or route. A specific terminology is unanimously adopted to describe these variations. Thus, RHA is said to be accessory when it coexists with a PHA from which it does not originate, and it is said to be replaced when it alone provides blood supply to the right liver in the absence of a celiac PHA [3]. However, the qualifier accessory should be considered with great caution; since, according to Michels, the terminal and selective character of the hepatic arteries does not authorize any sacrifice at the risk of inducing necrosis of the tributary hepatic territory [8]. Apart from PHA, RHA can arise from right gastric artery, GDA, SMA, CT or directly from the aorta [8].

Several authors have described a prebiliary course of the RHA with a prevalence ranging from 15 to 25% depending on series [3]. From a series of 138 cadaveric dissections with arterial latex injec-

tion, Weiglein [1] observed RHA crossing the CHD anteriorly in 29% of cases. A recent study conducted at Mahatma Gandhi Medical College and Research Institute (India) on 60 embalmed adult cadavers showed that RHA had a posterior course in 86.6% of cases and anterior course in 8.3% of cases [3].

The association of more than one variation is not uncommon; it can be observed in 46% of cases, prompting greater vigilance [8]. Honma et al. [5] reported in a 91-year-old male, a RHA arising directly from CHA and passing over the CHD. In the present case, except for the abnormal course of the RHA, we found no other vascular abnormalities.

In addition, it is also important to know the relationship between hepatic arteries and bile ducts. It is thanks to the work of Northover and Terblanche [10] that we know better the arterial network around the bile ducts; thus, in a quarter of cases, the CHD receives its blood supply from the RHA. Consequently, any damage to both RHA and CHA can cause biliary ischemia that may compromise hepatico-jejunal anastomosis [11]. However, the existence of arterial shunts in the hepatic hilum may avoid right lobe ischemia despite RHA obstruction as long as the extra-hepatic bile ducts remain intact [12].

Moreover, in patients undergoing pancreatoduodenectomy, the presence of these variations does not seem to increase postoperative morbidity or the rate of R1 resection, even with a laparoscopic approach [11,13]. In our patient, the anterior course of the RHA was not an obstacle either for resection with negative margins or for reconstruction.

All these facts highlight the interest of carrying out a vascular mapping as complete as possible before any HPB surgery, in search of eventual anatomical variations. For many years, Digital Subtraction Angiography (DSA) was considered the test of choice for exploring the celiomesenteric axis [14]. Computed Tomographic Angiography has come to supplant conventional angiography due in particular to its performance and non-invasiveness. In a comparative study, Takahashi et al. [15] showed a high sensitivity of Multidetector Computed Tomographic Angiography (MCTA) in the visualization of small caliber hepatic arteries (100% for RHA and LHA). Other authors have demonstrated the usefulness of MCTA in the mapping and detection of vascular abnormalities, particularly in living donor liver transplantation [16,17].

4. Conclusion

This case confirms once again the frequency of anatomical variations of the hepatic arteries, and underlines the value of CT Angiography to detect them in order to best plan any HPB surgery, where RHA remains an essential anatomical landmark that all surgeons must keep in mind in order to avoid any unfortunate incidents.

Declaration of Competing Interest

Nothing to report.

Funding

Nothing to report.

Ethical approval

Not applicable.

Consent

Written informed consent was obtained from the patient for publication of this case report and accompanying images. A copy of the written consent is available for review by the Editor-in-Chief of this journal on request.

Author contribution

Hani Bendib collected the data, wrote and revised the manuscript for intellectual content.

Abdelkrim Anou revised the manuscript for intellectual content.

Registration of research studies

Not applicable.

Guarantor

Hani Bendib is the article guarantor.

Provenance and peer review

Not commissioned, externally peer reviewed.

Appendix A. Hepatic arterial anatomy in 1000 cases [4]

Type 1: Normal, n = 757

Type 2: Replaced (accessory) LHA from left gastric artery, n = 97

Type 3: Replaced (accessory) RHA from SMA, n = 106

Type 4: Double replaced LHA and RHA (Types 2 & 3), n = 23

Type 5: CHA from SMA, n = 15

Type 6: CHA from the aorta, n = 2

References

- [1] A.H. Weiglein, Variations and topography of the arteries in the lesser omentum in humans, *Clin. Anat.* 9 (1996) 143–150.
- [2] B.-G. Wang, R. Frober, Accessory extrahepatic arteries: Blood supply of a human liver by three arteries a case report with brief literature review, *Ann. Anat.* 191 (2009) 477–484.
- [3] N. Mugunthan, R. Kannan, C.F. Jebakani, J. Anbalagan, Variations in the origin and course of right hepatic artery and its surgical significance, *J. Clin. Diagn. Res.* 10 (2016) AC01–AC04.
- [4] J.R. Hiatt, J. Gabbay, R.W. Busuttill, Surgical anatomy of the hepatic arteries in 1000 cases, *Ann. Surg.* 220 (1994) 50–52.
- [5] S. Honma, W. Matsuda, M. Kudo, Right hepatic artery traveling anteriorly to the common bile duct, *Anat. Sci. Int.* 88 (2013) 93–96.
- [6] R.A. Agha, T. Franchi, C. Sohrabi, G. Mathew, for the SCARE Group, The SCARE 2020 guideline: updating consensus Surgical Case Report (SCARE) guidelines, *Int. J. Surg.* 84 (2020) 226–230.
- [7] K. Sangameswaran, K. Rajeswari, Study of aberrant hepatic arteries and its relevance in trans-arterial embolization therapy in hepatocellular carcinomas, *Int. J. Anat. Res.* 5 (2017) 4040–4045.
- [8] U. Dandekar, K. Dandekar, S. Chavan, Right hepatic artery: a cadaver investigation and its clinical significance, *Anat. Res. Int.* 2015 (2015).
- [9] F. Peschaud, M. El-Hajjam, R. Malafosse, D. Goere, S. Benoist, C. Penna, B. Nordlinger, A common hepatic artery passing in front of the portal vein, *Surg. Radiol. Anat.* 28 (2006) 202–205.
- [10] J.M.A. Northover, J. Terblanche, A new look at the arterial supply of the bile duct in man and its surgical implications, *Br. J. Surg.* 66 (1979) 379–384.
- [11] W. Zhang, K. Wang, S. Liu, Y. Wang, K. Liu, L. Meng, Q. Chen, B. Jia, Y. Liu, A single-center clinical study of hepatic artery variations in laparoscopic pancreaticoduodenectomy, *Medicine (Baltimore)* 99 (2020).
- [12] S.M. Strasberg, W.S. Helton, An analytical review of vasculobiliary injury in laparoscopic and open cholecystectomy, *HPB (Oxford)* 13 (2011) 1–14.
- [13] N. Alexakis, K. Bramis, K. Toutouzias, G. Zografos, M. Konstadoulakis, Variant hepatic arterial anatomy encountered during pancreatoduodenectomy does not influence postoperative outcomes or resection margin status: a matched pair analysis of 105 patients, *J. Surg. Oncol.* 119 (2019) 1122–1127.
- [14] A.M. Covey, L.A. Brody, M.A. Maluccio, G.I. Getrajdman, K.T. Brown, Variant hepatic arterial anatomy revisited: digital subtraction angiography performed in 600 patients, *Radiology* 224 (2002) 542–547.

- [15] S. Takahashi, T. Murakami, M. Takamura, T. Kim, M. Hori, Y. Narumi, H. Nakamura, M. Kudo, Multi-detector row helical CT angiography of hepatic vessels: depiction with dual-arterial phase acquisition during single breath hold, *Radiology* 222 (2002) 81–88.
- [16] C. Duran, S. Uraz, M. Kantarci, E. Ozturk, S. Doganay, M. Dayangac, M. Bozkurt, Y. Yuzer, Y. Tokat, Hepatic arterial mapping by multidetector computed tomographic angiography in living donor liver transplantation, *J. Comput. Assist. Tomogr.* 33 (2009) 618–625.
- [17] L. Saba, G. Mallarini, Anatomic variations of arterial liver vascularization: an analysis by using MDCTA, *Surg. Radiol. Anat.* 33 (2011) 559–568.

Open Access

This article is published Open Access at [sciencedirect.com](https://www.sciencedirect.com). It is distributed under the [IJSCR Supplemental terms and conditions](#), which permits unrestricted non commercial use, distribution, and reproduction in any medium, provided the original authors and source are credited.