



ELSEVIER

Contents lists available at [ScienceDirect](https://www.sciencedirect.com)

## Parasite Epidemiology and Control

journal homepage: [www.elsevier.com/locate/parepi](http://www.elsevier.com/locate/parepi)

## A review of human alveolar echinococcosis in the Republic of Armenia from 2008 to 2020

Ani Manukyan<sup>a,b,\*</sup>, Lilit Avetisyan<sup>a</sup>, Gayane Sahakyan<sup>a</sup>, Adela Paez Jimenez<sup>b</sup>, Lusine Paronyan<sup>a</sup>, Karine Gevorgyan<sup>a</sup>, Artavazd Vanyan<sup>a</sup>

<sup>a</sup> National Center for Disease Control and Prevention, MOH, Republic of Armenia

<sup>b</sup> Mediterranean and Black Sea Programme for Intervention Epidemiology Training (MediPIET), Madrid, Spain

### ARTICLE INFO

#### Keywords:

Alveolar echinococcosis  
*Echinococcus multilocularis*  
 Armenia  
 Registries  
 Biopsy

### ABSTRACT

**Background:** Since the 90s' *Echinococcus multilocularis* infection has expanded the geographical area and central-eastern European countries had seen first alveolar echinococcosis (AE) human cases. AE is considered to be a very rare disease in Europe with average incidences of 0.03–0.2/100,000 inhabitants/year. Because of a suitable orography, this study aims to confirm whether there are human AE cases in Armenia, identify areas at risk, and also estimate AE annual incidence.

**Methods:** Retrospective AE case finding was carried out at main multi-profile medical centers equipped with the modern diagnostic means. The medical records of all patients with liver surgery admitted between January 2008 and June 2020 were reviewed. A specific form was developed in EpiInfo v.7.2. Annual national incidence was estimated using population denominators provided by the National Institute of Statistics.

**Results:** Overall, 11 AE cases have been identified. All patients were diagnosed at advanced stages, with subsequent poor prognosis and costly treatment. Confirmation was based on tissue biopsy and medical imaging results. Age ranged from 12 to 58 years with a median of 33 yrs. Patients were from rural communities, mostly in the Gegharkunik region (6 cases, 55%). Annual average incidence of AE was 0.033/100,000 varying between 0.032 in 2008 and 0.1 in 2017.

**Conclusions:** There are human AE cases happening in Armenia since more a decade ago. In the absence of an AE surveillance system, the burden of AE disease is difficult to estimate. Development of national AE guidelines with a case definition should help enforcing registry of all cases, early diagnosis and also clinical and public awareness.

## 1. Introduction

### 1.1. About disease: Zoonosis, severe and rare but emerging

Alveolar echinococcosis (AE) is a severe zoonosis due to accidental ingestion of the tapeworm *Echinococcus multilocularis* (*E. multilocularis*) eggs, a helminth of the *Cestoda* class (Eckert et al., 2001; Baumann et al., 2019; Oksanen et al., 2016). Natural definitive hosts of *E. multilocularis* are usually wild or domestic carnivores like foxes (*Vulpes vulpes*), domestic dogs (*Canis lupus*)

\* Corresponding author: National Center for Disease Control and Prevention, Mkhitar Heratsi Str., 12 Building, 0025, Yerevan, Armenia.  
 E-mail address: [ani.ncdc@gmail.com](mailto:ani.ncdc@gmail.com) (A. Manukyan).

<https://doi.org/10.1016/j.parepi.2022.e00246>

Received 2 October 2021; Received in revised form 14 February 2022; Accepted 20 February 2022

Available online 26 February 2022

2405-6731/© 2022 The Author(s). Published by Elsevier Ltd on behalf of World Federation of Parasitologists. This is an open access article

under the CC BY-NC-ND license (<http://creativecommons.org/licenses/by-nc-nd/4.0/>).

*familiaris*), cats (*Felis catus*), which harbour the parasite adult stage in their small intestines. Small mammals, predominantly rodents (mainly rodents belonging to family *Arvicolinae*) are intermediate hosts with the larvae stage in their liver. Humans, domestic and wild pigs, monkeys are accidental (aberrant) intermediate hosts (Eckert et al., 2001; Kreidl et al., 1998; Kern et al., 2004; Baumann et al., 2019; Khan et al., 2021; Oksanen et al., 2016). Wild rodents are infected via water and plants contaminated with parasitic eggs that are excreted within faeces of the definitive hosts (Baumann et al., 2019; Torgerson et al., 2010). Humans are infected during hunting of wild animals, farming, ownership/close contact with cats or dogs, consumption of wild berries, mushrooms, raw produce from unfenced gardens or possibly water contaminated with the helminth eggs (Kreidl et al., 1998; Kern et al., 2004; Torgerson et al., 2010; Oksanen et al., 2016). Humans do not transmit the disease.

With an asymptomatic latency period of around 5–15 years, AE causes a liver tumor-like lesion with subsequent infiltrative and destructive growth or metastasis in the lungs, brain, bone and other organs. The fatality rate in untreated or inadequately treated persons is high (Eckert et al., 2001; Kern et al., 2003; Khan et al., 2021; Oksanen et al., 2016). Treatment of AE is difficult and costly. Early diagnosis and radical/curative operations, i.e. liver resections capable of totally removing the metacystode tissue from the liver, followed by prolonged anti-infective prophylaxis with albendazole is advised. In a country as expensive as Switzerland average cost per AE patient was estimated at 110,000€ in 2008 (Torgerson et al., 2008). In Armenia, most AE patients are diagnosed at an advanced stage of disease, requiring palliative surgery with poorer prognosis. According to the State Health Agency (Ministry of Health of the Republic of Armenia), such surgery can cost 320,000–600,000 AMD (600–1000€), approximately three times monthly average salary in Armenia.

World Health Organization (WHO) included AE as 1 of 20 neglected tropical diseases and *E. multilocularis* as the food-borne parasite with the third largest global impact of 24 ranked parasites (Baumann et al., 2019).

### 1.2. Situation in surrounding countries, including examples of incidence

In the Eastern Mediterranean region, Turkey and Iran have reported human AE cases. *E. multilocularis* is endemic in large regions of the Russian Federation and adjacent countries (Belarus, Moldova, Georgia, Armenia, Azerbaijan, Uzbekistan, Kazakhstan, Turkmenistan, Tajikistan, Kyrgyzstan) (Eckert et al., 2001; Baumann et al., 2019; Torgerson et al., 2010; Vuitton et al., 2015). Regions of China, Japan, North America (Canada, Alaska and other northern states of the USA) are also highly endemic for *E. multilocularis* (Baumann et al., 2019; Torgerson et al., 2010; Deplazes et al., 2017). In Europe until the 1990s, only a “core” area consisting of Eastern France, Southern Germany and parts of Switzerland and Austria were known to be endemic. More recently, both an increase of AE human cases in the endemic areas, namely Germany, Switzerland, Austria and France and an emergence in central-eastern and Baltic countries has been identified. Human AE cases have been diagnosed in countries previously considered free of the infection, such as Poland, Slovakia, Lithuania, Slovenia, Belgium, and Hungary (Kern et al., 2004; Vuitton et al., 2015; Piarroux et al., 2013; Oksanen et al., 2016). Highest incidence is found in Switzerland (0.1–0.18/100,000 inhabitants); average national incidences in endemic European countries tend to be 0.03–0.2/100,000 inhabitants/year. As the disease clusters in rural areas with very specific geographic and climatic conditions (generally mid-mountain areas with long cold winters and high rainfall), far higher incidences from 4.7–8.1 cases per 100,000/year are observed in the specific areas where humans are directly exposed to *E. multilocularis* (Vuitton et al., 2015). Such increase could be due to the improvement of diagnostic tools, or to an increase in the population of foxes and urbanization with more potential contact with humans and also to a possible increased involvement of pet animals as definitive infectious hosts (Khan et al., 2021).

Regarding animals, *E. multilocularis* has been documented in red foxes from 21 countries with the highest pooled prevalence (PP > 10%) in Czech Republic, Estonia, France, Germany, Latvia, Lithuania, Poland, Slovakia, Liechtenstein and Switzerland (seem to be concentrated in central and north-eastern Europe). Pooled prevalence results showed that sylvatic animals (red foxes, raccoon dogs, golden jackals, wolves) are more frequently infected than domestic species (dogs, cats) (Oksanen et al., 2016). Of interest, Serbia first recorded *E. multilocularis* in foxes and jackals in 2016 (Lalošević et al., 2016).

### 1.3. Situation in Armenia

In the Republic of Armenia, early serological studies on echinococcosis (without distinction between alveolar and cystic) in 1970–1980 showed 4.9% IgG positivity in rural populations and 2.3% in urban populations (Gevorgyan et al., 2016). The country was considered as AE-free. However, over the recent years, 3 surgical cases of AE were identified by surgeons in Gegharkunik region. In the absence of an appropriate echinococcosis surveillance system, none of them was reported as such.

In 2017–2018 within the framework of the German Joint Program, the research group of Molecular Parasitology, Scientific Center for Zoology and Hydroecology NAS RA studied the epidemiological status of *Echinococcus* spp. in free-ranging dogs and wild animals in target regions of Armenia by application of parasitological and molecular methods. Faecal samples were collected in 15 sampling spots in the regions Ararat, Shirak, Gegharkunik, Vayots Dzor, Syunik and Yerevan. A total of 51 faecal samples presumably from wolves, jackals, lynx, bears, leopards, boars, badgers, martens and 69 faecal samples of stray dogs have been collected. From 115 valid samples 2 contained taeniid eggs. From every single egg the deoxyribonucleic acid (DNA) was extracted and polymerase chain reaction (PCR) was conducted using published primers and following described protocols. To confirm the host species, restriction fragment length polymorphism (RFLP-PCR) of the cytochrome *b* (*cob*) gene was performed. Lynx and dog were determined as infected definitive hosts. Based on the results of egg DNA sequencing the following parasite species were recorded: in dog-*E. multilocularis*; in lynx-*Echinococcus canadensis*, *Taenia hydatigena*, *Taenia laticollis*. This is a first molecularly verified identification of these parasites in Armenia and early findings suggest the need for its regular monitoring (Gevorgyan et al., 2019).

## 2. Objectives of the study

The lack of AE morbidity data in human and animal populations has failed to alarm public health authorities in Armenia. However, the elevated cost in human, financial terms and the presumed range extension of the parasite in its sylvatic life cycle, call for a proper assessment of the AE epidemiology and its trends, granting the design of an appropriate surveillance scheme. A retrospective case-finding of human AE cases over the last decade was conducted to preliminarily identify areas at risk and also estimate AE annual incidence in Armenia. Findings will inform the design of a surveillance schema to (1) register AE cases in a standardized manner and (2) allow for prospective follow-up of each registered case.

## 3. Materials and methods

### 3.1. Study design, active case finding procedure and case definition

Retrospective AE case finding started with the pilot study in Gegharkunik region. This study included a review of the surgery registries at the main hospital, looking for AE cases, and interviews of surgeons and oncologists. Then, the study was carried out in the capital city Yerevan at main multi-profile medical centers (namely Erebouni MC, Armenia RMC, Arabkir MC, Izmirlian MC, Astghik MC, Central Clinical Military Hospital of RA) equipped with the most modern diagnostic means, where patients with serious medical condition are referred to from anywhere in the country. The medical records of all patients with liver surgery admitted between January 2008 and June 2020 were reviewed. Diagnosis of AE cases was confirmed if (a) positive histopathology and/or (b) typical liver lesion morphology identified by imaging techniques (ultrasonography, computed tomography (CT) scan, and magnetic resonance imaging (MRI)) with or without the detection of serum antibodies (serology). Of note, all eligible case-patients were included in the study, regardless of their country of residence and disease outcome. Confirmed cases were orally administered a questionnaire through a phone interview to gather detailed information on potential exposures: place of residence, occupation, profession, workplace location, any trips to an endemic location outside of Armenia, any agricultural activity (professional or leisure/part time), any farming activity (professional or leisure/part time), hunting, ownership and frequent contact with domestic animals, consumption of wild unwashed berries/raw vegetables, house/apartment with an unfenced garden and practice of any leisure outdoor activity. In addition, administrative and clinical data were obtained from the clinical records (diagnosis date, symptoms, list of examinations, medical and surgical history, preliminary/final diagnosis, location and number of the parasite-induced lesions, liver affected, surgery and drug treatment, occurrence and location of metastasis, any accompanying diseases, AE progression (number of surgeries), medical imaging, type of follow-up.

### 3.2. Data analysis

Annual national incidence was estimated for 2008–2020 using population denominators provided by the National Institute of Statistics. A specific form was developed in EpiInfo v7.2 for data entry and all patient data are kept in an Access database. Data analysis was done with STATA 16.0 software. Basic statistics were used to describe the demographic and clinical characteristics of the study participants. Descriptive analysis includes frequencies for categorical variables, means and standard deviations for continuous variables. Spatial presentation of AE cases was mapped using ArcGIS 10.7 software.

## 4. Results

The pilot study in Gegharkunik did not find any case, other than those treated at the hospitals in Yerevan. From 2008 to 2020, a total of 11 confirmed AE cases were identified, 10 (91%) out of them with hepatic damage and 1 (9%) with spinal damage. Of interest, only 3 cases corresponded to previous reported suspicions by surgeons; 8 cases were newly identified. All AE cases were confirmed based on positive histopathological examination and imaging techniques findings. A piece of liver or gallbladder affected lesion (biopsy) was taken for histological examination by microscope after staining with hematoxylin and eosin. A total of 10 cases (out of 11) could be reached and interviewed via phone (response rate = 91%). One patient was already outside of Armenia (in Russia) and that is why was not interviewed properly. Out of them 6 were females (55%). When the disease was diagnosed age of patients ranged from 12 to 58 years with a median of 33 yrs., a standard deviation of 14 yrs. and a mean of 35 yrs. (Table A.1).

The most common presenting symptoms were abdominal pain, general malaise, feeling of heaviness, discomfort, fatigue, dry mouth, dizziness, nausea, cholestatic jaundice (Fig. A.1).

Mean of annual AE incidence per 100,000 inhabitants over the entire study period was 0.033 (95%CI: 0.004–0.2); it varied between 0.032 (95%CI: 0.004–0.2) in 2008 and 0.1 (95%CI: 0.03–0.3) in 2017, the year with the highest AE annual incidence (Fig. A.2). For comparison, annual incidence in France (at country level) was 0.026/100,000 in 2008 (Charbonnier et al., 2014).

Regarding risk factors, a total of 7 (64%) AE cases mentioned contact with animals. This same proportion (7 cases, 64%) have conducted agricultural work. Also 6 cases (55%) have been in Russia for working purposes. All cases were residents in rural communities: 55% in Gegharkunik (6 cases), 18% in Shirak (2 cases), 18% case in Aragatsotn (2 cases) and 9% in Vayots Dzor (1 case) (Fig. A.3).

Some patients underwent surgery several times (4 times-9%; 2 times-18%; 1 time-64%; no surgery-9%). The liver was the first and most common organ to be affected. Involvement of other abdominal organs and tissues, right lung, spleen have been registered. Ultrasonography, CT scan were the most common imaging technologies for the diagnosis of AE and they revealed hepatomegaly, necrotic

foci, various sizes calcified lesion in the liver segments (Fig. A.4). Laparotomy, cholecystectomy, hepatectomy was done under general anesthesia (Fig. A.5). The patients were in the hospital for an average 1 month after the operation. After discharge, the patients were under control of a surgeon and gastroenterologist to continue further antiparasitic treatment.

## 5. Discussion

Armenia is an emerging endemic AE territory. Worldwide approximately 18,235 (CIs 11,900–28,200) new cases of AE are yearly diagnosed (91% occurring in China) with a burden of 666,433 DALYs per annum, comparable to several diseases included in the neglected tropical diseases cluster (Baumann et al., 2019; Torgerson et al., 2010; Piarroux et al., 2013). Over the last two decades, an increasing spread of AE and a rise in the number of cases has been documented, especially in western, northern and eastern Europe, as well as in central Asia. Still, data on AE infections are lacking in many parts of the world (Kern et al., 2003).

Indeed, little was known about animal and human AE in Armenia, although there is a geographical bridge between AE endemic countries in Asia and Europe and host suitable fauna, orography and climatic conditions for its spread. This study confirms a first AE case in 2008 and another 10 sporadic cases since then, affecting already four different regions of Armenia. With a total population of less than 3 million inhabitants, estimated annual incidence is high enough to rank Armenia as an emerging endemic AE country, varying from 0.03 cases per 100,000 inhabitants in 2008 to 0.1 in 2017. For comparison, in the so-called “endemic countries” of Europe AE incidence averages 0.03–0.2/100,000 inhabitants/year with a highest incidence 0.1–0.18/100,000 inhabitants/year found in Switzerland (Torgerson et al., 2010).

While this study sheds light on AE incidence, the real burden of disease could be higher. AE infection is not easily identified due to the long latency period and thus some infected individuals do not search care or only at a very advanced stage; it can also be misdiagnosed as cirrhosis, liver cavernous hemangioma, hepatic pus-filled cysts or liver malignant tumor. Correct diagnosis of the first AE case ever identified in Croatia (February 2020) took 2.5 years, because radiologic findings were inconsistent with cystic echinococcosis and clinicians assumed that was the only type of human echinococcosis in Croatia (Dušek et al., 2020).

Regarding risk factors, there were no significant differences by gender. Most AE patients were farmers, with cattle and pets. Of note, this profile reflects a majority of the Armenian population, which is involved in agriculture, farming and cattle-breeding, since the primary sector comprises the biggest part of the economy.

An alarming and interesting fact was the young age of several AE cases, compared to European cases. While a 54-year mean age was reported in Switzerland (Torgerson et al., 2008) (population median age is 43 years), the 35-year mean age in Armenia (median age of the population is 35.4 years) is closer to the 33-year found in study using surveillance data in Kyrgyzstan (Usubalieva et al., 2013), where authors explained it by their younger population pyramid (median age is 26 years). In our opinion, it could also indicate wide spread of infection in the environment or important role of domestic animals, like dogs, with risk exposures occurring already at early ages (Fig. A.6). A study in Lithuania has identified *E. multilocularis* in domestic dogs and pigs, suggesting that transmission is occurring in the rural environment in close vicinity to human populations (Šarkūnas et al., 2010). Indeed, only a few of our case-patients with domestic animals had them ever seen by a veterinarian (46%).

The findings of this study also called attention to AE cases in Armenia either diagnosed at very advanced stages, with poor prognosis and costly treatment, or incorrectly diagnosed and missed. In untreated or inadequately treated AE cases, mortality is >90% within 10 years of diagnosis (Torgerson et al., 2008). In Europe treatment has changed average life expectancy at diagnosis from 3 years in the 1970s to 20 years in 2005 (Torgerson et al., 2008). In addition to chemotherapy, early diagnosis, improved surgery, and medical care of the patients have contributed to this success. AE treatment should be planned in a multidisciplinary discussion, taking all elements of available pre-treatment imaging into account and patients should be referred to recognized national/regional AE treatment centers (Brunetti et al., 2010). However, the first step is raising clinicians' awareness to include alveolar echinococcosis in differential diagnosis of liver lesions, since a majority of them may assume that cystic echinococcosis is the only type of human echinococcosis in Armenia. Imaging provides the first-line approach to such a diagnosis and serology provides strong complementary support. This study also highlights the usefulness of analyzing archival biopsies to retrospectively diagnose alveolar echinococcosis.

In addition, confirmation of AE cases in Armenia points out the need for an AE surveillance system. Adoption of an AE case definition and development of national guidelines (based on the ones from the European Echinococcosis Registry) for the prospective registry of all AE cases should be a priority. Because some of the clinicians interviewed were convinced there is no AE in Armenia and also some patients complained about insufficient support to find treatment, AE awareness campaigns among clinicians and population potentially at risk should be implemented.

## 6. Conclusions

In conclusion, AE is an emerging, and so far silent, threat in Armenia. These findings should draw attention on the need to implement echinococcosis surveillance using a “One Health” approach, involving experts and institutions outside the medical community for integrated human and animal surveillance. Adopting a standardized human AE case definition is key and it should be distributed to all medical centers, including private clinics; all AE confirmed cases should be recorded and reported. For trend monitoring purposes, sentinel AE surveillance network of clinicians in high-risk areas could be established. Awareness among clinicians should be raised to allow for earlier diagnosis and treatment, as well as preventive measures among general population residing in affected areas. Regular deworming of domestic carnivores that have access to wild rodents should help to reduce the risk of infection in humans.

### Declaration of Competing Interest

The authors declare that they have no known competing financial interests or personal relationships that could have appeared to influence the work reported in this paper.

### Acknowledgments

NCDC Armenia thank the patients and MediPIET network for their support and immense contribution towards this work.

### Appendices

**Table A.1**  
Demographic characteristics of AE patients.

Demographic characteristics	Patients
	<i>N</i> = 11 n (%)
<b>Age (at time of diagnosis)</b>	
< 20	1 (9)
20–29	4 (36)
30–39	2 (18)
40–49	1 (9)
50–59	3 (27)
<b>Sex</b>	
Male	5 (45)
Female	6 (55)
<b>Education level</b>	
Secondary school	8 (73)
High school	2 (18)
Data not available	1 (9)
<b>Marital status</b>	
Single	1 (9)
Married	9 (82)
Data not available	1 (9)

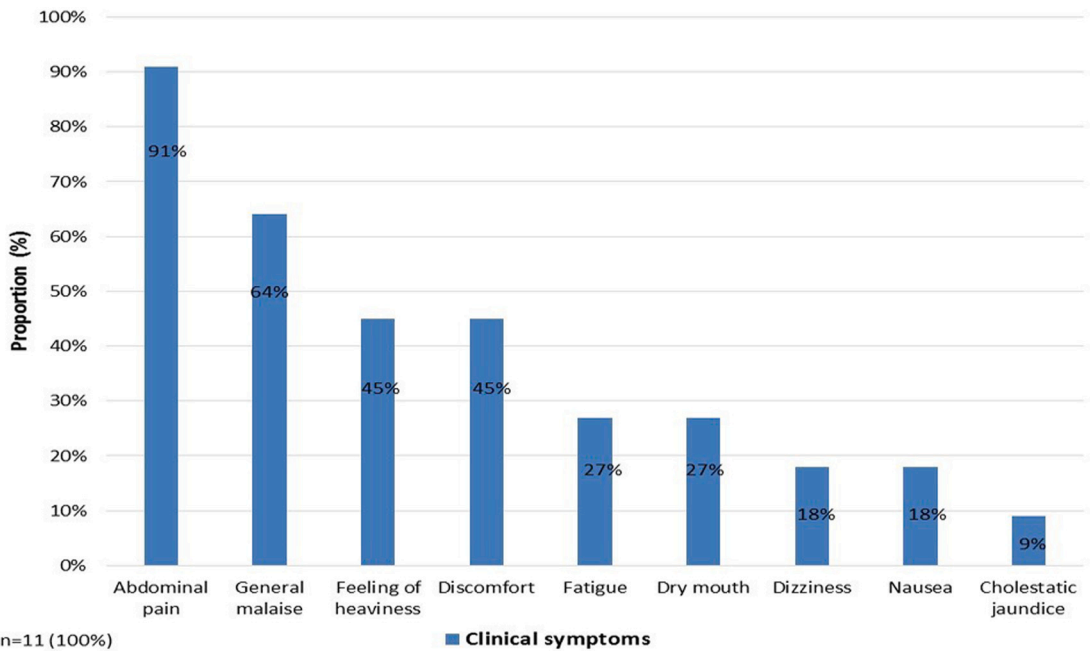


Fig. A.1. Presentation of clinical symptoms among AE cases identified in Armenia, 2008–2020.

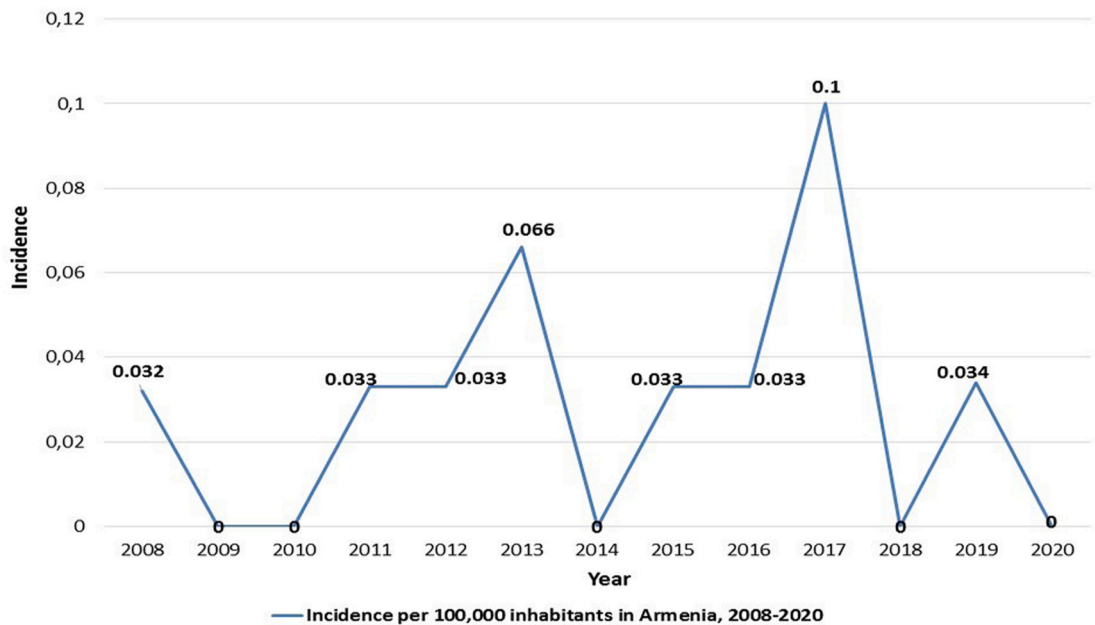


Fig. A.2. Cumulative incidence of AE cases per 100,000 inhabitants in Armenia, 2008–2020.



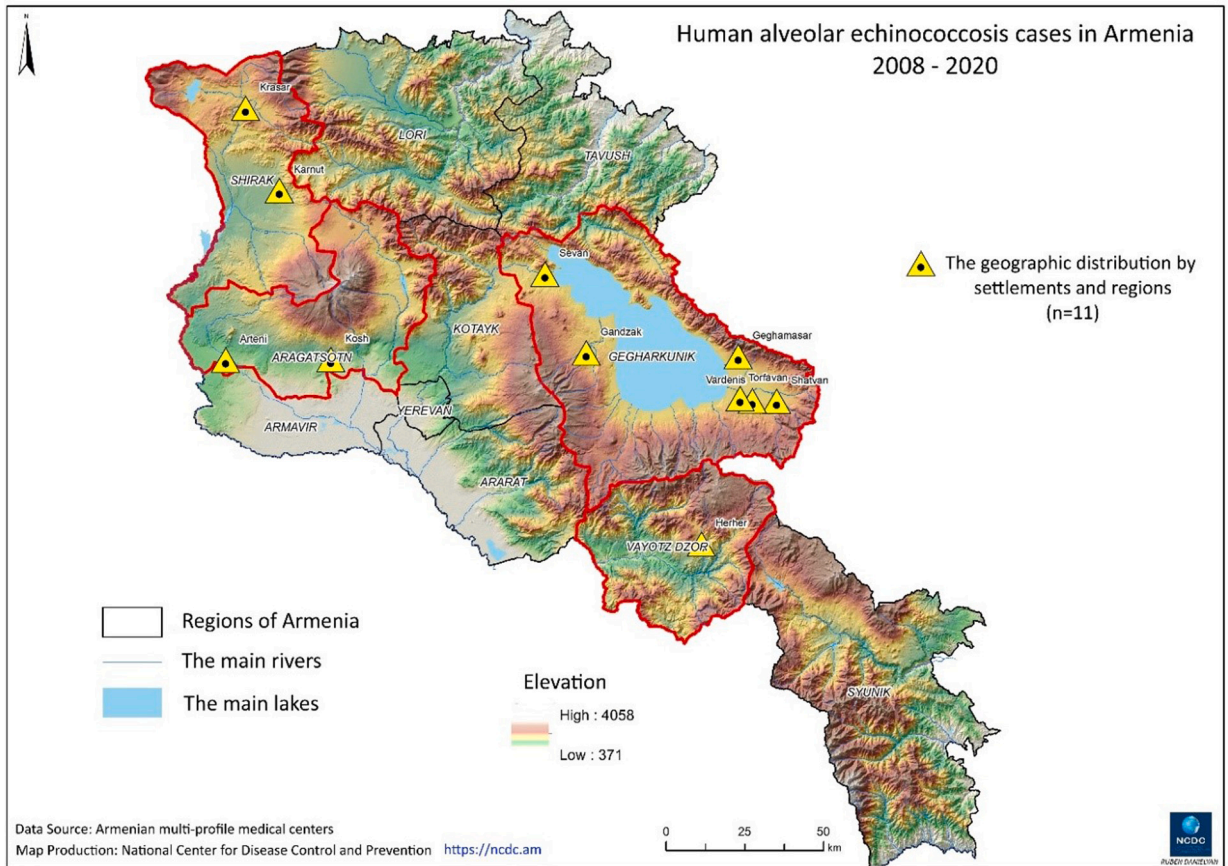


Fig. A.3. Spatial distribution of human AE cases in Armenia, 2008–2020.

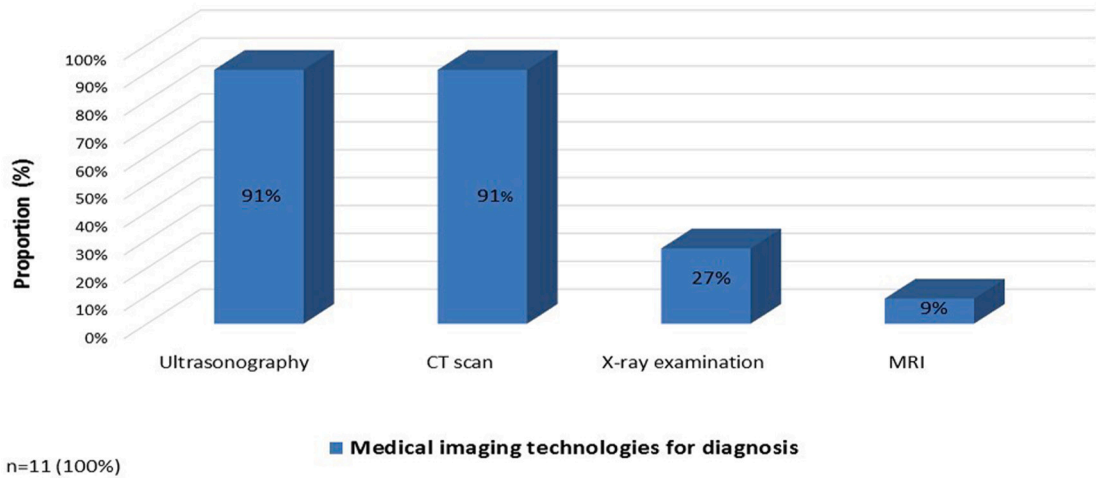
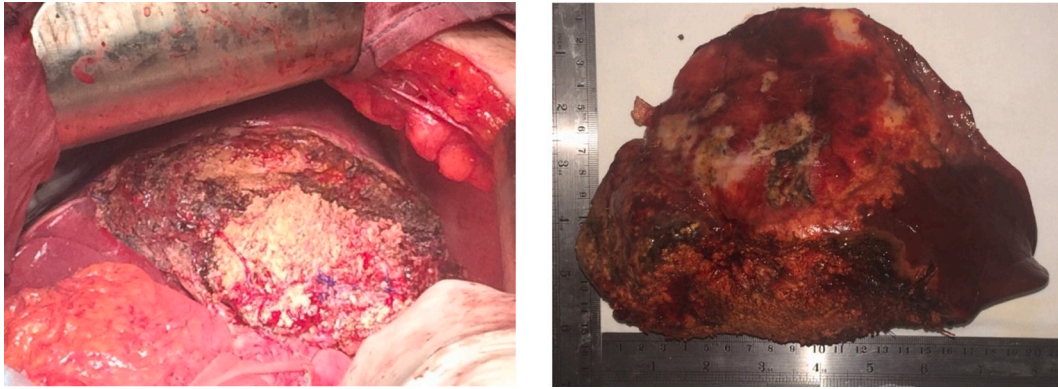
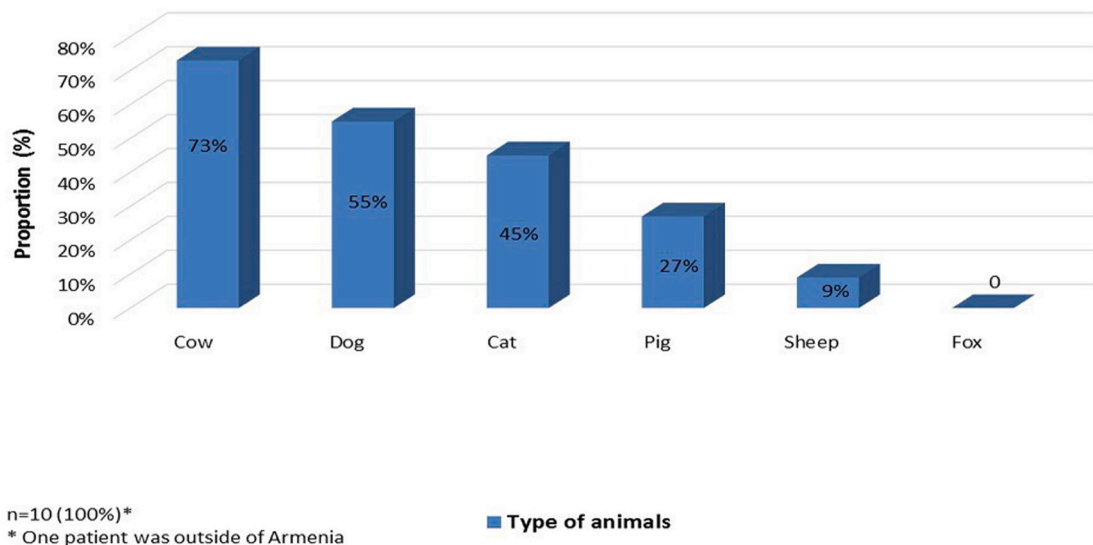


Fig. A.4. Common medical imaging technologies for the AE diagnosis.



**Fig. A.5.** Clinical picture by “Armenia” RMC surgical department. The team of surgeons performed alveococcosis surgery, removal of the left lobe of the liver, left hemihepatectomy with minimal blood loss.



**Fig. A.6.** Type of animals AE patients came in contact with. Patients were from rural communities, mostly involved in agricultural work.

## References

- Baumann, S., Shi, R., Liu, W., Bao, H., Schmidberger, J., Kratzer, W., Li, W., interdisciplinary Echinococcosis Working Group Ulm, 2019 Oct. Worldwide literature on epidemiology of human alveolar echinococcosis: a systematic review of research published in the twenty-first century. *Infection*. 47 (5), 703–727. <https://doi.org/10.1007/s15010-019-01325-2>. Epub 2019 May 30. Erratum in: *Infection*. 2022 Feb;50(1):287–288. PMID: 31147846; PMCID: PMC8505309.
- Brunetti, E., Kern, P., Vuitton, D.A., 2010 Apr. Writing panel for the WHO-IWGE. Expert consensus for the diagnosis and treatment of cystic and alveolar echinococcosis in humans. *Acta Trop*. 114 (1), 1–16. <https://doi.org/10.1016/j.actatropica.2009.11.001> (PMID: 19931502).
- Charbonnier, A., Knapp, J., Demonmerot, F., et al., 2014. A new data management system for the French National Registry of human alveolar echinococcosis cases. *Parasite*. 21, 69. <https://doi.org/10.1051/parasite/2014075>.
- Deplazes, P., Rinaldi, L., Alvarez Rojas, C.A., Torgerson, P.R., Harandi, M.F., Romig, T., Antolova, D., Schurer, J.M., Lahmar, S., Cringoli, G., Magambo, J., Thompson, R.C., Jenkins, E.J., 2017. Global distribution of alveolar and cystic echinococcosis. *Adv. Parasitol*. 95, 315–493. <https://doi.org/10.1016/bs.apar.2016.11.001>. Epub 2017 Jan 20. PMID: 28131365.
- Dušek, D., Vince, A., Kurelac, I., et al., 2020. Human Alveolar Echinococcosis. Croatia. *Emerg Infect Dis*. 26 (2), 364–366. <https://doi.org/10.3201/eid2602.181826>.
- Eckert, J., Gemmell, M.A., Meslin, F.X., Pawlowski, Z.S., World Health Organization, 2001. WHO/OIE Manual on Echinococcosis in Humans and Animals: A Public Health Problem of Global Concern / edited by J. Eckert ... [et al.]. World Organisation for Animal Health. <https://apps.who.int/iris/handle/10665/42427>.
- Gevorgyan, H., Aghayan, S., Malkhasyan, A., Atoyan, H., Asikyan, M., Wasserman, M., Mackenstedt, U., Th, Romig, March, 2019. Molecular Screening of Parasites in free-ranging dogs and wild animals in Armenia. *Current advances in pathogen research, Book of abstracts. FEBS*, p. 50.
- Kern, P., Bardonnnet, K., Renner, E., et al., 2003. European echinococcosis registry: human alveolar echinococcosis, Europe, 1982–2000. *Emerg. Infect. Dis*. 9 (3), 343–349. <https://doi.org/10.3201/eid0903.020341>.
- Gevorgyan, K., Paronyan, L., Vanyan, A., Keshishyan, A., 2016. Cross-sectional study on Echinococcosis in Aragacotn region of Armenia, 2014. *International Journal of Infectious Diseases* 53, 77–78. <https://doi.org/10.1016/j.ijid.2016.11.196>.
- Kern, P., Ammon, A., Kron, M., et al., 2004. Risk factors for alveolar echinococcosis in humans. *Emerg. Infect. Dis*. 10 (12), 2088–2093. <https://doi.org/10.3201/eid1012.030773>.



- Khan, A., Umhang, G., Ullah, Z., Boué, F., Bastid, V., Ullah, I., Mahmood, S., Afzal, M.S., Ahmed, H., 2021 Feb. Investigation of *Echinococcus multilocularis* in foxes and dogs in Pakistan by detection of copro-DNA. *Parasitol. Res.* 120 (2), 731–737. <https://doi.org/10.1007/s00436-020-07001-x>. Epub 2021 Jan 14. PMID: 33442815.
- Kreidl, P., Allerberger, F., Judmaier, G., Auer, H., Aspöck, H., Hall, A.J., 1998 May 15. Domestic pets as risk factors for alveolar hydatid disease in Austria. *Am. J. Epidemiol.* 147 (10), 978–981. <https://doi.org/10.1093/oxfordjournals.aje.a009388> (PMID: 9596476).
- Lalošević, D., Lalošević, V., Simin, V., et al., 2016. Spreading of multilocular echinococcosis in southern Europe: the first record in foxes and jackals in Serbia, Vojvodina Province. *Eur J Wildl Res* 62, 793–796. <https://doi.org/10.1007/s10344-016-1050-9>.
- Oksanen, A., Siles-Lucas, M., Karamon, J., et al., 2016. The geographical distribution and prevalence of *Echinococcus multilocularis* in animals in the European Union and adjacent countries: a systematic review and meta-analysis. *Parasites Vectors* 9, 519. <https://doi.org/10.1186/s13071-016-1746-4>.
- Piarroux, M., Piarroux, R., Knapp, J., et al., 2013. Populations at risk for alveolar echinococcosis, France. *Emerg Infect Dis.* 19 (5), 721–728. <https://doi.org/10.3201/eid1905.120867>.
- Šarkūnas, M., Bružinskaitė, R., Marcinkutė, A., et al., 2010. Emerging alveolar echinococcosis (AE) in humans and high prevalence of *Echinococcus multilocularis* in foxes and raccoon dogs in Lithuania. *Acta Vet. Scand.* 52, S11. <https://doi.org/10.1186/1751-0147-52-S1-S11>.
- Torgerson, P.R., Schweiger, A., Deplazes, P., Pohar, M., Reichen, J., Ammann, R.W., Tarr, P.E., Halkic, N., Müllhaupt, B., 2008 Jul. Alveolar echinococcosis: from a deadly disease to a well-controlled infection. Relative survival and economic analysis in Switzerland over the last 35 years. *J Hepatol.* 49 (1), 72–77. <https://doi.org/10.1016/j.jhep.2008.03.023>. Epub 2008 Apr 28. Erratum in: *J Hepatol.* 2018 Nov;69(5):1208. PMID: 18485517.
- Torgerson, P.R., Keller, K., Magnotta, M., Ragland, N., 2010. The global burden of alveolar echinococcosis. *PLoS Negl. Trop. Dis.* 4 (6), e722 <https://doi.org/10.1371/journal.pntd.0000722>.
- Usubalieva, J., Minbaeva, G., Ziadinov, I., Deplazes, P., Torgerson, P.R., 2013. Human alveolar echinococcosis in Kyrgyzstan [published correction appears in *Emerg Infect Dis.* 2014 Mar;20(3):516]. *Emerg. Infect. Dis.* 19 (7), 1095–1097. <https://doi.org/10.3201/eid1907.121405>.
- Vuitton, D.A., Demonmerot, F., Knapp, J., Richou, C., Grenouillet, F., Chauchet, A., Vuitton, L., Bresson-Hadni, S., Millon, L., 2015 Oct 30. Clinical epidemiology of human AE in Europe. *Vet. Parasitol.* 213 (3–4), 110–120. <https://doi.org/10.1016/j.vetpar.2015.07.036>. Epub 2015 Aug 20. PMID: 26346900.