

# Doppler waveform analysis during provocative manoeuvres in the assessment for arterial thoracic outlet syndrome results in high false-positive rates; a cross-sectional study

Lily Bishop<sup>1</sup>  and Matthew Bartlett<sup>2</sup>

## Abstract

**Objectives:** There is a high rate of false-positive arterial Thoracic Outlet Syndrome (ATOS) diagnoses due to limited research into the optimal use of ultrasound. To improve future diagnostic efficiency, we aimed to characterise the haemodynamic effects of different provocative positions and estimate the prevalence of compression in the healthy population.

**Design:** In this cross-sectional, observational study, the effect of varying degrees of arm abduction on discomfort levels and/or changes in subclavian artery Doppler waveform was analysed in the healthy population; the peak systolic velocity (PSV), systolic rise time (SRT), phasicity and extent of turbulence were recorded.

**Setting:** Department of the Vascular Studies, Royal Free Hospital.

**Participants:** 19 participants (11 females,  $27.4 \pm 5.2$  years) were recruited for bilateral scans.

**Main outcome measures:** Seven positions were investigated; the primary outcome was an occlusion or monophasic waveform indicating significant compression and this was compared with the secondary outcome; any physiological discomfort.

**Results:** 28.9% experienced significant arterial compression in at least one position;  $120^\circ$  abduction was the position with the greatest level of abduction that did not result in significant waveform changes or symptoms. The PSV and SRT were difficult to accurately measure and bore no correlation to the level of compression.

**Conclusion:** Ultrasound testing in isolation would result in a false indication of TOS in almost 30% of our normal population. With further research, the  $120^\circ$  abduction position may have a lower false-positive rate. The PSV and SRT must be interpreted with caution due to their variability even within the healthy population.

## Keywords

Thoracic outlet syndrome, diagnostic imaging, arterial waveform analysis, Doppler ultrasound

Date received: 5 February 2021; revised: 5 February 2021; accepted: 7 March 2021

## Introduction

Thoracic Outlet Syndrome (TOS) is a disorder which arises from abnormal compression of the structures passing through the thoracic outlet and often occurs in young and otherwise healthy individuals. The brachial plexus, subclavian vein and subclavian artery are those structures that can become compressed resulting in neurogenic TOS (NTOS), venous TOS (VTOS) and arterial TOS (ATOS), respectively. The thoracic outlet comprises three distinct compartments; the interscalene

<sup>1</sup>Department of Vascular Studies, Royal Free London NHS Foundation Trust, London, UK

<sup>2</sup>Department of Surgery & Interventional Medicine, University College London, London, UK

### Corresponding author:

Lily Bishop, Department of Vascular Studies, Royal Free Hospital, 6th Floor, Pond Street, London, NW3 2QG, UK.  
Email: lilybishop@nhs.net



triangle, the costoclavicular space and the pectoralis minor space. The precise location of neurovascular compression within the thoracic outlet determines the TOS subset and the accompanying signs and symptoms.<sup>1</sup> TOS can result from trauma, repetitive upper limb movements or congenital abnormalities, such as a cervical rib.<sup>2</sup> Thoracic anatomical variants appear to be relatively common, as described in a study on 50 cadavers which stated that only 10% had “normal” thoracic outlet anatomy bilaterally.<sup>3</sup>

The term TOS was first reported in literature in the 1950s<sup>4</sup> but remains a highly controversial condition due to the complexity of forming the diagnosis and the ensuing optimal management. Over 90% of TOS cases are NTOS, however our study focussed on ATOS; the most severe subtype which accounts for less than 1% of all TOS cases.<sup>5</sup> The Society of Vascular Surgery (SVS) defines ATOS as an objective abnormality of the subclavian artery caused by extrinsic compression and subsequent damage.<sup>6</sup> Subclavian artery compression at the interscalene triangle is considered responsible for ATOS, however the different subsets can possibly coexist which further complicates the issue.<sup>6</sup> The relative rarity of ATOS, combined with the fact that most patients are offered corrective surgery to reduce the compression, may explain the lack of large studies on ATOS patients.

Illig et al.<sup>6</sup> describe how ATOS may be asymptomatic, such as due to aneurysmal disease, or symptomatic, such as the onset of objective ischaemia during arm elevation. Typical chronic symptoms of upper limb ischaemia in ATOS include pain in the arm or hand with extreme exertion or arms overhead.<sup>6</sup> This is due to position-dependent geometric changes resulting in reduced blood flow into the affected limb. Additionally, the stress placed on the arterial wall can predispose it to serious sequelae, such as thrombosis and embolisation to the digital arteries.<sup>7</sup>

In order to diagnose ATOS, a thorough clinical history and physical examination must be taken. Doppler ultrasound imaging of the upper limb while the patient performs various provocative positions is a non-invasive, safe and cost-effective form of diagnostic imaging. The scan can show whether there are significant haemodynamic changes indicating a vascular component to the patient’s symptoms. Currently, there are no National Institute for Health and Care Excellence guidelines and no standardisation of protocols between different UK hospitals. As a result, the diagnostic accuracy of analysing the different positions with ultrasound is unknown. This is largely due to a high rate of false-positive results that these tests produce because even healthy individuals can undergo a degree of arterial compression when they perform such exaggerated provocative positions. However, these individuals do

not experience any ATOS-like symptoms in their day to day activities, do not have any long term damage to their vessels and do not suffer with any form of true ATOS.

In this cross-sectional observational study, we used ultrasound spectral Doppler waveform analysis of the subclavian artery in healthy participants to investigate whether there is a predictable, normal haemodynamic response to provocative positions. This is because active, dynamic assessments of the upper limb to collect objective haemodynamic data are recommended in the evaluation of ATOS.<sup>6</sup> This is certainly the case for radial artery palpation, however the validity of such tests while assessing the subclavian artery is debated and hence the justification of our study. We also examined the frequency at which the onset of any neurological discomfort correlated to any significant changes in waveform. This knowledge could underpin novel ATOS diagnostic pathways, with a more refined understanding of what constitutes a true-negative ATOS result with ultrasound testing.

## Methods

### *Participant recruitment*

The required sample size was calculated using G\*Power 3.1.9.2 software (Heinrich Heine University, Düsseldorf). As there was no previously stipulated partial eta squared in the literature that would have applied to this study, standardised small, medium, and large partial eta squared figures were used (0.01, 0.06 and 0.14, respectively).<sup>8</sup> The F test function was utilised, with alpha error probability 0.05, power probability 0.8, nonsphericity correction 1, 7 measures and 1 group. For the purposes of this initial study a medium effect size was deemed adequate and a corresponding sample size of 38 was chosen.

The London Bridge Research Ethics Committee and Health Research Authority provided approval (reference 18/LO/0526). Participants were over 18 years of age in order to comply with ethical regulations, and below the age of 40, in order to reduce the risk of pre-atherosclerotic changes that may alter the results. Exclusion criteria included any of the following vascular or neurological conditions of the upper limb; local musculo-skeletal trauma; invasive vascular procedures; upper limb or shoulder surgery; dislocation or fracture of the humerus, clavicle, first rib, second rib or third rib; inflammatory joint conditions; carpal tunnel syndrome; cervical disk disease; fibromyalgia or reflex sympathetic dystrophy. This ensured that any pre-existing conditions were not exacerbated by the positions which may have also contributed to false-positive results.

Potential participants were verbally screened for any of the aforementioned exclusion criteria. All recruited participants provided written informed consent. A total of 38 limbs from 19 participants (11 females, 8 males) with mean age 27.4 years (range 23–39) were assessed in one visit between April and November 2018.

### ***Participant positioning and assessment standardisation***

Following an initial two minute rest period, positions 1–7 (Figure 1) were performed. Sitting in the upright position with the head forward-facing, the patient actively manoeuvred their upper limb into each position whilst the mid-distal subclavian artery was imaged in longitudinal section from the infraclavicular window. Between each position, there was a rest period to normalise the blood flow and to ensure any symptoms had dissipated.

### ***Analysis of Doppler waveform parameters and symptomology***

All data were collected on a Toshiba Aplio 500 ultrasound machine by the same Clinical Vascular Scientist with an 11–4 MHz probe. For each assessment, the ultrasound B-mode and Doppler settings were optimised. We observed the haemodynamic changes within the subclavian artery by analysing the spectral Doppler waveform (Figure 2) whilst the participants adopted the different provocative positions (Figure 1). The peak systolic velocity (PSV) and systolic rise time (SRT) were also measured for each position. The SRT is the interval between the beginning of the systolic upstroke and the PSV.<sup>9</sup> Increases in PSV are expected at a site of reduced vessel luminal diameter<sup>10</sup> and increases in SRT are generally present distal to a significant stenosis.<sup>9</sup> No previous reports of attempting to quantify the SRT as a diagnostic measure for ATOS could be found in the literature.

We used the following terminology to describe waveform phasicity, as adapted from published literature<sup>11</sup>; ‘triphasic’, which is the normal subclavian artery waveform exhibiting forward systolic flow (1st phase), followed by a transient period of flow reversal (2nd phase) and then a further component of low velocity forward flow (3rd phase); ‘biphasic’ which consists of the first two phases only; and ‘monophasic’, which is abnormal and consists of only the first phase.

Upon a departure from laminar flow, the phasicity was further categorised as mildly disturbed or turbulent. Mild flow disturbance was visualised on the spectral trace as orderly in parts, but with irregular fluctuations in direction or velocity resulting in mild-moderate spectral broadening. Turbulence was

documented when there was a complete loss of the spectral window and multiple turbulent spikes. The waveform was assigned a severity score ranging from 1 for normal triphasic flow to 10 for an occlusion (Figure 2).

The primary outcome was a significant change in waveform during a provocative position achieving a score between 7 and 10; an occlusion or monophasic signal. The secondary outcome was the onset of any upper limb discomfort. To assess this, the participant was asked in the form of a dichotomous questionnaire if they experienced any of the following in each position; ‘pain’, ‘aching’, ‘pins and needles’, ‘coldness’, ‘numbness’ or ‘heaviness’.

### ***Statistical analysis***

By first assessing the parameters in the rested position and comparing this with the subsequent positions, each subject was effectively their own control. IBM SPSS Statistics for Windows, version 25.0 (IBM Corp., Armonk, NY, USA) software package was used for data analysis.

The waveform severity score provided ordinal data and was analysed by applying the related-samples Friedman’s two-way ANOVA test with Bonferroni correction.

In order to determine if the presence of symptoms significantly differed between each position, the non-parametric, binary Cochran’s Q-test was performed.


The Kolmogorov–Smirnov test showed that most of the PSV data met the normal distribution assumptions ( $p > 0.05$ ). A one-way, repeated-measures, within-subject ANOVA test, with Bonferroni correction, could then be performed. Mauchly’s test of sphericity was used to determine the Greenhouse-Geisser epsilon estimate of 0.548 which allowed PSV pairwise comparisons to be made from the ANOVA test.

The SRT dataset was checked for normality with the Kolmogorov Smirnov test. The significance level for all but one position was  $p < 0.05$  meaning the overall SRT dataset was not normally distributed. The nonparametric, Friedman’s two-way ANOVA was therefore performed.

## **Results**

A total of 28.9% of our healthy participants demonstrated significant changes in Doppler waveform in at least one position when compared to rest. Most remarkably, position 5 (180° abducted) led to an occlusion in two participants.

The pairwise comparisons of waveform scores between each position revealed that position 4 (120°

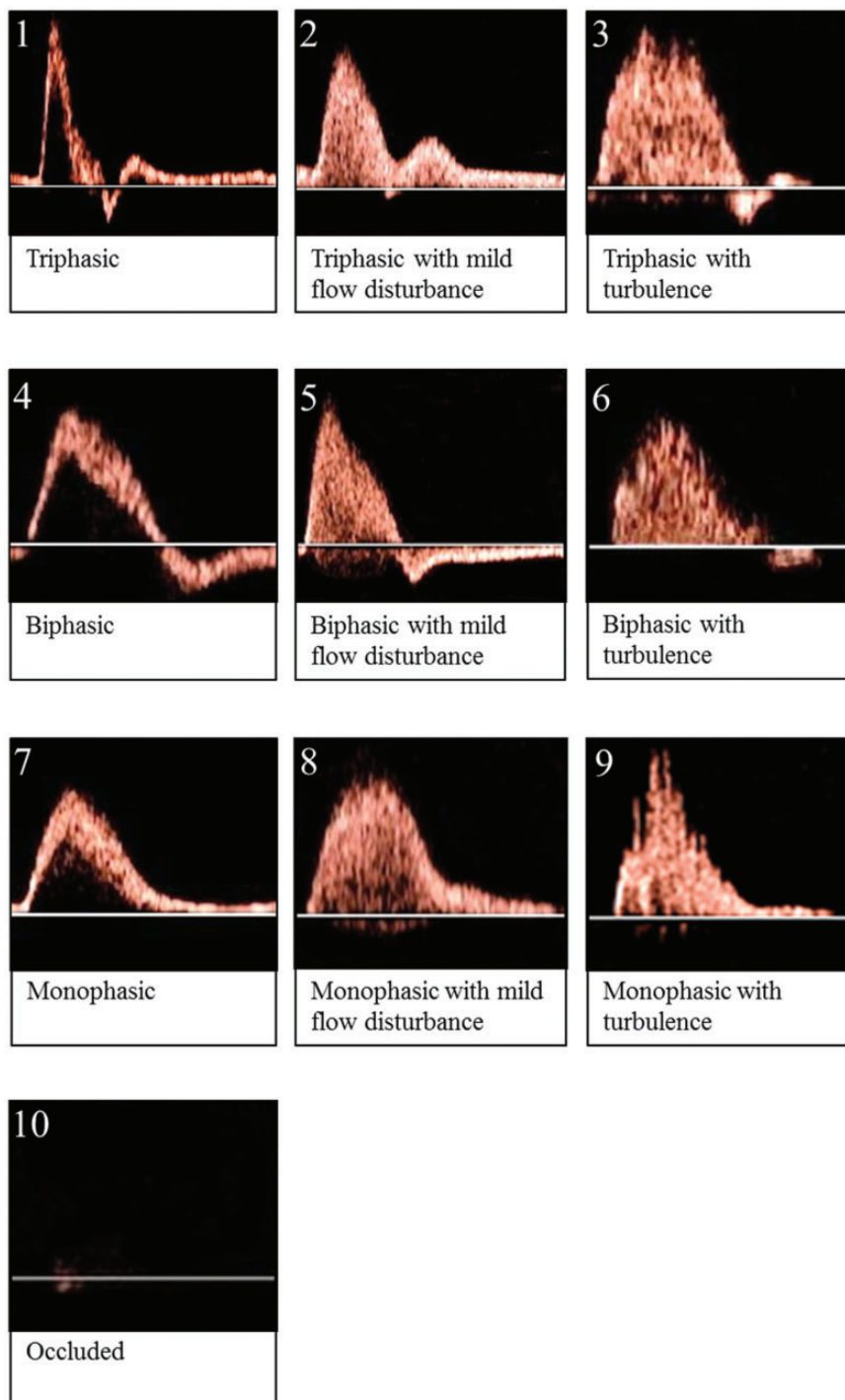


**Figure 1.** Demonstrative photographs of the resting and provocative upper limb positions, each with a corresponding position number and description.

abducted) was the position with the greatest level of abduction that did not significantly change the waveform score when compared to rest ( $p=0.306$ ). In contrast, the waveform score did significantly change in

positions 5, 6 and 7 ( $p<0.005$ ,  $p=0.014$  and  $p=0.023$ , respectively).

The participants reported minimal discomfort while adopting positions 1, 2, 3, 4 and 6. In contrast, there



**Figure 2.** Waveform images organised by severity score (1–10) with their corresponding description.

was a significantly greater level of discomfort reported during positions 5 (31%) and 7 (28%) ( $p = 0.001$  and  $p = 0.04$ , respectively).

Interestingly, only 21% of participants that described discomfort in certain provocative positions also developed a significant change in waveform. Similarly, only 50% of participants with a significant

change in waveform described any concurrent discomfort.

The pairwise comparisons of PSV showed that it only significantly differed between rest and position 2 (45° abducted) ( $p = 0.009$ ); changes in PSV in all other positions did not reach statistical significance ( $p > 0.05$ ).

The pairwise comparisons of SRT revealed significant differences between rest and during positions 4, 5, 6 and 7 ( $p=0.011$ ,  $p=0.019$ ,  $p=0.003$  and  $p=0.002$ , respectively).

## Discussion

The published literature on ATOS diagnosis is somewhat contradictory and incomplete. The previous studies to support the various provocative positions lack homogeneity and are generally of low methodological quality.<sup>12</sup> There are multiple well-established positions for TOS, such as the Adson's and Wright's tests, however in the literature these are intended for NTOS assessments, despite a change in radial pulse denoting a positive result.<sup>1</sup> While such stress tests are not specifically indicated for ATOS, they do tend to remain in routine use in UK vascular laboratories for ATOS and VTOS diagnostic ultrasound assessments, likely partially due to the overlap of symptoms. Due to the continued debate on which provocative positions have the highest sensitivity and specificity,<sup>13</sup> we attempted to establish the haemodynamic response during ATOS testing in healthy individuals.

Our findings support the SVS ATOS definition because we recorded occlusions and significant haemodynamic changes in the subclavian artery during stress positions which were asymptomatic and therefore do not meet the definition of ATOS; there must be extrinsic compression of the subclavian artery which presents as either proven symptomatic ischaemia or objective arterial damage.<sup>6</sup> In particular, the waveform scores for positions 5, 6 and 7 were significantly different to those at rest. These positions also resulted in both the occlusions, 87% of the monophasic turbulent waveforms and a significant proportion of discomfort. Due to the high proportion of healthy participants receiving false-positive results in these positions, their use is not recommended for diagnosing ATOS. In contrast, position 4 (120° abducted) was the greatest level of abduction that did not produce significant waveform changes or discomfort. Position 4 is also more regularly adopted in everyday activities. In future research it would therefore be worthwhile to assess how patients with confirmed ATOS compare when performing this position; if significant haemodynamic changes and symptoms are demonstrated then it may prove beneficial to incorporate into diagnostic testing. Additionally, we suggest exclusively analysing more commonly performed positions, such as increasing degrees of shoulder flexion, in order to distinguish the effects of each.

Over 90% of TOS diagnoses are due to neurological compression rather than vascular<sup>5</sup> and our findings are consistent with this; 79% of the transient discomfort

reported did not correlate to any significant haemodynamic change which demonstrates how even in the healthy population, neurological symptoms are relatively common. Likewise, less than 1% of diagnoses are ATOS,<sup>5</sup> and yet our study suggests that a degree of arterial compression can be experienced in the healthy population during the exaggerated positions commonly performed in ultrasound testing. However, only half of our participants with a significant change in waveform noted any discomfort.

Additionally, the transient physical symptoms of each TOS subset are difficult to distinguish from one another. All these factors highlight the importance of taking the whole clinical picture into account when attempting to rule out other types of thoracic compression. Ultrasound efficacy depends on a variety of aspects, such as patient habitus and operator skillset. We currently recommend a TOS scanning protocol that both directly assesses the subclavian artery for structural abnormalities and assesses patients dynamically. This may include some established positions but also any specific position that triggers symptoms for that individual. Critically, symptom onset must correlate with ischaemia. In the event of a positive ATOS result, the contralateral, asymptomatic upper limb should also be assessed as a control.

It is well understood that the PSV and SRT can be accurately assessed with spectral Doppler ultrasound. However, for ATOS diagnostics the exact arterial compression site cannot always be visualised<sup>14</sup> meaning we must indirectly assess the haemodynamic changes and previous studies reflect the disparity in technique. A 2009 study measured the PSV in the distal subclavian artery in healthy volunteers and generally reported decreased PSV values with increasing degrees of compression,<sup>15</sup> whereas former studies by Longley et al. attempted to measure the PSV at the mid-subclavian artery in asymptomatic volunteers and generally reported raised velocities.<sup>16</sup> In contrast again, Wadhvani et al.<sup>17</sup> measured the PSV during increasing degrees of abduction in five patients with clinically suspected TOS and despite analysing the infraclavicular subclavian artery, i.e. distal to the compression site, they consistently found a doubling of the PSV upon 90° abduction. The reliability of Wadhvani's study has been scrutinised though due to the lack of statistical power and small sample size.<sup>15</sup>

The majority of positions did not significantly alter the PSV in our healthy participants ( $p > 0.05$ ). For each participant and overall, the changes in PSV between positions was fairly erratic, such that no overall predictability or significance was implied; only the PSV between positions 1 and 2 significantly differed ( $p=0.009$ ). The increment in abduction between these positions is merely 45° and the statistical difference

here is unlikely to be clinically significant. Our findings are consistent with a previously published study which stated that there is no known correlation between the PSV and the degree of stenosis in TOS diagnostics.<sup>14</sup>

The lack of statistical significance in PSV values is likely partially attributable to difficulties in determining the true systolic peak in the presence of a complex flow field and turbulence;<sup>18</sup> measurements obtained were highly subjective and likely led to larger error margins. This emphasises how a consistent positioning of the sample volume, whether it is as close to the stenosis as possible or further distally, is critical in the attempt to standardise velocity criteria and protocols. We therefore suggest that PSV recordings are interpreted with caution due to the lack of guidelines and the variability even within the healthy population.

This study showed a significant increase in SRT in positions 4, 5, 6 and 7 compared to rest. However, these results are of limited value because, as described above, accurate measurements are difficult to obtain on spectral traces with turbulence. Future research may benefit from investigating restored laminar flow at brachial artery level as this may enable more accurate SRT measurements. Currently, we recommend against measuring the SRT in the subclavian artery as a diagnostic tool for ATOS.

We acknowledge some limitations of this study, including possible observational errors and assessment bias; due to the dynamic nature of the test it was impossible to blind the vascular scientist to the various positions. This assessment bias could have been reduced if the parameters had been randomly measured from the spectral traces by a different, blinded, team member. Secondly, this initial study would have been more comprehensive if we had been able to include symptomatic patients for comparison.

## Conclusion

We have demonstrated the high false-positive rates obtained during ATOS dynamic testing and the need for updated ultrasound diagnostic protocols. We have established that position 4 (120° abduction) warrants further investigation. PSV measurements need to be standardised and measuring the SRT in the brachial artery is an avenue to explore. If arterial damage within the subclavian artery is visualised, and the patient experiences objective symptomatic ischaemia while performing a defined stress position, or a position that they personally feel causes symptoms, then a diagnosis of ATOS can be considered.

## Acknowledgements

Authors would like to acknowledge and thank Mr Pranav Somaiya, the academic research supervisor, and Ms Kim

Pearce, for the statistical support. We would also like to thank the Vascular Studies Laboratory at the Royal Free Hospital London for accommodating the study.

## Authors Contribution

Ms Lily Bishop: Concept and design of study and data analysis technique, data acquisition, article draft, revision and approval.

Mr Matthew Bartlett: Concept and design of study and data analysis technique, article revision and approval.

## Declaration of conflicting interests

The author(s) declared no potential conflicts of interest with respect to the research, authorship, and/or publication of this article.

## Ethical approval

The London Bridge Research Ethics Committee and Health Research Authority provided ethical approval (reference 18/LO/0526).

## Funding

The author(s) disclosed receipt of the following financial support for the research, authorship, and/or publication of this article: The author(s) would like to thank the Royal Free Charity for the financial support to enable open-access publication.

## Guarantor

LB

## ORCID iD

Lily Bishop  <https://orcid.org/0000-0001-8024-8249>

## References

1. Hooper TL, Denton J, McGalliard MK, et al. Thoracic outlet syndrome: a controversial clinical condition. Part 1: anatomy, and clinical examination/diagnosis. *J Man Manip Ther* 2010; 18: 74–83.
2. Laulan J, Fouquet B, Rodaix C, et al. Thoracic outlet syndrome: definition, aetiological factors, diagnosis, management and occupational impact. *J Occup Rehabil* 2011; 21: 366–373.
3. Juvonen T, Satta J, Laitala P, et al. Anomalies at the thoracic outlet are frequent in the general population. *Am J Surg* 1995; 170: 33–37.
4. Peet RM, Henriksen JD, Anderson TP, et al. Thoracic-outlet syndrome: evaluation of a therapeutic exercise program. *Proc Staff Meet Mayo Clin* 1956; 31: 281–287.
5. Sanders RJ, Hammond SL and Rao NM. Diagnosis of thoracic outlet syndrome. *J Vasc Surg* 2007; 46: 601–604.
6. Illig KA, Donahue D, Duncan A, et al. Reporting standards of the society for vascular surgery for thoracic outlet syndrome. *J Vasc Surg* 2016; 64: 23–35.

7. Czihal M, Banafsche R, Hoffmann U, et al. Vascular compression syndromes. *Vasa* 2015; 44: 419–434.
8. Field A. *Discovering statistics using IBM SPSS statistics*. 4th ed. London, UK: Sage, 2013.
9. Burnham SJ, Jaques P and Burnham CB. Noninvasive detection of iliac artery stenosis in the presence of superficial femoral artery obstruction. *J Vasc Surg* 1992; 16: 445–451.
10. Ota H, Takase K, Rikimaru H, et al. Quantitative vascular measurements in arterial occlusive disease. *Radiographics* 2005; 25: 1141–1158.
11. Scissons R. Characterizing triphasic, biphasic, and monophasic Doppler waveforms. *J Diagn Med Sonogr* 2008; 24: 269–276.
12. Dessureault-Dober I, Bronchti G and Bussièrès A. Diagnostic accuracy of clinical tests for neurogenic and vascular thoracic outlet syndrome: a systematic review. *J Manipulative Physiol Ther* 2018; 41: 789–799.
13. Kuhn JE, Lebus VGF and Bible JE. Thoracic outlet syndrome. *J Am Acad Orthop Surg* 2015; 23: 222–232.
14. Demondion X, Vidal C, Herbinet P, et al. Ultrasonographic assessment of arterial cross-sectional area in the thoracic outlet on postural maneuvers measured with power Doppler ultrasonography in both asymptomatic and symptomatic populations. *J Ultrasound Med* 2006; 25: 217–224.
15. Stapleton C, Herrington L and George K. Sonographic evaluation of the subclavian artery during thoracic outlet syndrome shoulder manoeuvres. *Man Ther* 2009; 14: 19–27.
16. Longley DG, Yedlicka JW, Molina EJ, et al. Thoracic outlet syndrome: evaluation of the subclavian vessels by color duplex sonography. *AJR Am J Roentgenol* 1992; 158: 623–630.
17. Wadhvani R, Chaubal N, Sukthankar R, et al. Color Doppler and duplex sonography in 5 patients with thoracic outlet syndrome. *J Ultrasound Med* 2001; 20: 795–801.
18. Hoskins PR. A review of the measurement of blood velocity and related quantities using Doppler ultrasound. *Proc Inst Mech Eng H* 1999; 213: 391–400.