

Outcomes of Endovascular Thrombectomy Performed 6–24 h after Acute Stroke from Extracranial Internal Carotid Artery Occlusion

Eitaro OKUMURA,¹ Junya TSURUKIRI,¹ Takahiro OTA,² Hiroyuki JIMBO,³ Keigo SHIGETA,⁴ Tatsuo AMANO,⁵ Masayuki UEDA,⁶ Yuji MATSUMARU,⁷ Yoshiaki SHIOKAWA,⁸ and Teruyuki HIRANO⁵

¹*Department of Emergency and Critical Care Medicine, Tokyo Medical University Hachioji Medical Center, Hachioji, Tokyo, Japan;*

²*Department of Neurosurgery, Tokyo Metropolitan Tama Medical Center, Fuchu, Tokyo, Japan;*

³*Department of Neurosurgery, Tokyo Medical University Hachioji Medical Center, Hachioji, Tokyo, Japan;*

⁴*Department of Neurosurgery, National Hospital Organization Disaster Medicine Center, Tachikawa, Tokyo, Japan;*

⁵*Department of Stroke and Cerebrovascular Medicine, Kyorin University, Mitaka, Tokyo, Japan;*

⁶*Department of Neurology and Stroke Medicine, Tokyo Metropolitan Tama Medical Center, Fuchu, Tokyo, Japan;*

⁷*Division of Stroke Prevention and Treatment, Department of Neurosurgery, University of Tsukuba, Tsukuba, Ibaraki, Japan;*

⁸*Department of Neurosurgery, Kyorin University, Mitaka, Tokyo, Japan*

Abstract

Thrombectomy has demonstrated clinical efficacy against acute ischemic stroke caused by intracranial occlusion of the internal carotid artery (ICA), even if performed 6–24 h after onset. This study investigated the outcomes of thrombectomy performed 6–24 h after stroke onset caused by extracranial ICA occlusion. Of 586 stroke patients receiving thrombectomy during the past 3 years and registered in the Tama Registry of Acute Endovascular Thrombectomy database, 24 were identified with ICA occlusion (14 extracranial and 10 intracranial), known to be well 6–24 h before presentation, and with pre-stroke modified Rankin Scale (mRS) score of 0 or 1. Clinical outcomes measured were the rate of functional independence at 90 days according to mRS score of 0–2 and 90 day mortality rate. Of patients with extracranial ICA occlusion, two received additional carotid stenting with thrombectomy. The median interval between the last time the patient was known to be well and hospital arrival was 601 (interquartile range, 476–729 min). Both the rate of functional independence at 90 days and 90 day mortality were comparable between patients with extracranial or intracranial ICA occlusion (36% vs. 40% and 7% vs. 10%, respectively). No symptomatic intracranial hemorrhages occurred within 24 h following treatment of extracranial ICA occlusion. Thrombectomy performed 6–24 h after extracranial ICA results in acceptable functional outcome. Further clinical study is warranted to better define the temporal window of thrombectomy for acceptable functional outcome in patients with extracranial ICA occlusion.

Key words: atrial fibrillation, cerebral infarction, emergency medicine, endovascular therapy

Received December 5, 2018; Accepted May 23, 2019

Copyright© 2019 by The Japan Neurosurgical Society This work is licensed under a Creative Commons Attribution-NonCommercial-NoDerivatives International License.

Introduction

Endovascular thrombectomy within 6 h has been shown to be effective for the treatment of ischemic stroke in patients with large vessel occlusion (LVO) of the internal carotid artery (ICA) or middle cerebral artery (MCA).¹ Furthermore, the presence of sluggish or absent flow caused by intracranial occlusion of a parent artery was high in the Multicenter Randomized Clinical Trial of Endovascular Treatment for Acute Ischemic Stroke in the Netherlands dataset.² In such cases, endovascular treatment would also have been beneficial within this timeframe.

Two recent endovascular thrombectomy trials [DAWN (diffusion-weighted imaging (DWI) or computed tomography perfusion Assessment with Clinical Mismatch in the Triage of Wake-Up and Late Presenting Strokes Undergoing Neurointervention with Trevo) and DEFUSE 3 [Endovascular therapy (EVT) Following Imaging Evaluation for Ischemic Stroke-3]] reported benefits of thrombectomy performed up to 24 h after onset compared with medical therapy alone.^{2,3} These studies predominantly included patients with intracranial occlusion of the ICA or MCA, and there is still no conclusive evidence for benefits of endovascular thrombectomy performed 6–24 h after acute extracranial ICA occlusion. Therefore, a retrospective study was conducted to elucidate the outcomes of endovascular thrombectomy at 6–24 h after stroke due to extracranial ICA occlusion using the Tama Registry of Acute endovascular Thrombectomy (TREAT) database.

Materials and Methods

Patients

This was a retrospective, observational study using data from TREAT (UMIN-CTR: UMIN000026888), a multicenter registry of mechanical thrombectomy for acute LVO in the Tama area of Tokyo, Japan.⁴ Twelve of the 13 recanalization therapy-capable stroke centers in the Tama area participated in the study. The ethics committee of each participating hospital approved the study and waived the requirement for written informed consent because of the retrospective design. The survey covered 586 patients with LVO who underwent acute thrombectomy between January 2015 and December 2017. Occlusion sites in the ICA, MCA, anterior cerebral artery, vertebral artery, and basilar artery were included. All patients were retrospectively registered. All enrolled stroke patients received endovascular therapy at the discretion of attending stroke specialists certified by the Japanese Society for Neuroendovascular Therapy.

All eligible patients met the following criteria: (1) 18 years of age or older, (2) last known to be well 6–24 h before hospital arrival, (3) presenting with a baseline National Institutes of Health Stroke Scale (NIHSS) score ≥ 5 , (4) pre-stroke mRS score of 0 or 1, and (5) ICA occlusion verified by magnetic resonance angiography (MRA) with absence of ICA. Treatment decisions were based on the NIHSS score, occlusion site according to MRA, and DWI-fluid-attenuated inversion recovery mismatch. Emergency thrombectomy was performed within 24 h after stroke onset.

The site of ICA occlusion was ultimately confirmed by cerebral angiography at each stroke center. Intracranial ICA occlusion was defined as the absence of the intradural ICA by cerebral angiography before performing EVT, whereas extracranial ICA occlusion was defined as the absence of the extradural ICA or cervical ICA by angiography and the resolution of cerebral blood flow by EVT at the same level of extracranial ICA. If angiography revealed occlusion at the level of the carotid bulb with clear presence of calcifications or plaque, atherosclerosis was considered as the most likely cause of occlusion. If occlusion was located above the level of the carotid bulb without calcifications or plaque and angiography revealed tapering of the blood flow, dissection was considered the most likely cause of occlusion.

Data collection

Demographic, clinical, and neuroimaging data were retrieved from the TREAT database. The following characteristics were gathered for all eligible patients: age, sex, vascular disease risk (including hypertension, diabetes, lipid metabolism abnormalities, and atrial fibrillation), medications, baseline NIHSS score, mRS scores (pre-stroke and 90 days post-stroke), MRA results, DWI-Alberta Stroke Program Early Computed Tomography Scores (ASPECTS), time last seen well to time of revascularization (delay to therapy), modified thrombolysis in cerebral infarction (TICI) score, symptomatic intracranial hemorrhage (sICH) at 24 h, and 90 day mortality.

Endovascular therapy

For endovascular thrombectomy, a stent retriever (Solitaire, Covidien/ev3, Dublin, Ireland; Trevo, Stryker Neurovascular, Mountain View, CA, USA; and REVIVE, Johnson & Johnson, NJ, USA) or Penumbra MAX system (Penumbra Inc., Alameda, CA, USA) were available in Japan at the time. For carotid stenting, Wallstent (Boston Scientific, Natick, MA, USA), Protégé (eV3 Covidien, Irvine, CA, USA), and Precise (Cordis Corporation, Bridgewater, NJ,

USA) were also available. These devices were used for the treatment at the discretion of the attending stroke specialist.

Outcomes

The efficacy outcome included functional independence, which was defined as a mRS score of 0–2 at 90 days after the treatment. Patient mRS scores at 90 days were retrieved from the TREAT registry database and were initially determined by telephone follow-up or outpatient visit. In the present study, 90 day mRS scores of patients lost to follow-up were replaced by discharge mRS scores (scores of 3 and 4). The technical outcome of thrombectomy was defined by a modified TICI score as 2b (50–99% reperfusion) or 3 (complete reperfusion) according to the recommendation of Zaidat et al.⁶⁾ The safety outcomes included 90 day mortality and incidence of sICH within 24 h post-thrombectomy according to the definition of the Safe Implementation of Thrombolysis in Stroke-Monitoring Study and European-Australasian Acute Stroke Study trials.^{6,7)}

Statistical analysis

Data from all eligible patients were analyzed. Continuous variables are shown as medians with interquartile ranges (IQRs) and categorical variables as frequencies or proportion of the total (%). Between-group differences in continuous variables were assessed by Mann–Whitney *U*-test and categorical variables by Fisher's exact test. Spearman correlation coefficient was used to identify associations between the evaluated parameters. All statistical analyses were performed using Prism version 6.0a statistical software (GraphPad Software, San Diego, CA, USA). A probability (*P*) of <0.05 was considered significant for all tests.

Results

Demographics and clinical characteristics

Twenty-four patients (mean age, 77 years; age range, 55–91 years; 75% males), including 14 with extracranial and 10 with intracranial ICA occlusion, were enrolled in this study. The demographic and clinical characteristics of all patients are summarized in Table 1. ICA occlusion was confirmed by MRA in all patients. The median baseline NIHSS score was 17 (IQR, 14–21), and 63% presented with NIHSS score of 10–20 (moderate to severe stroke). Among patients with extracranial ICA occlusion, cerebral embolus was the cause in 6, atherothrombosis in another 6, and other causes in 2. The median DWI-ASPECTS was 7 (IQR, 5–8). The median interval

between time last known to be well and hospital arrival was 601 min (IQR, 476–729 min). The median interval between imaging and arterial puncture was 49 min (IQR, 38–60 min), and time between arterial puncture and revascularization was 44 min (IQR, 28–89 min). Thus, median interval between the time last known to be well and revascularization was 721 min (IQR, 637–864 min). Clinical and safety outcomes are shown in Table 2. After EVT, 71% patients achieved 50–99% reperfusion or complete reperfusion (TICI score of 2b or 3) and 38% achieved the functional outcome criterion of mRS score of ≤2 at 90 days. Details of the mRS scores at 90 days are shown in Figure 1. The rate of sICH within 24 h was 4%, and 90 day mortality rate was 8%.

Subanalysis of ICA occlusion

Among 24 patients, eight who had extracranial ICA occlusion due to atherosclerosis or other causes were categorized into Group A. Overall, 16 patients who had intracranial (*n* = 10) and extracranial (*n* = 6) ICA occlusion due to embolus were categorized into Group B. Although there were no significant differences in clinical characteristics, including age (78 vs. 78 years), median baseline NIHSS score (19 vs. 18), and median DWI-ASPECTS (7 vs. 6), a significant difference was noted in the median interval between the time that the patient was last known to be well and hospital arrival between the two groups (490 min in Group A, and 687 min in Group B). With regard to the median intervals of clinical course at our hospital, no significant differences were noted between the two groups.

With regard to first EVT in Group A, stent retriever was used in two patients (Solitaire, *n* = 1; Trevo, *n* = 1), aspiration catheter (Penumbra) in three patients, and other angioplasty in three patients. In Group B, stent retriever was used for first EVT in nine patients (Solitaire, *n* = 8; Trevo, *n* = 1) and aspiration catheter (Penumbra) in five patients. For second EVT in Group A, stent retriever was used in one patient (Solitaire) and aspiration catheter (Penumbra) in one patient, whereas in Group B, stent retriever was used in two patients (Solitaire *n* = 1; Revive, *n* = 1) and aspiration catheter (Penumbra) was used in four patients.

No significant differences were noted in safety outcomes, including the TICI 2b/3 classification rate (63% vs. 69%), functional independence rate (38% vs. 38%), and the 90 day mortality rate (0% vs. 13%), between the two groups. Only one case of sICH was encountered within 24 h after thrombectomy in this study cohort (Table 2).

Table 1 Demographics and clinical characteristics of patients with carotid artery occlusion

Variable	Total (<i>n</i> = 24)	Extracranial (<i>n</i> = 14)	Intracranial (<i>n</i> = 10)
Age, years	77 ± 8	77 ± 8	76 ± 9
Age ≥ 80 years, <i>n</i> (%)	7 (29)	4 (29)	3 (30)
Male sex, <i>n</i> (%)	18 (75)	10 (71)	8 (80)
Atrial fibrillation, <i>n</i> (%)	12 (50)	6 (43)	6 (60)
Diabetes mellitus, <i>n</i> (%)	6 (25)	4 (29)	2 (20)
Hypertension, <i>n</i> (%)	19 (79)	9 (64)	10 (100)
Lipid metabolism abnormalities, <i>n</i> (%)	11 (46)	6 (43)	5 (50)
Medication use			
Antiplatelet	6 (25)	3 (21)	3 (30)
Anticoagulant	5 (21)	2 (14)	3 (30)
Statin	7 (29)	5 (36)	2 (20)
Pre-stroke modified Rankin Scale score, <i>n</i> (%)			
0	19 (79)	10 (71)	9 (90)
1	5 (21)	4 (29)	1 (10)
Baseline NIHSS score			
Median	19	20	16
Interquartile range	14–21	16–21	13–21
10–20, <i>n</i> (%)	15 (63)	8 (57)	7 (70)
Type of stroke onset, <i>n</i> (%)			
On awakening	4 (17)	3 (21)	1 (10)
Unwitnessed stroke	1 (4)	0	1 (10)
Witnessed stroke	19 (79)	11 (79)	8 (80)
Type of stroke, <i>n</i> (%)			
Cerebral embolism	14 (58)	6 (43)	8 (80)
Atherothrombotic	7 (29)	6 (43)	1 (10)
Others	3 (13)	2 (14)	1 (10)
Imaging, <i>n</i> (%)			
MRI	24 (100)	14 (100)	10 (100)
DWI-ASPECTS			
Median	7	6	6
Interquartile range	5–8	6–7	3–7
Time last seen well to hospital arrival (min)			
Median	601	583	712
Interquartile range	476–729	480–677	485–768
Time last seen well to imaging (min)			
Median	627	607	730
Interquartile range	495–756	492–697	510–871
Time from hospital arrival to arterial puncture (min)			
Median	73	72	84
Interquartile range	63–99	66–76	63–103
Time from imaging to arterial puncture (min)			
Median	49	57	52
Interquartile range	38–60	36–84	40–61
Time last seen well to arterial puncture (min)			
Median	677	653	758
Interquartile range	551–795	544–752	570–925
Time last seen well to revascularization (min)			
Median	721	693	783
Interquartile range	637–864	634–814	643–948

ASPECTS: Alberta Stroke Program Early Computed Tomography Scores, DWI: diffusion-weighted imaging, MRI: magnetic resonance imaging, NIHSS: National Institutes of Health Stroke Scale.

Table 2 Clinical outcomes

Outcome	Total (n = 24)	Group A (n = 8)	Group B (n = 16)
Modified Rankin Scale score at 90 days, n (%)			
0–2	9 (38)	3 (38)	6 (38)
0–3	12 (50)	4 (50)	8 (50)
4–6	12 (50)	4 (50)	8 (50)
Grade of 2b or 3 on TICI scale, n (%)	16 (67)	5 (63)	11 (69)
Complication			
Stroke-related death at 90 days, n (%)	2 (8)	0	2 (13)
Symptomatic Intracranial hemorrhage at 24 h, n (%)	1 (4)	0	1 (6)
HI-1	7 (29)	2 (25)	5 (31)
HI-2	1 (3)	0	1 (6)
PH-1	0	0	0
PH-2	0	0	0
RIH	0	0	0
IVH	0	0	0

HI: hemorrhagic infarction, IVH: intraventricular hemorrhage, PH: parenchymal hematoma, RIH: remote intracranial hemorrhage, TICI: thrombolysis in cerebral infarction.

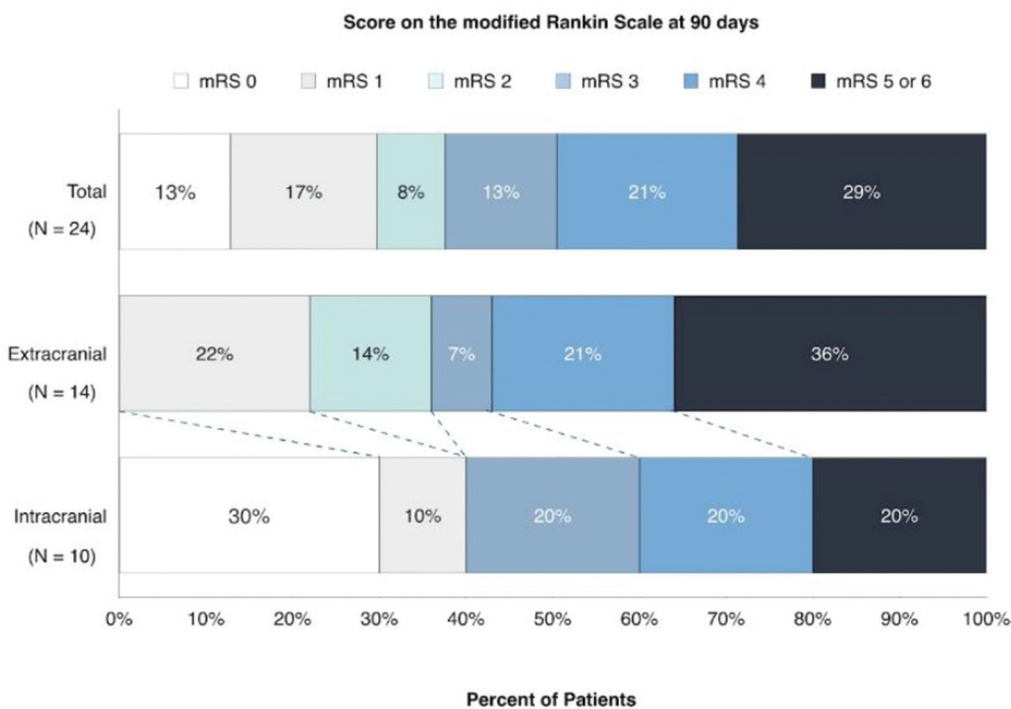


Fig. 1 Scores on the modified Rankin Scale (mRS) at 90 days. Scores for disability on the mRS range from 0 to 6, with 0 indicating no symptoms, 1 no clinically significant disability, 2 slight disability, 3 moderate disability, 4 moderately severe disability, 5 severe disability, and 6 death. The numbers in the bars are percentages of patients who had each score; the percentages may not sum to 100 because of rounding.

Discussion

The greatest challenge in stroke treatment is to restore perfusion within a critical time window before irreversible neural damage. As the time between stroke onset and hospital arrival is not controllable by physicians, defining the limits of this window for specific therapies is crucial for

best possible outcome. The DAWN trial demonstrated that thrombectomy performed 6–24 h after onset still improved outcome as measured by functional independence at 90 days compared with medical treatment alone (48% vs. 13%).²⁾ Therefore, endovascular thrombectomy for revascularization remains a high priority within the first day post-stroke.

The prognosis for patients with acute stroke and carotid artery occlusion is poor, with permanent disability reported in 40–69% of cases, death in 16–55%, and good recovery in only 2–12%.⁸⁾ Furthermore, complete LVO, including extracranial ICA occlusion, accounts for 6–15% of acute ischemic strokes, and is associated with poor outcome and low revascularization rate if treated only by intravenous tissue plasminogen activator (IV t-PA).^{9,10)} Therefore, additional therapy is warranted.

The identification of extracranial ICA occlusion by MRA is difficult sometimes in acute stroke setting. A recent study has demonstrated that CT angiography can differentiate intracranial from extracranial occlusions, especially in terms of atherosclerotic or dissection.¹¹⁾ However, for acute ischemic stroke within 24 h, MRI/MRA is superior to CT angiography. Furthermore, approximately one-third of patients with an apparent extracranial ICA occlusion were determined in acute ischemic stroke, whereas the artery is patent by angiography during EVT.¹¹⁾ Although EVT is important in the treatment of acute ischemic stroke within 8 h, its role in patients with apparent occlusion of the extracranial ICA within 24 h after onset is inconclusive. Kappelhof et al.¹¹⁾ found that carotid stenting for extracranial ICA occlusion due to thrombosis or dissection resulted in higher recanalization rate (87%) and improved functional independence (68%) compared with IV t-PA. Duijsens et al.¹²⁾ reported that the rates of recanalization and favorable outcome by EVT within 4 h were higher in patients with ICA occlusion due to progression of intracranial LVO compared with patients with occlusion due to thrombosis or dissection (83% vs. 60% and 50% vs. 40%, respectively). This study demonstrated that recanalization may be achieved both in patients with ICA occlusion due to thrombosis or dissection and in those with occlusion due to other embolic causes. Indeed, the recanalization rate by EVT within 24 h was similar between the two groups (63% vs. 69%). Furthermore, there were no differences in the recanalization rate between the first use of stent retriever and aspiration catheter in both groups.

We also found that the rate of functional independence at 90 days was 38%, 2.5 times higher than the rate of the non-treated patients with intracranial ICA occlusion in the DAWN trial. No significant differences were determined in sICH rate at 24 h and 90 day mortality between extracranial and intracranial ICA occlusion cases (0% vs. 10% and 7% vs. 10%, respectively). Therefore, the safety outcomes in our study were acceptable compared with the aforementioned studies. The clinical utility

of endovascular thrombectomy at 6–24 h post-event in patients with acute stroke and an apparent occlusion of extracranial ICA on MRA was demonstrated in our study. Further investigation is needed to evaluate efficacy in patients with moderate infarct volume at presentation.

There are several limitations to this study, most notably the retrospective design and small number of cases. Other notable weaknesses were the use of a post hoc hypothesis and lack of a control group for comparison against endovascular thrombectomy. In addition, treatment and ischemic stroke subtype classifications are based on the discretion of the attending stroke specialist; therefore, the possibility of bias cannot be excluded. The outcomes were defined as mRS of ≤ 2 at 90 days after stroke and the 90 day mortality rate, and we did not investigate utility-weighted modification of the usual Rankin Scale because of the small sample size. Moreover, the patients with ICA occlusion treated within 6 h were not included in this study, and a subgroup analysis of the patients with LVO treated by thrombectomy between <6 and ≥ 6 h is underway using TREAT database in other TREAT subanalysis group.

Conclusion

In the TREAT database, endovascular thrombectomy performed 6–24 h after stroke onset seems to be beneficial in re-establishing perfusion and improving functional independence in stroke patients with extracranial ICA occlusion. Further large-scale investigations are warranted to determine whether the time window of endovascular thrombectomy can be further expanded for patients with extracranial ICA occlusion.

Acknowledgment

The author would like to thank Enago (www.enago.com) for the English language review.

Authors' Contributions

Conceived and designed the experiments: OE, TJ. Performed the experiments and analyzed the data: OE, TJ, JH.

Contributed to interpretation of data: OE, TJ, JH, OT. Critically revised the manuscript: SK, AT, SY, AT. Approved the final version to be submitted: OE, TJ, JH, OT, SK, AT, SY, AT.

Sources of Funding

This registry is partially supported by the Japanese Society of Neuroendovascular Therapy.

Conflicts of Interest Disclosure

Dr. Hirano has received honoraria from Bayer, Boehringer-Ingelheim, Bristol-Myers Squibb, Daiichi-Sankyo, Otsuka Pharma, Pfizer, and Sanofi. Dr. Matsumaru has received honoraria from Medtronic, Stryker, and Johnson & Johnson. Dr. Shiokawa has received research grants from AbbVie GK and ONO Pharmaceutical Co., Ltd. The other authors report no conflicts.

References

- 1) Jovin TG, Chamorro A, Cobo E, et al.: Thrombectomy within 8 hours after symptom onset in ischemic stroke. *N Engl J Med* 372: 2296–2306, 2015
- 2) Albers GW, Marks MP, Kemp S, et al.: Thrombectomy for stroke at 6 to 16 hours with selection by perfusion imaging. *N Engl J Med* 378: 708–718, 2018
- 3) Matsumaru Y, Ishikawa E, Yamamoto T, Matsumura A. Recent trends in neuro-endovascular treatment for acute ischemic stroke, cerebral aneurysms, carotid stenosis, and brain arteriovenous malformations. *Neurol Med Chir (Tokyo)* 57: 253–260, 2017
- 4) Nogueira RG, Jadhav AP, Haussen DC, et al.: Thrombectomy 6 to 24 hours after stroke with a mismatch between deficit and infarct. *N Engl J Med* 378: 11–21, 2018
- 5) Ota T, Shigeta K, Amano T, et al.: Regionwide retrospective survey of acute mechanical thrombectomy in Tama, suburban Tokyo: a preliminary report. *J Stroke Cerebrovasc Dis* 27: 3350–3355, 2018
- 6) Zaidat OO, Yoo AJ, Khatri P, et al.: Recommendations on angiographic revascularization grading standards for acute ischemic stroke: a consensus statement. *Stroke* 44: 2650–2663, 2013
- 7) Wahlgren N, Ahmed A, Eriksson N, et al.: Multivariable analysis of outcome predictors and adjustment of main outcome results to baseline data profile in randomized controlled trials: Safe Implementation of Thrombolysis in Stroke-MONitoring Study (SITS-MOST). *Stroke* 39: 3316–3322, 2008
- 8) Larrue V, von Kummer RR, Müller A, Bluhmki E. Risk factors for severe hemorrhagic transformation in ischemic stroke patients treated with recombinant tissue plasminogen activator: a secondary analysis of the European-Australasian Acute Stroke Study (ECASS II). *Stroke* 32: 438–441, 2001
- 9) Kappelhof M, Marquering HA, Berkhemer OA, Majoie CB. Intra-arterial treatment of patients with acute ischemic stroke and internal carotid artery occlusion: a literature review. *J Neurointerv Surg* 7: 8–15, 2015
- 10) De Silva DA, Brekenfeld C, Ebinger M, et al.: The benefits of intravenous thrombolysis relate to the site of baseline arterial occlusion in the Echoplanar Imaging Thrombolytic Evaluation Trial (EPITHET). *Stroke* 41: 295–299, 2010
- 11) Kappelhof M, Marquering HA, Berkhemer OA, et al.: Accuracy of CT angiography for differentiating pseudo-occlusion from true occlusion or high-grade stenosis of the extracranial ICA in acute ischemic stroke: a retrospective MR CLEAN substudy. *AJNR Am J Neuroradiol* 39: 892–898, 2018
- 12) Duijsens HM, Spaander F, van Dijk LC, et al.: Endovascular treatment in patients with acute ischemic stroke and apparent occlusion of the extracranial internal carotid artery on CTA. *J Neurointerv Surg* 7: 709–714, 2015

Address reprint requests to: Junya Tsurukiri, MD, PhD, Emergency and Critical Care Medicine, Tokyo Medical University Hachioji Medical Center, 1163 Tatemachi, Hachioji, Tokyo 193-0998, Japan.
e-mail: junya99@tokyo-med.ac.jp