


CASE REPORT

Open Access



Aureobasidium melanigenum catheter-related bloodstream infection: a case report

Shinya Yamamoto¹, Mahoko Ikeda^{1,2*} , Yuki Ohama², Tomohiro Sunouchi³, Yasutaka Hoshino⁴, Hiroshi Ito¹, Marie Yamashita¹, Yoshiaki Kanno¹, Koh Okamoto¹, Satoshi Yamagoe⁴, Yoshitsugu Miyazaki⁴, Shu Okugawa¹, Jun Fujishiro³ and Kyoji Moriya^{1,2}

Abstract

Background: *Aureobasidium melanigenum* is a ubiquitous dematiaceous fungus that rarely causes invasive human infections. Here, we present a case of *Aureobasidium melanigenum* bloodstream infection in a 20-year-old man with long-term catheter use.

Case presentation: A 20-year-old man receiving home care with severe disabilities due to cerebral palsy and short bowel syndrome, resulting in long-term central venous catheter use, was referred to our hospital with a fever. After the detection of yeast-like cells in blood cultures on day 3, antifungal therapy was initiated. Two identification tests performed at a clinical microbiological laboratory showed different identification results: *Aureobasidium pullulans* from matrix-assisted laser desorption/ionization time-of-flight mass spectrometry, and *Cryptococcus albidus* from a VITEK2 system. Therefore, we changed the antifungal drug to liposomal amphotericin B. The fungus was identified as *A. melanigenum* by DNA sequence-based analysis. The patient recovered with antifungal therapy and long-term catheter removal.

Conclusion: It is difficult to correctly identify *A. melanigenum* by routine microbiological testing. Clinicians must pay attention to the process of identification of yeast-like cells and retain *A. melanigenum* in cases of refractory fungal infection.

Keywords: *Aureobasidium melanigenum*, Catheter-related bloodstream infection, DNA sequence-based identification, Dimorphic fungus

Background

Aureobasidium is a ubiquitous, saprophytic, dematiaceous fungus found in fresh water, oil-treated wood, and even in houses [1–3]. It produces various useful materials, such as pullulan [4], which is used as a biocontrol product against post-harvest diseases of fruits and vegetables [5], and cosmetic and biomedical applications,

such as drug delivery, gene targeting, tissue engineering, and vaccination [6]. Therefore, research on its bioproducts is a hot topic in several fields, including biotechnology [7] and biomedical research [8].

Aureobasidium species are also known to be causative pathogens of human infections, especially *A. pullulans*. *A. pullulans* subspecies has been redefined to four species (*A. pullulans*, *A. melanigenum*, *A. subglaciale*, and *A. nambiae*) since 2014 [1]. The virulence of *Aureobasidium* species in a murine sepsis model showed no significant

*Correspondence: mhk-ikeda@umin.ac.jp

¹ Department of Infectious Disease, The University of Tokyo Hospital, 7-3-1, Hongo, Bunkyo-ku, Tokyo 113-8655, Japan

Full list of author information is available at the end of the article



difference among species; however, *A. melanigenum* with darkly pigmented colonies showed greater lethality [9].

In humans, *Aureobasidium* infection is usually cutaneous because it occurs due to traumatic inoculation of the skin [10–12] and eye [13, 14]. However, bloodstream infection due to an indwelling catheter can also occur [9, 15–17]. Data on *Aureobasidium* infection in humans are limited, especially regarding its diagnosis and management. Herein, we describe a case of *A. melanigenum* catheter-related bloodstream infection (CRBSI) in a patient receiving home care.

Case presentation

A 20-year-old man receiving home care with a long-term central venous catheter (CVC) was referred to our hospital with fever and dyspnea (day 0). Central parenteral nutrition through the CVC was started 2 years prior. His medical history included severe neurological disabilities due to cerebral injury after influenza encephalopathy, cardioplasty, esophagogastric disconnection, and small bowel resection due to postoperative ileus 3 years ago. His medications included lansoprazole, carbamazepine, triclofos sodium, baclofen, and daikenchuto.

On admission, he had a high-grade fever of 38.6 °C and chills. Physical examination revealed no significant abnormalities, except for scattered erythema. Laboratory data were as follows: white blood cell count 5700/μL; hemoglobin 11.8 g/dL; platelet count 243,000/μL; albumin 3.5 g/dL; total bilirubin 0.3 mg/dL; aspartate aminotransferase 20 U/L; alanine aminotransferase 33 U/L; γ-glutamyl transpeptidase, 178 U/L; serum creatinine 0.44 mg/dL; C-reactive protein 4.97 mg/dL; and procalcitonin 0.30 ng/mL. Cefazolin was started at a dosage of 0.5 g every 12 h due to a suspected CRBSI following collection of one set of blood cultures from the CVC. He still had fever between 38.1 and 39.3 °C and chills during cefazolin administration.

On day 3, yeast-like cells grew in an aerobic blood culture bottle obtained on admission (Fig. 1a). The serum beta-D glucan measured was 10.8 pg/mL (Wako Pure Chemical Industries, Ltd., Tokyo, Japan; cut-off value, < 11 pg/mL). Retinal examination revealed no evidence of endophthalmitis. Micafungin was added at a dose of 100 mg every 24 h against suspected candidemia after an additional set of blood cultures, and the CVC was removed. The patient became afebrile after initiating systemic antifungal therapy. The colony appeared rough and pale orange in color. The colony's India ink stain did not show a zone of clearance of ink particles, like *Cryptococcus*. Colonies were tested on CHROMagar Candida medium (Kanto Chemical Co., Inc., Tokyo, Japan) using matrix-assisted laser desorption/ionization time-of-flight mass spectrometry (MALDI-TOF MS, the MALDI

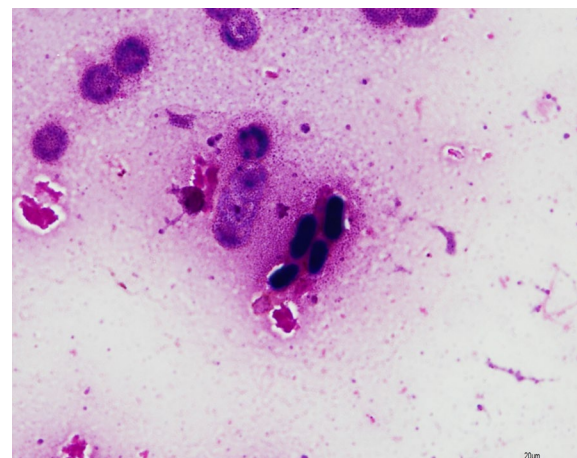


Fig. 1 Microscopy images of *Aureobasidium melanigenum* Gram stain (1000 ×) of positive blood cultures

Biotyper Reference Library Ver.4.0.0.1, Filamentous Fungi Library Ver.1.0; Bruker Daltoniks, Germany), identifying them as *Aureobasidium pullulans* (score 1.919). On day 6, the high fever recurred. Micafungin was stopped and liposomal-amphotericin B (L-AMB) was started (3 mg/kg/day) for *Cryptococcus albidus* owing to a 90% probability of identification using the VITEK2 COMPACT Microbial Detection System (version 8.01 database: SYS-MEX bioMerieux Co., Ltd., Tokyo, Japan).

The treatment was subsequently stopped because urticaria appeared after the 3-day use of L-AMB. After the discontinuation of L-AMB, no additional systemic antibiotics were administered. The patient remained afebrile. Minimum inhibitory concentrations (MIC) according to the reference method for broth dilution antifungal susceptibility testing of yeasts [18] were as follows: micafungin 0.25 μg/mL; caspofungin 0.5 μg/mL; AMPH-B 1 μg/mL; 5-flucytosine 0.25 μg/mL; fluconazole 8 μg/mL; itraconazole 0.06 μg/mL; and voriconazole 0.03 μg/mL.

The fungus was identified as *Aureobasidium*; however, it was impossible to differentiate between *A. pullulans* and *A. melanigenum* by sequencing the internal transcribed spacer regions. Comparison of the sequence from the isolate to sequences in the MYCOBANK database (<https://www.mycobank.org/>) revealed 99.82% similarity of the sequence with *A. pullulans* CBS 110.67 strain and 99.83% similarity with *A. melanigenum* CBS 123.37 strain. Next, the other two regions, β-tubulin and elongase, were compared using the BLAST database (<http://www.ncbi.nlm.nih.gov/BLAST>). The sequence of the isolate showed 88.5% similarity with *A. pullulans* CBS 584.75 strain and 94.20% similarity with *A. melanigenum* CBS 105.22 strain in the β-tubulin gene

region respectively, and in the elongase gene region, the sequence of the isolate showed 92.37% similarity with *A. pullulans* CBS 584.75 strain and 95.22% similarity with *A. melanigenum* CBS 109800 strain.

Therefore, the fungus was identified based on clustering in the phylogenetic analysis of β -tubulin and elongase genes with representative strains [19]. A phylogenetic tree was constructed by the neighbor-joining method using the MEGA X program [20] from the distance data generated by multi-alignment of the nucleotide sequence. A bootstrap value of 70% or more was considered as moderate support for the identification of clades. This fungus was placed in the *A. melanigenum* clade in the phylogenetic tree. Thus, the fungus was identified as *A. melanigenum*. The colonies were black (Fig. 2a), and conidiogenous cells were also detected (Fig. 2b). Fungemia was dismissed after day 7. The patient was discharged on day 27 without complications. There was no recurrence of *A. melanigenum* bloodstream infection.

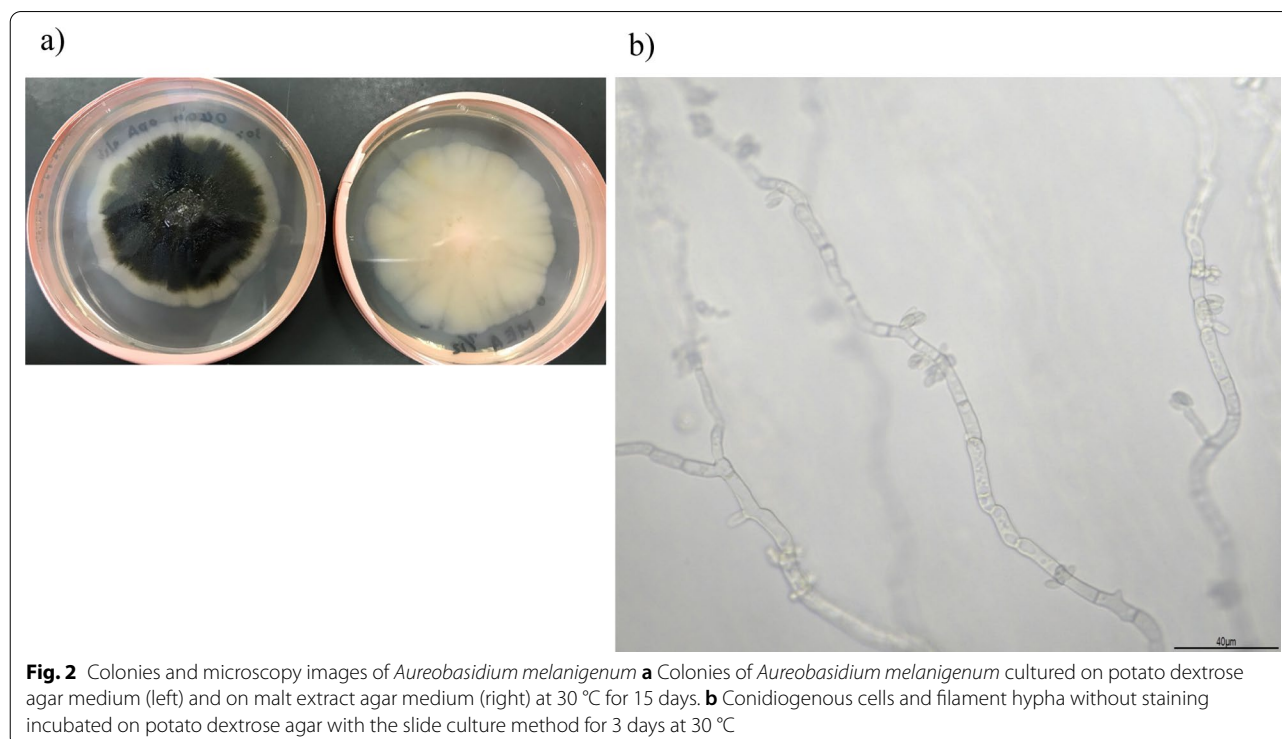
Discussion and conclusions

We describe a case of CRBSI caused by *A. melanigenum*, which was successfully treated by removing the CVC and antifungal therapy. The identification of *Aureobasidium* species using routine microbiological tests is difficult.

Little is known about the predisposing factors for *Aureobasidium* infections. Previous case reports and studies revealed the risk factors of *Aureobasidium*

infection, such as immunosuppressant use, steroids and HIV infection [21], cancer (with chemotherapy) [22], transplantation [23], trauma history [24], asplenia [25], leukemia [25, 26], and parenteral nutrition [21, 22]. *Aureobasidium* might be a more important pathogen in the future because of iatrogenic immunosuppression, such as solid organ transplant and massive chemotherapy, and artificial devices, such as central venous ports, would be increasing. In this case, the patient was not immunodeficient but might have been malnourished due to prolonged intravenous nutrition. The relationship between the medication used in this case and *Aureobasidium* infection was unclear.

The identification of *A. melanigenum* infection is difficult before the colonies darken. We could not confirm the species in the early phase of the case; hence, we could not suspect *Aureobasidium* infection. In addition, *A. melanigenum* is a dimorphic cell that initially mimics *Candida* species. The patient was initially diagnosed with candidemia based on the results of Gram staining. Conventional identification using MALDI-TOF MS or VITEK2 systems might also have the risk of misidentification, depending on the version of the database and the method of identification (e.g., in this case, MALDI-TOF MS database had only *A. pullulans* in *Aureobasidium* species). VITEK2 and MALDI-TOF MS analyses yielded different results for the identification of fungi, and both were incorrect in this case. Molecular methods play an



important role in confirming the identity of this organism. Because the sequencing of internal transcribed spacer regions could not differentiate between *A. pullulans* and *A. melanigenum*, additional sequencing of different regions, such as the β -tubulin gene and elongase gene, might be needed. Clinicians should consider that yeast-like cells suggest not only *Candida* and *Cryptococcus* species but also other pathogens, including *A. melanigenum*, although *Aureobasidium* remains a rare causative organism of catheter-related infections.

There are no established criteria for antifungal susceptibility of *Aureobasidium* species. *A. melanigenum* and *A. pullulans* showed similar antifungal susceptibility patterns, such as low MICs of amphotericin B, itraconazole, and posaconazole, and both had high MICs for fluconazole [23]. These susceptibilities were reported in a previous clinical report [24], and the pattern was the same as that observed in our case. Amphotericin B is recommended for *Aureobasidium* spp. in the clinical guidelines for systemic phaeohyphomycosis [25], although there is no standardized treatment for *Aureobasidium* infection.

For non-pharmacological management, catheter removal is the most important treatment approach for CRBSI caused by *A. melanigenum*. A previous report indicated that catheter removal was necessary for CVC-related *A. pullulans* septicemia [17]. Removal of the CVC might be critical to resolve fungemia because in our case, systemic antifungal therapy could not be continued for a sufficient duration. Hand hygiene before CVC care at home is also important to prevent infection by such fungi [26].

We have highlighted a case of CRBSI caused by *A. melanigenum*. Identification of *A. melanigenum* is difficult using conventional diagnostic approaches, and molecular methods play an important role in confirming *A. melanigenum* infection. Further studies are needed to determine the appropriate treatment for *Aureobasidium* infections.

Abbreviations

CRBSI: Catheter-related bloodstream infection; CVC: Central venous catheter; MALDI-TOF MS: Matrix-assisted laser desorption/ionization time-of-flight mass spectrometry; L-AMB: Liposomal-amphotericin B; MIC: Minimum inhibitory concentrations.

Acknowledgements

We would like to thank Editage (www.editage.com) for the English language editing.

Authors' contributions

SYT, MI, TS, and JF constitute our team that cared for the patient; SYT and MI drafted the manuscript and revised the manuscript; YO and YH, SYG offered the measuring microbiological data; HI, MY, YK, KO, SO, and KM suggested and revised the manuscript. All authors read and approved the final manuscript.

Funding

No funds, Grants, or other support was received.

Availability of data and materials

Not applicable.

Declarations

Ethics approval and consent to participate

Not applicable.

Consent for publication

Written informed consent was obtained from the patient's parents for publication of clinical details because the patient was incapable of expressing his intention due to cerebral palsy, and all decisions about the patients were made by the patient's parent.

Competing interests

The authors declare that they have no competing interests.

Author details

¹Department of Infectious Disease, The University of Tokyo Hospital, 7-3-1, Hongo, Bunkyo-ku, Tokyo 113-8655, Japan. ²Department of Infection Control and Prevention, The University of Tokyo Hospital, 7-3-1, Hongo, Bunkyo-ku, Tokyo 113-8655, Japan. ³Department of Pediatric Surgery, The University of Tokyo Hospital, 7-3-1, Hongo, Bunkyo-ku, Tokyo 113-8655, Japan. ⁴Department of Chemotherapy and Mycoses, National Institute of Infectious Diseases, Toyama 1-23-1, Shinjuku-ku, Tokyo 162-8640, Japan.

Received: 23 March 2021 Accepted: 24 March 2022

Published online: 05 April 2022

References

- Gostincar C, Ohm RA, Kogej T, Sonjak S, Turk M, Zajc J, Zalar P, Grube M, Sun H, Han J, et al. Genome sequencing of four *Aureobasidium pullulans* varieties: biotechnological potential, stress tolerance, and description of new species. *BMC Genomics*. 2014;15:549.
- van Nieuwenhuijzen EJ, Houbbraken JA, Meijer M, Adan OC, Samson RA. *Aureobasidium melanogenum*: a native of dark biofinishes on oil treated wood. *Antonie Van Leeuwenhoek*. 2016;109(5):661–83.
- Kaarakainen P, Rintala H, Vepsäläinen A, Hyvärinen A, Nevalainen A, Mekklin T. Microbial content of house dust samples determined with qPCR. *Sci Total Environ*. 2009;407(16):4673–80.
- Chi Z, Wang F, Chi Z, Yue L, Liu G, Zhang T. Bioproducts from *Aureobasidium pullulans*, a biotechnologically important yeast. *Appl Microbiol Biotechnol*. 2009;82(5):793–804.
- Agirman B, Erten H. Biocorrelability and action mechanisms of *Aureobasidium pullulans* GE17 and *Meyerozyma guilliermondii* KL3 against *Penicillium digitatum* DSM2750 and *Penicillium expansum* DSM62841 causing postharvest diseases. *Yeast*. 2020;37(9–10):437–48.
- Singh RS, Kaur N, Hassan M, Kennedy JF. Pullulan in biomedical research and development—a review. *Int J Biol Macromol*. 2021;166:694–706.
- Prasongsuk S, Lotrakul P, Ali I, Bankeeree W, Punnapayak H. The current status of *Aureobasidium pullulans* in biotechnology. *Folia Microbiol (Praha)*. 2018;63(2):129–40.
- Singh RS, Kaur N, Hassan M, Kennedy JF. Pullulan in biomedical research and development—a review. *Int J Biol Macromol*. 2020.
- Wang M, Danesi P, James TY, Al-Hatmi AMS, Najafzadeh MJ, Dolatabadi S, Ming C, Liou GY, Kang Y, de Hoog S. Comparative pathogenicity of opportunistic black yeasts in *Aureobasidium*. *Mycoses*. 2019;62(9):803–11.
- Chen WT, Tu ME, Sun PL. Superficial phaeohyphomycosis caused by *Aureobasidium melanogenum* mimicking *Tinea nigra* in an immunocompetent patient and review of published reports. *Mycopathologia*. 2016;181(7–8):555–60.
- Chan GF, Sinniah S, Idris TI, Puad MS, Abd Rahman AZ. Multiple rare opportunistic and pathogenic fungi in persistent foot skin infection. *Pak J Biol Sci*. 2013;16(5):208–18.
- Arranz Sanchez DM, de la Calle MC, Martin-Diaz MA, Flores CR, Gonzalez-Beato MJ, Pinto PH, Diaz Diaz RM. Subcutaneous mycosis produced by *Aureobasidium pullulans* in a renal transplant recipient. *J Eur Acad Dermatol Venereol*. 2006;20(2):229–30.

13. Maverick KJ, Conners MS. *Aureobasidium pullulans* fungal keratitis following LASEK. *J Refract Surg*. 2007;23(7):727–9.
14. Chawla B, Sharma N, Titiyal JS, Nayak N, Satpathy G. *Aureobasidium pullulans* Keratitis Following Automated Lamellar Therapeutic Keratoplasty. *Ophthalmic Surg Lasers Imaging* 2010:1–3.
15. Huang YT, Liaw SJ, Liao CH, Yang JL, Lai DM, Lee YC, Hsueh PR. Catheter-related septicemia due to *Aureobasidium pullulans*. *Int J Infect Dis*. 2008;12(6):e137–139.
16. Hawkes M, Rennie R, Sand C, Vaudry W. *Aureobasidium pullulans* infection: fungemia in an infant and a review of human cases. *Diagn Microbiol Infect Dis*. 2005;51(3):209–13.
17. Wang SC, Lo HJ, Lin LJ, Chen CH. Port catheter-associated *Aureobasidium melanigenum* fungemia. *J Formos Med Assoc*. 2018;117(4):346–7.
18. Clinical and Laboratory Standards Institute. Reference Method for Broth Dilution Antifungal Susceptibility Testing of Yeasts; Approved Standard CLSI document M27-A3, 3rd edition. 950 West Valley Road, Suite 2500, Wayne, Pennsylvania 19087 USA.
19. Zalar P, Gostincar C, de Hoog GS, Ursic V, Sudhadham M, Gunde-Cimerman N. Redefinition of *Aureobasidium pullulans* and its varieties. *Stud Mycol*. 2008;61:21–38.
20. Kumar S, Stecher G, Li M, Knyaz C, Tamura K. MEGA X: molecular evolutionary genetics analysis across computing platforms. *Mol Biol Evol*. 2018;35(6):1547–9.
21. Mittal J, Szymczak WA, Pirofski LA, Galen BT. Fungemia caused by *Aureobasidium pullulans* in a patient with advanced AIDS: a case report and review of the medical literature. *JMM Case Rep*. 2018;5(4):e005144.
22. Mehta SR, Johns S, Stark P, Fierer J. Successful treatment of *Aureobasidium pullulans* central catheter-related fungemia and septic pulmonary emboli. *IDCases*. 2017;10:65–7.
23. Najafzadeh MJ, Sutton DA, Keisari MS, Zarrinfar H, de Hoog GS, Chowdhary A, Meis JF. In vitro activities of eight antifungal drugs against 104 environmental and clinical isolates of *Aureobasidium pullulans*. *Antimicrob Agents Chemother*. 2014;58(9):5629–31.
24. Oliveira LR, Moraes-Souza H, Maltos AL, Santos KC, Molina RJ, Barata CH. *Aureobasidium pullulans* infection in a patient with chronic lymphocytic leukemia. *Rev Soc Bras Med Trop*. 2013;46(5):660–2.
25. Chowdhary A, Meis JF, Guarro J, de Hoog GS, Kathuria S, Arendrup MC, Arikian-Akdagli S, Akova M, Boekhout T, Caira M, et al. ESCMID and ECMM joint clinical guidelines for the diagnosis and management of systemic phaeohyphomycosis: diseases caused by black fungi. *Clin Microbiol Infect*. 2014;20(Suppl 3):47–75.
26. Chamroensakchai T, Leedumrongwattanukul K, Takkavatakarn K, Manuprasert W, Kanjanabuch T. Peritoneal dialysis (PD) catheter-related peritonitis from *Aureobasidium pullulans* caused by poor caregiver's hand hygiene. *Med Mycol Case Rep*. 2019;25:35–8.

Publisher's Note

Springer Nature remains neutral with regard to jurisdictional claims in published maps and institutional affiliations.

Ready to submit your research? Choose BMC and benefit from:

- fast, convenient online submission
- thorough peer review by experienced researchers in your field
- rapid publication on acceptance
- support for research data, including large and complex data types
- gold Open Access which fosters wider collaboration and increased citations
- maximum visibility for your research: over 100M website views per year

At BMC, research is always in progress.

Learn more biomedcentral.com/submissions

