



Contents lists available at ScienceDirect

## International Journal of Surgery Case Reports

journal homepage: [www.casereports.com](http://www.casereports.com)

## Cryptogenic stroke following abdominal free flap breast reconstruction surgery

Huizhuang Xie<sup>a</sup>, Charles M. Malata<sup>b,c,d,\*</sup><sup>a</sup> School of Clinical Medicine, University College Cork, Ireland<sup>b</sup> Plastic & Reconstructive Surgery Department, Addenbrooke's Hospital, Cambridge University Hospitals NHS Foundation Trust, Cambridge, UK<sup>c</sup> Cambridge Breast Unit, Cambridge University Hospitals NHS Foundation Trust, UK<sup>d</sup> Postgraduate Medical Institute at Anglia Ruskin University, Cambridge & Chelmsford, UK

## ARTICLE INFO

## Article history:

Received 26 November 2013

Received in revised form 5 September 2014

Accepted 12 October 2014

Available online 11 November 2014

## Keywords:

Cryptogenic stroke

CVA (cerebrovascular accident)

Cardiovascular abnormalities

Microvascular breast reconstruction

Unusual complication of DIEP flap

Patent foramen ovale (PFO)

## ABSTRACT

**INTRODUCTION:** Abdominal free flap breast reconstruction is regarded as the gold standard method of post-mastectomy breast reconstruction by many. It is a major surgery which can be associated with varied systemic complications. To date, there have been no reports of cerebrovascular complications in the literature which examine the possible relation between thromboembolism and patent foramen ovale (PFO) in patients undergoing microvascular breast reconstruction.

**PRESENTATION OF CASE:** A 54-year old female with a pre-existing PFO developed a stroke following bilateral mastectomies and immediate free flap breast reconstruction on postoperative day 5. This was attributed to an air embolus caused by central venous pressure line removal. After uneventful intra and early postoperative periods, the patient had collapsed suddenly on day 5 and become unresponsive immediately following the removal of a central venous line. Brain magnetic resonance imaging confirmed a cerebrovascular accident. This resolved within 48 h following therapeutic heparinisation. A clinical diagnosis of paradoxical embolism was made and she was subsequently referred to the cardiologists for angiographic closure of the PFO.

**DISCUSSION:** The case study herein reported gives an account that PFO can have considerable health implications in the early postoperative period and conceivably intraoperatively in patients undergoing major reconstructive surgeries.

**CONCLUSION:** Surgeons and cardiologists should be aware of this cerebrovascular complication secondary to PFO following major reconstructive surgery such as microvascular breast reconstruction. It also serves to challenge microvascular surgeons to reconsider routine use of central venous pressure lines in free flap patients who might otherwise have good peripheral vessels for postoperative fluid and antibiotic administration.

© 2014 The Authors. Published by Elsevier Ltd. on behalf of Surgical Associates Ltd. This is an open access article under the CC BY-NC-ND license (<http://creativecommons.org/licenses/by-nc-nd/3.0/>).

## 1. Introduction

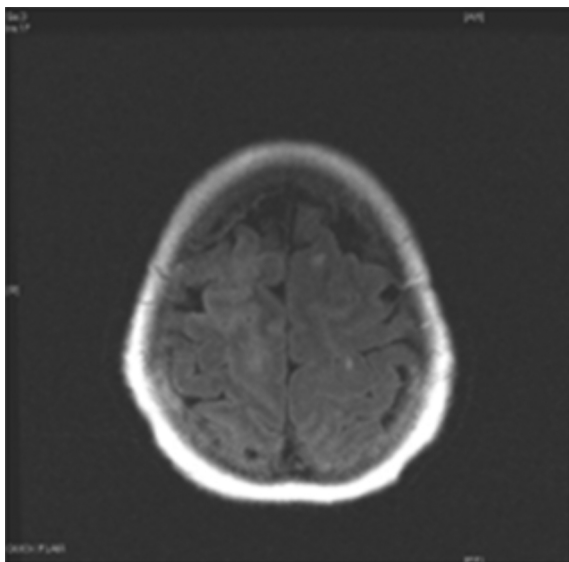
Autogenous tissue based microsurgical breast reconstruction has over the years grown in popularity as an important component of breast cancer treatment. Established options include the free transverse rectus abdominis myocutaneous (TRAM), deep inferior epigastric perforator (DIEP), superficial inferior epigastric (SIEA),

gluteal artery perforator (GAP) and transverse upper gracilis (TUG) flaps. Abdominal free flap breast reconstruction is regarded as the gold standard method of post-mastectomy breast reconstruction by many. It has been associated with a variety of systemic complications such as deep vein thrombosis, pulmonary embolism and pneumonia.<sup>1</sup> However, to the best of our knowledge, there has been no reported cerebrovascular complication of such surgery, let alone any studies examining the possible relation between thromboembolism and patent foramen ovale (PFO) in patients undergoing microvascular breast reconstruction.

While most adult patients with isolated patent foramen ovale are asymptomatic and have no associated abnormal cardiac clinical findings, it has been implicated as a cause of cryptogenic cerebrovascular accident (CVA) in both the younger people and older (greater than 55 years of age) patients.<sup>2</sup>

\* Corresponding author at: Department of Plastic and Reconstructive Surgery, Box 186, Addenbrooke's University Hospital, Cambridge University Hospitals NHS Foundation Trust, Cambridge CB2 2QQ, UK. Tel.: +44 1223 586672; fax: +44 1223 257177.

E-mail address: [cmalata@hotmail.com](mailto:cmalata@hotmail.com) (C.M. Malata).



**Fig. 1.** MRI image shows signs of recent infarct in the right frontal and occipital lobes.

A patient with PFO who subsequently developed a CVA from an air embolus caused by CVP line removal 5 days after immediate bilateral abdominal free flap breast reconstruction is herein presented.

## 2. Presentation of case

A 54-year old BRCA-1 gene mutation carrier underwent bilateral mastectomies with immediate abdominal free flap breast reconstruction following primary chemotherapy for a right breast cancer. This was on a background history of a right sided transient ischaemic attack (TIA) 10 years previously. The patient had no history of diabetes, smoking, hypertension or hypercholesterolaemia. Transoesophageal echocardiography (TOE) had revealed a patent foramen ovale (PFO) as well as a small right to left shunt on valsalva. She had thus been placed on long-term aspirin as secondary TIA prevention.

The surgery was uneventful and she had a good early postoperative recovery. However, on postoperative day 5, she collapsed suddenly and became hypoxic and unresponsive following the injudicious removal of a central venous line (right internal jugular triple lumen line) which was performed while the patient was still sat up. On examination, patient was hypertensive and ECG showed sinus tachycardia. There were neurological deficits comprising left sided motor and sensory loss, left sided neglect and anosognosia following resuscitation.

The patient was referred to the on-call physician team who, after an assessment, suspected that the patient's cardiorespiratory collapse and the subsequent infarcts were due to venous thromboembolism or platelet emboli. The patient was thus commenced on therapeutic doses of heparin. Emergency brain and chest computed tomography (CT) scans were unremarkable but subsequent magnetic resonance imaging (MRI) brain scan revealed changes of acute infarction in both the frontal and occipital lobes (Fig. 1) and these findings were reported as confirming a cerebrovascular accident.

However, clinically this eventually resolved within 48 h following therapeutic heparinisation of 1.5 mg/kg once daily by subcutaneous injection (112.5 mg of tinzaparin). She went on to make an uneventful recovery apart from an expanding right breast haematoma secondary to the heparinisation which was successfully evacuated under local anaesthetic without flap compromise.

A clinical diagnosis of paradoxical embolism was made and the patient was subsequently referred to the cardiologists for angiographic closure of the PFO.

## 3. Discussion

### 3.1. Complications of microvascular breast reconstructive surgery in a PFO patient

Patients with interatrial communications such as PFO are at a higher risk for paradoxical embolic events leading to stroke. In the *Patent Foramen Ovale in Cryptogenic Stroke Study* (PICSS), a third (33.8%) of patients, aged 30–85 years old, were found to have a PFO present.<sup>3</sup>

Local complications of abdominal flap breast reconstruction such as haematoma, seroma, wound infection, skin necrosis, hernias, etc. are well documented in the literature. Systemic complications such as pulmonary thrombosis and deep vein thrombosis (DVT) have also been reported.<sup>4</sup> In the case study reported, a 54-year old known PFO patient underwent immediate bilateral abdominal free flap breast reconstruction in an operation which lasted 11 h. Although the surgery was uncomplicated, the patient subsequently developed the unusual complication of cryptogenic stroke which was later found to be an air embolus which had navigated its way to the systemic circulation via her PFO.

This unique complication raises a number of interesting issues relating to PFO patients and breast reconstruction surgery. First and foremost, should known PFO status be considered as a contraindication to major reconstructive surgery such as bilateral microvascular flap breast reconstruction with its potentially increased risk of venous thromboembolism and paradoxical embolism? It also raises the issue of the appropriate measures that could be taken in such patients to prevent a CVA other than a surgical closure of PFO. It is important to note that PFO closure in this patient was not practicable prior to breast reconstruction as she had a large invasive breast cancer, necessitating primary chemotherapy and therefore had to be surgically treated urgently within the chemotherapeutic window.<sup>5</sup> Lastly, it is not known if PFO has an impact on postoperative recovery after an autologous breast reconstruction. However, in the case presented, the PFO acted as the mechanism by which an air embolus in a central vein had likely made its way into the cerebral vascular circulation. Fortunately, the air embolus was absorbed upon administration of high percentage oxygen to aid in air bubble reduction and prevent further ischaemia and the patient eventually made a full recovery.

Currently, there are no consensus protocols on the optimal management of PFO in those patients with cryptogenic stroke. Also, apart from a surgical closure of PFO which might not be the most ideal option in a breast cancer patient, other appropriate medical management options such as warfarin, aspirin or both to prevent a CVA should be discussed with the patient, if they are well enough to give informed consent.

### 3.2. Iatrogenic implications of central venous line removal

Although in this case study, microvascular surgery per se might not constitute a specific risk factor for paradoxical embolism any more than other operations of a similar magnitude, however, a PFO patient undergoing a lengthy operation might entail a higher risk profile for the entrapment of air from operative field into the venous or arterial vasculature. Another aetiological reason is the iatrogenic creation of pressure gradient such as during the insertion and removal of central venous catheter which allows air entry into the circulation. Also, in up to 35% of the general population, PFO is present which can cause paradoxical systemic air embolism

when air passes from the right to the left side of the heart which in turn can lead to ischaemic events such as stroke or myocardial ischaemia.

### 3.3. Paradoxical embolisation and PFO

Paradoxical embolisation is a syndrome which occurs when emboli arise from the venous circulation and enter the arterial circulation through an atrial septal defect or a right-to-left shunt such as patent foramen ovale and results in occlusive effects distally such as the cerebral ischaemia reported in our patient. This phenomenon is a rare and possibly underdiagnosed cause of ischaemic stroke. In the report by Loscalzo<sup>6</sup> which reviewed thirty cases of paradoxical embolism to consolidate clinical presentations and predisposing factors, seven of the thirty patients had had a recent operation. Therefore, the recognition of the potential diagnosis of paradoxical embolisation is important in any patient undergoing major and lengthy surgeries.

Of note, although the patient had a previous TIA episode, which is a risk factor by itself which puts patients at a higher risk of stroke recurrence, however this was a past medical history of TIA event that had happened 10 years previously. The risk of stroke after a TIA is only highest in the early period (first few days to weeks) after the TIA. TIA is associated with high early risk of stroke with 3.5%, 8.0% and 9.2% at 2, 30 and 90 days after TIA.<sup>7</sup> Also, the patient had since been under continual care and placed on long term aspirin as secondary TIA prevention.

The investigative workup of a suspicious paradoxical embolisation diagnosis should include a computed tomographic scan of the brain to differentiate between a haemorrhagic and an ischaemic stroke. Other serial measurements to rule out a myocardial infarction include cardiac isoenzymes (such as troponin) and electrocardiography. Other useful investigations comprise cardiac echocardiography and duplex scanning of the carotid artery to locate any thrombi associated with arteromatous plaques. In a patient with suspected paradoxical embolism, transesophageal echocardiography with contrast medium has been shown to be the investigation of choice to detect any patent foramen ovale or other heart defects. Treatment should then be initiated with anticoagulation therapy such as heparin followed by warfarin in patients with no contraindications for at least three months. In patients who have a large right-to-left shunt discovered on imaging, a vena caval filter device or an operative closure of a patent foramen ovale should be considered. However, these further investigations are dependent on the surgeons or physicians caring for the patient being aware of the potential diagnosis of paradoxical embolism in such a setting.

### 3.4. Learning points in this case study

This case report serves as a useful reminder to all healthcare professionals that their patients can develop unusual and rare systemic complications of surgery. It highlights the possibility that major reconstructive surgery such as bilateral microvascular breast reconstruction and its invasive monitoring and attendant vascular access lines constitute risk factors for vascular air embolism. Although microvascular surgery per se might not represent a specific risk factor for paradoxical embolism any more than other operations of a similar magnitude, however, a PFO patient undergoing such surgery has a risk similar to anyone undergoing microvascular anastomoses to the internal mammary vein as air may be sucked into the internal mammary vein but this risk is no higher whether the patient has a PFO or not. Nevertheless, in a PFO patient the air embolus might be transferred to the left side of the circulation and this is the main point being put across in the present case report. Microvascular surgical anastomoses to large veins with a significant “venturi effect” is a risk factor for air embolism (and

not paradoxical embolism per se). Paradoxical embolism, however, makes such air embolism more serious than otherwise it would be. Hence, this topic is relevant for not only plastic surgeons but also physicians alike when a known PFO status patient is being considered for major and lengthy reconstructive surgeries. The two main purposes of this case study are:

- Microvascular surgery poses a risk factor for air embolism which might have catastrophic effects in a PFO patient where the air embolus can be shunted from the right to the left sided circulation.
- It also serves to challenge microvascular surgeons to reconsider routine use of central venous pressure lines in patients who might otherwise have good peripheral vessels for postoperative fluid and antibiotic administration.

The injudicious removal of the central venous pressure (CVP) line, in this case, was performed while the patient was still sat up. Because of the every-so-often dramatic consequences of air embolism which can be accentuated in a PFO patient, the best practice of catheter removal should be emphasised. This is the major learning point for nurses, residents and other medical staff. There are no specific data to support various techniques used to prevent air embolism during CVP line removal. However, the Trendelenburg's position (head – down position) is a favoured practice during central venous pressure (CVP) line removal as the exit site is then below the level of the right atrium. Also, the CVP line should ideally be removed during exhalation as inspiration allows air to be entrained into the venous circulation when intrathoracic pressure decreases below the atmospheric pressure. Immediately following line removal, firm pressure with gauze should be applied at the exit site until haemostasis is obtained and the wound should then be sealed with an air occlusive dressing or sterile gauze. The patient should then remain in the recumbent or horizontal position for at least 15 min.

## 4. Conclusion

While there is a paucity of information on how a significant cardiac abnormality such as PFO should be managed in the context of planned major breast reconstructive surgery, as illustrated in the present case report, a patent PFO can have considerable health implications in the postoperative period and conceivably intra-operatively in patients undergoing major surgeries. One should consider the diagnosis of paradoxical air embolism in any patient with neurological deficit in whom there is no definite left sided circulatory source. This principle applies predominantly if there is concomitant enhanced potential for venous thrombosis to occur due to prolonged immobility or endothelial damage caused by trauma or major surgeries. As such, awareness of this unique and unusual cerebrovascular complication secondary to PFO case report should be heightened.

### Conflict of interest

None.

### Funding

None.

### Ethical approval

Written informed consent was obtained from the patient for publication of this case report and accompanying images. A copy

of the written consent is available for review by the Editor-in-Chief of this journal on request.

#### Author contributions

Xie Huizhuang: data collection, data analysis, writing of report;  
Charles Malata: data analysis, chief investigator, editing of report.

#### References

1. Roje Z, Janković S, Ninković M. Breast reconstruction after mastectomy. *Coll Antropol* 2010;**34**(Suppl. 1):113–23.
2. Handke M, Harloff A, Olschewski M, Hetzel M, Geibel A. Annette patent foramen ovale and cryptogenic stroke in older patients. *N Engl J Med* 2007;**357**:2262–8.
3. Homma S, Sacco RL, Di Tullio MR, Sciacca RR, Mohr JP. Effect of medical treatment in stroke patients with patent foramen ovale: patent foramen ovale in Cryptogenic Stroke Study. *Circulation* 2002;**105**:2625–31.
4. Khouri RK, Ahn CY, Salzhauer MA, Scherff D, Shaw WW. Simultaneous bilateral breast reconstruction with the transverse rectus abdominus musculocutaneous free flap. *Ann Surg* 1997;**226**:25–34.
5. Azzawi K, Ismail A, Earl H, Forouhi P, Malata CM. Influence of neoadjuvant chemotherapy on outcomes of immediate breast reconstruction. *Plast Reconstr Surg* 2010;**126**:1–11.
6. Loscalzo J. Paradoxical embolism: clinical presentation, diagnostic strategies and therapeutic options. *Am Heart J* 1986;**112**:141–5.
7. Wu CM, McLaughlin K, Lorenzetti DL, Hill MD, Manns BJ, Ghali WA. Early risk of stroke after transient ischemic attack: a systematic review and meta-analysis. *Arch Intern Med* 2007;**167**(22):2417–22, <http://dx.doi.org/10.1001/archinte.167.22.2417>.

#### Open Access

This article is published Open Access at [scimedirect.com](http://scimedirect.com). It is distributed under the [IJSCR Supplemental terms and conditions](#), which permits unrestricted non commercial use, distribution, and reproduction in any medium, provided the original authors and source are credited.