

# A Post-Aspiration Giant Spermatocele in a Young Man: A Case Report and Literature Review

Nader Salama<sup>1</sup>  and Omer Sirelkhatim Hassan<sup>2</sup>

<sup>1</sup>Department of Urology, Alexandria Faculty of Medicine, Alexandria, Egypt. <sup>2</sup>Department of Urology, Bahari Faculty of Medicine, Khartoum Bahari, Sudan.

Clinical Medicine Insights: Case Reports  
Volume 15: 1–5  
© The Author(s) 2022  
Article reuse guidelines:  
sagepub.com/journals-permissions  
DOI: 10.1177/11795476221097218



**ABSTRACT:** We report a case of a post-aspiration giant unilocular spermatocele in a young man. A 27-year-old man sought medical advice for a huge right scrotal swelling. The swelling first appeared following scrotal trauma and was aspirated. Shortly after, it reappeared and persisted for several years with a sense of heaviness, infrequent periods of right scrotal pain, and cosmetic concerns. Ultrasonography of the scrotum revealed a huge fluid cyst pushing the testis antero-inferiorly in the right hemi-scrotum. Scrotal exploration suggested the spermatocele nature of the cyst that emerged from the head of the epididymis. The cyst was excised, and its fluid content and wall underwent pathological examination for confirmation.

**KEYWORDS:** Spermatocele, giant, aspiration, scrotum

**RECEIVED:** January 31, 2022. **ACCEPTED:** April 4, 2022.

**TYPE:** Case Report

**FUNDING:** The author(s) received no financial support for the research, authorship, and/or publication of this article.

**DECLARATION OF CONFLICTING INTERESTS:** The author(s) declared no potential conflicts of interest with respect to the research, authorship, and/or publication of this article.

**CORRESPONDING AUTHOR:** Omer Sirelkhatim Hassan, Department of Urology, Faculty of Medicine, University of Bahari, Khartoum Bahari Elkadaro, Sudan.  
Email: Omerelsir4002@gmail.com

## Introduction

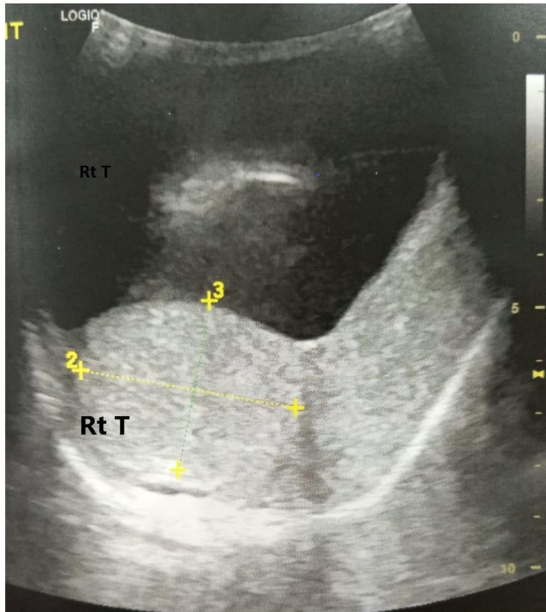
Spermatocele is one of the common cystic lesions of the scrotum. It appears on the head of the epididymis, mostly due to the partial or complete obstruction of one of the efferent ductules. Less ordinarily, it arises from the tubules of the rete testis or the aberrant ducts.<sup>1,2</sup> It is commonly unilateral, solitary, less than 1 cm in diameter, and therefore it is often asymptomatic.<sup>1,2</sup> It infrequently gets big enough to bother the patient, be associated with scrotal heaviness, raise suspicions of neoplasm, or necessitate treatment.<sup>3–11</sup> This condition is typically insidious and its diagnosis is incidental; therefore, its true incidence has not been documented yet. However, spermatoceles are common as some authors reported an incidence of 30% in men who underwent scrotal sonographic scanning for different reasons.<sup>12</sup> In the literature, spermatocele has its peak incidence in men aged 65 to 74 years; therefore, it is considered a disease of elderly men.<sup>13</sup> Herein, we report a case of a symptomatic post-aspiration giant spermatocele in a young man followed by a brief review of the literature.

## Case Presentation

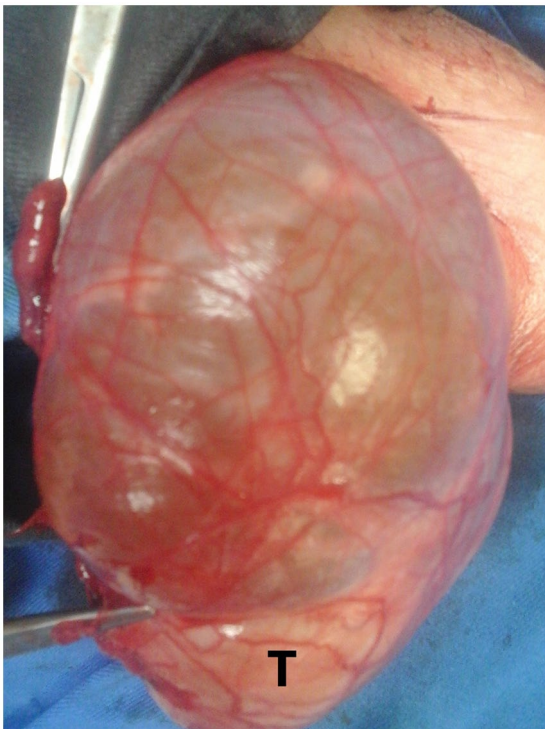
A 27-year-old male religious teacher consulted the Urology Outpatient Clinic of the Alexandria Main University hospital for right scrotal swelling. The patient's history revealed a scrotal trauma during his childhood at the age of 10 years when his colleague in the school directly kicked his scrotum. About 2 months after this incident, he noticed a painless swelling at the same site of the trauma at the right hemi-scrotum. The swelling gradually increased in size and soon reached the size of a ball, about 5 cm diameter. Three years later, the patient's father sought medical advice concerning his son's condition. Aspiration of the scrotal swelling was done, and the swelling

disappeared. Unfortunately, all the clinical and radiological data related to this event were lost. A few months later, the same scrotal swelling reappeared. No genitourinary infection or recent scrotal trauma was associated with the newly developing swelling. The patient had no past sexual experience and did not practise masturbation because of his strict religious background. The swelling increased gradually in size over the last 13 years and eventually outgrew its initial size. The patient did not attempt to consult a physician all this time because he was shy; however, his upcoming wedding pushed him to consult a physician in our hospital. The patient infrequently complained of a dragging pain in his right scrotum, mostly at the end of the day at work. His physical examination revealed, on inspection, a huge elliptical swelling in the right hemi-scrotum. The swelling was superior and posterior to the right testis. On palpation, the swelling was soft, non-tender, non-fluctuating, and extended upwards, hiding the spermatic cord. The overlying skin was free. The physical examination of his left hemi-scrotum was unremarkable. The transillumination test was positive indicating the cystic nature of the swelling. The results of the hematological, biochemical, and hormonal evaluations were unremarkable. The urine examination did not reveal any infection. His semen evaluation presented normal parameters. The color duplex scanning of the scrotum revealed a unilocular, well-demarcated, anechoic cystic mass (measuring 7 cm × 7 cm) with a posterior acoustic enhancement in the right hemi-scrotum. The mass was overriding and pushing the testis inferiorly to the bottom of the scrotum (Figure 1), suggesting the existence of a giant spermatocele. The right epididymis could not be seen during the duplex examination, in contrast to the left epididymis, that was of normal size and echogenicity. Both testicular volumes



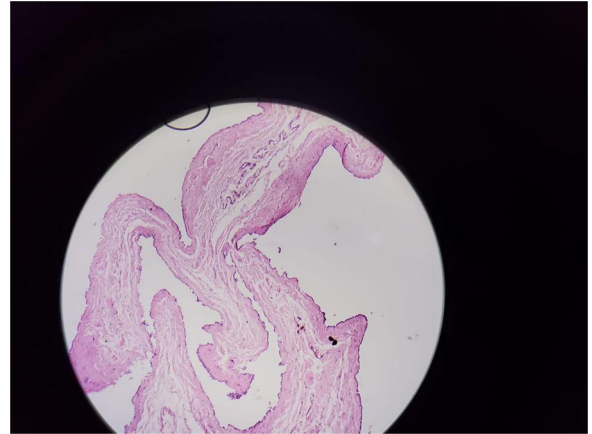


**Figure 1.** A grayscale image of the right scrotal sac showed a well-demarcated unilocular giant cyst positioned superiorly to the right testis (Rt T) suggesting a spermatocele. The hyperechoic line and dots around it were just artifacts.



**Figure 2.** The spermatocele was overriding the superior and posterior aspects of the testis (T), pushing it inferiorly and anteriorly but not enveloping it as is the case in a hydrocele. The tunical covering of the testis was maintained.

were normal and testes showed diffuse homogenous parenchymal echo patterns. There were no focal lesions or calcification in the testes, which also indicated preserved parenchymal



**Figure 3.** Histopathological examinations of the cyst revealed ciliated cuboidal epithelium lining its wall. The epithelium formed papillary infoldings.

vasculature. Surgical exploration was expedited through a right scrotal incision. The cyst was dissected bluntly from the wall of the scrotum (Figure 2), after which it was separated gently from the spermatic cord, testis, and epididymis. During the separation, adherence was observed between the mass and the head of the epididymis. The cyst was excised and the testis was returned into the scrotum. The incision was closed 1 layer at a time. The cyst was then opened, and its fluid content, which was slightly turbid and straw-colored, was collected (250 ml in volume). Two samples of the fluid were taken. One of the samples was examined using a light microscope and found to contain no pus cells or sperm cells. However, the sample was not further processed, and centrifuged, as in the case of cryptozoospermia, to show any possible rare sperm in the resulting sediment.<sup>14</sup> The albumin level in the other sample was measured (4.6 g/100 ml) and found to be higher than the serum albumin level (3.76 g/100 ml). The specimen was sent for histopathological examination, that revealed a cyst wall lined with a single layer of ciliated cuboidal epithelium with focal papillae (Figure 3). The postoperative course was uneventful, and the patient was discharged from the hospital to go home.

### Discussion

A spermatocele is usually defined as a sperm-containing cyst inside the scrotum.<sup>1,12,13</sup> It is usually confined to the epididymal head, where it mostly originates following the dilation of the efferent ductules, although it may also commence from the expansion of tubules of the rete testis or aberrant ducts.<sup>1,2</sup> The exact dilation of these para-testicular tubules and the pathogenesis of the spermatocele have not yet been determined. The onset of spermatoceles is usually idiopathic. However, the dilation of these tubules may develop secondary to trauma, epididymitis, or scrotal surgery.<sup>2,4</sup> In the present report, a connecting relationship between spermatocele development and scrotal trauma seemed evocative. This agrees with Crossan<sup>2</sup> who stated that “the (scrotal) swelling or tumor is what is most

complained of, and if this is a slowly progressive affair following trauma, it would cause one to be suspicious of spermatocele." Therefore, the history of trauma in the present report can attract attention to the possibility of the existing condition. In his illustrative, although now outdated, article, Crossan<sup>2</sup> summarized the proposed relationship between trauma and spermatocele given by Hochenegg (an earlier researcher, cited in Crossan's article). This former researcher suggested that scrotal trauma can push the testis, which is a mobile organ, to move while the epididymis, which is a fixed structure, cannot follow this movement. This puts tension on the efferent ductules while piercing the tunica albuginea and eventually its obliteration. Other researchers suggested additional mechanisms for spermatocele evolution. In this context, Itoh et al<sup>15</sup> proposed that immature germ cells may agglutinate after shedding out the seminiferous epithelium in old people and block the restricted lumen of the spermatic conduits, bringing about the development of a spermatocele. That is why spermatocele is more common in old men.<sup>13,15</sup> On the other hand, Bay et al<sup>16</sup> speculated that a hormonal disturbance may occur during intrauterine fetal life, which may induce the weakening of the external layer of the epididymis, which is an androgen-dependent organ, with diverticulum creation and the development of a spermatocele.

A giant spermatocele is a rare occurrence. A search of the PubMed database for articles in English on this subject matter could yield 9 cases of giant spermatoceles.<sup>3-11</sup> A giant spermatocele is usually single and unilocular, just like the one in the present case report. However, bilateral<sup>5,10</sup> multilocular<sup>3,5,6</sup> spermatoceles have been reported in the literature. Six of the reported cases of giant spermatoceles occurred in men above 40 years<sup>3,5-8,11</sup> unlike our patient. The remaining 3 cases involved males aged 14, 27, and 40 years.<sup>4,9,10</sup> All the reported cases seemed to be idiopathic, except for 1 case with a history of scrotal trauma,<sup>4</sup> like our patient. A search of accessible database using the index terms "aspiration," "giant spermatocele," and "young adult" was also unfruitful. Therefore, to the best of our knowledge, this present case report is the first one for a post-aspiration giant spermatocele in a young man with a history of scrotal trauma, that initially started during childhood.

Patients with spermatoceles usually seek medical advice when the lesion increases in size (which usually occur over many years) or when the spermatocele becomes painful. This has been reported to take approximately 3 to 132 months (mean 48 months).<sup>17</sup> As long as this duration is, it is still shorter than that in the current case report (which included 2 durations: the first was 3 years [36 months] before the aspiration of the cyst, and the second was 13 years [156 months] before surgery). In the present report, the patient also endured the condition and refrained from surgery for many years, despite the giant size of his scrotum. However, he did not believe his

scrotal swelling was a "third testis" like some men who perceive spermatoceles as an extra testis.<sup>18</sup>

Such giant scrotal swellings as the one in this case report are frequently believed to be a vaginal hydroceles. However, a careful diagnostic workup can help establish the correct diagnosis. Spermatoceles usually occur on the upper part of the testis, pushing it inferiorly. Usually, they can be felt as distinct structures. In contrast, the hydrocele surrounds the testis on the lateral and anterior aspects without displacing, which gives the false impression of an enlarged testis.<sup>19</sup> Ultrasonography can aid in differentiating one from the other. The hydrocele mostly demonstrates an echo-free cystic structure that envelops the testis<sup>19</sup> while the spermatocele may show low-level internal echoes due to the presence of plenty of sperms or other cells, which may move away from the colored duplex probe on compression, giving the characteristic falling snow sign.<sup>20</sup> In the current report, the patient presented with a single pathology (spermatocele). Various inguinal and scrotal associations have been reported with spermatocele like intratesticular varicocele,<sup>21</sup> indirect inguinal hernia,<sup>11</sup> extra scrotal spermatocele extending into the inguinal canal,<sup>22</sup> and associated hydrocele in the same side.<sup>23</sup>

When aspiration is done alone for spermatocele, it usually reaccumulates.<sup>13,23</sup> This scenario was seen during the initial treatment (aspiration) of the patient in our case report. Therefore, aspiration followed by sclerotherapy has been practised by some physicians to stop the recurrence.<sup>23</sup>

Spermatoceles have been managed via surgical excision, which is currently regarded as the gold standard of treatment.<sup>13</sup> Surgery is usually recommended when the diameter of the spermatocele reaches 4 cm and if it is associated with symptoms that cause the patient discomfort, such as cosmetic concerns or scrotal pain (as is the case in the present report) or if there is an associated hernia or hydrocele.<sup>3-11,23</sup> Surgery is also indicated if a neoplastic pathology cannot be ruled out. Adenocarcinoma of the rete testis has been reported in the literature.<sup>24</sup> Some cases may present with soft scrotal swellings,<sup>24</sup> which was the case in the patient in this case report. In giant spermatoceles, surgery is also advisable because the torsions of the testis<sup>10</sup> and the cyst itself around its pedicle<sup>4,9</sup> are documented possibilities. Takimoto et al<sup>4</sup> tried to explain the occurrence of testicular torsion in such cases. Their hypothesis relied on the concept that the axis of the spermatic cord may be disturbed by the big size of the spermatocele, which increases the traction force on the cord.

A review of the literature revealed that the terms "epididymal cyst" and "spermatocele" have been utilized conversely or even inaccurately to describe the same pathology as that of the patient in the case report by Ameli et al.<sup>9</sup> This is in line with the findings of some authors who noticed the inability to differentiate between the 2 terms over the last 40 years.<sup>25</sup>

Such diagnostic incompetence may be related to the limited ability of clinical and sonographic examinations to differentiate between the 2 kinds of cyst.<sup>26</sup> As a result, some authors simply consider spermatocele an epididymal cyst that appears after puberty when spermatogenesis begins.<sup>27</sup> Customarily, physicians depend on the presence (spermatocele) or absence (epididymal cyst) of sperm to differentiate between the 2 lesions.<sup>3,5-11,25</sup>

In the present report, sperm could not be identified in a random sample of the content of the excised cyst. This could be because the huge amount of fluid inside the cyst (250 ml) may have diluted the sperms, especially if there were not many of them present in the cyst as reported in some individual cases.<sup>28</sup> It could also be because an unfortunate technical error had been committed by the laboratory technician when neither the sample nor the whole fluid content of the cyst was processed just like in cases of cryptozoospermia,<sup>14</sup> as mentioned before. However, there are several arguments in favor of the diagnosis of a spermatocele in the reported patient. First, the cyst was adherent to the epididymal head. The epididymal head is mostly occupied by the efferent tubules and their connections with the rete testis, the 2 places where the spermatoceles mostly arise,<sup>1,2</sup> leaving little room for the epididymis proper tube.<sup>29</sup> This contrasts with an epididymal cyst, which could arise from anywhere along with the epididymis itself.<sup>12,19</sup> Second, the cyst had a proteinaceous fluid whose albumin content was higher than that of serum. This simulates the seminal fluid's composition<sup>30</sup> and indicates the presence of communication with the semen-carrying system. This is contrary to the clear serous fluid of the true epididymal cyst, which is not in continuity with the testis.<sup>31</sup> Third, the cyst was lined with ciliated cuboidal epithelium that is similar to that of the rete testis and efferent tubules.<sup>29</sup> This is different from the epididymal tube, whose wall is coated with pseudostratified columnar epithelium having stereocilia and not true cilia.<sup>32</sup> Fourth, the epithelial lining of the excised cyst showed papillary infoldings, which is another diagnostic feature of the spermatocele wall.<sup>33</sup>

Therefore, in the current report, we relied on the histopathological examination to identify the excised cyst as a "spermatocele." This is in line with the findings of Takimoto et al<sup>4</sup> who depended only on the histopathological assessment to diagnose their reported giant spermatocele without documenting the existence of sperms in the cyst content. It also agrees with the study by Yeung et al<sup>29</sup> in which they concluded that the histological features of extra-testicular cystic structures provide evidence of their origin.

## Conclusion

Spermatoceles may occur at a young age and attain a giant size. Men usually avoid treatment until they experience symptoms that cause either discomfort or cosmetic concerns. Surgery is the treatment of choice for giant spermatoceles that are likely to be complicated by testicular torsion. It is advisable to

expedite a regular clinical and sonographic examination of the scrotum following trauma for the possible development of a spermatocele. Patient's self-examination of the scrotum should be encouraged as a routine, especially after genital trauma.


## Author Contributions

N.S. contributed to the conception and design of the study, analysis, and interpretation of data, and drafting the article with final approval of its completed form. O.S.H. contributed to the interpretation of data and drafting the article with final approval of its completed form.

## Informed Consent

The patient has consented to his case information for publication purpose.

## ORCID iD

Nader Salama  <https://orcid.org/0000-0002-0359-089X>

## REFERENCES

- Oliva E, Young RH. Paratesticular tumor-like lesions. *Semin Diagn Pathol.* 2000;17:340-358.
- Crossan ET. Spermatocele. *Ann Surg.* 1920;72:500-507.
- Yagi H, Igawa M, Shiina H, Shigeno K, Yoneda T, Wada Y. Multilocular spermatocele: a case report. *Int Urol Nephrol.* 2001;32:413-416.
- Takimoto K, Okamoto K, Wakabayashi Y, Okada Y. Torsion of spermatocele: a rare manifestation. *Urol Int.* 2002;69:164-165.
- Basar H, Baydar S, Boyunaga H, et al. Primary bilateral spermatocele. *Internet J Urol.* 2003;10:59-61.
- Yeh HC, Wang CJ, Liu CC, Wu WJ, Chou YH, Huang CH. Giant spermatocele mimicking hydrocele: a case report. *Kaohsiung J Med Sci.* 2007;23:366-369.
- Castelino-Prabhu S, Ali SZ. Spermiphages in a giant spermatocele. *Diagn Cytopathol.* 2010;38:816-817.
- Jain N, Chauhan U, Sethi S, Goel V, Puri SK. Tubular ectasia of rete testis with spermatocele. *J Clin Diagn Res.* 2015;9:TJ03-TJ04.
- Ameli M, Boroumand-Noughabi S, Gholami-Mahtaj L. A 14-year-old boy with torsion of the epididymal cyst. *Case Rep Urol.* 2015;2015:731987.
- Ameli M, Parsapour A, Gholami-Mahtaj L. A 40-year-old man with testicular torsion and large bilateral spermatoceles. *Qatar Med J.* 2016;2016:10.
- Wani I. Hernia with spermatocele, cord and testis inside sac: case report. *Int J Surg Case Rep.* 2018;53:397-399.
- Rubenstein RA, Dogra VS, Seftel AD, Resnick MI. Benign intrascrotal lesions. *J Urol.* 2004;171:1765-1772.
- Lundström KJ, Söderström L, Jernow H, Stattin P, Nordin P. Epidemiology of hydrocele and spermatocele; incidence, treatment and complications. *Scand J Urol.* 2019;53:134-138.
- World Health Organization. *WHO Laboratory Manual for the Examination and Processing of Human Semen.* 5th ed. World Health Organization; 2010.
- Itoh M, Li XQ, Miyamoto K, Takeuchi Y. Degeneration of the seminiferous epithelium with ageing is a cause of spermatoceles? *Int J Androl.* 1999;22:91-96.
- Bay K, Askund C, Skakkebaek NE, Andersson AM. Testicular dysgenesis syndrome: possible role of endocrine disruptors. *Best Pract Res Clin Endocrinol Metab.* 2006;20:77-90.
- Walsh TJ, Seeger KT, Turek PJ. Spermatoceles in adults: when does size matter? *Arch Androl.* 2007;53:345-348.
- McHugh J. The third testicle? What is the epididymis? Accessed August 5, 2016. <https://northeastgaurology.com/2016/08/05/the-third-testicle-what-is-the-epididymis/#:~:text=If%20sperm%20fluid%20accumulates%20near%20the%20head%20of,not%20the%20testis%20proper.%20From%20the%20Mayo%20Clinic>
- Srisajjakul S, Prapaisilp P, Bangchokdee S. Diagnostic clues, pitfalls, and imaging characteristics of 'celes' that arise in abdominal and pelvic structures. *Abdom Radiol.* 2020;45:3638-3652.
- Sista AK, Filly RA. Color Doppler sonography in evaluation of spermatoceles: the "falling snow" sign. *J Ultrasound Med.* 2008;27:141-143.
- Erdem LO, Akduman B. Intratesticular varicocele concomitant with spermatocele. *J Diagn Med Sonogr.* 2004;20:440-443.

22. Singh I, Tk A, Behera DP, et al. Extra scrotal spermatocele – a unique case presentation & brief review of literature. *Ann Urol Nephrol.* 2020;2:1-3.
23. Shan CJ, Lucon AM, Pagani R, Srougi M. Sclerotherapy of hydroceles and spermatoceles with alcohol: results and effects on the semen analysis. *Int Braz J Urol.* 2011;37:307-312.
24. Sánchez-Chapado M, Angulo JC, Haas GP. Adenocarcinoma of the rete testis. *Urology.* 1995;46:468-475.
25. O'Kelly F, McAlpine K, Abdeen N, Keays MA, Guerra LA, Leonard MP. The futility of continued surveillance of epididymal cysts - a study of the prevalence and clinico-demographics in pre- vs. post-pubertal boys. *Can Urol Assoc J.* 2019;13:E398-E403.
26. Boscarelli A, Bellini T. Epididymal cyst in children. *Eur J Pediatr.* 2021;180:2723-2729.
27. Homayoon K, Suhre CD, Steinhardt GF. Epididymal cysts in children: natural history. *J Urol.* 2004;171:1274-1276.
28. Cooper TG, Raczek S, Yeung CH, Schwab E, Schulze H, Hertle L. Composition of fluids obtained from human epididymal cysts. *Urol Res.* 1992;20:275-280.
29. Yeung CH, Cooper TG, Bergmann M, Schulze H. Organization of tubules in the human caput epididymidis and the ultrastructure of their epithelia. *Am J Anat.* 1991;191:261-279.
30. Owen DH, Katz DF. A review of the physical and chemical properties of human semen and the formulation of a semen simulant. *J Androl.* 2005;26:459-469.
31. Jones J. Epididymal cyst. Accessed September 20, 2021. <https://radiopaedia.org/articles/epididymal-cyst?lang=gb>
32. Hess R. The efferent ductules: structure and functions. In: Robaire B, Hinton BT, eds. *The Epididymis: From Molecules to Clinical Practice.* Kluwer Academic/Plenum; 2002:49-80.
33. Patron A, Parwani A. Spermatocele. Accessed January 1, 2022. <https://www.pathologyoutlines.com/topic/testisspermatocele.html>