

Acute hepatitis E in a renal transplantation recipient: a case report

Mitsutoshi Shindo¹
Hiroaki Takemae²
Takafumi Kubo²
Masatsugu Soeno²
Tetsuo Ando²
Yoshiyuki Morishita¹

¹Division of Nephrology, First Department of Integrated Medicine, Saitama Medical Center, Jichi Medical University, Saitama, Japan;
²Department of Dialysis and Transplant Surgery, Hidaka Hospital, Gunma, Japan

Abstract: Hepatitis E is caused by infection with the hepatitis E virus (HEV). HEV is transmitted orally via HEV-contaminated food or drink. Hepatitis E usually shows mild symptoms and is self-limiting in the general population; however, it may progress to chronic hepatitis in immunosuppressed patients such as recipients of organ transplantation. However, a few cases of acute hepatitis E have been reported in organ transplantation recipients. We herein report a case of acute hepatitis E in a 31-year-old male renal transplant recipient. The patient underwent renal transplantation 2 years ago, and his postoperative course was uneventful without rejection. After complaining of general fatigue and low-grade fever for 1 week, he was referred to and admitted to our hospital. Careful interview revealed that he ate undercooked pork 10 weeks prior. Blood analysis revealed liver dysfunction but was serologically negative for hepatitis A, B and C virus, cytomegalovirus infection and collagen diseases. Immunoglobulin A antibody against hepatitis E virus (HEV-IgA) was also negative at that point. After 2 weeks of admission, HEV-IgA and HEV-RNA were measured again as hepatitis E could not be ruled out due to history of ingestion of undercooked meat that may have been contaminated with HEV. At that time, HEV-IgA and HEV-RNA (genotype 3) were positive. Thus, an acute hepatitis E was diagnosed. His liver function gradually improved to within the normal range, and HEV-IgA and HEV-RNA were negative at 11 weeks after admission. In conclusion, we describe here a case of acute hepatitis E in a renal transplant recipient. Careful interview regarding the possibility of ingestion of HEV-contaminated food and repeated measurements of HEV-IgA were helpful in finalizing a diagnosis.

Keywords: hepatitis E virus, anti-HEV IgA, recipient, renal transplantation, zoonosis

Introduction

Hepatitis E is caused by infection with the hepatitis E virus (HEV), which is a single-stranded, non-enveloped, RNA icosahedral virus.¹ HEV is most commonly transmitted orally through ingesting food or drink that is contaminated with HEV.^{2,3} Hepatitis E has been reported to usually cause mild symptoms such as low-grade fever, appetite loss and mild jaundice and is self-limiting in the general population.¹ However, it may develop into chronic hepatitis in immunosuppressed patients such as recipients of organ transplantation.⁴ In the study by Kamar et al,⁵ 66% of hepatitis E patients who were also organ transplantation recipients progressed to chronic hepatitis and 10% these chronic hepatitis E patients progressed to liver cirrhosis.

However, a few cases of acute hepatitis E have been reported in organ transplantation recipients. We herein report a case of acute hepatitis E in a renal transplant recipient.

Correspondence: Yoshiyuki Morishita
Division of Nephrology, First Department of Integrated Medicine, Saitama Medical Center, Jichi Medical University, 1-847 Amanuma-cho, Omiya-ku, Saitama-city, Saitama 330-8503, Japan
Tel +81 48 647 2111
Fax: +81 48 647 6831
Email ymori@jichi.ac.jp

Case report

The patient was a 31-year-old man who underwent renal transplantation 2 years ago. The donor was his mother. Their ABO blood type was compatible, and antibodies against donor-specific human leukocyte antigen were negative in the recipient as determined by complement-dependent cytotoxicity, flow cytometry-based crossmatch and panel reactive antibody. His postoperative course was uneventful without rejection, and his immunosuppressive regimen consisted of 3.5 mg/day tacrolimus, 1000 mg/day mycophenolate mofetil and 0.5 mg/day everolimus. The patient's liver function was normal. He was referred to our hospital after complaining of general fatigue and low-grade fever starting 1 week before presentation. Careful interview revealed that he ate undercooked pork 10 weeks prior. A low-grade fever was observed, but jaundice and abdominal pain were not. Blood examination revealed liver dysfunction. He was admitted to our hospital for further examination and treatment for liver dysfunction. Written informed consent to publication was obtained from the patient.

The laboratory data upon admission are shown in Table 1. Blood examination showed liver dysfunction but was negative for antigens and antibodies for hepatitis A, B and C virus, cytomegalovirus (CMV) infection and collagen diseases (Table 1).

Immunoglobulin A antibody against hepatitis E virus (HEV-IgA) was also negative at that point (Table 1). Notably, markers of liver damage were upregulated over time (Figure 1). Because we knew he ate undercooked pork 10 weeks prior, we thought that the possibility of hepatitis E could not be ruled out as the cause of his liver disease. Therefore, we measured HEV-IgA again and also measured HEV-IgM and HEV-RNA 2 weeks after admission. At that time, both HEV-IgA and HEV-IgM were positive as well as genotype 3 HEV-RNA (4.3 log copy/mL, cutoff value: <2.0 log copy/mL; Figure 1). Therefore, acute hepatitis E was diagnosed. The administration of ursodeoxycholic acid, monoammonium glycyrrhizinate, glycine, aminoacetic acid and L-cysteine hydrochloride hydrate was started for liver protection. No specific antiviral agent against HEV was used. His liver function gradually improved to within the normal range, and HEV-IgA and HEV-RNA were once again negative at 11 weeks after admission (Figure 1). During this episode, the administration of immunosuppressive agents was continued without deterioration in renal function of the transplanted kidney.

Discussion

We have described a case of acute hepatitis E in a renal transplant recipient. Four genotypes of HEV have been reported.⁶

Table 1 Laboratory findings at initial presentation

Complete blood count and blood chemistry		Immunological analysis		Urinary analysis	
WBC	4630/ μ L	HBs-Ag	–	pH	5.5
RBC	496 \times 10 ³ / μ L	HBs-Ab	–	Protein	–
Hematocrit	43.5%	HBc-Ab	–	Occult blood	–
Hemoglobin	14.2 g/dL	HAV-IgG	–	WBC	–
Platelets	17.1 \times 10 ⁴ / μ L	HAV-IgM	–		
Total protein	7.7 g/dL	HCV-Ab	–		
Albumin	4.5 g/dL	HEV-IgA	–		
Total bilirubin	0.9 mg/dL	CMV (CI0/11)	0/0		
AST	156 IU/L	CMV-IgG	+		
ALT	300 IU/L	CMV-IgM	–		
ALP	414 IU/L	Antinuclear antibody	40-fold		
γ -GTP	126 IU/L	Anti-mitochondrial M2 antibody	–		
BUN	19.9 mg/dL				
Creatinine	1.46 mg/dL				
Uric Acid	6.7 mg/dL				
Sodium	137 mmol/L				
Potassium	4.3 mmol/L				
Chloride	104 mmol/L				
Calcium	9.9 mg/dL				
Phosphorus	3.4 mg/dL				
CRP	<0.05 mg/dL				

Abbreviations: WBC, white blood cells; HBs-Ag, hepatitis B virus surface antigen; RBC, red blood cells; HBs-Ab, antibody against hepatitis B virus surface protein; HBc-Ab, antibody against hepatitis B virus core proteins; HBs-Ag, hepatitis B virus surface-antigen; HAV-IgG, immunoglobulin G antibody against hepatitis A virus; HAV-IgM, immunoglobulin M antibody against hepatitis A virus; HCV-Ab, antibody against hepatitis C virus; HEV-IgA, immunoglobulin A antibody against hepatitis E virus; CMV, cytomegalovirus; AST, aspartate aminotransferase; CMV-IgG, immunoglobulin G antibody against cytomegalovirus; ALT, alanine aminotransferase; CMV-IgM, immunoglobulin M antibody against cytomegalovirus; ALP, alkaline phosphatase; γ -GTP, γ -glutamyl transpeptidase; BUN, blood urea nitrogen; CRP, C-reactive protein.

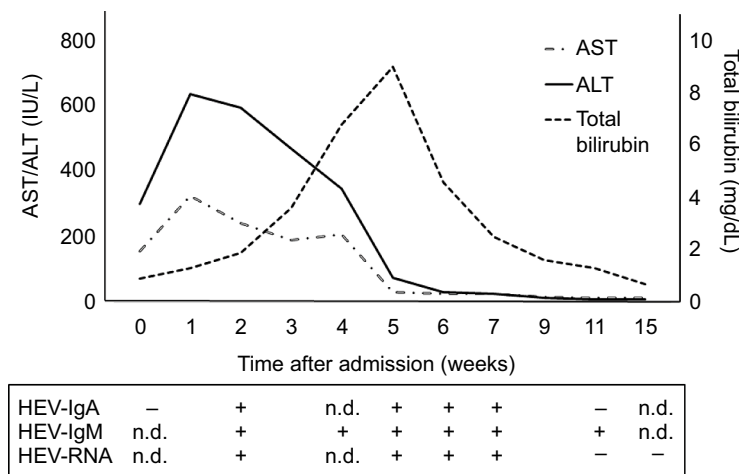


Figure 1 Patient's clinical course.

Abbreviations: AST, aspartate aminotransferase; ALT, alanine aminotransferase; HEV-IgA, immunoglobulin A antibody against hepatitis E virus; HEV-IgM, immunoglobulin M antibody against hepatitis E virus; HEV, hepatitis E virus; n.d., not determined.

Genotypes 1 and 2 of HEV can only be transmitted to humans via waterborne and fecal–oral transmission.⁶ Genotypes 3 and 4 of HEV are transmitted via zoonotic infections from pigs, wild boar, deer and other animals and humans.⁶ Humans are therefore commonly infected with HEV by ingesting meat or water contaminated with HEV.⁷ In addition, blood transfusion and allograft transplantation reportedly increase the risk of transmission of HEV because screening for HEV is not well established in blood and organ donation.^{8,9} In the present case, the patient had a recent history of ingestion of undercooked meat but not of blood transfusion. Additionally, his postoperative course was uneventful without liver dysfunction during the 2 years after renal transplantation. Therefore, HEV in this patient may be caused by ingestion of HEV-contaminated meat.

Previously, hepatitis E has been diagnosed based on the presence of HEV-IgM and HEV-RNA.¹⁰ However, recently HEV-IgA has been used as a first screening examination to detect the acute phase of HEV infection because HEV-IgA is superior to HEV-IgM in terms of sensitivity and specificity.¹¹ HEV-IgA has been reported to be positive when symptoms appear, and liver enzymes increase in the general population.¹¹ However, in this patient, HEV-IgA was negative when symptoms first appeared and liver enzymes increased. Notably, HEV-IgA showed a delayed positive response at 5 weeks later. Immunosuppression in this patient may contribute to the delayed production of HEV-IgA. It may therefore be better to measure HEV-IgA repeatedly with HEV-RNA to diagnose hepatitis E in immunosuppressed patients. A previous study reported that hepatitis E progressed to chronic hepatitis in 66% of organ transplantation recipients

and all chronic hepatitis E infections were caused by HEV genotype 3.¹⁰ In this case, HEV (genotype 3) infection did not progress to chronic hepatitis despite the patient taking immunosuppressive agents. The low titer of HEV-RNA of 4.3 log copy/mL (cutoff value: <2.0 log copy/mL) may have contributed to the HEV infection not progressing to a chronic infection. Further studies are required to investigate both the mechanism of progression of HEV infection to chronic hepatitis and the optimal testing and treatment of HEV in immunosuppressed patients.

Conclusion

We have described a case of acute hepatitis E in a renal transplant recipient. Careful interview regarding the possibility of consumption of HEV-contaminated food and repeated measurements of HEV-IgA were helpful in finalizing a diagnosis. Undercooked meat may be recommended to be excluded from menu in immunosuppressed patients such as recipients of organ transplantation.

Acknowledgment

We thank Simon Teteris, PhD, from the Edanz Group for editing the English in this manuscript.

Author contributions

All authors contributed toward data analysis, drafting and revising the paper and agree to be accountable for all aspects of the work.

Disclosure

The authors report no conflicts of interest in this work.

References

1. Dalton HR, Bendall R, Ijaz S, Banks M. Hepatitis E: an emerging infection in developed countries. *Lancet Infect Dis*. 2008;8(11):698–709.
2. Tei S, Kitajima N, Takahashi K, Mishiro S. Zoonotic transmission of hepatitis E virus from deer to human beings. *Lancet*. 2003;362(9371):371–373.
3. Matsuda H, Okada K, Takahashi K, Mishiro S. Severe hepatitis E virus infection after ingestion of uncooked liver from a wild boar. *J Infect Dis*. 2003;188:944.
4. Kamar N, Kamar N, Selvaraj S, et al. Hepatitis E virus and chronic hepatitis in organ-transplant recipients. *N Engl J Med*. 2008;358:811–817.
5. Kamar N, Garrouste C, Haagsma EB, et al. Factors associated with chronic hepatitis in patients with hepatitis E virus infection who have received solid organ transplants. *Gastroenterology*. 2011;140:1481–1489.
6. Okamoto H. Genetic variability and evolution of hepatitis E virus. *Virus Res*. 2007;127:216–228.
7. Kamar N, Bendall R, Legrand-Abravanel F, et al. Hepatitis E. *Lancet*. 2012;379(9835):2477–2488.
8. Hewitt PE, Ijaz S, Brailsford SR, et al. Hepatitis E virus in blood components: a prevalence and transmission study in southeast England. *Lancet*. 2014;384(9956):1766–1773.
9. Gallian P, Lhomme S, Piquet Y, et al. Hepatitis E virus infections in blood donors, France. *Emerg Infect Dis*. 2014;20:1914–1917.
10. Kamar N, Dalton HR, Abravanel F, Izopet J. Hepatitis E virus infection. *Clin Microbiol Rev*. 2014;27:116–138.
11. Takahashi M, Kusakai S, Mizuo H, et al. Simultaneous detection of immunoglobulin A (IgA) and IgM antibodies against hepatitis E virus (HEV) is highly specific for diagnosis of acute HEV infection. *J Clin Microbiol*. 2005;43:49–56.

International Medical Case Reports Journal

Publish your work in this journal

The International Medical Case Reports Journal is an international, peer-reviewed open-access journal publishing original case reports from all medical specialties. Previously unpublished medical posters are also accepted relating to any area of clinical or preclinical science. Submissions should not normally exceed 2,000 words or

4 published pages including figures, diagrams and references. The manuscript management system is completely online and includes a very quick and fair peer-review system, which is all easy to use. Visit <http://www.dovepress.com/testimonials.php> to read real quotes from published authors.

Submit your manuscript here: <https://www.dovepress.com/international-medical-case-reports-journal-journal>

Dovepress