

# Evaluation of clinical curative effects of disposable stitching instrument in redundant prepuce patients

HAITAO WANG<sup>1,2</sup>, NINGJIE CHEN<sup>2</sup>, RAN HUO<sup>1</sup>, JINCUN YANG<sup>2</sup>, XIA LI<sup>1,2</sup> and NAN XING<sup>2</sup>

<sup>1</sup>Department of Burn and Plastic Surgery, Shandong Provincial Hospital, Shandong University, Jinan, Shandong 250021; <sup>2</sup>Department of Burn and Plastic Surgery, Weihai Municipal Hospital, Dalian Medical University, Weihai, Shandong 264200, P.R. China

Received February 27, 2017; Accepted March 30, 2017

DOI: 10.3892/etm.2017.4453

**Abstract.** The present study aimed to investigate the clinical curative effect of disposable stitching instrument operation in patients with redundant prepuce or phimosis. A total of 102 cases of patients with circumcision were randomly selected (from June 2013 to December 2014) from the department of plastic and aesthetic surgery of our hospital and were randomly divided into control and observation groups (n=51). Patients in the control group were treated by traditional circumcision operation, while patients in the observation group were treated by novel disposable circumcision stitching instrument. Operation time, bleeding volume, incision healing time, postoperative complications and incision aesthetic satisfaction in the groups were observed. As a result, intraoperative bleeding volume of patients in the observation group was significantly less in comparison to the control group. Operation time and incision healing time of patients in the observation group was shorter than that of the control group. Additionally, the incidence of postoperative complications of patients in the observation group was noted to be lower than that of the control group. On the other hand, the incision aesthetic satisfaction of patients in the observation group was higher than that of the control group. Blood vessel counting and nerve fiber counting of tissue specimen in the observation group were more than those of the control group. Postoperative VAS scores of patients in the observation group were significantly lower than that of the control group. Each rating scale scores of EPQ of patients in the observation group improved significantly compared with that of the control group. In conclusion, the present findings show that disposable circumcision stitching instrument operation is more advantageous in comparison to the traditional procedure along with minimal complications and better post surgery health condition of patients.

## Introduction

Phimosis and redundant prepuce is one of the common clinical diseases in urology that affect the normal penile development (1). It also results in repeated attacks of acrobystitis, along with symptoms such as dyspareunia, infection of urinary system and the invasion of genital system (epididymis, testis, seminal vesicle and prostate) (1). Long-term stimulation of smegma praeputii is an important factor that induces carcinoma of penis and cervical cancer of spouse leading to sexual dysfunction including premature ejaculation (2-4). Patients with redundant prepuce often choose operative treatment, and the traditional circumcision is the most common option. However, the traditional procedure has disadvantages of lengthy operation time, large bleeding volume, and unaesthetic incisal edge. On the other hand, disposable circumcision stitching instrument operation has the advantages of short operation time, has less bleeding volume and aesthetic incisal edge, which is helpful for the harmonious sexual life of patients (5).

The present study conducted disposable circumcision stitching instrument operation on the patients with phimosis and redundant prepuce and received a satisfactory curative effect. The details are reported as follows.

## Materials and methods

*General data.* A total of 102 cases of patients with circumcision were randomly selected (from June 2013 to December 2014) from the Department of Plastic and Aesthetic Surgery of our hospital. Inclusion criteria were: i) patients with typical phimosis or redundant prepuce who need operative treatment; ii) normal development of penis and iii) signed informed consent. Exclusion criteria were: i) penis dysplasia and genital tract malformation; ii) premature ejaculation caused by spermato cystitis, urethritis and prostatitis; iii) without re-examination and follow-up visit according to study requirement. Computer software was used to divide them into the control and observation groups (n=51 per group). The general data of two groups showed no statistical significance ( $P>0.05$ , Table I). This study was approved by the Ethics Committee of Shandong Provincial Hospital. Signed written informed consents were obtained from all participants before the study.

---

*Correspondence to:* Professor Ran Huo, Department of Burn and Plastic Surgery, Shandong Provincial Hospital, Shandong University, 324 Jingwu Weiqi Road, Jinan, Shandong 250021, P.R. China  
E-mail: odeesu238@163.com

*Key words:* circumcision, redundant prepuce, phimosis, male sexual function

Table I. General data of study objects.

Items	Observation group n=51 cases	Control group n=51 cases	t/ $\chi^2$	P-value
Age (years)	20-45	20-40		
Mean age (years)	28.86±7.69	29.35±8.18	0.312	0.756
Types (n, %)				
Redundant prepuce	38 (78.51)	35 (68.62)	0.193	0.661
Phimosis	13 (21.49)	16 (31.38)		
Degree of education (n, %)				
Middle school or below	11 (21.56)	9 (17.64)	0.780	0.677
High school	26 (50.98)	24 (47.06)		
Junior college or above	14 (27.45)	18 (35.29)		

*Preoperative preparation.* Before operation, the patients in the two groups received convention blood urine examination. Prepuce cavity and balanus were washed 1 day before operation. Furthermore, the patients also received psychological counseling for the elimination of their nervousness and fear. Before surgery, the surgical sites of patients were given routine disinfection and drape, with 5-10 ml of 1% lidocaine to conduct nerve block anesthesia of the penile base.

*Operation methods.* Traditional method was applied to the control group. In this protocol, haemostatic forceps were used to clamp the middle frenum of the prepuce flank area, and was pulled for cutting the bilateral prepuce tissue along the parallel site (with a parallel distance of 5 mm) of coronary sulcus. The prepuce frenum tissue was kept at approximately 10 mm. Then, electrocoagulation was applied to stop the bleeding and the incision was sutured after detection of active hemorrhage.

Disposable circumcision stitching instrument (produced by Jiangxi Langhe Medical Instrument Co., Ltd., Jiangxi, China) operation was applied to the observation group. The second, sixth and tenth migration spots of inner and outer plates of prepuce were raised by hemostatic forceps. Furthermore, a 30-degree angle towards the dorsal part between penis axis and the bar axis of campaniform glans penis base was kept. Ribbon or silk thread was used for fixation on the rod and to take the safety catch out. The knob was pressed for 10 sec, to lightly spin and quit the campaniform glans penis base to stop the bleeding. The pressure was released after 20 sec to check the suture situation, with pressure dressing to the incision.

*Morphological observation of tissue specimens.* The prepuce tissue specimens of patients in the two groups were analyzed by standard H&E staining. Under optical microscope, the form of organization, especially the difference of vasculature including blood vessel and lymph-vessel of tissue specimens were observed. S-100 immunohistochemical staining method was applied to observe the nerve architecture. A 40-time optical microscope was used to observe the immunohistochemical results.

*Postoperative care and follow-up visit.* The patients of the observation group scrubbed the wound edge using iodophor

every day after 1 week of operation. At the postoperative 6-month follow-up visit, the operation effect, sexual function and psychological status were evaluated.

*Evaluation methods.* The operation results and postoperative complications of the two groups of patients were compared, including operation time, intra-operative bleeding volume, incision healing time, postoperative incision infection and incision edema. VAS scores were recorded to evaluate the pain grade. The Chinese index of sexual function for premature ejaculation (CIPE) was used to conduct a questionnaire survey. A 5-grade method of 1-5 scores was applied to evaluate libido, erectile hardness, ejaculation incubation, erection hold time, ejaculation control difficulty, sexual satisfaction of spouses, orgasm frequency of spouse, sexual self-confidence and self-anxiety level of patients for 6 months after operation. The total score was 50, which had a positive relation with sexual function. Furthermore, an Eysenck personality questionnaire was applied to monitor the psychological states of patients in the two groups.

*Statistical analysis.* Software SPSS 19.0 (SPSS, Inc. Chicago, IL, USA) was utilized to process data.  $P < 0.05$  indicates a statistically significant difference.

## Results

*Surgery and postoperative complications.* The results of the surgery using the two methods and their respective postoperative complications were compared. The intraoperative bleeding volume of patients in the observation group was significantly less in comparison with the control group. Operation time and incision healing time of patients in the observation group was also shorter ( $P < 0.05$ , Table II). The postoperative complications of patients in the observation group were significantly lower than that of the control group (Table III).

*Morphological results.* The morphological observation of tissue specimens revealed that the blood vessel counting ( $7.35 \pm 2.18$ ) and nerve fiber counting ( $15.34 \pm 2.46$ ) of tissue specimen in the observation group were significantly higher than those of the control group ( $4.32 \pm 1.57$  and  $9.65 \pm 1.48$ ) ( $P < 0.05$ , Figs. 1 and 2).

Table II. Comparison of postoperative situations between the two groups of patients.

Groups	Cases	Operation time (min)	Intraoperative bleeding (ml)	Incision healing time (days)
Observation group	51	7.83±1.62	1.97±0.63	11.23±2.53
Control group	51	19.14±3.57	9.57±1.38	18.56±3.47
t-test		20.063	35.778	12.190
P-value		<0.0001	<0.0001	<0.0001

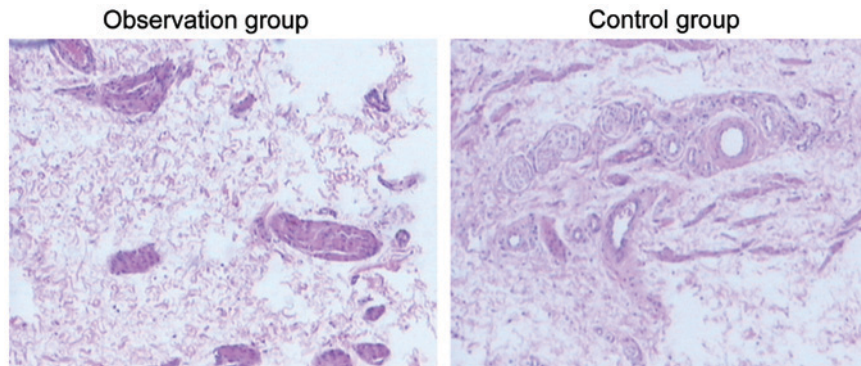


Figure 1. H&amp;E staining showed blood vessel counting in the two groups.

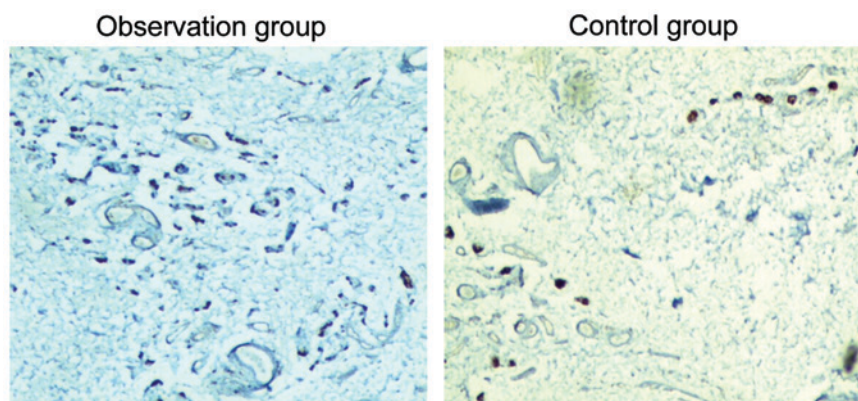


Figure 2. Immunohistochemical staining showed nerve fiber counting in the two groups.

Table III. Comparison of postoperative complications in the two groups.

Groups	Cases	Incision infection	Incision split	Incision edema
Observation group	51	4 (7.84)	7 (13.72)	9 (17.64)
Control group	51	0 (0.00)	1 (1.96)	2 (3.21)
$\chi^2$		14.370		
P-value		0.0002		

Table IV. Comparison of postoperative VAS scores of patients in the two groups.

Groups	Cases	6 h after operation	12 h after operation	24 h after operation
Observation group	51	5.13±1.14	3.16±1.13	1.85±1.14
Control group	51	7.16±1.23	5.33±1.25	3.58±1.26
t-test		8.644	9.179	7.271
P-value		<0.0001	<0.0001	<0.0001

*Postoperative results.* Postoperative VAS score improvement of patients in the observation group was significantly higher than that of the control group, and the difference had

statistical significance ( $P < 0.05$ , Table IV). Furthermore, the incision aesthetic satisfaction of the observation group was significantly higher at 98.03%, a degree of satisfaction

Table V. Incision aesthetic satisfaction of patient in the two groups (n, %).

Groups	Cases	Very satisfied	Satisfied	Dissatisfied	Total degree of satisfaction
Observation group	51	39 (76.47)	11 (21.56)	1 (1.97)	50 (98.03)
Control group	51	19 (3.72)	20 (39.21)	12 (23.52)	39 (76.47)
$\chi^2$		29.993			
P-value		<0.0001			

Table VI. Comparison of EPQ score of patients in the two groups.

Groups	Cases	Introversion and extroversion	Emotionality	Metaphrenia tendency	Dissimulation
Observation group	51	56.95±3.14	47.16±3.13	39.35±2.14	51.13±3.12
Control group	51	47.16±3.23	59.33±3.25	49.58±2.26	56.26±3.17
t-test		15.769	19.262	23.473	8.237
P-value		<0.0001	<0.0001	<0.0001	<0.0001

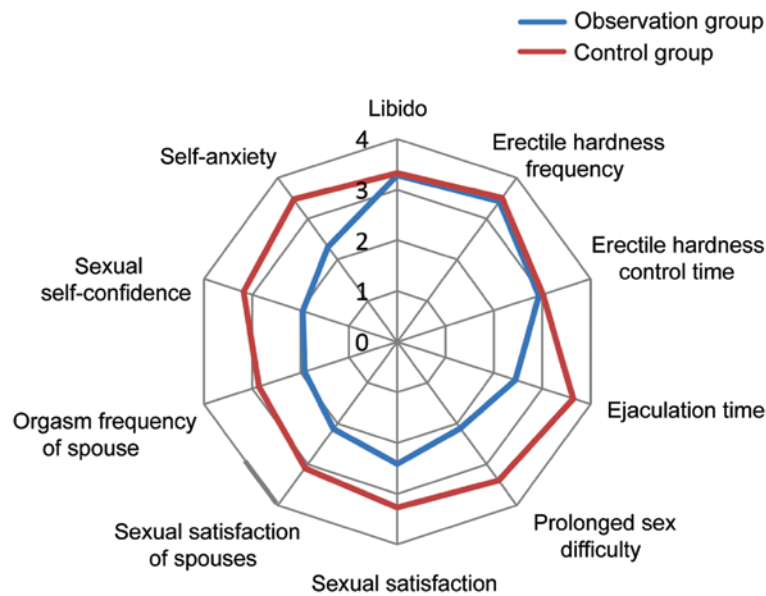


Figure 3. CIPE scores of patients in the two groups. CIPE, Chinese index of sexual function for premature ejaculation.

that was obviously higher than that of the control group at 76.47% ( $P<0.05$ , Table V).

CIPE scores of patients in the two groups 6 months after operation were compared. The comparison of libido, erectile hardness frequency and erectile hardness control time of patients in the two groups had no obvious difference ( $P>0.05$ ). Additionally, prolonged sex difficulty and ejaculation time, sexual satisfaction of spouses, orgasm frequency of spouse, sexual self-confidence and self-anxiety level of patients in the observation group were better than those of the control group ( $P<0.05$ ), (Fig. 3).

**EPQ results.** After operation, EPQ of patients in the two groups were compared. The emotionality, metaphrenia tendency and

dissimulation of the observation group were significantly improved compared to the control group ( $P<0.05$ , Table VI).

## Discussion

The growth of phimosis leads to prepuce connecting with glans closely, which effectively protects the shaft of the penis and glans. Consequently, immature male children often have the symptom of redundant prepuce (6,7). The development of penis, leads to preputial orifice expanding gradually, and epithelial keratinization separation formation is covered by glans. After puberty, if the skin of penis still wraps the glans completely or incompletely, the condition is named phimosis or redundant prepuce (7-9). Furthermore, prepuce could be



divided into two layers including inner and outer plate. The cuticle of inner plate is less and its mucosa surface is moister, which is easily bruised and broken and integrates with more virus target cells (such as Langerhans cell, CD4T lymphocyte, macrophage) (10,11). Langerhans cell belongs to immature dendritic cells, and its cytoplasm contains a great number of racket and columnar particles. When the mucosa or skin of some part is infected, Langerhans cells of root position would identify, capture and dispose the virus and germ. Therefore, the inner plate is easier to be infected by HIV than the outer plate (12,13). In a related clinical study, it was found that the prepuce cavity would form a moist environment for the patient with phimosis after sexual intercourse, which would promote the transcription and duplication of the virus HIV. Circumcision could reduce the infection rate of HIV, especially the infection rate of HIV from female, up to 60% (14,15).

Traditional operation method is relatively complicated, and the excision length of inner and outer plate of prepuce is difficult to control, thus it is not accepted by most people (16). The present study results showed that the bleeding of the observation group was less than that of the control group. Operation time and recovery time of incision was shorter compared to the control group. The postoperative complication incidence (5.88%) was also lower than that of the control group (39.21%), which is closely related to the advantages of disposable circumcision stitching instrument. Furthermore, it had less wounds, one main operation and had easy postoperative care.

HE staining and S-100 protein immunohistochemical staining were used to observe the histomorphology of the removed tissue specimens from the patients in the two groups. Blood vessel counting and nerve fiber counting of tissue specimen in the observation group were more than those of the control group ( $P < 0.05$ ). On the other hand, VAS scores 6, 12 and 24 h after operation of patients in the observation group were significantly lower than that of the control group ( $P < 0.05$ ). This results in greater damage to superficial fascia of penis when traditional operation was applied to wipe out the prepuce, causing damage to vasculature and nerve fiber. Moreover, it would increase the incidence of postoperative hematoma, edema and the postoperative pain degree.

The disposable circumcision stitching instrument operation only cut the epidermal layer of prepuce, which could efficiently alleviate complications, such as hematoma and edema. At the same time, it could effectively prevent the incision of nerve tissue where nerve fiber distributes densely (17). It also retained the fascia and nerve tissue between lamina proprias of inner and outer plates of prepuce as much as possible, to reduce the paresthesia of patients (18). The results of this study showed that the sexual dysfunction such as premature ejaculation of the observation group improved much more than that of the control group, and the psychological state was also superior in the observation group ( $P < 0.05$ ). The possible justification for the above observation could be the direct exposure of glans penis to the outside and its reduced surface cornification sensitivity after disposable circumcision stitching instrument operation, leading to elevated ejaculation threshold. In addition, the disposable method could keep a favorable tactile function as it improved the quality of sexual life and the psychological state of patients (19,20).

Collectively, the application of disposable circumcision stitching instrument operation to circumcision has an obvious superiority, which is worthy of promoting in clinic.

## References

- Xie ST, Chen GY, Wei QH, Liu XT, Jiao L and Tang Y: Outward versus inward placement in Shang Ring circumcision for phimosis and redundant prepuce in adult men: Analysis of 527 cases. *Zhonghua Nan Ke Xue* 20: 325-328, 2014 (In Chinese).
- Lei JH, Liu LR, Wei Q, Xue WB, Song TR, Yan SB, Yang L, Han P and Zhu YC: Circumcision with 'no-flip Shang Ring' and 'Dorsal Slit' methods for adult males: A single-centered, prospective, clinical study. *Asian J Androl* 18: 798-802, 2016.
- Larke NL, Thomas SL, dos Santos Silva I and Weiss HA: Male circumcision and penile cancer: A systematic review and meta-analysis. *Cancer Causes Control* 22: 1097-1110, 2011.
- Namavar MR and Robati B: Removal of foreskin remnants in circumcised adults for treatment of premature ejaculation. *Urol Ann* 3: 87-92, 2011.
- Pan F, Pan L, Zhang A, Liu Y, Zhang F and Dai Y: Circumcision with a novel disposable device in Chinese children: A randomized controlled trial. *Int J Urol* 20: 220-226, 2013.
- Abdulwahab-Ahmed A and Mungadi IA: Techniques of male circumcision. *J Surg Tech Case Rep* 5: 1-7, 2013.
- Mavhu W, Frade S, Yongho AM, Farrell M, Hatzold K, Machaku M, Onyango M, Mugurungi O, Fimbo B, Cherutich P, *et al*: Provider attitudes toward the voluntary medical male circumcision scale-up in Kenya, South Africa, Tanzania and Zimbabwe. *PLoS One* 9: e82911, 2014.
- Dias J, Freitas R, Amorim R, Espiridião P, Xambre L and Ferraz L: Adult circumcision and male sexual health: A retrospective analysis. *Andrologia* 46: 459-464, 2014.
- Jayathunge PH, McBride WJ, MacLaren D, Kaldor J, Valley A and Turville S: Male circumcision and HIV transmission; What do we know? *Open AIDS J* 8: 31-44, 2014.
- Fahrbach KM, Barry SM, Anderson MR and Hope TJ: Enhanced cellular responses and environmental sampling within inner foreskin explants: Implications for the foreskin's role in HIV transmission. *Mucosal Immunol* 3: 410-418, 2010.
- Hirbod T, Bailey RC, Agot K, Moses S, Ndinya-Achola J, Murugu R, Andersson J, Nilsson J and Brodiden K: Abundant expression of HIV target cells and C-type lectin receptors in the foreskin tissue of young Kenyan men. *Am J Pathol* 176: 2798-2805, 2010.
- Subbiah V and Subbiah IM: Killing two birds with one stone: *BRAF V600E* inhibitor therapy for hairy cell leukemia and Langerhans/dendritic cell sarcoma. *Ann Hematol* 92: 1149-1149, 2013.
- Ganor Y and Bomsel M: HIV-1 transmission in the male genital tract. *Am J Reprod Immunol* 65: 284-291, 2011.
- Krieger JN: Male circumcision and HIV infection risk. *World J Urol* 30: 3-13, 2012.
- Peltzer K, Simbayi L, Banyini M and Kekana Q: HIV risk reduction intervention among medically circumcised young men in South Africa: A randomized controlled trial. *Int J Behav Med* 19: 336-341, 2012.
- Dinh MH, Fahrbach KM and Hope TJ: The role of the foreskin in male circumcision: An evidence-based review. *Am J Reprod Immunol* 65: 279-283, 2011.
- Ly BD, Zhang SG, Zhu XW, Zhang J, Chen G, Chen MF, Shen HL, Pei ZJ and Chen ZD: Disposable circumcision suture device: Clinical effect and patient satisfaction. *Asian J Androl* 16: 453-456, 2014.
- Cao DH, Dong Q and Wei Q: Commentary on 'Disposable circumcision suture device: Clinical effect and patient satisfaction'. *Asian J Androl* 17: 516, 2015.
- Cox G, Krieger JN and Morris BJ: Histological correlates of penile sexual sensation: Does circumcision make a difference? *Sex Med* 3: 76-85, 2015.
- Homfray V, Tanton C, Mitchell KR, Miller RF, Field N, Macdowall W, Wellings K, Sonnenberg P, Johnson AM and Mercer CH: Examining the association between male circumcision and sexual function: Evidence from a British probability survey. *AIDS* 29: 1411-1416, 2015.