

Case Report

Surgical Management of Double/Triple Mandibular Fractures Involving the Condylar Segment: Our Perspective

Sunil S. Nayak¹, Abhay Taranath Kamath²

¹Department of Oral and Maxillofacial Surgery, ²Head of Department of Oral and Maxillofacial Surgery, Manipal College of Dental Sciences, Manipal Academy of Higher Education, Manipal, Karnataka, India

Received : 30-11-17.
Accepted : 03-01-18.
Published : 29-01-18.

ABSTRACT

A series of surgical cases operated in our unit are considered to analyze and evaluate the different techniques and sequencing employed in the surgical management of double/triple mandibular fractures involving a condylar fracture. Deviating from the normal sequence of reducing and fixing the dentate segment first, we addressed the condylar segment first. A combination of different approaches for different cases such as a periangular with a vestibular, a preauricular and a retromandibular with a vestibular were used according to the type of fractures. The accessibility to one difficult case with a medially displaced condyle was facilitated by using Hegar's uterine dilators. In all cases, good anatomical reduction was achieved with stable occlusion and without any signs of facial nerve impairment. The 'Condyle first' approach in the surgical management of double/triple mandibular fractures, is a reliable and efficient technique.

KEYWORDS: *Condylar fractures, double mandibular fractures, Hegar's dilators*

INTRODUCTION

The management of condylar fractures has been a hugely controversial topic in oral and maxillofacial surgery. There has been a large difference of opinion regarding open or closed treatment of condylar fractures among oral and maxillofacial surgeons. Sequencing of surgical management of double or triple mandibular fractures involving a fractured condyle is another debatable topic of interest to surgeons. Traditionally, while one school of thought favors addressing of the dentate segment first, only a very few advocate the "condyle first" approach.

The surgical management of double/triple mandibular fractures involving a condylar component as dealt with in our unit has been depicted in a series of cases.

CASE REPORTS

This case series involves four patients operated in our surgical unit. Informed consent was obtained from each of these patients.

CASE 1

A 28-year-old patient reported following a road traffic accident (RTA) with a complaint of pain in the lower jaw and difficulty in biting. After the preliminary care and management, routine blood and biochemistry

investigations were carried out, values of which were well within normal limits. Radiographic and computed tomography revealed a right-side subcondylar fracture with an associated left parasymphyseal fracture [Figure 1] and a right zygomaticomaxillary complex (ZMC) fracture.

The patient was taken under general anesthesia and was intubated nasally. After adequate preparation, we approached the condylar fracture through a periangular approach, and this was followed by an intraoral vestibular approach to reduce and fix the parasymphyseal fracture [Figures 2-4]. Finally, we addressed the ZMC fracture.

CASE 2

A 21-year-old male patient presented with a bilateral condylar and a symphysis fracture. In this case, a combined approach was employed to reduce and fix the fractured condyle. The right medially displaced condylar fracture was addressed. A preauricular approach was advocated to retrieve the medially displaced fractured condyle [Figure 5]. To facilitate proper reduction and fixation of the fractured

Address for correspondence: Dr. Abhay Taranath Kamath, Department of Oral and Maxillofacial Surgery, Manipal College of Dental Sciences, Manipal, Karnataka, India.
E-mail: abhaytaranathk@gmail.com

This is an open access article distributed under the terms of the Creative Commons Attribution-NonCommercial-ShareAlike 3.0 License, which allows others to remix, tweak, and build upon the work non-commercially, as long as the author is credited and the new creations are licensed under the identical terms.

For reprints contact: reprints@medknow.com

How to cite this article: Nayak SS, Kamath AT. Surgical management of double/triple mandibular fractures involving the condylar segment: Our perspective. J Int Soc Prevent Communit Dent 2018;8:87-91.

Access this article online	
Quick Response Code: 	Website: www.jispcd.org
	DOI: 10.4103/jispcd.JISPCD_428_17

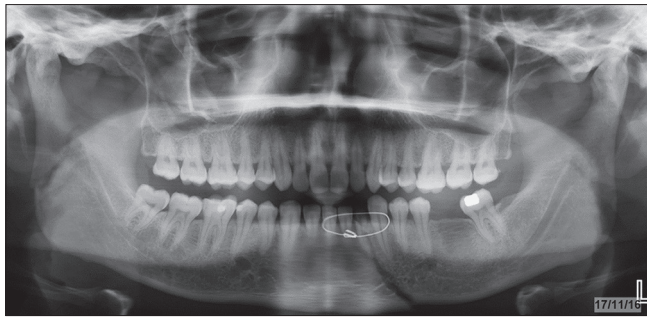


Figure 1: Orthopantomogram

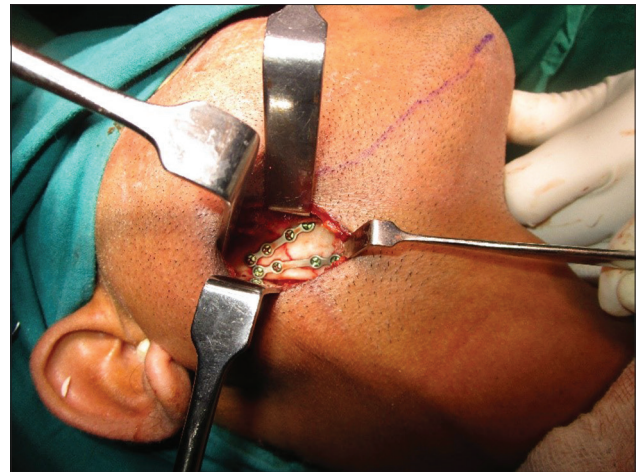


Figure 2: Fixation of the subcondylar fracture by the periangular approach

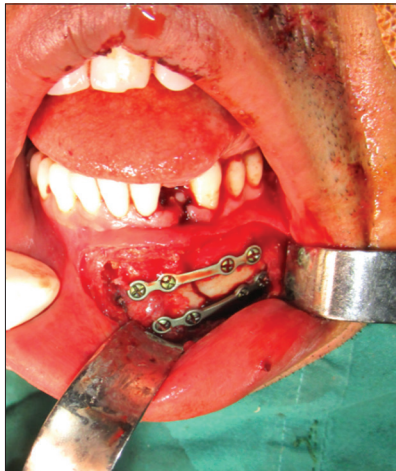

Figure 3: Fixation of the parasymphyseal fracture

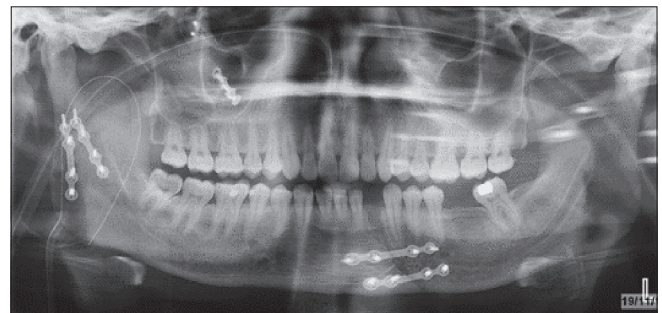

Figure 4: Postoperative orthopantomogram

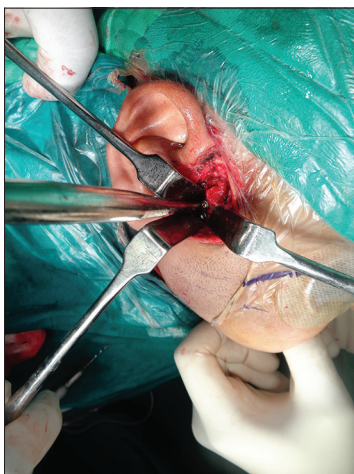


Figure 5: Preauricular approach

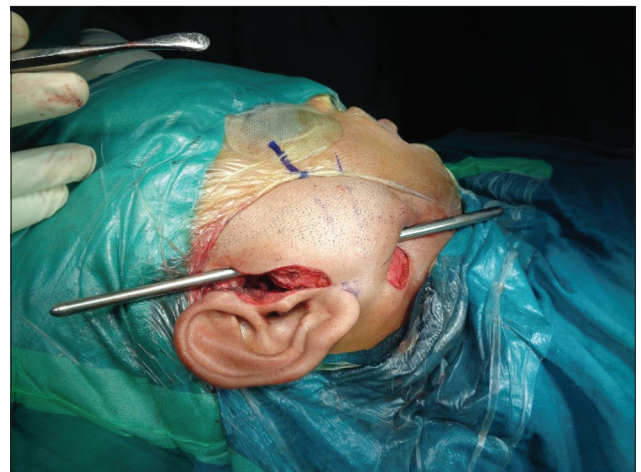


Figure 6: Use of Hegar's uterine dilator

segments, a retromandibular approach was also used. We used Hegar's uterine dilators in sequence to create an accessible working space for reduction and fixation, passing it through the retromandibular incision, and exiting through the preauricular incision [Figure 6]. During plating, the superior screws were placed through the preauricular incision and the inferior screws were placed through the retromandibular incision. Finally, the symphysis fracture was reduced and fixed through an intraoral vestibular

incision. Postoperative radiograph was taken to assess the surgical outcome [Figure 7].

CASE 3

A 35-year-old male, carpenter by profession, reported to us following a RTA. He was diagnosed with a panfacial fracture which included a LeFort 3, ZMC, naso-orbital-ethmoid, bilateral condylar, and symphysis fractures [Figures 8 and 9]. The right

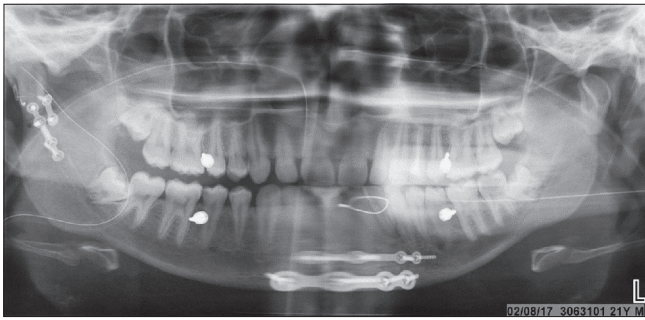


Figure 7: Postoperative orthopantomogram (Case 2)

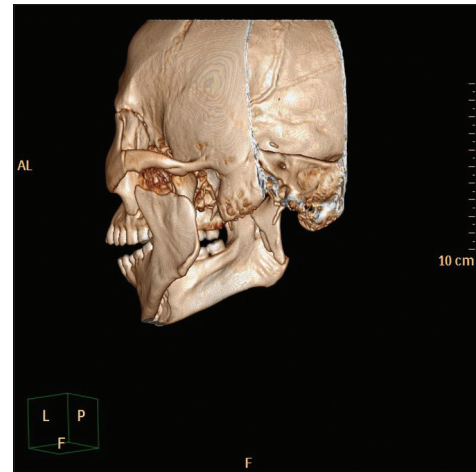


Figure 8: Three-dimensional computed tomography scan showing bilateral condylar fractures

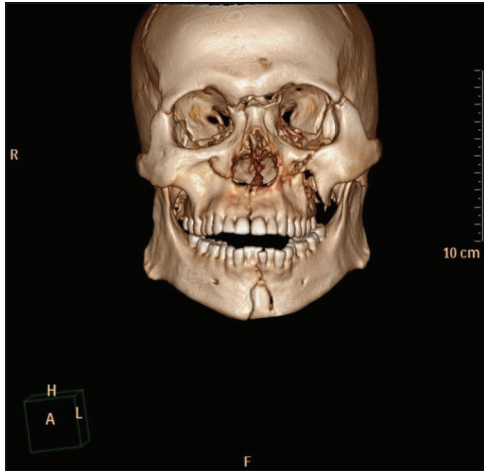


Figure 9: Three-dimensional computed tomography scan showing symphysis fracture

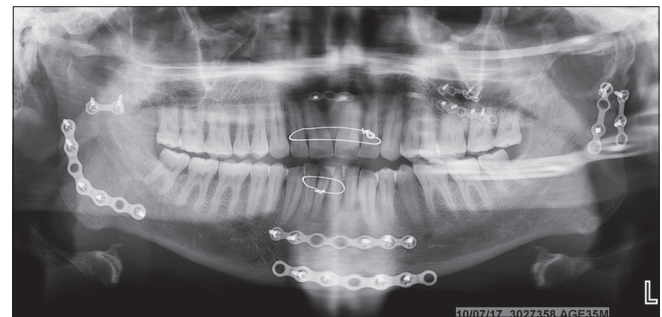


Figure 10: Postoperative orthopantomogram showing two-plate fixation of the fractured condyles

subcondylar-ramus fracture was approached through a periangular incision. The left dislocated condyle was then reduced and fixed through a preauricular approach. This was followed by the symphysis fracture reduction and fixation through an intraoral vestibular approach. The midface was finally reduced and fixed. This was followed by a postoperative orthopantomogram for assessment [Figure 10].

CASE 4

A 22-year-old student reported following a RTA and was diagnosed with a panfacial fracture which included bilateral subcondylar, symphysis, bilateral ZMC, and a LeFort 2 fracture. We decided to restore the vertical ramus height first and addressed the left subcondylar fracture through a retromandibular approach [Figure 11]. The next step was to reduce and fix the mandibular symphysis fracture. Having established a stable base, the midface was addressed next and a stable occlusion was achieved.

Open reduction and internal fixation was employed for the surgical management, and Zimmer Biomet Titanium implants were used for fixation in all cases. A variety of different condylar approaches were employed for the above cases. In all cases, we reduced and fixed the condylar fractures first.

In the first case, while we used a periangular incision, in the second case, we had used a combination of preauricular and retromandibular approaches to reduce and fix a fractured condylar segment which was difficult to retrieve from its displaced site. The lack in laxity of the soft tissues due to its bulkiness and fibrosis led us to the use of Hegar's uterine dilators in a sequencing manner of their sizes, to gain space and create an accessible working area. In the third case, we addressed both condylar fractures, but by different approaches, the periangular approach for the right subcondylar fracture and the preauricular approach for the left dislocated condylar fracture. In the fourth case, we used a retromandibular transmasseteric anteroparotid approach to address the condyle on the left side while the right condyle was left untouched.

RESULTS

Different surgical approaches were employed but the condylar fracture was addressed first in each of the above cases. Even though some of the cases had associated midface fractures, the mandible was approached first. All the patients had double or triple mandibular fractures with one of the components being a condylar fracture.

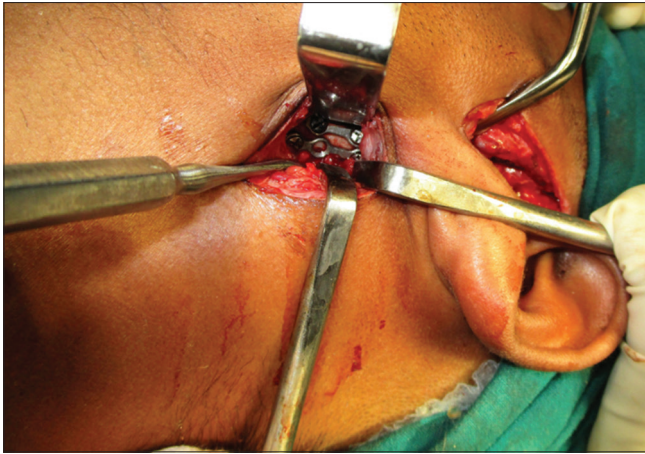


Figure 11: Retromandibular approach

All cases showed good postoperative results. The postoperative occlusion was found to be stable in all patients. No signs of neurological deficit were present. The postoperative functional activity of the patients improved drastically compared to the preoperative status. The second patient who had a bilateral condylar fracture exhibited minor deviation of the chin toward the left while opening the mouth. This could be attributed to the fact that only the right condylar segment was reduced and fixed. The minor discrepancy was corrected using guiding elastics postoperatively.

DISCUSSION

RTA accounted for about 49.5% of mandibular fractures and the mean age of the patients affected was 28 years.^[1,2] The incidence of double/triple mandibular fractures among all mandibular fractures ranges between 22% and 52%.^[3]

Some authors are of the opinion that reduction and fixation of the condyle before the symphysis in double mandibular fractures is difficult due to the potential chances of the condylar fragment being malpositioned.^[4]

Orabona *et al.* conducted a study in this regard and had come to a conclusion that tooth bearing fractured fragments should be reduced before nontooth-bearing fractured fragments, but they were also of the opinion that fracture reduction and fixation was much easier to perform when the nontooth-bearing component was addressed first.^[5]

The absence of craniomandibular articulation results in lack of posterior support to the mandibular ramus segment making it malpositioned.^[6] When fracture at the anterior region such as the symphysis is fixed first following maxillomandibular fixation, the mandible can flare laterally at the gonial angle and at the inferior border.^[6] In all our patients, we reduced and fixed the condylar segment first and restored the craniomandibular articulation.

Reconstruction of fractures involving the symphysis, condyle, and midface is best started from the condyle.^[7] The proper mandibular width as well as the sagittal mandibular position can be adequately restored when reduction and fixation of the condyle is done first.^[7,8] The same sequence was followed in fracture management of our patients.

Open reduction and internal fixation of the condylar fracture first helps in restoration of the midface projection, particularly in panfacial fractures. The reconstruction of the condylar segment first helps in restoring the posterior facial height. This would benefit in treating associated mandibular and midface fractures.^[9]

Symphysis reduction after fixation of the condyle could adversely affect the condylar internal fixation when a single plate is used to fix the fractured condyle.^[10] Single-plate fixation of the fractured condyle may result in internal fixation failure. Hence, two straight plates or three-dimensional plates are highly recommended.^[11] Two miniplates, applied in a triangular fashion, one at the posterior border of the ramus and one below the sigmoid notch, are ideal in fixation of subcondylar fractures.^[12] In our unit, the condylar segment was fixed by two plates, along the same principles.

The distribution of compressive stress on the posterior border of the ramus and tensile stress inferior and parallel to the sigmoid notch of the mandible were demonstrated by the photoelastic analysis put forth by Meyer *et al.*^[13] In our patients, two plates were fixed, one along the posterior border of the ramus and the other below the sigmoid notch [Figures 4, 7, and 10] to counter these areas of stress.

The retromandibular transparotid approach is a reliable technique for the surgical management of condylar fractures.^[14] Rarely, some complications such as sialocele can result from this approach.^[15] We preferred the retromandibular transmasseteric anteroparotid approach which is considered to be a friendly approach to surgeons of varying grades.^[16] A combined approach to the fractured mandibular condyle [Figure 6] such as the preauricular and submandibular is employed sometimes to aid in reduction and fixation of difficult fractures of the condyle.^[17] This also helps in applying traction to the mandible inferiorly.^[18]

The fractured condylar area can be associated with functional disability subsequent to surgery.^[19] None of our patients presented with any complications postoperatively which give credibility to our surgical techniques.

CONCLUSION

Open reduction and internal fixation of the fractured condylar fragment before the tooth-bearing fractured

fragment is a reliable and efficient technique. Reconstruction of the fractured condylar fragment first helps establish the posterior facial height which acts as a scaffold to treat other associated fractures.

DECLARATION OF PATIENT CONSENT

The authors certify that they have obtained all appropriate patient consent forms. In the form, the patients have given their consent for images and other clinical information to be reported in the journal. The patients understand that name and initials will not be published and due efforts will be made to conceal identity, but anonymity cannot be guaranteed.

FINANCIAL SUPPORT AND SPONSORSHIP

Nil.

CONFLICTS OF INTEREST

There are no conflicts of interest.

REFERENCES

- Munante-Cardenas JL, Facchina Nunes PH, Passeri LA. Etiology, treatment, and complications of mandibular fractures. *J Craniofac Surg* 2015;26:611-5.
- Singaram M, Sree GV, Udhayakumar RK. Prevalence, pattern, etiology, and management of maxillofacial trauma in a developing country: A retrospective study. *J Korean Assoc Oral Maxillofac Surg* 2016;42:174-81.
- Ogundare BO, Bonnick A, Bayley N. Pattern of mandibular fractures in an urban major trauma center. *J Oral Maxillofac Surg* 2003;61:713-8.
- Vesnaver A, Ahčan U, Rozman J. Evaluation of surgical treatment in mandibular condyle fractures. *J Craniomaxillofac Surg* 2012;40:647-53.
- Orabona GD, Abbate V, D'Amato S, Romano A, Iaconetta G. Surgical sequence of reduction in double mandibular fractures treatment. *Ann Ital Chir* 2014;85:207-13.
- Cillo JE Jr., Ellis E 3rd. Treatment of patients with double unilateral fractures of the mandible. *J Oral Maxillofac Surg* 2007;65:1461-9.
- Yang R, Zhang C, Liu Y, Li Z, Li Z. Why should we start from mandibular fractures in the treatment of panfacial fractures? *J Oral Maxillofac Surg* 2012;70:1386-92.
- Zhang Y, He Y. Symphyseal/parasymphyseal and bilateral condyle fracture a special fracture pattern and special treatment consideration. *Int J Oral Maxillofac Surg* 2015;44:e1-330.
- Tullio A, Sesenna E. Role of surgical reduction of condylar fractures in the management of panfacial fractures. *Br J Oral Maxillofac Surg* 2000;38:472-6.
- Pau M, Reinbacher KE, Feichtinger M, Navysany K, Kärcher H. The mandibular symphysis as a starting point for the occlusal-level reconstruction of panfacial fractures with bicondylar fractures and interruption of the maxillary and mandibular arches: Report of two cases. *J Craniomaxillofac Surg* 2014;42:e51-6.
- Meyer C, Serhir L, Boutemi P. Experimental evaluation of three osteosynthesis devices used for stabilizing condylar fractures of the mandible. *J Craniomaxillofac Surg* 2006;34:173-81.
- Choi BH, Kim KN, Kim HJ, Kim MK. Evaluation of condylar neck fracture plating techniques. *J Craniomaxillofac Surg* 1999;27:109-12.
- Meyer C, Kahn JL, Boutemi P, Wilk A. Photoelastic analysis of bone deformation in the region of the mandibular condyle during mastication. *J Craniomaxillofac Surg* 2002;30:160-9.
- D'Agostino A, Trevisiol L, Procacci P, Favero V, Odorizzi S, Nocini PF, *et al.* Is the retromandibular transparotid approach a reliable option for the surgical treatment of condylar fractures? *J Oral Maxillofac Surg* 2017;75:348-56.
- Rajeev R, Sajesh S, Jose M, Kumar ND. Sialocele: A rare sequelae of transparotid approach in subcondylar fracture management. *Natl J Maxillofac Surg* 2016;7:201-4.
- Crowley M, Siddiqui A, Burke E. Surgical management of condylar fracture: A trainee friendly approach. *Br J Oral Maxillofac Surg* 2017;55:e132.
- Kumar PS, Kumar CR, Anandan H. A study on open versus closed reduction of mandibular condyle fractures and their management. *Int J Sci Stud* 2017;5:9-13.
- Choi KY, Yang JD, Chung HY, Cho BC. Current concepts in the mandibular condyle fracture management part II: Open reduction versus closed reduction. *Arch Plast Surg* 2012;39:301-8.
- Bayat M, Parvin M, Meybodi AA. Mandibular subcondylar fractures: A Review on treatment strategies. *Electron Physician* 2016;8:3144-9.