

Cutaneous draining sinus tract of odontogenic origin

A case of chronic misdiagnosis

Mohammad I. Al-Obaida, MSEd, FRCD (C), Ebtissam M. Al-Madi, MSD, FACD.

ABSTRACT

تشير دراسة الحالة هذه إلى حالة مريضة شابة تعاني من ناسور جيبى جلدي ذو منشأ سني، كان هناك خطأ في التشخيص مبدئياً مما أدى إلى شفاء متأخر واستطباب خاطئ. هذا الناسور ذو قناة مرضية تنشأ من التجويف الفموي ولكنه خرج من على سطح جلد الوجه. أدى الخطأ التشخيصي إلى معالجة غير مناسبة. وبعد ما تم تصويب التشخيص، أُجري العلاج النوعي من خلال المعالجة الفموية لإزالة مصدر الإلتان. وقد كانت حالة علاجية لبية بسيطة وفعالة. هذه الحالة بالبداية تم تشخيصها بشكل خاطئ على أنها كيس دهني أو تقرح من الغدة النكافية، تم تصحيح التشخيص من خلال الفحص السريري الدقيق والتقييم وتقني الأثر باستخدام تقنية التصوير المتقدمة (تقنية تصوير الشعاعي باستخدام الحزم المخروطية) وأُنجزت المعالجة اللبية والتي أنتجت شفاء سريع للحالة. ثم تبع ذلك معالجة الندبة التي تكونت مكان فتحة الناسور في الخد من قسم الجلدية لإزالة آثار الندبة باستخدام الليزر.

This is a case of a patient with a buccal cutaneous sinus tract, originally misdiagnosed, with delayed healing and potential malpractice. An odontogenic cutaneous sinus tract is a pathologic canal that initiates in the oral cavity but opens externally at the cutaneous surface of the face or neck. It is frequently misdiagnosed, leading to inappropriate treatment. Once correct diagnosis is made, definitive treatment, through oral therapy to eliminate the source of infection, is simple and effective. This case was initially misdiagnosed as a sebaceous cyst and laceration of parotid gland. The case was correctly diagnosed through detailed examination and evaluation, using tracing and advanced imaging technology (cone beam imaging). Endodontic treatment was performed, which resulted in rapid resolution of the case, followed by dermatologic treatment with fractional laser to treat the scar formed.

*Saudi Med J 2019; Vol. 40 (3): 292-297
doi:10.15537/smj.2019.3.23963*

From the Department of Restorative Dentistry, College of Dentistry, King Saud University, Riyadh, Kingdom of Saudi Arabia.

Received 8th November 2018. Accepted 29th January 2019.

*Address correspondence and reprint request to: Dr. Ebtissam M. Al-Madi, Department of Restorative Dentistry, College of Dentistry, King Saud University, Riyadh, Kingdom of Saudi Arabia.
E-mail: ealmadi@ksu.edu.sa
ORCID ID: orcid.org/0000-0001-9758-7757*

An odontogenic cutaneous sinus tract is a pathologic channel that initiates in the oral cavity and exits at the cutaneous surface of the face or neck. It might resemble an ulcer, cyst, furuncle, or retracted, sunken skin.¹ Notably, it is commonly misdiagnosed, due to the rarity of its occurrence and the lack of associated symptoms.² This typically results in unsuitable treatment (namely, surgical excision, antibiotics, biopsy, or radiotherapy) and subsequent relapse of the cutaneous sinus tract.¹ Patients require multiple visits to the physician to receive a proper diagnosis.¹ Approximately 50% of affected patients may undergo multiple ineffective attempts at incision, drainage, and long-term use of antibiotics, due to improper diagnosis and lack of treatment of the infectious dental etiology.³ Approximately 80% of cutaneous dental sinus tracts originate from mandibular teeth and nearly 50% of these lesions are associated with anterior mandibular teeth.⁴ However, eradication of the cause of the infection, either through endodontic treatment (if the tooth can be restored), or extraction (if the tooth cannot be restored), provides simple and effective resolution of the sinus tract.⁵ Odontogenic cutaneous sinus tracts arise due to pulp infection, root fracture, chemical irritation, chronic apical periodontitis, or dental trauma.⁶ Affected teeth become necrotic and exhibit apical periodontitis due to spread of infection into the periradicular area. The infected by-products of infection will follow the path of least resistance, desiccate and breakthrough the skin to form draining sinus tracts.⁶ This case report describes

a patient who presented with a buccal odontogenic cutaneous sinus tract, which was initially misdiagnosed as a sebaceous cyst and laceration of the parotid gland. This encounter may serve as a reminder to both medical and dental practitioners that inflammatory facial lesions may originate from dental infections.

Case Report. Patient's information. A 27-year-old Yemeni woman was referred to the dental hospital in King Saud University, Riyadh, Kingdom of Saudi Arabia, by a general dentist for evaluation and extraction of her third molar (wisdom) tooth. Upon examination, the patient requested an opinion regarding a chronic complaint of a discharge from a wound in her cheek. Examination showed a cutaneous sinus tract with purulent discharge (Figure 1). Seven years prior to the referral, the patient presented to dermatology clinic with a depression (dimple) in her left cheek, which was then diagnosed as a sebaceous cyst. Based on that diagnosis, the cyst was drained, and the pus was suctioned at several appointments, but no improvement was observed. The depression became more prominent. Six months later, she presented to a plastic surgeon in Yemen, the surgeon performed incision and curettage under local anesthesia and prescribed amoxicillin clavulanate 1g bid for 7 days. Subsequently, swelling occurred and continuous purulent drainage increased. The surgeon performed a culture, and prescribed amoxicillin 500 mg tid for 7 days. A few months later, the continuous discharge remained, therefore, the patient returned to her dermatologist, who performed biopsy, the dermatologist asked the patient to chew gum during the procedure in order to determine if the salivary glands were involved. Saliva was secreted during chewing, and the dermatologist concluded that the parotid gland had been lacerated during the curettage that was previously performed, and that the parotid gland should be removed. The dermatologist referred the patient to a plastic surgeon; however, she was reluctant to undergo the procedure and did not take any action. One year later, the symptoms remained, thus the patient returned to the first plastic surgeon in Yemen who had performed the curettage, with the dermatologist's suggestion that the parotid gland had been lacerated, and that this served as the source of persistent infection and discharge. The surgeon performed interventional

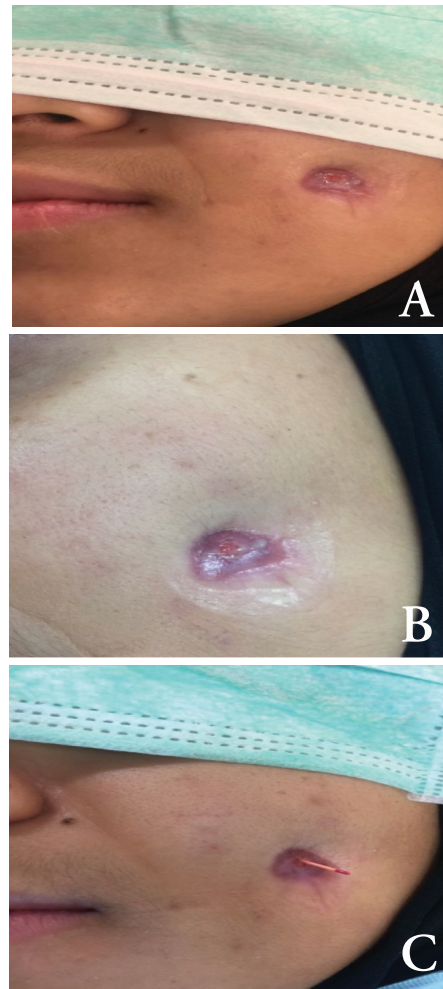


Figure 1 - Photograph during the first visit A) extraoral finding, B) extraoral finding close up, and C) extraoral finding tracing with gutta percha point

radiology and injected contrast medium into the parotid gland, showing that the gland was intact. The patient then sought a second opinion, this second surgeon performed a series of X-rays, with a similar result. The second surgeon suggested an exploratory surgery to investigate the issue; however, the patient refused. The patient then presented to a third plastic surgeon, who agreed with the other surgeons, that the parotid gland was intact; this third surgeon advised the patient not to undergo any more surgeries to avoid exacerbating the problem. Thus, the patient discontinued treatment until she came to the dental hospital, King Saud University, Riyadh, Kingdom of Saudi Arabia. During examination at the hospital, the patient explained that the wound would heal; then (a few days later), pus and blood would accumulate, such that the cheek and face

Disclosure. Authors have no conflict of interests, and the work was not supported or funded by any drug company.

Table 1 - Timeline of the 27-year-old Yemeni woman referred to the dental hospital in King Saud University, Riyadh, Kingdom of Saudi Arabia,

Date	Relevant pat medical history and interventions		
7 years ago	Patient visited dermatology clinic with depression (dimple) in her left cheek. It was diagnosed as a sebaceous cyst. The cyst was drained, and the pus was suctioned at several appointments with no improvement. The depression became more prominent.		
6.5 years ago	She went to a plastic surgeon that performed incision and curettage under local anesthesia and prescribed Augmentin 1 gr BID for 7 days. Swelling occurred and continuous purulent drainage increased. The surgeon performed a culture, and prescribed Amoxil 500 mg TID for 7 days.		
6 years ago	The patient went back to her dermatologist and took a biopsy. The dermatologist decided the parotid gland was lacerated and should be removed. She refused.		
5 years ago	She returned to the first plastic surgeon. The surgeon performed interventional radiology with contrast medium to prove the parotid gland intact. The patient went to a second surgeon and he diagnosed the same and suggested exploratory surgery. She refused.		
	The patient went to a third plastic surgeon, he advised her not to do any more surgeries for fear of exacerbating the problem.		
Date	Summaries from initial and follow up	Diagnostic testing (including tests)	Interventions
Visit 1	Chronic repeated incidences of discharge from a wound in her cheek. Examination showed a cutaneous sinus tract with purulent discharge.	CBCT showed MB root of tooth #26 penetrating out of the alveolar bone. Pulp testing, percussion, and periodontal probing with normal responses. Sinus tract tracing. Diagnosis: odontogenic cutaneous sinus tract secondary to a necrotic pulp of tooth #26.	RCT #26. Cleaning and shaping and Ca (OH) ₂ placement.
Visit 2 (1 week later)	Signs of healing. Reduced discharge. The color of scar improved.		Cleaning and shaping of #26, and fresh Ca (OH) ₂ placed.
Visit 3 (after 6 weeks)	Continued improvement		Obturation of tooth #26.
Visit 4 (7 weeks)	Substantial healing occurred.		Adjacent tooth treated.
Subsequent visits	Scar subcision and fraxel laser skin resurfacing.		

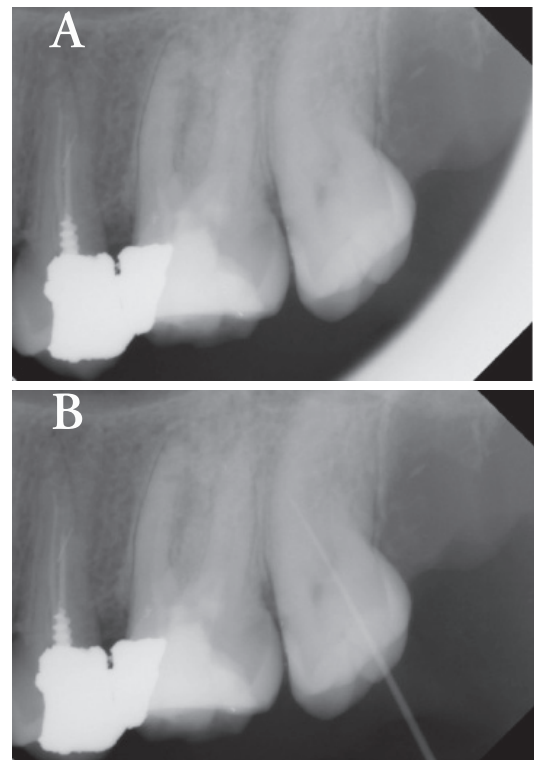
CBCT - cone-beam computed tomography, MB - mesiobuccal canal, RCT - root canal treatment

would swell, and the cyst would burst. This pattern was continuously repeated (Table 1).

Clinical findings. Medical history showed that the patient had no reported medical conditions. She was not taking any medication and reported no allergies. Moreover, the patient did not report any dental pain. Intraoral examination focused on the maxillary left molars, which were near the dimple in the cheek.

Diagnostic assessment. Pulp testing, percussion, and periodontal probing were carried out for the tooth, and revealed normal responses. Neighboring and contralateral teeth were also tested and were all within normal. Sinus tract tracing was performed through insertion of a size 30 gutta percha in the fistulae area, and a radiograph was taken (Figure 2). Cone beam imaging revealed that the mesiobuccal root of tooth #26 penetrated out of the alveolar bone (Figure 3). Based on the medical history and the results of examination, the patient was diagnosed with odontogenic cutaneous sinus tract secondary to necrotic pulp of tooth #26. Root canal treatment was planned.

Therapeutic intervention. During the first visit, access opening was carried out for tooth #26, initial instrumentation and irrigation included an irrigating regimen of sodium hypochlorite (NaOCl) (5.25%), followed by saline, and then chlorohexidine (2%). The

**Figure 2** - Initial radiograph A) pretreatment B) sinus tract tracing with Gutta Percha

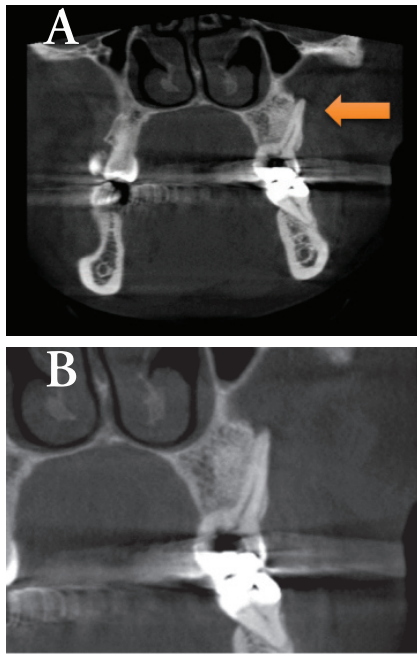


Figure 3 - Initial visit showing the A) cone-beam x-ray and the B) cone-beam closeup. Extrusion of mesiobuccal root (arrow) outside the alveolus

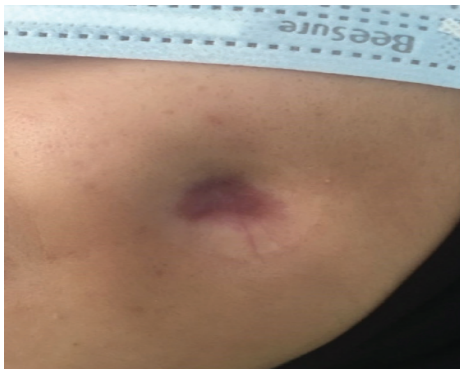


Figure 4 - Extra oral healing after one week post endodontic treatment.

canals were dried and $\text{Ca}(\text{OH})_2$ (Multi-Cal, Pulpdent Corporation, USA) was applied. The patient was examined one week later and showed discontinuation of the external discharge (Figure 4). There were obvious signs of initial healing of the fistulae. The prior erythematous color of the external scar had reduced. During the second visit, the canals were instrumented with single file, single use WaveOne NiTi files (Dentsply, Maillefer) ISO 25 with taper (8%). The primary WaveOne was used for the buccal canals, while the WaveOne large (file tip ISO 40 with an apical taper of 8%) was used for the palatal canal. The irrigation protocol was repeated, and fresh $\text{Ca}(\text{OH})_2$ was applied. The patient returned

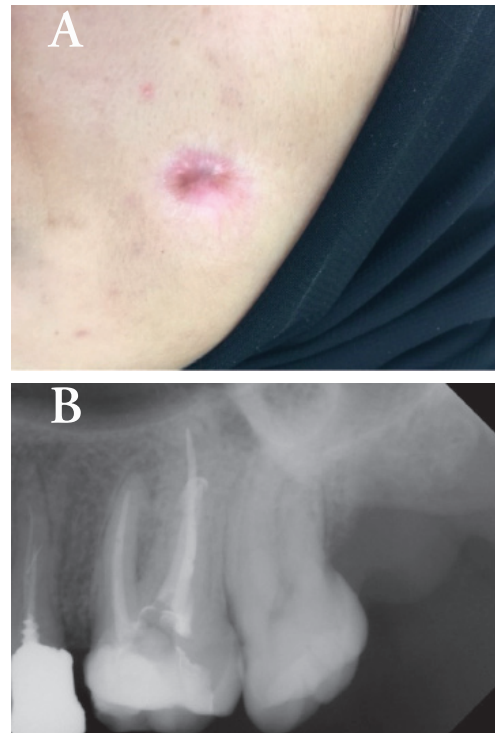


Figure 5 - A) Extraoral healing after 6 weeks B) Obturation of canals.

6 weeks later for obturation, this was performed using continuous wave vertical obturation with AH26 Plus sealer and 0.04 taper cones for the buccal canals as well as ISO 40 for the palatal canal (Figure 5).

Follow-up and outcomes. The final visit was after 7 weeks; examination showed that substantial healing occurred, and the adjacent tooth was finalized (Figure 6). Scar subcision and Fraxel laser skin resurfacing were used to improve the texture and tone of the skin (Figure 7).

Discussion. Cutaneous sinus tracts may arise from several diseases, such as carcinomas, furuncles, osteomyelitis, bacterial infections, congenital fistulas, and pyogenic granulomas.² However, a dental infection should be suspected as the primary etiology in chronic draining cutaneous sinus tracts of the face and neck.^{5,7} This diagnosis might be easily overlooked by physicians, but not by dentists; however, many affected patients initially present to a physician for treatment.⁸ The osteoclastic process of the dental infection progresses gradually through the alveolar bone and may spread into the adjacent soft tissues, eventually breaking through the skin.⁷ Eighty percent of described cases have involved mandibular teeth, the remaining 20% involved maxillary teeth. Therefore, the most common locations for cutaneous odontogenic

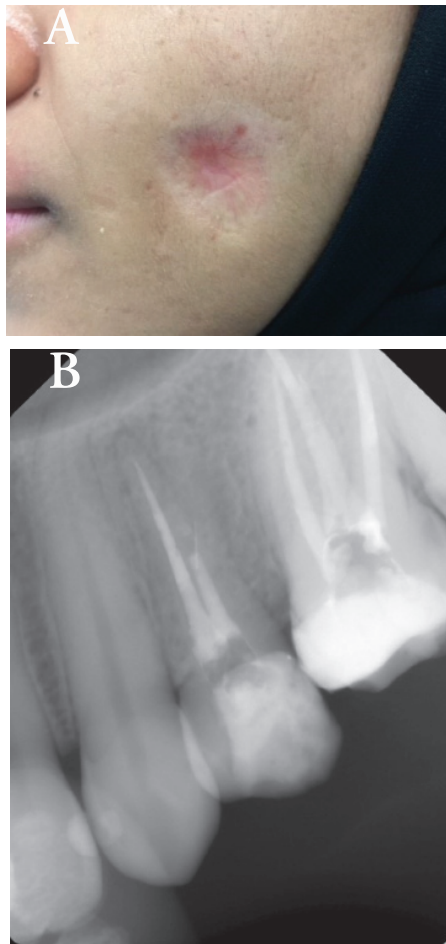


Figure 6 - A) Extra oral healing after 7 weeks. B) Obturation and treatment of adjacent diseased tooth.

sinuses are the jaw and chin. Cutaneous sinus tracts involving maxillary anterior teeth are likely to erupt on the upper lip region, the philtrum, nasolabial fold, nose or infraorbital region. Conversely, cutaneous sinus tracts involving maxillary teeth might erupt on the cheek.⁸ Misdiagnosis is common, as odontogenic cutaneous sinus tracts are uncommon.² In addition, misdiagnosis can cause inappropriate and unnecessary treatment that might increase the chronicity of the lesion.² Such treatment can affect facial aesthetics due to the appearance of skin scarring.⁸ Unnecessary excision of vital structures, as was suggested in this case (the parotid gland), may endanger facial nerves and arteries. Removal of the parotid gland would have led to reduced salivary secretion and lubrication of the oral cavity, thus causing a variety of other problems. The diagnosis of an odontogenic cutaneous sinus tract is difficult, as these lesions are not necessarily adjacent to the primary dental infection; moreover many patients do not report

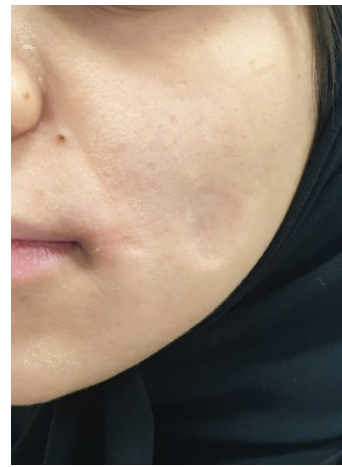

Figure 7 - Healing after skin resurfacing.

dental symptoms, as in the present case.⁵ Arrival at an accurate diagnosis, requires a clear and accurate medical and clinical history, as well as clear assessment of dental pain. Because of the complexity of the drainage pathways, all mandibular and maxillary teeth need to be examined, specifically in areas in the midline. Pulp tests and apical tests should be performed on both suspected and adjacent teeth. Clinicians should carefully investigate the possibility of a potential odontogenic chronic infection. Radiographic examination, whether conventional or advanced imaging should be performed to identify radiolucencies at the apex of suspected teeth; these could indicate presence of infection. Notably, this investigation is more important if multiple teeth are suspected. The application of advanced 3D imaging is important, and patients should be evaluated using orthopantomography and cone-beam computed tomography (CBCT).^{5,7} In the present case, CBCT revealed the affected tooth, whereas conventional 2D radiography did not demonstrate unusual findings. Tracing with an endodontic gutta-percha point along the sinus tract during radiographic examination may also assist in identifying the affected tooth, as in the present case.² Additionally, some studies have revealed the use of microbiologic culturing and sensitivity tests of the exudate from the sinus tract, in order to detect microbial flora and to dismiss specific infections (such as actinomycosis and syphilis).² This was initially planned for the patient in the present case; however, because there were signs of initial improvement at the second visit, such tests were unnecessary.

The treatment of odontogenic cutaneous sinus tracts requires the treatment of the cause of infection, either by extraction in the case of a non-restorable

tooth, or root canal treatment if the tooth is restorable.⁵ Recurrence will most likely occur if excision of the lesion is carried out surgically, without suitable treatment of the affected teeth, as demonstrated in the present case. Once the tooth is treated, the need for surgical excision is controversial. Some studies have suggested complete excision of the sinus tract lining, while others have suggested that surgical treatment and antibiotic therapy are not necessary after dental treatment.^{2,5} In this case, root canal treatment was sufficient for healing to occur.

Plastic surgery may be needed at a later stage if healing results in cutaneous retraction. In the present case, the patient is likely to require filler placement, or a skin graft in the dimple area. The patient did not desire for any further treatment at this time.

In conclusion, this case report emphasizes the importance of considering dental infection as a primary etiology in cutaneous facial sinus tracts. Although odontogenic cutaneous sinus tracts frequently develop adjacent to the source of the underlying infection, the likelihood of a distant lesion must always be considered. This case involved a cutaneous sinus draining in the cheek, which was related to a non-vital upper molar, the sinus was initially misdiagnosed by physicians and repeated treatment attempts were unsuccessful. After referral to an endodontic clinic, the underlying cause was recognized. Appropriate treatment was followed by rapid resolution of the lesion. This case report emphasizes the need for physicians managing treatment of similar cases to be aware of the dental origin of cutaneous sinuses in the head and neck region. Physicians should consider referral to a dental practitioner for further evaluation. Dental practitioners should also perform

a thorough history and examination, accompanied by appropriate additional investigations.

Acknowledgment. *The authors would like to thank Dr. Ahmed Al-Eissa, for his help in the treatment of the patient with Scar subcision and Fraxel laser skin resurfacing after her dental treatment.*

References

1. Curvers F, De Haes P, Lambrechts P. Non-surgical endodontic therapy as treatment of choice for a misdiagnosed recurring extraoral sinus tract. *European Endodontic Journal* 2017; 2: 13.
2. Bai J, Ji AP, Huang MW. Submental cutaneous sinus tract of mandibular second molar origin. *Int Endod J* 2014; 47: 1185-1191.
3. Sato T, Suenaga H, Igarashi M, Hoshi K, Takato T. Rare case of external dental fistula of the submental region misdiagnosed as inverted follicular keratosis and thyroglossal duct cyst. *Int J Surg Case Rep* 2015; 16: 39-43.
4. Rabuffetti A, Augello M, Husner A, Ghazal G, Leiggenger CS. An uncommon cause for a non-healing cutaneous fistula in the parotid gland area - A case report. *Ann Med Surg (Lond)* 2018; 33: 36-39.
5. Tian J, Liang G, Qi W, Jiang H. Odontogenic cutaneous sinus tract associated with a mandibular second molar having a rare distolingual root: a case report. *Head Face Med* 2015; 11: 13.
6. Guevara-Gutiérrez E, Riera-Leal L, Gómez-Martínez M, Amezcua-Rosas G, Chávez-Vaca CL, Tlacuilo-Parra A. Odontogenic cutaneous fistulas: clinical and epidemiologic characteristics of 75 cases. *Int J Dermatol* 2015; 54: 50-55.
7. Giménez-García R, Martínez-Vera F, Fuentes-Vera L. Cutaneous Sinus Tracts of Odontogenic Origin: Two Case Reports. *J Am Board Fam Med* 2015; 28: 838-840.
8. Chang LS. Common pitfall of plastic surgeon for diagnosing cutaneous odontogenic sinus. *Arch Craniofac Surg* 2018; 19: 291-295.