

# Myocarditis and intramural coronary vasculitis in polyarteritis nodosa: an unusual treatable form of heart failure

Cristina Chimenti<sup>1,2</sup>, Maria Alfarano<sup>1</sup>, Federica Toto<sup>1</sup>, Francesca Fanisio<sup>1</sup>, Romina Verardo<sup>2</sup>, Nicola Galea<sup>3</sup>, Luciano Agati<sup>1</sup> and Andrea Frustaci<sup>1,2\*</sup>

<sup>1</sup>Department of Clinical, Internal, Anesthesiologist and Cardiovascular Sciences, Sapienza University, Viale del Policlinico 155, Rome, 00161, Italy; <sup>2</sup>Cellular and Molecular Cardiology Lab, IRCCS L. Spallanzani, Rome, Italy; <sup>3</sup>Department of Experimental Medicine, La Sapienza University, Rome, Italy

## Abstract

We describe an uncommon cardiac presentation of polyarteritis nodosa. A 68-year-old woman, with a history of fatigue, weight loss, and myalgia of the lower extremities, was admitted for congestive heart failure. Coronary arteries were normal. Endomyocardial biopsy showed active lymphocytic myocarditis with associated intramural small vessels necrotizing vasculitis. The overexpression of TLR-4 and the negativity for myocardial viruses suggested an immune mediated mechanism of cardiac damage. These histologic findings associated to weight loss >4 kg not due to dieting or other factors, myalgias, and polyneuropathy, were consistent with the diagnosis of polyarteritis nodosa. Immunosuppressive treatment, consisting of cyclophosphamide and prednisolone, led to a significant improvement of cardiac function. Polyarteritis nodosa can be the cause of unexplained heart failure due to myocarditis and intramural vessels vasculitis. Its recognition is crucial to obtain a cardiac recovery with a tailored immunosuppressive treatment.

**Keywords** Myocarditis; Polyarteritis nodosa; Immunosuppression

Received: 2 July 2020; Revised: 30 July 2020; Accepted: 26 August 2020

\*Correspondence to: Andrea Frustaci, Department of Clinical, Internal, Anesthesiologist and Cardiovascular Sciences, Sapienza University, Viale del Policlinico 155, 00161 Rome, Italy. Tel: + 39 06 5517 0520. Email: biocard@inmi.it

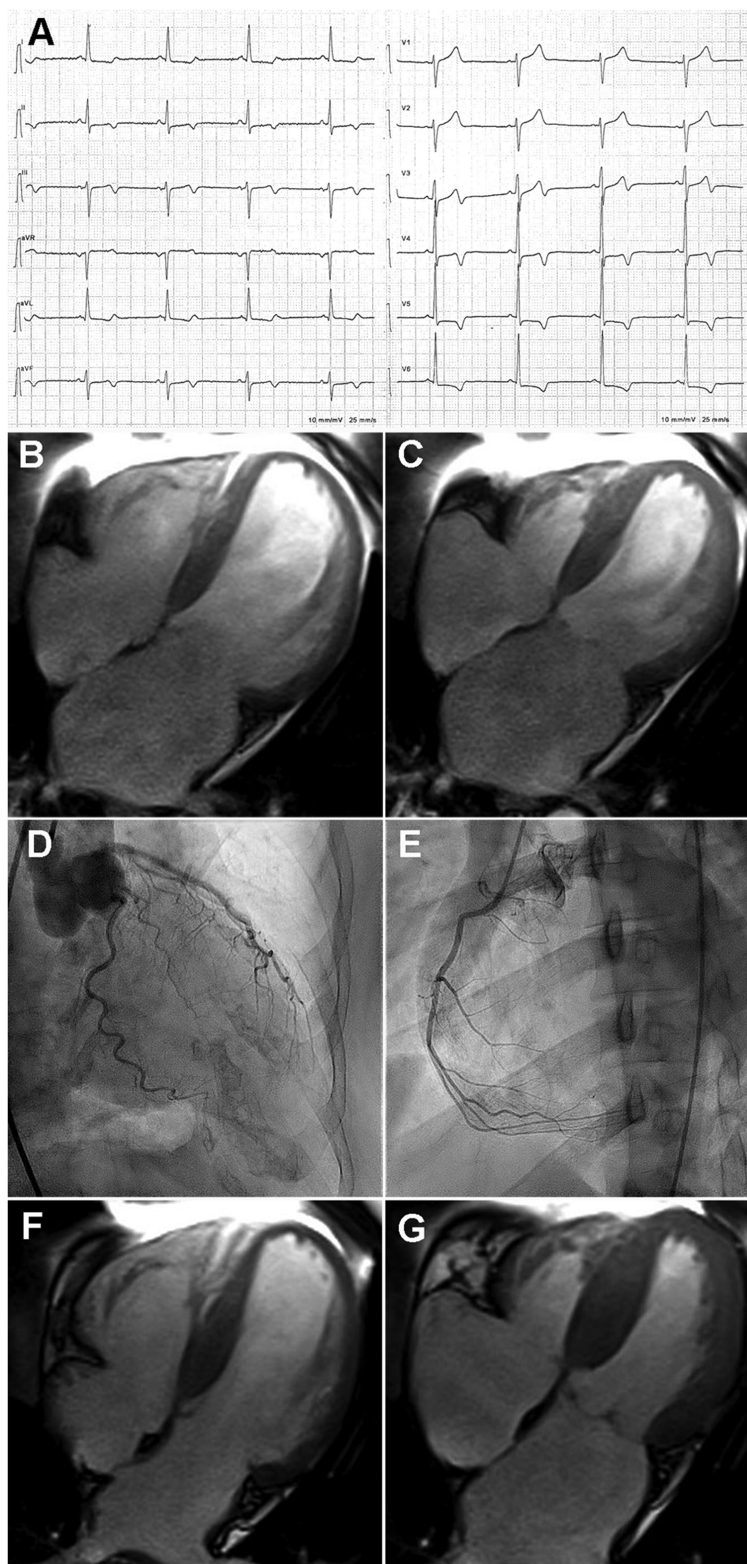
## Introduction

Heart failure is a leading cause of deaths and hospitalization. Mortality rate is as high as 50% within 5 years from diagnosis and 25% at 1 month readmission<sup>1</sup> and depends largely on demographics, disease severity, and the use of appropriate medical therapy. It can be caused by several and heterogeneous entities, including coronary, valvular, and heart muscle diseases. The identification of the underline cause is crucial to establish a possible specific treatment and to obtain a functional recovery. We described an unusual case of polyarteritis nodosa, which presented with congestive heart failure in which the appropriate diagnosis was followed by a significant improvement in cardiac function with an immunosuppressive treatment.

## Case report

A 68-year-old woman was admitted for severe myalgia and fever. She had a 7-month history of fatigue, weight loss of about 6 kg, headache, and myalgia of the lower extremities. Her symptoms began after an episode of EBV viral infection. Clinical assessment demonstrated shortness of breath on mild exertion (NYHA III), no neuromuscular weakness, tenderness, or skin abnormalities. Cardiac examination showed normal heart sounds without murmur. Routine laboratories tests were normal apart from the following: Hb: 12.4 g/dL, WBC: 9,160/μL (64% neutrophils), CRP: 18 mg/L. An electrophysiologic test of the lower extremities revealed an axonal sensorimotor asymmetric polyneuropathy and myopathy. Colour-duplex ultrasound was consistent with

**Figure 1** (A) ECG revealing sinus rhythm with repolarization abnormalities. (B, C) Cardiac magnetic resonance 4-chamber view cine steady-state free-precession frames in diastole (B) and systole (C) showing reduced LV function. (D, E) Left (D) and right (E) coronary angiography demonstrating normal coronary network. (F, G) Cardiac magnetic resonance 4-chamber cine steady-state free-precession frames on end diastole (F) and systole (G) showing recovery of cardiac contractility.



right subclavian and temporal arteritis. To rule out systemic autoimmune diseases, extractable nuclear antigen (ENA), anti-dsDNA antibodies (anti-DNA), lupus anticoagulant, anti-JO-1, anti-Mi2beta, anti-Mi2alfa, PM-SCL75, PM-SCL100, and anti-Ku were performed and scored negative.

An electrocardiogram revealed a sinus rhythm with a heart rate of 55 b.p.m. and negative T waves in precordial leads V3–V6 (Figure 1A). Two-dimensional echocardiography showed a mildly dilated (left ventricular end-diastolic diameter: 57 mm) and globally hypokinetic left ventricle with ejection fraction reduced to 30%. Cardiac magnetic resonance showed global LV hypokinesia (Figure 1B and C and Supporting Information, Movie S1) and subepicardial late gadolinium enhancement of anterolateral segment. In order to identify the aetiology of LV dysfunction, a coronary angiography was performed that showed normal coronary network with no evidence of aneurysms (Figure 1D and E). Thus, the patient underwent a left ventricular endomyocardial biopsy that showed focal lymphomononuclear infiltrates associated with necrosis of adjacent myocytes (Figure 2A), suggestive of active myocarditis according with Dallas criteria. In addition, a necrotizing vasculitis of intramural coronary arteries, identified by the presence of inflammatory infiltrates with necrosis of vessel wall, was detected (Figure 2B). Phenotypic characterization of inflammatory infiltrates showed positivity for T-lymphocytes CD43<sup>+</sup> and CD45RO<sup>+</sup> (Figure 2C) associated with cardiomyocyte overexpression of TLR-4 (Figure 2D). This finding, together with negative PCR for the most common

cardiotropic viruses, including EBV, on myocardial tissue<sup>2</sup> suggested an immune-mediated myocarditis.

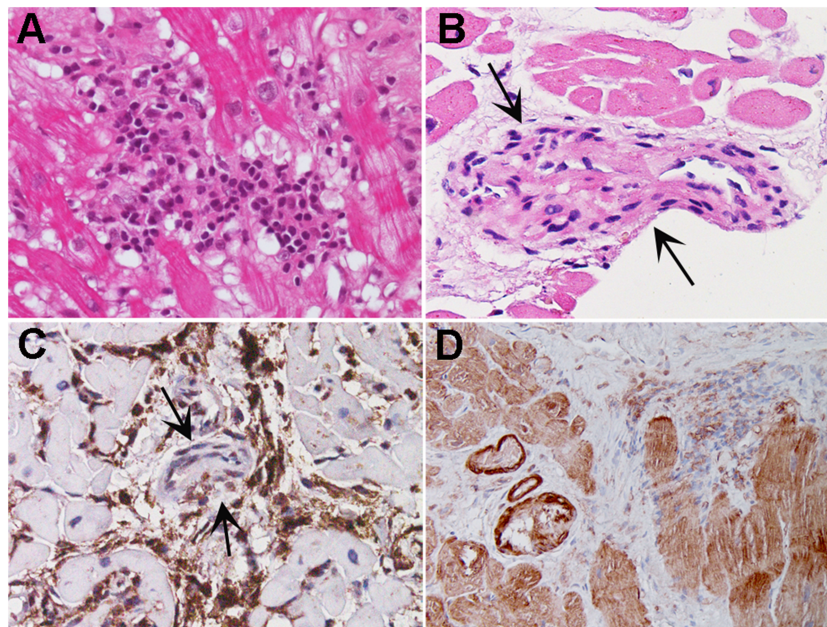
According with the American College of Rheumatology 1990 criteria, the patient received a diagnosis of polyarteritis nodosa,<sup>3</sup> being present 4 out of the 10 criteria (weight loss >4 kg not due to dieting or other factors, myalgia, polyneuropathy, inflammatory infiltrates in the coronary small vessel wall).

Patient was treated with cyclophosphamide (2 mg/kg/day) and prednisolone (1 mg/kg/day). At 6 month follow-up, NYHA class improved from III to I; two-dimensional echocardiography and cardiac magnetic resonance revealed an increase of the LV ejection fraction from 30% to 50%. (Figure 1F and G and Supporting Information, Movie S2), while subepicardial late gadolinium enhancement of anterolateral segment remained unchanged. After 6 months, prednisolone was reduced and withdrawn at 12 months, while cyclophosphamide was continued at a dose of 1 mg/kg every week and after the first year of treatment reduced to 0.5 mg/kg once a month for 12 months.

## Discussion

Polyarteritis nodosa is a rare form of systemic inflammatory necrotizing vasculitis of medium-sized arteries with or without aneurysms formation. It can occur at any age with wide

**Figure 2** (A) Left ventricular endomyocardial biopsy showing active lymphocytic myocarditis associated with intramural coronary vessel vasculitis (arrows) (B) (haematoxylin and eosin; magnification 400×). (C) At immunohistochemistry, inflammatory infiltrates adjacent to cardiomyocytes and vessel wall (arrows) were represented by T lymphocytes CD45RO<sup>+</sup> (magnification 400×). (D) TLR4 immunostaining showed overexpression in cardiomyocytes (magnification 200×).



variability in organ involvement.<sup>4</sup> Cardiac involvement ranges from 4% to 30% and includes mainly coronary vasculitis of epicardial coronary arteries.<sup>5</sup> The occurrence of heart failure is a rare event, mainly related to myocardial infarction, due to epicardial coronary arteries aneurysms and/or thrombotic occlusion.<sup>6</sup> Rarely, polyarteritis nodosa is confined to intramural coronary vessels, while myocardial inflammation, described in up to 3% of autopsy cases,<sup>5,7</sup> has never been demonstrated by *in vivo* reports.

We describe an uncommon cardiac presentation of polyarteritis nodosa in a patient with congestive heart failure and normal epicardial coronary arteries. The diagnosis was obtained 'in vivo' by endomyocardial biopsy that showed intramural small vessels necrotizing vasculitis and active lymphocytic myocarditis. The overexpression of TLR-4 and the negativity for myocardial viruses suggested an immune mediated mechanism of cardiac damage.<sup>8</sup> Immunosuppressive treatment, combining cyclophosphamide and prednisolone, led to a net improvement of cardiac function. Several autoimmune systemic diseases can involve the heart leading to an

inflammatory process and should be taken into account in presence of a new onset heart failure.<sup>9</sup>

In conclusion, polyarteritis nodosa can be the cause of unexplained heart failure due to myocarditis and intramural vessels vasculitis. Its recognition is crucial to obtain a cardiac recovery with a tailored immunosuppressive treatment.

## Supporting information

Additional supporting information may be found online in the Supporting Information section at the end of the article.

**Movie S1.** Cardiac magnetic resonance showed global LV hypokinesia with reduced LV ejection fraction to 30%.

**Movie S2.** Increase of the LV ejection fraction to 50% after immunosuppressive therapy.

## References

1. Levy D, Kenchaiah S, Larson MG, Benjamin EJ, Kupka MJ, Ho KKL, Murabito JM, Vasan RS. Long-term trends in the incidence of and survival with heart failure. *N Engl J Med* 2002; **347**: 1397–1402.
2. Frustaci A, Calabrese F, Chimenti C, Pieroni M, Thiene G, Maseri A. Lone hepatitis C virus myocarditis responsive to immunosuppressive therapy. *Chest* 2002; **122**: 1348–1356.
3. Lightfoot RW Jr, Michel BA, Bloch DA, Hunder GG, Zvaifler NJ, McShane DJ, Arend WP, Calabrese LH, Leavitt RY, Lie JT, Masi AT, Mills JA, Stevens MB, Wallace SL. The American College of Rheumatology 1990 criteria for the classification of polyarteritis nodosa. *Arthritis Rheum* 1990; **33**: 1088–1093.
4. Hernández-Rodríguez J, Alba MA, Prieto-González S, Cid MC. Diagnosis and classification of polyarteritis nodosa. *J Autoimmun.* 2014; **48–49**: 84–89.
5. Holsinger DR, Osmundson PJ, Edwards JE. The heart in periarteritis nodosa. *Circulation* 1962; **25**: 610–618.
6. Peters B, von Spiczak J, Ruschitzka F, Distler O, Manka R, Alkadhi H. Cardiac manifestation of polyarteritis nodosa. *Eur Heart J* 2018; **39**: 2603.
7. Sakai K, Asakura K, Saito K, Fukunaga T. Sudden unexpected death due to coronary thrombosis associated with isolated necrotizing vasculitis in the coronary arteries of a young adult. *Forensic Sci Med Pathol* 2019; **15**: 252–257.
8. Chimenti C, Verardo R, Scopelliti F, Grande C, Petrosillo N, Piselli P, De Paulis R, Frustaci A. Myocardial expression of toll-like receptor 4 predicts the response to immunosuppressive therapy in patients with virus-negative chronic inflammatory cardiomyopathy. *Eur J Heart Fail* 2017; **19**: 915–925.
9. Caforio ALP, Adler Y, Agostini C, Allanore Y, Anastakis A, Arad M, Böhm M, Charron P, Elliott PM, Eriksson U, Felix SB, Garcia-Pavia P, Hachulla E, Heymans S, Imazio M, Klingel K, Marcolongo R, Matucci Cerinic M, Pantazis A, Plein S, Poli V, Rigopoulos A, Seferovic P, Shoenfeld Y, Zamorano JL, Linhart A. Diagnosis and management of myocardial involvement in systemic immune-mediated diseases: a position statement of the European Society of Cardiology Working Group on Myocardial and Pericardial Disease. *Eur Heart J* 2017; **38**: 2649–2662.