

Outcomes following Microvascular Mandibular Reconstruction in Pediatric Patients and Young Adults

Shannon M. Malloy, BS*
 Wouter J. Dronkers, BSc*†
 Joseph M. Firriolo, MD*
 Laura C. Nuzzi, BA*
 Maarten J. Koudstaal, MD, DMD,
 PhD†‡§
 Bonnie L. Padwa, DMD, MD*¶
 Amir H. Taghnia, MD, MPH,
 MBA*
 Brian I. Labow, MD, FACS, FAAP*

Background: The etiology and treatment of complex mandibular defects in children differ markedly from those of adults, although treatment with free bone flaps is historical in both groups. While adult outcomes and complication rates are well known, few pediatric data exist, especially for patients with congenital deficiencies. This study reports early and late outcomes from a cohort of young, primarily syndromic patients undergoing microvascular mandibular reconstruction.

Methods: This is a retrospective case series of patients who underwent microvascular mandibular reconstruction between 1995 and 2016.

Results: Thirteen patients received a total of 13 fibula transfers and 1 medial femoral condyle transfer. Most patients carried a congenital diagnosis (77%), and the average age during surgery was 11.7 ± 5.7 years. The median (interquartile range) [IQR] length of follow-up was 6.3 (5.7) years. There was a 100% flap survival rate, although 86% of all patients experienced at least one complication. Half of all procedures resulted in an early complication. Nine patients (69%) developed late complications, of which temporal mandibular joint ankylosis was the most common ($n = 5$; 38%).

Conclusions: This study is one of few detailing outcomes following mandibular reconstruction by free flap transfer in pediatric patients. These patients were primarily syndromic with appreciable complication rates higher than in other adult and pediatric studies. Some complications are manageable or self-resolving, but others lead to functional problems that may require late operative interventions to correct. Microsurgical treatment should be reserved for children with large, complex mandibular defects when other options are unavailable or have been exhausted. (*Plast Reconstr Surg Glob Open* 2020;8:e3243; doi: [10.1097/GOX.0000000000003243](https://doi.org/10.1097/GOX.0000000000003243); Published online 20 November 2020.)

INTRODUCTION

Mandibular defects can result in significant functional and aesthetic abnormalities, impairing speech, mastication, swallowing, respiration, and psychosocial well-being.¹ In adults, malignancy is the primary origin of mandibular defects, with approximately 80% of patients undergoing

radiation therapy in conjunction with surgical resection.^{2,3} Osseous or osteocutaneous free flaps have become the preferred treatment option for patients of all ages with complex mandibular defects that are large (>6 cm), require multiple tissue types, have been exposed to radiation, or have failed previous treatment strategies.^{1,4-9} Although fibula flaps are common and reliable (97% flap survival),¹⁰ adult studies report high complication rates (28%–61%).^{3,11-15}

Mandibular defects in children and young adults are relatively uncommon and are primarily congenital in nature, followed by primary bone tumors and trauma.¹⁶⁻²⁴ Pediatric patients are rarely exposed to radiation, tend to have smaller defects, and have better tissue quality, thus affording the opportunity to mitigate most defects with non-microsurgical techniques.²⁵

However, a subset of children has complex or large mandibular defects, and these patients will require more intensive interventions, such as free tissue transfer. Given the rarity of these conditions, it is not surprising that few

From the *Department of Plastic and Oral Surgery, Boston Children's Hospital, Harvard Medical School, Boston, Mass.; †Department of Oral and Maxillofacial Surgery, Erasmus Medical Center, Rotterdam, The Netherlands; ‡Karolinska Institute, Stockholm, Sweden; §University College London Medical School, London, UK; and ¶Harvard School of Dental Medicine and Harvard Medical School, Boston, Mass.

Received for publication July 29, 2020; accepted September 14, 2020.

Copyright © 2020 The Authors. Published by Wolters Kluwer Health, Inc. on behalf of The American Society of Plastic Surgeons. This is an open-access article distributed under the terms of the [Creative Commons Attribution-Non Commercial-No Derivatives License 4.0 \(CCBY-NC-ND\)](https://creativecommons.org/licenses/by-nc-nd/4.0/), where it is permissible to download and share the work provided it is properly cited. The work cannot be changed in any way or used commercially without permission from the journal.

DOI: [10.1097/GOX.0000000000003243](https://doi.org/10.1097/GOX.0000000000003243)

Disclosure: None of the authors has a financial interest in any of the products, devices, or drugs mentioned in this manuscript.

outcomes studies exist on free tissue transfer for treating pediatric mandibular defects.^{1,13,16–23} Most have limited follow-up times and primarily concern about defects secondary to trauma or cancer, with few reports dedicated to pediatric patients with congenital conditions (eg, craniofacial microsomia (CFM)).^{1,16,17,20,26–29} For syndromic patients, non-microsurgical approaches are usually exhausted or not applicable, rendering free tissue transfer as a viable option. Caution must be exercised when extrapolating data concerning mandibular defect reconstruction from adults to children and adolescents, as these two populations have drastically different defect etiology, tissue condition, growth patterns, and healing potentials. The purpose of this retrospective case series is to report early and late outcomes in pediatric patients undergoing microsurgical mandibular reconstruction for both congenital and acquired conditions.

METHODS

This study was approved by the Boston Children’s Hospital Institutional Review Board (IRB-P00027292) with a waiver of informed consent to retrospectively review the medical records and retrieve clinical data of patients who presented to our institution for mandibular reconstruction using an osseous or osteocutaneous free flap from January 1995 through July 2016. Potential patients were identified using the *Current Procedural Technology* codes for free vascularized bone flaps: fibula (20955), metatarsal (20957), other bone graft (20962), and free osteocutaneous flap with microvascular anastomosis (20969).

Clinical notes, operative reports, perioperative and postoperative 2D and 3D photography, and pathology and radiology reports served as primary information sources. Demographic variables obtained included gender, age at the time of surgery, and primary diagnosis, and previous attempts at mandibular reconstruction were recorded. Follow-up time was defined as the length of time between the date of surgery and most recent office visit. Pertinent operative details included the location and extent of the defect, type of flap, donor and recipient vessels, fixation

techniques, and any additional procedures related to outcomes following mandibular reconstruction.

Outcomes data including flap survival, early and late complications, facial symmetry, and dental occlusion were recorded. Dental occlusion was measured using Angle’s Classification on both the right and left sides, and then averaged to determine a final occlusion grade.³⁰ Given the long follow-up period for these patients, early outcomes were defined as those assessed within the first postoperative year, while late outcomes were defined as those assessed after a minimum of 1-year follow-up to better differentiate early and late outcomes. Descriptive statistics were performed for all variables, using SPSS, version 23.0 (IBM Corp, Armonk, N.Y.) The two-tailed Fisher exact test was used to compare clinical information. The mean was reported for normally distributed variables, while the median was reported for variables with a skewed distribution. A maximum threshold of 20% missing data was used for all analyses and $P < 0.05$ was considered statistically significant for all analyses.

RESULTS

Patient Characteristics

The sample included 13 patients undergoing 14 mandibular reconstructive procedures using free bone flaps. Eight (62%) patients were women, with a mean age at the time of surgery of 11.7 ± 5.7 years (range, 1.9–21.4 years; Table 1). An estimated 10 (77%) patients had a congenital anomaly as their primary diagnosis: 8 patients with type III craniofacial microsomia (CFM) who have been featured in a previous case series,³¹ and 2 with bilateral CFM. Two additional patients underwent hemimandibulectomy for Ewing sarcoma with adjuvant chemotherapy, and 1 underwent hemimandibulectomy for osteosarcoma with neoadjuvant and postoperative chemotherapy. One patient underwent an additional free tissue transfer after a non-union occurred following distraction, lengthening 10 years after the index reconstruction. Six (46%) patients had a prior failed attempt at reconstruction using non-vascularized bone grafts.

Table 1. Patient Characteristics

Patient	Gender	Primary Diagnosis	Affected Side	Age at Surgery (y)	Length of Follow-up (y)	Previous Attempted Reconstruction(s)
1 ^A	Female	CFM	Left	8.4	12.0	Costochondral bone graft
1 ^B	Female	Non-union after late distraction	Left	18.1	2.2	Costochondral bone graft, free fibula flap
2	Male	CFM	Left	12.8	8.5	—
3	Female	CFM	Right	6.3	3.2	—
4	Female	CFM	Right	9.5	7.9	—
5	Female	CFM	Right	5.9	7.7	Costochondral bone graft (2)
6	Male	Ewing sarcoma	Right	11.3	4.9	—
7	Female	CFM	Left	7.7	8.6	—
8	Female	CFM	Left	18.9	7.8	Iliac crest bone graft
9	Male	CFM	Left	21.4	2.1	Costochondral bone graft
10	Female	CFM	Right	14.7	3.8	Costochondral bone grafts (2), iliac crest bone graft (2)
11	Male	CFM	Right	16.8	2.3	Costochondral bone graft
12	Male	Ewing sarcoma	Left	1.9	10.0	—
13	Female	Osteosarcoma	Right	10.5	3.1	—

^{1A} refers to the first free bone flap transfer; ^{1B} refers to this patient’s second bone flap transfer. CFM, craniofacial microsomia.

Operative Details

Fibula flaps were used in all 13 patients (Table 2). An additional medial femoral condyle flap was used in one patient to treat a non-union. Nine procedures (64%) used osseous bone flaps, while osteocutaneous flaps were used in the remaining 5 (36%). The ramus-condyle was the most frequently reconstructed anatomic site (n = 8), followed by the hemimandible (n = 4), and the ramus-body (n = 2). The mean length of harvested fibula bone was 8.9 ± 2.9 cm (range, 4.0–14.0 cm) (Figs. 1–4). The length of the medial femoral condyle flap was 4.5 cm.

Early Outcomes

The median (IQR) clinical follow-up was 6.3 (5.7) years (range, 2.1 years–12.0 years). There was a 100% survival rate for all 14 bone flaps based on radiographic imaging at follow-up. In this series, 46% of patients experienced at least one early complication occurring within the first postoperative year, which included partial transient facial nerve palsy (n = 4), surgical site infection (n = 3), open wound at the donor site (n = 1), native neck skin and soft-tissue loss at the recipient site requiring debridement and closure (n = 1), and non-union at the distal osteosynthesis site (n = 1) (Table 3). All early complications resolved following supportive therapy or were corrected with a secondary procedure.

Late Outcomes

Dental occlusion was determined in 11 patients. Most patients had a severe malocclusion before reconstruction. After reconstruction, 5 (45%) patients obtained a Class I occlusion, while 6 (55%) patients had a class II malocclusion (Fig. 5). The majority of patients with malocclusion (n = 4, 67%) received orthodontic treatment to improve occlusion. Occlusion could not be determined for 2 patients due to the absence of clinical dental photographs. Mandibular symmetry (midline deviation) following reconstruction could be assessed in 9 (69%) patients. The mean midline deviation was 3.2 ± 2.5 mm (range, 0.0–8.0 mm).

Late complications were observed in 10 (71%) of 14 procedures. Temporal mandibular joint (TMJ) ankylosis was the most common late complication (n = 5). All patients who developed TMJ ankylosis were patients with CFM and developed the complication an average of 2.5 ± 1.4 years post-reconstruction (range, 1.1–4.4 years). These patients subsequently underwent TMJ release and arthroplasty at an average of 2.9 ± 1.5 years after microsurgical reconstruction. This procedure was repeated in 2 patients due to recurrent ankylosis. One patient developed a temporomandibular disorder (TMD) with chronic facial pain and swelling, which responded to supportive pain management treatment. One patient experienced limited motion at the TMJ, which required prolonged physical

Table 2. Operative Details

Patient	Extent of Defect	Affected Side	Surgical Approach	Type of Bone Flap	Length of Bone Flap (cm)	Donor Vessel	Recipient Vessel
1 ^A	Ramus-condyle unit	Left	Tunnel	Fibula, osseous	8.0	FA	EJV
1 ^B	Hemimandible	Left	Submandibular incisions	Medial femoral condyle, osseous	4.5	STA	EJV
2	Ramus-condyle unit	Left	Tunnel	Fibula, osseous	11.0	EC	IJV
3	Ramus-condyle unit	Right	Tunnel	Fibula, osseous	9.0	EC	EJV
4	Ramus-condyle unit	Right	Tunnel	Fibula, osseous	10.0	STA	FV
5	Ramus-condyle unit	Right	Tunnel	Fibula, osseous	10.0	FA	EJV
6	Hemimandible	Right	Open	Fibula, osteocutaneous	7.0	FA	FV
7	Ramus-condyle unit	Left	Tunnel	Fibula, osteocutaneous	10.0	STA	FV & EJV
8	Ramus-condyle unit	Left	Tunnel	Fibula, osteocutaneous	11.0	STA	IJV
9	Ramus-condyle unit	Left	Tunnel	Fibula, osseous	11.0	EC	EJV
10	Ramus-body	Right	Tunnel	Fibula, osseous	8.0	LA	EJV
11	Ramus-body	Right	Tunnel	Fibula, osteocutaneous	6.0	EC	EJV
12	Hemimandible	Left	Open	Fibula, osseous	4.0	FA	EJV
13	Hemimandible	Right	Open	Fibula, osteocutaneous	14.0	STA	IJV & EJV

EC, external carotid artery; EJV, external jugular vein; FA, facial artery; FV, facial vein; IJV, internal jugular vein; LA, lingual artery; STA, superficial temporal artery.

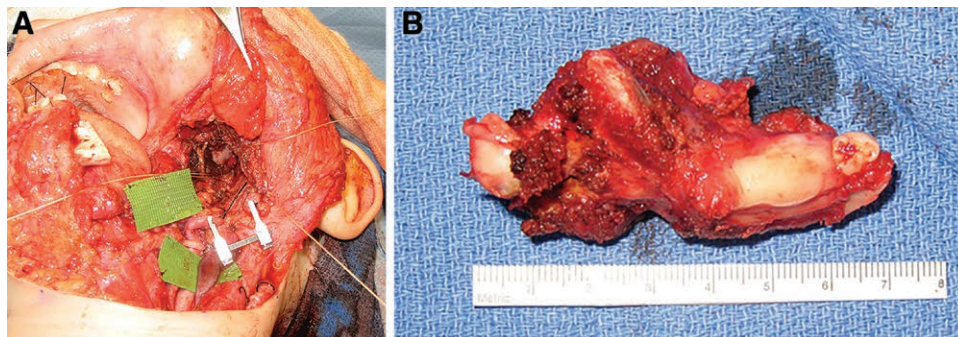


Fig. 1. Patient with Ewing sarcoma following resection. (A) The intact glenoid cartilage is seen in the deepest part of the wound, and the buccal fat pad is held cranially by forceps. Stay sutures in the pterygoid musculature were used to stabilize the flap following inset. The double approximating clamp holds a potential donor vessel. (B) Resected mandible specimen with clear margins.

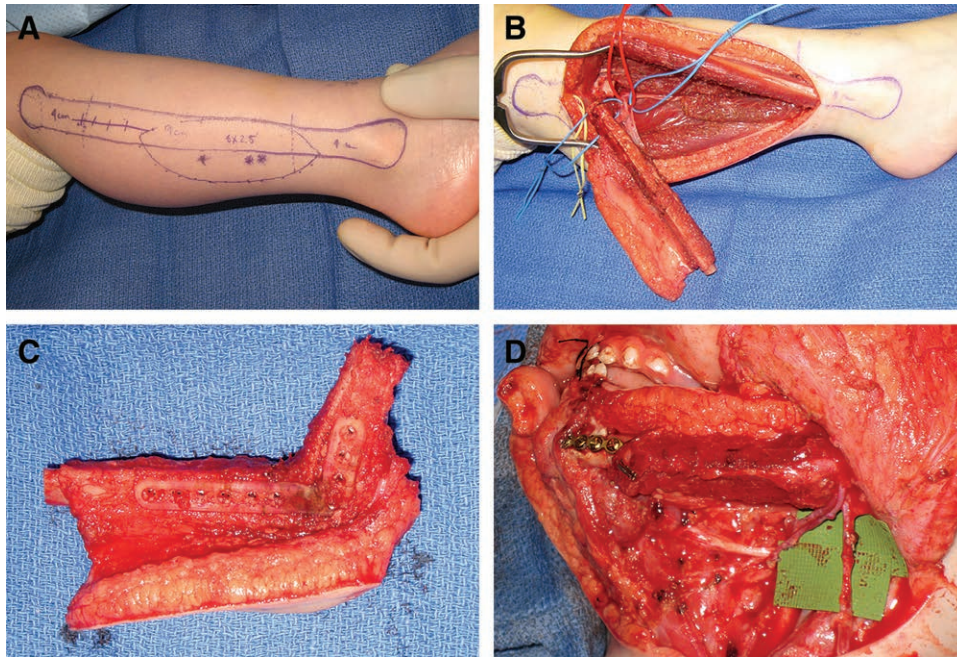


Fig. 2. Osteoseptocutaneous fibula harvest and flap placement in mandible. (A) Preoperative markings for osteoseptocutaneous fibula harvest. (B) Flap in situ attached by peroneal vessels. (C) Flap following single osteotomy and fixation using a resorbable plate in case distraction is needed later in life. (D) Flap inset and revascularized. The facial artery, lingual vein, and external jugular vein were used.

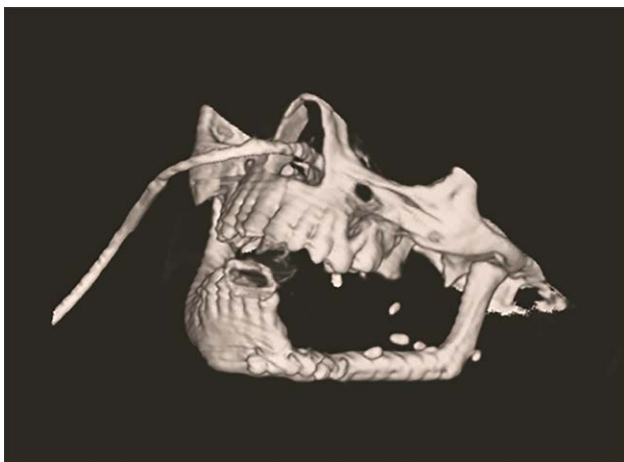


Fig. 3. Three months postoperative three-dimensional CT scan image of the flap. The new "condyle" is well-seated in TMJ.

therapy after reconstruction. No growth disturbances were observed following surgery.

Other long-term complications included chronic pain (n = 1), non-union (n = 1), chronic open wound (n = 1), hypertrophic scarring (n = 1), and donor site morbidity (n = 1). These were resolved either via a secondary procedure or ongoing management. Only 2 patients experienced donor site complications. One patient who was initially clinically monitored for a non-healing wound at the donor site categorized as a short-term complication ultimately received a local flap to cover the defect. The remaining patient experienced chronic right heel pain, leg length discrepancy, and valgus anomalies of the donor leg and knee, all of which resolved with physical therapy.

As previously stated, 6 of 13 patients underwent previous reconstruction using non-vascularized bone grafts. Complication rates (presence of early, late, or any

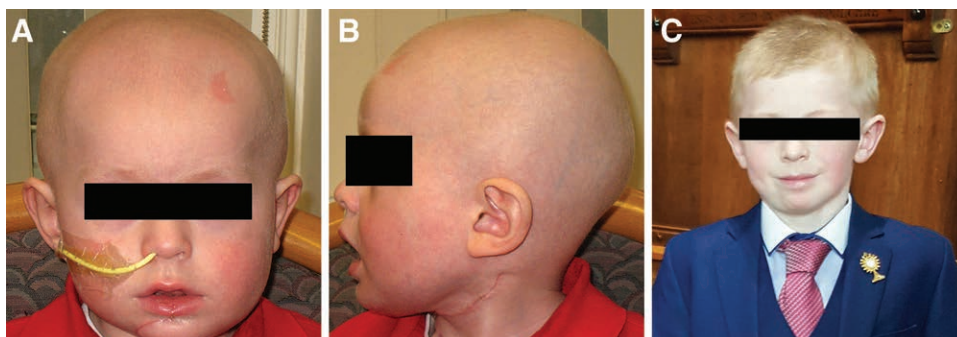


Fig. 4. Postoperative photographs of a pediatric patient. Patient outcome 2 weeks (A) and 6 years (B) after surgery.

Table 3. Patient Outcomes

Outcome	Patient Incidence (n)
Short-term (within postoperative year)	
Transient facial paresis	31% (4)
Surgical site infection	23% (3)
Bone non-union	7% (1)
Open wound	7% (1)
Soft-tissue loss requiring debridement and closure	7% (1)
Long-term (>postoperative year)	
Flap survival	100% (13)
TMJ ankylosis	38% (5)
Chronic pain	7% (1)
Chronic neck wound	7% (1)
Bone non-union	7% (1)
Donor site morbidity	7% (1)

complications) did not vary by prior reconstruction history ($P > 0.05$, all) (Fig. 6).

DISCUSSION

In this study, we retrospectively analyzed clinical and demographic data for pediatric patients and young adults undergoing mandibular reconstruction using free vascularized bone flaps. To date, this investigation represents

one of the few studies of its kind to detail complications of mandibular reconstruction in mostly syndromic pediatric patients.

Outcomes data for mandibular reconstructions are well known in adults. Although the vast majority of attempted flap transfers are successful, they are accompanied by high complication rates. Common complications for adults include surgical site infection, hematoma, skin necrosis, fistulae, facial nerve injury, dental malocclusion, ankle instability, and metatarsal flexor dysfunction.^{17,22,31-34} Due to patients' advanced age, defects of primarily oncologic origin, poor tissue quality, and comorbidities, these complications can be difficult to manage.

Although the general techniques are similar, flap transfers for mandibular reconstruction differ between adult and pediatric groups. In adults, the tissues at both the donor and recipient sites tend to be of poorer quality due to malignancy and age, increasing the risk of complications like non-union and infection.³⁵ Conversely, children undergoing mandibular reconstruction often have non-cancerous diagnoses, such as craniofacial conditions or trauma. The affected site is usually exempt from radiation treatment, preserving the tissues in good condition for reconstruction. Children also have relatively large

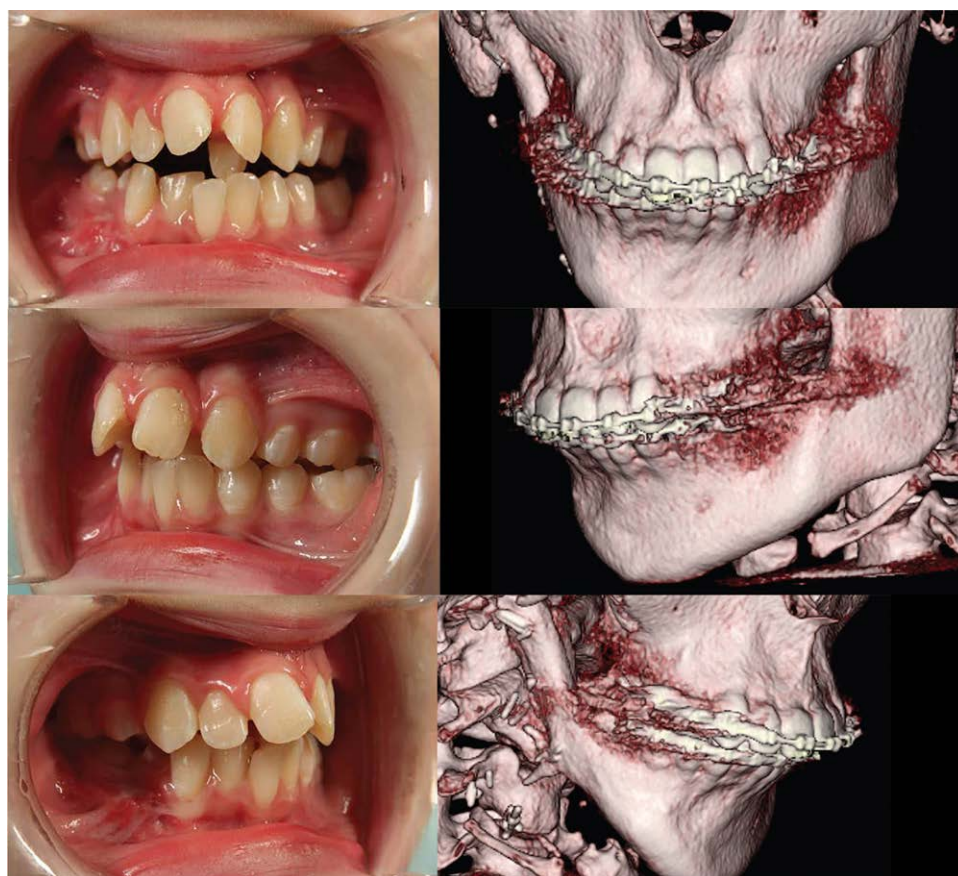


Fig. 5. Malocclusion and correction. Left column, Preoperative photographs demonstrating malocclusion of a patient with CFM. Right column, Postoperative scan images with reconstructed mandible and orthodontics showing improved occlusion.

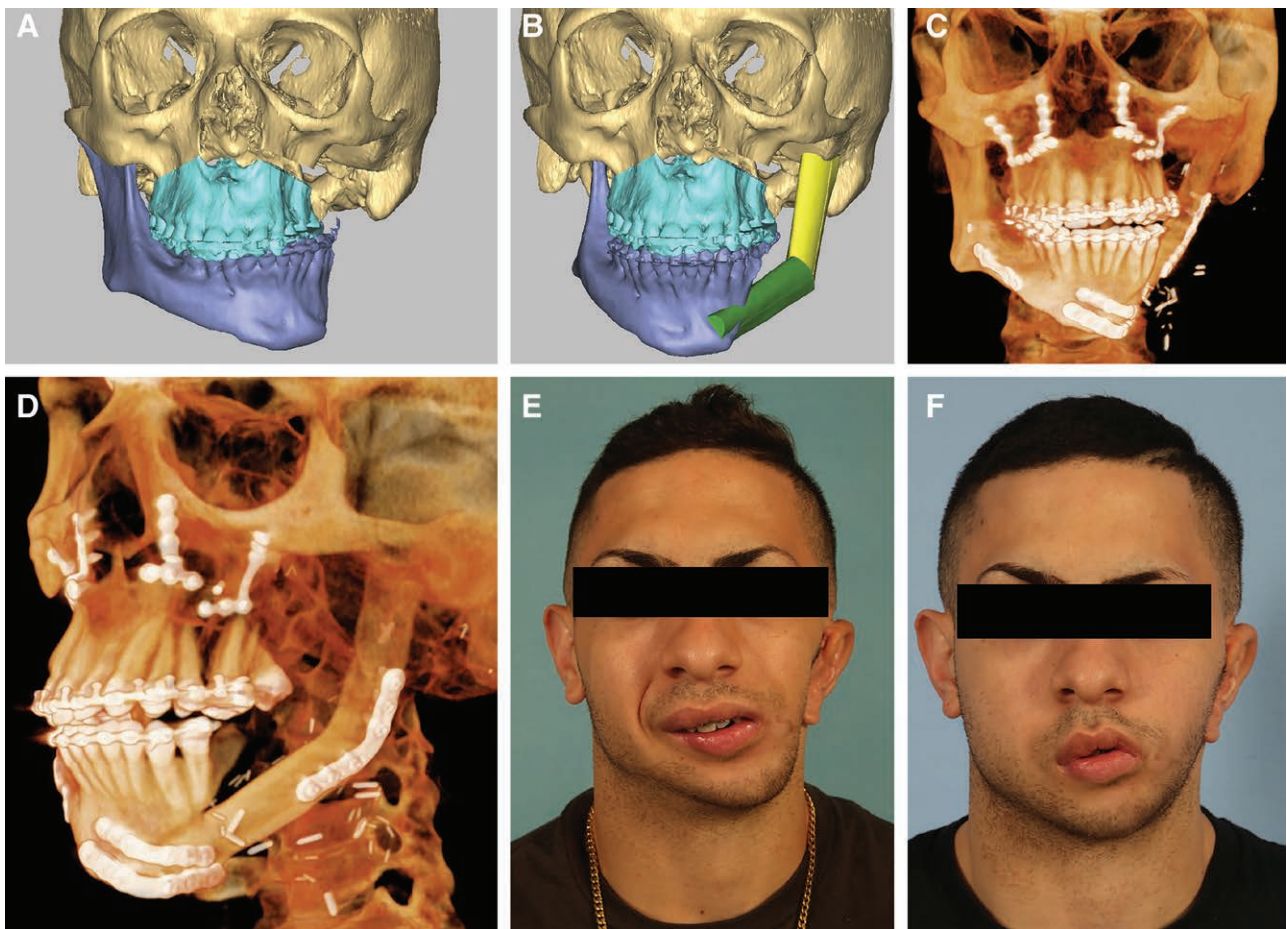


Fig. 6. CFM patient undergoing mandibular reconstruction. (A) Preoperative 3D CT scan image of an adult male patient with CFM. (B) Proposed fibula placement. (C,D) Postoperative scan images showing the newly reconstructed mandible. (E) Preoperative photograph of the patient. (F) Postoperative results.

pedicle vessels often free from systemic disease, such as type II diabetes mellitus, which may adversely affect vascular patency. Unlike adults who are skeletally mature, pediatric patients will continue to experience local dynamic changes following flap transfer as they grow. However, potential secondary asymmetry, additional mandibular reconstruction later in life, and donor site complications raise concerns for free-bone flaps in this population. Despite the potential benefits of vascularized bone flaps in pediatric mandibular reconstruction, research in young patients is limited, with most reports limited to surgical technique.^{1,16–18,26,27,36}

In this series, the flap transfer survival rate was 100%, similar to other pediatric case series.^{1,16,17,20,27} However, 86% of all patients in this sample experienced at least 1 early or late complication. This complication rate is higher than those reported in the pediatric and adult literature (range, 0%–73%).^{1,16,17,20,26–29} In part, this may reflect the extended follow-up period and inclusion of late complications such as TMJ ankylosis, which may not have manifested in other studies with shorter follow-up periods.^{1,16–18,20,21,36,37}

The most common early complications observed in our sample included transient facial nerve palsy, surgical site infections (SSI), and bony non-union. These complications

occurred at rates comparable to previous pediatric syndromic and oncologic series.^{1,16,20,26,27} Known risk factors for developing postoperative SSI and non-union include malignant pathology, large oral defects, free flap reconstruction, mandibulectomy, and clean-contaminated surgical sites.³ The facial neuropraxia is most likely secondary to intraoperative traction injury. The two-incision tunneled approach diminishes scarring and the extent of dissection. However, in patients with congenital mandibular differences, both a soft-tissue and bony deficiency exist. Despite using a deep approach below the facial nerve with a nerve-stimulator, expansion of facial width places the soft-tissues and nerve on stretch. In some patients, facial weakness lasted up to 6 months, but always resolved. In no instances was there a permanent loss of facial nerve function.

The most common late complication in our cohort was TMJ ankylosis, which is not observed in adult studies and may contribute to the high complication rate in this series. In this series, all CFM patients presented with Kaban-Pruzansky type III mandibles marked by an absence of the TMJ³⁸ and ankylosis occurred in the reconstructed joint in 5 patients. We attempted to improve symmetry and posterior facial height by rotating the mandible to the midline in a counterclockwise direction. We established the best-fit

dental occlusion and fixed this position intraoperatively with intermaxillary fixation (IMF) and an occlusal splint, while the fibula was inserted without a contralateral-releasing osteotomy in the youngest patients. The ramus lengthening and midline correction on the affected side might have caused the fibula to push superiorly into the fossa. The tight abutment of the articulating surface of the fibula and skull base in our patients who did not undergo contralateral-releasing osteotomies may have contributed to our high rate of ankylosis. In the previous study from our group, we found that the use of a contralateral-releasing osteotomy was significantly associated with a reduction in ankylosis in patients with CFM undergoing construction of the ramus-condyle with a fibula flap.³¹ Another study reported a series of 10 patients with CFM who received a free fibula flap for ramus construction at a mean age of 7.2 years.²⁹ In contrast to our results, ankylosis did not develop in any of their patients over a mean follow-up period of 45 months. They inserted the fibula in a passive position with a plan for distraction osteogenesis at a later date to lengthen and rotate the mandible. The difference in technique between these two reports, rather than the use of a microvascular flap, is likely what accounted for the significant difference in the rate of ankylosis.

Fortunately, TMJ ankylosis was corrected successfully in all patients following gap arthroplasty. We recommend avoiding close approximation of the articulating flap surface and the skull base. This can be accomplished either by creating a contralateral-releasing osteotomy to allow the mandible to rotate while minimizing upward pressure on the fibula at the time of the construction, or by inserting the fibula in a passive position and planning to use distraction osteogenesis in the future to achieve symmetry and occlusal correction.³⁸

Of the 3 oncological patients in our series, 2 experienced early complications, and all experienced late complications. At the time of surgery, 1 patient had recently finished chemotherapy and 2 patients were concurrently receiving chemotherapy, which may have impeded wound healing. Other studies report similar complications with oncological patients who received adjuvant therapies, suggesting that oncologic treatment may increase the risk of a short- or long-term complication, regardless of age.^{17,39}

Ankle instability and other donor-site morbidities are common complications following fibula flap transfers.¹⁷ In our series, 2 patients developed donor-site complications, which required treatment via soft-tissue transfer or physical therapy. Furthermore, permanent ankle instability and bone-deformity at follow-up were not reported in any of our patients. It should be emphasized that standard measurements cannot be applied to pediatric fibula flap design, and that leaving the proximal and distal quarter of the bone is generally safe. Given that less than 10 cm of bone was required for most patients in our series, more than enough fibula remained to ensure ankle and knee stability.

Almost half (46%) of patients in this series underwent a prior reconstruction using a non-vascularized bone graft. Prior non-vascularized bone grafting was not associated with developing a postoperative complication, and

such history should not solely dissuade surgeons from subsequent attempt with a vascularized bone flap.

After reconstruction, nearly half (42%) of our sample achieved class I occlusion, while the remainder had a class II malocclusion because of either insufficient advancement or unsatisfactory growth of the constructed ramus-condyle unit. There were 2 patients (patients 3 and 4) who had a class I occlusion following fibula construction, but after ankylosis release, the mandible on the reconstructed side moved posteriorly, resulting in a class II malocclusion. Our rate of post-construction malocclusion is higher than that reported in previous studies, which vary from 0% to 18%.^{17,20} However, these two studies assessed occlusal results with a panoramic radiograph, which is insufficient for properly documenting malocclusion. One study reported their results of fibula reconstruction in a cohort of children who had resection for benign and malignant pathology.¹⁷ Although it was not documented, these patients likely had a normal pre-morbid occlusion. These patients, who exhibited otherwise normal development, differ significantly than our sample, which was composed primarily of patients with congenital asymmetry and malocclusion, which may explain our unusually high rate of malocclusion. In our cohort, skeletally mature patients had correction of class II malocclusion and remaining asymmetry with orthognathic surgery.

Symmetry is an elusive goal in facial reconstruction in pediatric patients, especially in syndromic children, due to the complexity of these deficits and also the differential growth of the reconstructed and uninvolved sides. Patients should be advised that future interventions may be suggested to optimize facial symmetry. Most of our patients developed minor mandibular midline deviation over time. Although some studies report excellent outcomes after reconstruction, others describe the necessity for additional operations to improve facial symmetry.^{1,20,38} Orthognathic surgery, genioplasty, structural fat grafting, or soft-tissue corrections can all be used to mitigate some of the long-term effects of differential growth. In this series, no cases displayed any secondary asymmetry remotely severe enough to approach the original deformity.

Although our series reflects higher complication rates than those in adults, the nature of the complications in our series differs markedly. This highlights how free flap reconstruction can have drastically different risk profiles depending on the patient's age and defect etiology.³ Furthermore, the importance of long-term outcomes is underscored by the observation that roughly half the patients in this series did not manifest their complication until after the first postoperative year.

Microvascular bone flap transfer procedures present an innovative and viable option for pediatric patients with complex medical needs by potentially restoring functionality in the mandible and improving overall quality of life. However, as demonstrated in this series, these operations are technically demanding, with long recovery periods and high postoperative complication rates. Surgeons should only consider this surgical route if defects are sufficiently large and complex that less-invasive forms of treatment are not applicable or have failed. In addition,

given the dental, orthognathic, and TMJ issues surrounding these cases, a craniofacial team of microsurgeons, oral and maxillofacial surgeons, orthodontists, and dentists is required. Surgeons counseling young patients for microvascular mandibular reconstruction develop a long-term plan of care to recognize and treat late complications.

The present study is limited by its retrospective design, small sample size, variable follow-up time, and tertiary center referral bias. Because postoperative films to follow bone healing were not obtained weekly, a precise mean time to bone healing cannot be obtained. However, bone union occurred within 3 months following reconstruction in all patients. This study did not conduct a formal comparison of affected and unaffected sides, nor were flap dimensions measured at follow-up visits. These analyses would greatly strengthen the conclusions of this study and should be incorporated in a systematic manner in future investigations. We do acknowledge that a lack of clinical dental photographs for two patients limits our occlusion analysis. Due to the limited body of literature in this area, additional studies are needed to create standardized measurements for complications, occlusion, and functional and aesthetical outcomes of mandibular reconstruction in pediatric patients. Additional studies should determine the ideal age for surgical intervention in this population because no current guidelines exist.

CONCLUSIONS

This study examines early and late outcomes following mandibular reconstruction using vascularized bone flaps in a pediatric sample. We conclude that this technique is a reliable tool to restore structure and functionality in young patients with large tissue deficiencies of congenital, traumatic, and oncologic origin. Complication rates are appreciable in both short and long term and differ markedly in nature from those of adult patients. Some of these complications are manageable or self-resolving. However, others lead to functional problems and require late operative interventions to correct. As such, microsurgical procedures should be reserved for patients with large, complex mandibular defects where other options cannot be used, or have been exhausted.

Brian I. Labow, MD, FACS, FAAP

Department of Plastic and Oral Surgery
Boston Children's Hospital
300 Longwood Avenue
Boston, MA 02115

E-mail: brian.labow@childrens.harvard.edu

PATIENT CONSENT

Informed consent was obtained from the patients for use of their photographs in this article.

REFERENCES

- Cleveland EC, Zampell J, Avraham T, et al. Reconstruction of congenital mandibular hypoplasia with microvascular free fibula flaps in the pediatric population: A paradigm shift. *J Craniofac Surg.* 2017;28:79–83.
- Merlotti A, Alterio D, Vigna-Taglianti R, et al; Italian Association of Radiation Oncology. Technical guidelines for head and neck cancer IMRT on behalf of the Italian Association of Radiation Oncology – Head And Neck Working Group. *Radiat Oncol.* 2014;9:264.
- van Gemert JTM, Abbink JH, van Es RJJ, et al. Early and late complications in the reconstructed mandible with free fibula flaps. *J Surg Oncol.* 2018;117:773–780.
- Hidalgo DA. Fibula free flap: A new method of mandible reconstruction. *Plast Reconstr Surg.* 1989;84:71–79.
- Kademani D, Mardini S, Moran SL. Reconstruction of head and neck defects: A systematic approach to treatment. *Semin Plast Surg.* 2008;22:141–155.
- Valentini V, Califano L, Cassoni A, et al. Maxillo-mandibular reconstruction in pediatric patients: How to do it? *J Craniofac Surg.* 2018;29:761–766.
- Baron S, Salvan D, Cloutier L, et al. Fibula free flap in the treatment of mandibular osteoradionecrosis. *Eur Ann Otorhinolaryngol Head Neck Dis.* 2016;133:7–11.
- Löfstrand J, Nyberg M, Karlsson T, et al. Quality of life after free fibula flap reconstruction of segmental mandibular defects. *J Reconstr Microsurg.* 2018;34:108–120.
- Kokosis G, Schmitz R, Powers DB, et al. Mandibular reconstruction using the free vascularized fibula graft: An overview of different modifications. *Arch Plast Surg.* 2016;43:3–9.
- Brown JS, Lowe D, Kanatas A, et al. Mandibular reconstruction with vascularised bone flaps: A systematic review over 25 years. *Br J Oral Maxillofac Surg.* 2017;55:113–126.
- Taylor GI, Corlett RJ, Ashton MW. The evolution of free vascularized bone transfer: A 40-year experience. *Plast Reconstr Surg.* 2016;137:1292–1305.
- Shindo M, Fong BP, Funk GF, et al. The fibula osteocutaneous flap in head and neck reconstruction: A critical evaluation of donor site morbidity. *Arch Otolaryngol Head Neck Surg.* 2000;126:1467–1472.
- Hoffman GR, Islam S, Eisenberg RL. Microvascular reconstruction of the mouth, face and jaws. Oromandibular reconstruction – free fibula flap. *Aust Dent J.* 2012;57:379–387.
- Lahtinen S, Koivunen P, Ala-Kokko T, et al. Complications and outcome after free flap surgery for cancer of the head and neck. *Br J Oral Maxillofac Surg.* 2018;56:684–691.
- Lodders JN, Schulten EA, de Visscher JG, et al. Complications and risk after mandibular reconstruction with fibular free flaps in patients with oral squamous cell carcinoma: A retrospective cohort study. *J Reconstr Microsurg.* 2016;32:455–463.
- Bilkay U, Tiftkcioglu YO, Temiz G, et al. Free-tissue transfers for reconstruction of oromandibular area in children. *Microsurgery.* 2008;28:91–98.
- Crosby MA, Martin JW, Robb GL, et al. Pediatric mandibular reconstruction using a vascularized fibula flap. *Head Neck.* 2008;30:311–319.
- Guo L, Ferraro NF, Padwa BL, et al. Vascularized fibular graft for pediatric mandibular reconstruction. *Plast Reconstr Surg.* 2008;121:2095–2105.
- Su T, Fernandes R. Microvascular reconstruction of the mandible: An argument for the fibula osteocutaneous free flap. *Revista Española de Cirugía Oral y Maxilofacial* 2012;36:1–8.
- Warren SM, Borud LJ, Brecht LE, et al. Microvascular reconstruction of the pediatric mandible. *Plast Reconstr Surg.* 2007;119:649–661.
- Upton J, Guo L. Pediatric free tissue transfer: A 29-year experience with 433 transfers. *Plast Reconstr Surg.* 2008;121:1725–1737.
- Yazar S, Wei FC, Cheng MH, et al. Safety and reliability of microsurgical free tissue transfers in paediatric head and neck reconstruction – a report of 72 cases. *J Plast Reconstr Aesthet Surg.* 2008;61:767–71.
- Benoit MM, Vargas SO, Bhattacharyya N, et al. The presentation and management of mandibular tumors in the pediatric population. *Laryngoscope.* 2013;123:2035–2042.

24. Elledge R, Parmar S. Free flaps for head and neck cancer in paediatric and neonatal patients. *Curr Opin Otolaryngol Head Neck Surg.* 2018;26:127–133.
25. Chopra S, Enepekides DJ. The role of distraction osteogenesis in mandibular reconstruction. *Curr Opin Otolaryngol Head Neck Surg.* 2007;15:197–201.
26. Bianchi B, Ferri A, Ferrari S, et al. Microvascular reconstruction of mandibular defects in paediatric patients. *J Craniomaxillofac Surg.* 2011;39:289–295.
27. Temiz G, Bilkay U, Tiftikçioğlu YÖ, et al. The evaluation of flap growth and long-term results of pediatric mandible reconstructions using free fibular flaps. *Microsurgery.* 2015;35:253–261.
28. Olvera-Caballero C. Mandibular reconstruction in children. *Microsurgery.* 2000;20:158–161.
29. Santamaría E, Morales C, Taylor JA, et al. Mandibular microsurgical reconstruction in patients with hemifacial microsomia. *Plast Reconstr Surg.* 2008;122:1839–1849.
30. Angle E. Classification of malocclusion. *Dental Cosm.* 1899;41:248–264.
31. Resnick CM, Genuth J, Calabrese CE, et al. Temporomandibular joint ankylosis after ramus construction with free fibula flaps in children with hemifacial microsomia. *J Oral Maxillofac Surg.* 2018;76:2001.e1–2001.e15.
32. Chen CT, Feng CH, Tsay PK, et al. Functional outcomes following surgical treatment of bilateral mandibular condylar fractures. *Int J Oral Maxillofac Surg.* 2011;40:38–44.
33. Seth R, Futran ND, Alam DS, et al. Outcomes of vascularized bone graft reconstruction of the mandible in bisphosphonate-related osteonecrosis of the jaws. *Laryngoscope.* 2010;120:2165–2171.
34. Chiapasco M, Biglioli F, Autelitano L, et al. Clinical outcome of dental implants placed in fibula-free flaps used for the reconstruction of maxillo-mandibular defects following ablation for tumors or osteoradionecrosis. *Clin Oral Implants Res.* 2006;17:220–228.
35. Brinkman JN, Kambiz S, de Jong T, et al. Long-term outcomes after double free flap reconstruction for locally advanced head and neck cancer. *J Reconstr Microsurg.* 2019;35:66–73.
36. Delgado L, Verma A, O TM, et al. Orthognathic considerations of vascular malformations. *Otolaryngol Clin North Am.* 2018;51:225–235.
37. Bertin H, Mercier J, Cohen A, et al. Surgical correction of mandibular hypoplasia in hemifacial microsomia: A retrospective study in 39 patients. *J Craniomaxillofac Surg.* 2017;45:1031–1038.
38. Kaban LB, Moses MH, Mulliken JB. Surgical correction of hemifacial microsomia in the growing child. *Plast Reconstr Surg.* 1988;82:9–19.
39. Garfein E, Doscher M, Tepper O, et al. Reconstruction of the pediatric midface following oncologic resection. *J Reconstr Microsurg.* 2015;31:336–342.