

# Surgical treatment of a chronically fixed lateral patella dislocation in an adolescent patient

Xinning Li,<sup>1</sup> Natalie M. Nielsen,<sup>2</sup>  
Hanbing Zhou,<sup>2</sup> Beth Shubin Stein,<sup>3</sup>  
Yvonne A. Shelton,<sup>2</sup> Brian D. Busconi<sup>2</sup>

<sup>1</sup>Department of Orthopaedic Surgery, Division of Sports Medicine and Shoulder and Elbow Surgery, Boston University School of Medicine, Boston, MA;

<sup>2</sup>Department of Orthopedic Surgery, University of Massachusetts Medical Center, Worcester, MA; <sup>3</sup>Department of Orthopedic Surgery, Division of Sports Medicine, Hospital for Special Surgery, New York, NY, USA

## Abstract

Acute patellar dislocation or subluxation is a common cause for knee injuries in the United States and accounts for 2% to 3% of all injuries. Up to 49% of patients will have recurrent subluxations or dislocations. Importance of both soft tissue (predominantly, the medial patellofemoral ligament, MPFL, which is responsible for 60% of the resistance to lateral dislocation) and bony constraint of femoral trochlea in preventing subluxation and dislocation is well documented. Acute patella dislocation will require closed reduction and management typically consist of conservative or surgical treatment depending on the symptoms and recurrence of instability. Most patients are diagnosed and treated in a timely manner. We present a 15 years old male with a missed traumatic lateral patella dislocation during childhood. The patient presented as an adolescent with a chronically fixed lateral patella dislocation and was managed with surgery. The key steps in the surgical reconstruction of this patient required first mobilizing the patella with a lateral retinacular release and V-Y lengthening of the shortened or contracted quadriceps tendon. Then a combination of MPFL reconstruction using the semitendinosus autograft, tibial tubercle osteotomy with antero-medialization, and lateral facetectomy was performed. At the one-year follow-up, our patient had improved knee range of motion and decrease in pain. Chronically fixed lateral dislocated patella is a rare and complex problem to manage in older patients that will require a thorough work-up and appropriate surgical planning along with reconstruction.

## Introduction

Acute patellar dislocation or subluxation is a common cause for knee injuries in the United States and accounts for 2% to 3% of all injuries.<sup>1</sup> Up to 49% of patients will have recurrent subluxations or dislocations.<sup>2-4</sup> Importance of both soft tissue [predominantly, the medial patellofemoral ligament (MPFL), which is responsible for 60% of the resistance to lateral dislocation] and bony constraint of femoral trochlea in preventing subluxation and dislocation is well documented.<sup>5,6</sup> Reconstruction of the MPFL has been proven clinically to provide functional improvement in patients with recurrent patellar instability without significant increase in Q-angle or tibial tubercle-trochlea groove (TT-TG) distance.<sup>7,8</sup> In the subset of patients with chondral changes (localized to the lateral and inferior patella) and a lateralized tibial tubercle (TT-TG >20 mm), an anteromedial tibial tubercle transfer has been shown to provide good to excellent patellofemoral pain relief as well as treating the instability as it modifies both the Q-angle while unloading the patellofemoral joint stress.<sup>9</sup> Utilizing either a soft tissue and/or bone-based procedure can be successful in the treatment of patients with recurrent patella instability. However, the treatment of older patients with a fixed lateral patella dislocation can be challenging. Most patients are surgically treated in a timely manner with appropriate conservative or surgical management to maximize their overall function. We present a rare case of an adolescent male (15 years old) with a history of traumatic lateral patella dislocation during childhood and required delayed surgical reconstruction. The patient and parents were informed that the data concerning his case would be submitted for publication, and both has provided us with consent.

## Case Report

A 15-year-old active male referred to our orthopedic clinic after an unsuccessful attempt at a closed reduction of a right lateral patellar dislocation in the emergency room. The patient states that he sustained a knee injury by *falling off a fire hydrant*. He also reports a vague history of trauma to this knee during his childhood but with no previous surgical interventions. The patient was seen by a physician in Puerto Rico over ten years ago for this injury, but both he and his parents was not sure of the diagnosis. Further questioning reveals that the patient and his parents always noticed a *bump* on the lateral aspect of his right knee since childhood with limitation of motion and activity. Gait is slightly antalgic and initial examination of this patient's right knee reveals a gross deformity on the

Correspondence: Xinning Li, Hospital for Special Surgery, Department of Orthopedic Surgery, Division of Sports Medicine, New York, NY 10021, USA.

E-mail: xinning.li@gmail.com

Key words: pediatric orthopedics, patella dislocation, Faulkerson procedure, MPFL reconstruction.

Contributions: XL contributed to the conception, drafting, revision, and collection of the patient data and radiographs of this study. NE and HZ contributed to the drafting and revision of this manuscript. BSS, YS and BB contributed to the critical reviewing and editing of this manuscript.

Conflict of interests: the authors declare no potential conflict of interests.

Funding: funding was provided internally by the University of Massachusetts Medical Center - division of Sports Medicine.

Received for publication: 10 March 2013.

Revision received: 29 March 2013.

Accepted for publication: 21 April 2013.

This work is licensed under a Creative Commons Attribution NonCommercial 3.0 License (CC BY-NC 3.0).

©Copyright X. Li et al., 2013  
Licensee PAGEPress, Italy  
Orthopedic Reviews 2013; 5:e9  
doi:10.4081/or.2013.e9

anterolateral aspect of the knee (Figure 1). There was minimal pain with palpation of the patella. Knee range of motion was limited to 15° to 120° with no pain at the extremes of motion and stable to provocative testing. Examination of the contra-lateral knee was normal. An attempt to reduce the patella in clinic was unsuccessful as there was minimal patellar movement with medially directed force. Initial radiographs of the knee (Figure 2) demonstrated a lateral dislocated patella with no fracture or patella alta and no trochlear dysplasia (no crossing sign). Magnetic resonance imaging (MRI) of the right knee confirms the lateral patella dislocation with attenuation of the MPFL, mild joint effusion, and without bone edema (Figure 3). TT-TG distance was 33 mm on computed tomography (CT) scan. Both the conservative and surgical options was discussed with the patient and his family, decision was made to proceed with surgical intervention.

Anterior incision and a medial para-patellar arthrotomy were performed. There was significant lateral displacement of the tibial tubercle with a fixed patella in the lateral gutter. Due to the contracture of the vastus lateralis region, we first proceeded with a lateral retinacular release and V-Y lengthening of quadriceps tendon was needed to fully mobilize the patella for

reduction (Figure 4). The articular surface of the patella was then evaluated and a significant degenerative lateral facet was noted. As a result, we performed a lateral facetectomy of the patella to improve its articulation with the trochlea. Next, a tibial tubercle osteotomy to anteromedialize the tubercle was performed to both centralize and decrease the loading stress on the patella. Semitendinosis autograft was then harvested to reconstruct the MPFL at its isometric point. The graft on the patella was tunneled and sutured onto itself while the femur fixation was performed with a tenodesis screw. At this point, we were able to achieve full extension and 125 degree of flexion. Finally, tibial fasciotomies were performed to prevent compartment syndrome. All wound was closed over a drain and the patient was placed in posterior splint, and he was switched to hinged knee brace at 2 weeks post-op and initiated quadriceps exercises. At 14 weeks post-op, patient had knee flexion to 120 degree and full extension. At 1 year of follow-up, flexion improved to greater than 125 degree with full extension and has returned to normal activities. Radiographs (>1 yr f/u) demonstrate anatomic articulation of the patella on the femoral trochlea groove (Figure 5).

more than 10 years from the original event as an adolescent (15 years old). Both the patient and his parents report noticing a deformity or bump on his knees since the original injury. A physician in Puerto Rico saw him but no treatment was performed. Given the chronicity of the lateral dislocation and the soft tissue contracture, the first step in our operative management was to release the patella from the lateral gutter. Lateral release was performed first, however, the quadriceps tendon was also contracted and the patella was unable to be reduced. Thus, we performed a V-Y lengthening of the quadriceps tendon. Once the patella was mobilized, the next step was to evaluate the articulation with the femoral trochlea. There was no trochlea dysplasia and we were able to achieve stability with a distal realignment and a trochleoplasty was not required. Congenital patella dislocations are typically associated with trochlea dysplasia, thus we believe this particular patient did not have a congenital patella dislocation, but rather an acute patella dislocation secondary to trauma that resulted in a chronically fixed lateral patella in the lateral gutter. The under surface of the patella was inspected and significant

degeneration/malformation was seen at the lateral facet. Thus, we performed a lateral facetectomy to remove the osteophytes and malformation. After the patella was centered on the groove, an anteromedialization of the tibial tubercle was performed to decrease the Q-angle and improve tracking. Given the attenuated proximal tissue, we also reconstructed the MPFL with a semitendinosis autograft to provide a checkrein to lateral patella subluxation. Tensioning of the graft was done after the tubercle osteotomy with the knee in 30 degrees of flexion in order to engage the patella in the trochlea and prevent over tightening of the MPFL. Extreme caution was taken to not over tension the patella as this may result in increased force and early degeneration of the medial patella as well as medial instability.

Indications for MPFL reconstruction include lateral patellar instability and with/without trochlear dysplasia.<sup>7,13</sup> Both autograft and allografts can be used for the reconstruction procedure. The key to the successful outcome in MPFL reconstruction is placement of the graft in an isometric location so the length of the graft does not change with knee range of motion. Immediate passive range of

## Discussion

Recurrent patellar dislocation is a disabling condition most often associated with sporting and physical activities. While the majority of patients are managed non-operatively following first time dislocation, up to 49% of these patients will go on to experience recurrent patellar dislocation or subluxation.<sup>2,3,9</sup> Many predisposing factors to primary and recurrent dislocations have been identified and including patella alta, abnormal patella morphology, lateral patellar displacement, trochlear dysplasia, increased Q angle with lateralized tibial tuberosity, genu valgum, vastus medialis hypoplasia, ligament hyperlaxity, external tibial torsion, subtalar joint pronation, and increased femoral anteversion.<sup>10-12</sup> Traditionally, acute first-time patellar dislocations without associated fractures have been treated with closed reduction and non-operatively with 2-3 weeks of immobilization in a splint, cast or brace. For recurrent instability, surgical management may be indicated depending on patient specific factors, symptoms, limitations to activities and a variety of surgical procedures exist to address both the soft tissue restraint and bone deformity.

In our present case, the patient has a history of traumatic knee injury in his childhood that was likely consistent with an acute patella dislocation. He presented to our clinic with a chronically fixed lateral patella dislocation

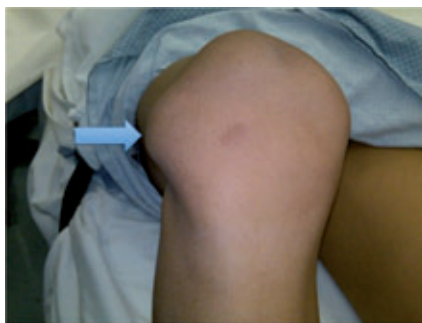

Figure 1. Picture taken of the patient's knee in clinic. Blue arrow points to the dislocated patella and deformity. The patient and parents noted this deformity since childhood.

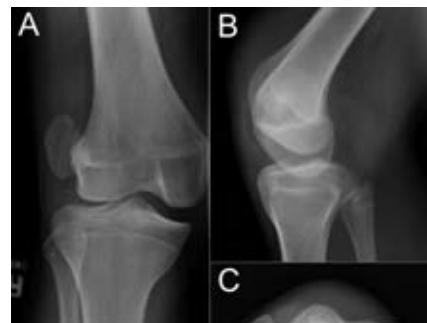

Figure 2. AP (A), lateral (B) and Merchant (C) radiographic views of the patella demonstrates the patella dislocated in the lateral gutter. On the Merchant view (C), femoral trochlea dysplasia is not seen. This was further confirmed intraoperatively.

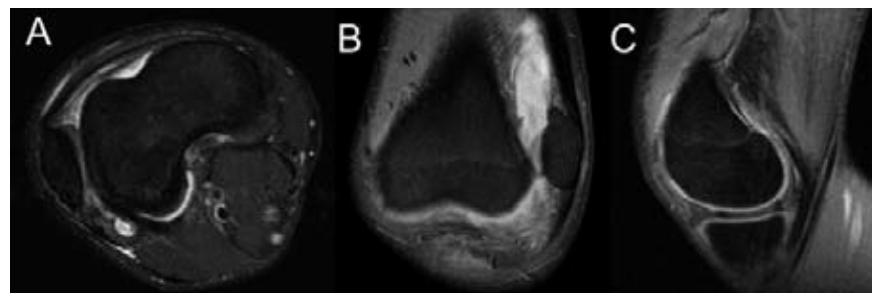
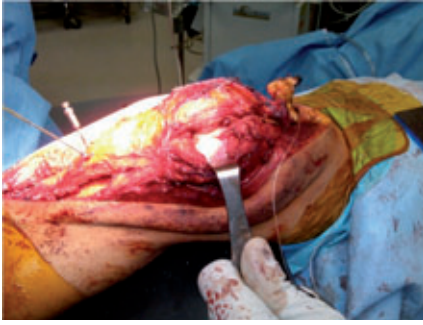
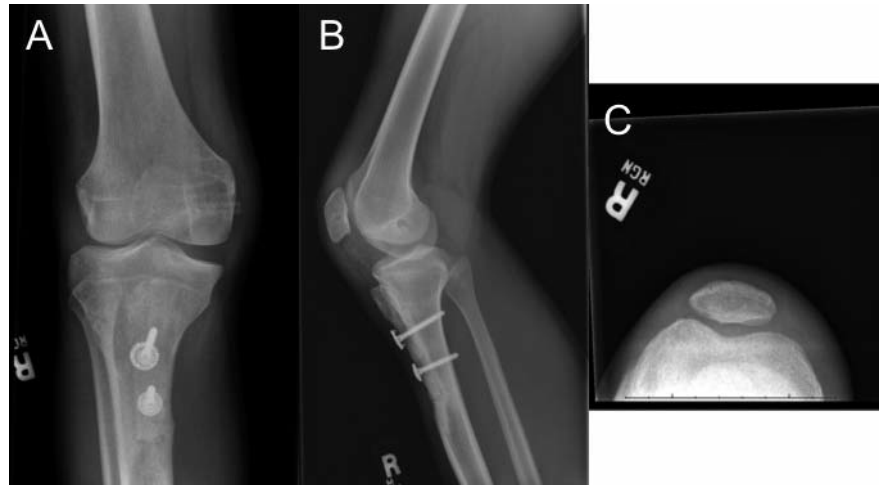
Figure 3. Magnetic resonance images in axial (A), coronal (B) and sagittal (C) views confirms the laterally dislocated patella. Axial cuts (A) indicate the medial patellofemoral ligament is attenuated without rupture and no bone edema is present, which indicate the chronic nature of this pathology.



**Figure 4.** Intra-operative photograph of the V-Y lengthening of the quadriceps tendon and also the distal tibial tubercle realignment. Photograph taken before the medial patellofemoral ligament reconstruction.



**Figure 5.** AP (A), lateral (B), and Merchant (C) radiographic views of the knee at the 1 year follow-up visit. The patella is anatomically located in the trochlea groove with union of the distal tibial tubercle osteotomy site.

motion is started post-operatively to prevent stiffness and patients are allowed to weight-bear as tolerated in a knee immobilizer until knee motion and quadriceps function has returned to normal.<sup>7,14</sup> Long-term follow-up of MPFL reconstruction demonstrates satisfactory results in the majority of patients. Nomura *et al.*<sup>15</sup> evaluated 24 knees from 22 patients after MPFL reconstruction with a mean follow-up of 11.9 years and found 88% of patients had excellent/good outcomes according to the Crosby/Insall criteria. Twelve percent of patients had fair/poor outcomes and no patients were worse at follow-up. Anteromedial tibial tubercle transfer is the procedure of choice for patella instability with a TT-TG distance of >20 mm and patella articular degeneration (lateral and distal facet) caused by mal-alignment. The osteotomy plane is deep to the tibial tubercle, and should be fairly steep to allow for 12-15 mm of anteriorization of the tubercle, which will help unload the patella. Balancing the amount of anteriorization versus medialization can be done by changing the slope of the osteotomy. Fulkerson *et al.*<sup>9</sup> reported 93% excellent/good results subjectively at two-year follow up and 89% excellent/good results objectively using the knee instability scale.

## Conclusions

Surgical management of a chronically fixed lateral patella dislocation in an adolescent patient is extremely rare. Typically these patients are treated with closed reduction at the time of dislocation and subsequent surgery

if the instability persists. However, this patient presented at more than 10 years from the original injury. Given the chronicity of the dislocation and the associated soft tissue contractures, the first step in surgical reconstruction is to first mobilize the patella with a lateral retinacular release and V-Y lengthening of the shortened or contracted quadriceps tendon. Our patient also required a combination of MPFL reconstruction using the semitendinosus autograft, tibial tubercle osteotomy with anterior-medialization, and lateral facetectomy. Late presentation of a fixed laterally dislocated patella is a complex problem that requires a thorough work-up and appropriate surgical planning.

## References

1. Aglietti P, Buzzi R, Install J. Disorders of the patellofemoral joint. Insall J, Scott W, eds. New York, NY: Churchill Livingstone; 2001.
2. Fithian DC, Paxton EW, Stone ML, et al. Epidemiology and natural history of acute patellar dislocation. *Am J Sports Med* 2004;32:1114-21.
3. Hawkins RJ, Bell RH, Anisette G. Acute patellar dislocations. The natural history. *Am J Sports Med* 1986;14:117-20.
4. Macnab I. Recurrent dislocation of the patella. *J Bone Joint Surg Am* 1952;34A: 957-67.
5. Conlan T, Garth WP Jr, Lemons JE. Evaluation of the medial soft-tissue restraints of the extensor mechanism of the knee. *J Bone Joint Surg Am* 1993;75: 682-93.
6. Desio SM, Burks RT, Bachus KN. Soft tissue restraints to lateral patellar translation in the human knee. *Am J Sports Med* 1998;26:59-65.
7. Steiner TM, Torga-Spak R, Teitge RA. Medial patellofemoral ligament reconstruction in patients with lateral patellar instability and trochlear dysplasia. *Am J Sports Med* 2006;34:1254-61.
8. Drez D, Jr., Edwards TB, Williams CS. Results of medial patellofemoral ligament reconstruction in the treatment of patellar dislocation. *Arthroscopy* 2001;17:298-306.
9. Fulkerson JP, Becker GJ, Meaney JA, et al. Anteromedial tibial tubercle transfer without bone graft. *Am J Sports Med* 1990;18:490-7.
10. Stefancin JJ, Parker RD. First-time traumatic patellar dislocation: a systematic review. *Clin Orthop Relat Res* 2007;455:93-101.
11. Arendt EA, Fithian DC, Cohen E. Current concepts of lateral patella dislocation. *Clin Sports Med* 2002;21:499-519.
12. Beasley LS, Vidal AF. Traumatic patellar dislocation in children and adolescents: treatment update and literature review. *Curr Opin Pediatr* 2004;16:29-36.
13. Christiansen SE, Jakobsen BW, Lund B, Lind M. Isolated repair of the medial patellofemoral ligament in primary dislocation of the patella: a prospective randomized study. *Arthroscopy* 2008;24:881-7.
14. Fithian DC, Powers CM, Khan N. Rehabilitation of the knee after medial patellofemoral ligament reconstruction. *Clin Sports Med* 2010;29:283-90.
15. Nomura E, Inoue M, Kobayashi S. Long-term follow-up and knee osteoarthritis change after medial patellofemoral ligament reconstruction for recurrent patellar dislocation. *Am J Sports Med* 2007;35: 1851-8.