




Available online at [www.sciencedirect.com](http://www.sciencedirect.com)

ScienceDirect

journal homepage: [www.elsevier.com/locate/ajur](http://www.elsevier.com/locate/ajur)



## Review

# The role of ureteroscopy for treatment of staghorn calculi: A systematic review

Etienne Xavier Keller <sup>a,b,c,1</sup>, Vincent De Coninck <sup>a,b,d,1</sup>,  
Steeve Doizi <sup>a,b</sup>, Olivier Traxer <sup>a,b,\*</sup>

<sup>a</sup> Sorbonne Université, Service d'Urologie, AP-HP, Hôpital Tenon, F-75020, Paris, France

<sup>b</sup> Sorbonne Université, GRC n°20, Groupe de Recherche Clinique sur la Lithiase Urinaire, Hôpital Tenon, F-75020, Paris, France

<sup>c</sup> Department of Urology, University Hospital Zurich, University of Zurich, Zurich, Switzerland

<sup>d</sup> Department of Urology, AZ Klina, Brasschaat, Belgium

Received 2 June 2019; received in revised form 16 September 2019; accepted 16 October 2019

Available online 5 December 2019

## KEYWORDS

Staghorn calculi;  
Ureteroscopy;  
Percutaneous  
nephrolithotomy;  
Combined approach;  
Intrarenal surgery;  
Simultaneous  
bilateral endoscopic  
surgery

**Abstract** *Objective:* To define the role of ureteroscopy for treatment of staghorn calculi. *Methods:* A systematic review was conducted using the Scopus and Medline databases. Original articles and systematic reviews were selected according to Preferred Reporting Items for Systematic Reviews and Meta-Analyses (PRISMA) guidelines. Only studies relating to the role of ureteroscopy for treatment of staghorn calculi were included.

*Results:* In five studies on ureteroscopic monotherapy, stone-free rate (SFR) ranged from 33% to 93%, with a maximum four ureteroscopy sessions per patient and no major complications. Endoscopic combined intrarenal surgery (ECIRS) was compared with percutaneous nephrolithotomy (PNL) in two studies and reached significantly higher SFR (88%–91% vs. 59%–65%) and lower operative times (84–110 min vs. 105–129 min). The role of salvage ureteroscopy for residual stones after primary PNL has been highlighted by two studies with a final SFR of 83%–89%. One study reported on the feasibility of ureteroscopy for ureteral stones and same-session PNL for contralateral staghorn calculi, with a SFR of 92%.

*Conclusion:* Ureteroscopy plays a pivotal role in the setting of a combined approach to staghorn calculi. Ureteroscopy is also particularly suitable for clearance of residual stones. In specific cases, ureteroscopy may become the sole applicable therapeutic option to staghorn calculi. Technological advances and refinement of techniques suggest a major role of ureteroscopy for staghorn calculi treatment in close future.

© 2020 Editorial Office of Asian Journal of Urology. Production and hosting by Elsevier B.V. This is an open access article under the CC BY-NC-ND license (<http://creativecommons.org/licenses/by-nc-nd/4.0/>).

\* Corresponding author. Sorbonne Université, Service d'Urologie, AP-HP, Hôpital Tenon, F-75020, Paris, France.

E-mail address: [olivier.traxer@aphp.fr](mailto:olivier.traxer@aphp.fr) (O. Traxer).

Peer review under responsibility of Second Military Medical University.

<sup>1</sup> These authors contributed equally.

## 1. Introduction

Staghorn calculi are large branched kidney stones that occupy a large portion of the pyelocaliceal cavities. The exact definition of staghorn calculi in terms of size and shape is a matter of debate, but most authors agree to differentiate “complete” from “partial” staghorn calculi by the extent of involved calices (Fig. 1) [1]. Mostly, staghorn calculi have a mixed stone composition and are related to infection or to a metabolic condition [2,3].

Over the past decades, percutaneous nephrolithotomy (PNL) has been the mainstay of treatment for staghorn calculi [4]. Comparatively, ureteroscopy is considered inferior for staghorn calculi treatment, due to its lower stone clearance rate for such large renal stones [5].

The aim of this study was to define the role of ureteroscopy for treatment of staghorn calculi based on a systematic review of the literature.

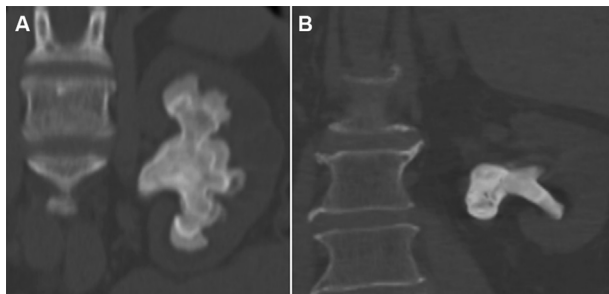
## 2. Methods

A systematic review was conducted using the Scopus and Medline databases, updated to March 2019 with no time period restriction. The search terms (“ureteroscopy” OR “ureterorenoscopy” OR “retrograde intrarenal surgery”) AND (“staghorn calculi” OR “staghorn stone”) were used and the filters “English” and “humans” were applied. Original articles and systematic reviews were selected according to Preferred Reporting Items for Systematic Reviews and Meta-Analyses (PRISMA) guidelines (Fig. 2). Reference lists of selected manuscripts were checked manually for eligible articles. Only studies relating to the role of ureteroscopy for treatment of staghorn calculi were included. Case reports, editorials and letters were excluded. A narrative synthesis for analysis of the studies was used.

## 3. Results

### 3.1. Ureteroscopic monotherapy

Five studies reporting on fully ureteroscopic management of staghorn calculi were found [5–9]. Aso et al. [6] reported on 34 patients operated between 1986 and 1989



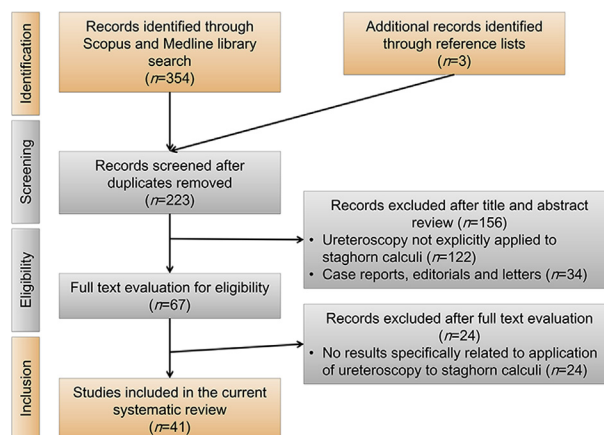
**Figure 1** Staghorn calculi. (A) Complete staghorn calculi occupy the whole pyelocaliceal cavities; (B) Partial staghorn calculi have at least one calyceal branch attached to the renal pelvis.

using flexible ureteroscopy and electrohydraulic lithotripsy. Up to four ureteroscopy sessions with a mean operative time of 99 min per session resulted in a stone-free rate (SFR) of 53% for complete staghorn calculi. In the group of patients with partial staghorn calculi, up to three sessions with a mean 90 min per session yielded a SFR of 47%. Complications such as fever, sepsis, extravasation and subcapsular hematoma occurred in 59% and 26% of all operative session for complete and partial staghorn calculi, respectively [6].

In a case series including a few patients with staghorn calculi, Grasso et al. [7] were able to achieve a 93% SFR within a maximum of three ureteroscopy sessions. One decade later, a series of nine patients with morbid obesity was presented by Wheat et al. [8]. The authors favored multi-stage ureteroscopy sessions over PNL in light of the possible difficulties for percutaneous tract establishment. Mean body mass index was 48 kg/m<sup>2</sup> and patients underwent a mean 2.3 ureteroscopy sessions. The SFR was 33% and mean decrease in stone size was 83%. No complications occurred and the authors concluded that staged ureteroscopy offers a reduction in stone burden with an acceptable patient outcome [8]. A more recent study by Cohen et al. [5] reported on a subgroup of patients undergoing fully ureteroscopic management for staghorn calculi. The SFR was 81% with a maximum of three operative sessions per patient. The latest study was published in 2018 by Scotland et al. [9], with a SFR of 23%, 71% and 82% after 1-stage, 2-stage and 3-stage ureteroscopy for staghorn calculi, respectively.

### 3.2. Combined antegrade and retrograde approach

For many years in the past century, PNL and ureteroscopy had evolved separately rather than synergistically. While the combination of PNL with extracorporeal shockwave lithotripsy had been acknowledged as a way to increase efficacy of staghorn calculi treatment [10–12], the adjunction of ureteroscopy to PNL had only been sparsely described and was reserved for particular clinical situations, including a few cases with staghorn calculi [13–16]. A patient positioning that would satisfy both techniques concomitantly was not further developed for many years and technological refinements to ureteroscopes were still



**Figure 2** Flow chart of the literature search.

to come. It was not until recently that Landman et al. [17] as well as Marguet et al. [18] emphasized the added value of simultaneous ureteroscopy during PNL for staghorn calculi, presenting the retrograde approach as a substitution for an additional percutaneous tract to the kidney [17,18]. Landman et al. [17] and Marguet et al. [18] achieved a SFR of 78% and 71%, respectively, with no major complications using a combined approach with a single percutaneous tract. In the same years, Kidd and Conlin [19] described a series of difficult cases with complex staghorn calculi that were managed by a combined approach. Drilling a path through the stone by Holmium lithotripsy and retrieval of a through-and-through guidewire by ureteroscopy were described as key factors leading to the success of the surgery.

Historically, the combined approach to staghorn calculi had been described with patients placed in a modified prone split-leg position [13–17,19,20]. Alternatively, ureteroscopy had also been performed in a conventional lithotomy position and then followed by prone position for PNL [18]. In 2007, three independent groups of scientists were first in presenting the advantages of a supine position for the combined approach [21–23]. In 2008—after further refinement of patient positioning—Scoffone et al. [24,25] defined the so-called endoscopic combined intrarenal surgery (ECIRS), which refers to combination of PNL in a Galdakao-modified supine Valdivia position with simultaneous retrograde intrarenal surgery (RIRS). Although staghorn calculi were included in these series, no specific SFRs were reported for these patient subgroups. In 2012, Lai et al. [26] reported on 20 patients undergoing a second-stage ECIRS after primary minimally invasive PNL (mini-PNL) and reported on a SFR of 90%. In 2015, Zhong et al. [27] compared ECIRS to conventional PNL in prone position for staghorn calculi and found a significantly higher SFR (91% vs. 65% at 1 month,  $p=0.038$ ), a significantly lower operative time (110 vs. 129 min,  $p<0.001$ ) and a significantly lower hemoglobin drop (2.1 g/L vs. 3.5 g/L,  $p<0.001$ ) in favor of ECIRS. Similarly, in 2016, Wen et al. [28] compared ECIRS with mini-PNL in prone position and found a significantly higher SFR (88% vs. 59%,  $p=0.007$ ) and lower operative time (84 vs. 105 min,  $p=0.002$ ) in favor of ECIRS for patients with partial staghorn calculi.

### 3.3. Salvage ureteroscopy after PNL

Recently, Xu et al. [29] presented a series of patients undergoing staged salvage ureteroscopy after primary single-tract mini-PNL for treatment of patients with a solitary kidney and staghorn calculi. After salvage ureteroscopy, SFR was 83%. The authors justified this strategy in light of the possibly fatal consequences of bleeding complications associated with the number and size of percutaneous access tracts [29]. Similarly, Zeng et al. [30] performed up to two single-tract mini-PNL sessions followed by a salvage ureteroscopy. The SFR after 3 months was 89%.

Ureteroscopy has also been mentioned as a salvage procedure for residual stones in many other studies after primary PNL for staghorn calculi [23,31–40]. Unfortunately, these studies did not provide any preoperative

characteristics or any outcome data specifically relating to these patient subgroups.

### 3.4. Same-session ureteroscopy and contralateral PNL

Although rare, patients may present with a unilateral staghorn calculus and contralateral ureteral stones. If no acute obstructive uropathy is present at the time of diagnosis, these patients may be either offered a staged approach (first retrograde ureteral stone clearance, second PNL of the contralateral staghorn calculus), or a same-session ureteroscopy and contralateral PNL—also referred to as simultaneous bilateral endoscopic surgery (SBES).

The largest consecutive series published to date consists of 52 patients that were treated by semirigid ureteroscopy in supine lithotomy position for ureteral stones and by PNL in prone position for staghorn calculi in a single operative session [41]. The SFR was 92%. The authors compared this series with a group of patients undergoing a staged approach (SFR 94%) and concluded that the simultaneous procedure was equally effective and safe.

### 3.5. Ureteroscopy followed by extracorporeal shock wave lithotripsy

Management of staghorn calculi by primary ureteroscopic lithotripsy followed by one or more sessions of extracorporeal shock wave lithotripsy (ESWL) has been described by few authors [42–44]. These case series comprised eight to 26 patients and SFRs were between 80%–100%, based on plain radiographs with tolerance to residual fragments <4 mm. In the largest and most recent series, Mugjya et al. [44] declared the need for a mean 8.4 ESWL sessions (range 3–26 sessions) until stone-free status was declared. The authors presented the rationale for this strategy, namely the potentially lower renal parenchyma injury compared to a percutaneous approach and the possibility to rule out any ureteral strictures that would impact on spontaneous stone passage after ESWL.

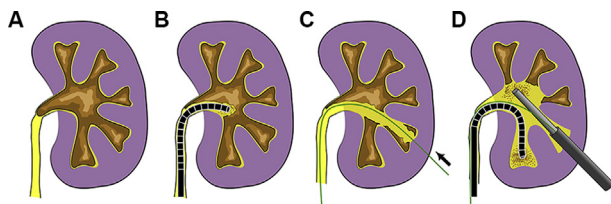
## 4. Discussion

European Association of Urology (EAU) and American Urological Association (AUA) guidelines recommend ureteroscopy only as a secondary choice for stones >2 cm, with PNL recommended as a first-line approach [45,46]. For complete staghorn calculi, EAU guidelines suggest ureteroscopy only as a combined approach together with PNL. AUA guidelines additionally emphasize on the necessity to achieve a stone-free status in patients harboring staghorn calculi, provided that comorbidities do not preclude treatment. The later recommendation is based on numerous literature reports which associate staghorn calculi with risks for renal function deterioration and potentially lethal infectious complications [1].

In agreement with recommendations from EAU and AUA guidelines, the integration of ureteroscopy in a combined antegrade and retrograde approach seems to be particularly advantageous for treatment of staghorn calculi. First,

antegrade placement of a guidewire and tract dilation comes at ease after retrograde stone debulking (Fig. 3) [19]. Second, stone clearance can be performed with the nephroscope and ureteroscope working synergistically. Third, calyces not amenable to the nephroscope may become accessible for the ureteroscope, therefore alleviating the need for an additional percutaneous tract to the kidney [17,18]. Forth, large stone fragments may be displaced with the ureteroscope in a position that will allow rapid clearance over the percutaneous tract, a technique described as the “pass-the-ball” maneuver [47]. Fifth, a final ureteroscopic inspection of the whole upper urinary tract allows eventual residual stone fragments (including those migrated to the ureter) to be cleared at the end of the procedure.

While a prone position had been historically described for the combined approach, more recent patient positioning developments suggest a Galdakao-modified supine Valdivia position in order to facilitate the procedure [24,25]. Table 1 highlights commonly cited risks and limitations of prone or supine approaches (expert opinion). Patient positioning should be tailored according to the



**Figure 3** Combined approach to staghorn calculi. (A) Complete staghorn calculi may preclude antegrade access to the pyelocaliceal cavities; (B) Primary retrograde approach allows for stone debulking by the means of flexible ureteroscopy with laser lithotripsy; (C) Antegrade guidewire insertion becomes possible after sufficient stone debulking. The arrow indicates the typical percutaneous way of insertion of a guidewire; (D) Synergistical use of the antegrade and retrograde approach. Flexible ureteroscopy is used for calyces that would be difficult to access with a nephroscope, alleviating the need for additional percutaneous tract dilations.

clinical situation, experience of the operative room staff and skills of the surgeons.

Ureteroscopy also appears relevant for the management of residual stones after primary PNL for staghorn calculi. As mentioned in the AUA Guidelines, a stone-free status shall be aimed in patients harboring infectious staghorn calculi [1]. Salvage ureteroscopy may therefore be particularly suitable for clearance of residual stones (expert opinion).

In certain special conditions, patients may be poor candidates for PNL and may rely on fully ureteroscopic monotherapy for treatment of staghorn calculi. Such situations may be encountered in face of antiplatelets or anticoagulants therapy, bleeding diathesis, anatomical constraints including morbid obesity, complex comorbid medical conditions or whenever a patient refuses a percutaneous approach. While ureteroscopic monotherapy for staghorn calculi has been described as feasible and safe in past studies [5–9], it is of utmost importance to inform the patient that a multi-stage approach is likely to be necessary.

Other strategies such as primary ureteroscopy and adjuvant ESWL have not been further developed through the 21st century. A possible explanation might have been the refinement of PNL techniques and instruments, together with cumulative evidence supporting PNL as a primary treatment option for staghorn calculi. Of note, simultaneous ESWL during ureteroscopy represents a technically feasible treatment option and may be evaluated for treatment of staghorn calculi in future (expert opinion).

Lately, feasibility of simultaneous bilateral endoscopic surgery (SBES) in a Galdakao-modified supine Valdivia position has been described [48]. Patients with staghorn calculi were excluded from that study. In contrast, Shen et al. [41] applied a SBES-like protocol to patients with ureteral stones and contralateral staghorn calculi. Considering the possible complications of both ureteroscopy (particularly infectious obstructive uropathy) and percutaneous surgery (particularly bleeding and infectious complications), it should be questioned whether this approach is safe in cases with contralateral staghorn calculi. In such cases, it should be advised not to perform the contralateral percutaneous access until the safe course of ureteroscopy has been secured (expert opinion).

**Table 1** Risks and limitations of patient positioning for combined approaches to staghorn calculi (expert opinion).

Topic	Patient position	Risks and limitations
Anesthesia	Prone	Accidental extubation and endotracheal tube kinking, impaired ventilation and circulation, neck, eyeball and peripheral plexus injuries
Puncture	Supine	Restricted area of puncture, greater amplitude of respiratory movements of the kidney (debated), more challenging upper pole calyceal puncture (debated), longer tract length with decreased nephroscope mobility (debated)
Navigation	Supine	Restricted working space, rapid intrarenal pressure loss and collapse of pyelocaliceal cavities (debated, may become an advantage)
Stone extraction	Prone	Lower probability for spontaneous stone evacuation over the percutaneous access sheath (exception: Use of the vacuum cleaner effect)
Ureteroscopy	Prone	Restricted working space, unusual navigation (inverted anatomy), potentially higher risk for stool contamination



Ongoing technological advances may redefine the role of ureteroscopy for staghorn calculi treatment in close future [49]. Of particular interest, the concept of active stone fragment aspiration over an ureteral access sheath has been recently presented as a method allowing faster stone clearance during ureteroscopy [50,51]. Also, cumulative evidence from *in vitro* studies suggests the Thulium fiber laser as a potentially major advancement for ureteroscopic laser-lithotripsy, since it has been shown to overcome the limitations of currently available Holmium:YAG laser generators [52]. Altogether, there is a possibility for ureteroscopy to become routinely integrated in the management of staghorn calculi treatment.

## 5. Conclusion

Ureteroscopy plays a pivotal role in the setting of a combined approach to staghorn calculi. Ureteroscopy is also particularly suitable for clearance of residual stones. In specific cases, ureteroscopy may become the sole applicable therapeutic option to staghorn calculi. Technological advances and refinement of techniques suggest a major role of ureteroscopy for staghorn calculi treatment in close future.

## Author contributions

*Study design:* Etienne Xavier Keller, Olivier Traxer.

*Data acquisition:* Etienne Xavier Keller, Vincent De Coninck.

*Data analysis:* Etienne Xavier Keller, Vincent De Coninck, Steeve Doizi, Olivier Traxer.

*Drafting of the manuscript:* Etienne Xavier Keller, Vincent De Coninck.

*Critical revision of the manuscript:* Etienne Xavier Keller, Vincent De Coninck, Steeve Doizi, Olivier Traxer.

*Supervision:* Olivier Traxer.

## Conflicts of interest

Dr. Etienne Xavier Keller is a consultant for Olympus, Recordati and Debiopharm. Dr. Vincent De Coninck is a consultant for Boston Scientific. Dr. Steeve Doizi is a consultant for Coloplast. Prof. Olivier Traxer is a consultant for Coloplast, Rocamed, Olympus, EMS, Boston Scientific and IPG Medical.

## References

- [1] Preminger GM, Assimos DG, Lingeman JE, Nakada SY, Pearle MS, Wolf Jr JS, et al. Chapter 1: AUA guideline on management of staghorn calculi: diagnosis and treatment recommendations. *J Urol* 2005;173:1991–2000.
- [2] Viprakasit DP, Sawyer MD, Herrell SD, Miller NL. Changing composition of staghorn calculi. *J Urol* 2011;186:2285–90.
- [3] Daudon M, Jungers P. Stone composition and morphology: a window on etiology. In: Talati JJTH, Albala DM, Ye Z, editors. *Urolithiasis: basic science and clinical practice*. London: Springer; 2012. p113–40.
- [4] Al-Kohlany KM, Shokeir AA, Mosbah A, Mohsen T, Shoma AM, Eraky I, et al. Treatment of complete staghorn stones: a prospective randomized comparison of open surgery versus percutaneous nephrolithotomy. *J Urol* 2005;173:469–73.
- [5] Cohen J, Cohen S, Grasso M. Ureteropyeloscopic treatment of large, complex intrarenal and proximal ureteral calculi. *BJU Int* 2013;111:E127–31. <https://doi.org/10.1111/j.1464-410X.2012.11352.x>.
- [6] Aso Y, Ohta N, Nakano M, Ohtawara Y, Tajima A, Kawabe K. Treatment of staghorn calculi by fiberoptic transurethral nephrolithotripsy. *J Urol* 1990;144:17–9.
- [7] Grasso M, Conlin M, Bagley D. Retrograde ureteropyeloscopic treatment of 2 cm or greater upper urinary tract and minor Staghorn calculi. *J Urol* 1998;160:346–51.
- [8] Wheat JC, Roberts WW, Wolf Jr JS. Multi-session retrograde endoscopic lithotripsy of large renal calculi in obese patients. *Can J Urol* 2009;16:4915–20.
- [9] Scotland KB, Rudnick B, Healy KA, Hubosky SG, Bagley DH. Retrograde ureteroscopic management of large renal calculi: a single institutional experience and concise literature review. *J Endourol* 2018;32:603–7.
- [10] Kahnoski RJ, Lingeman JE, Coury TA, Steele RE, Mosbaugh PG. Combined percutaneous and extracorporeal shock wave lithotripsy for staghorn calculi: an alternative to anatomic nephrolithotomy. *J Urol* 1986;135:679–81.
- [11] Segura JW, Patterson DE, LeRoy AJ. Combined percutaneous ultrasonic lithotripsy and extracorporeal shock wave lithotripsy for struvite staghorn calculi. *World J Urol* 1987;5:245–7.
- [12] Meretyk S, Gofrit ON, Gafni O, Pode D, Shapiro A, Verstandig A, et al. Complete staghorn calculi: random prospective comparison between extracorporeal shock wave lithotripsy monotherapy and combined with percutaneous nephrostolithotomy. *J Urol* 1997;157:780–6.
- [13] Lehman T, Bagley DH. Reverse lithotomy: modified prone position for simultaneous nephroscopic and ureteroscopic procedures in women. *Urology* 1988;32:529–31.
- [14] Grasso M, Nord R, Bagley DH. Prone split leg and flank roll positioning: simultaneous antegrade and retrograde access to the upper urinary tract. *J Endourol* 1993;7:307–10.
- [15] Grasso M, Lang G, Taylor FC. Flexible ureteroscopically assisted percutaneous renal access. *Tech Urol* 1995;1:39–43.
- [16] Grasso M, Lang G, Loisesides P, Bagley D, Taylor F. Endoscopic management of the symptomatic caliceal diverticular calculus. *J Urol* 1995;153:1878–81.
- [17] Landman J, Venkatesh R, Lee DI, Rehman J, Ragab M, Darcy M, et al. Combined percutaneous and retrograde approach to staghorn calculi with application of the ureteral access sheath to facilitate percutaneous nephrolithotomy. *J Urol* 2003;169:64–7.
- [18] Marguet CG, Springhart WP, Tan YH, Patel A, Undre S, Albala DM, et al. Simultaneous combined use of flexible ureteroscopy and percutaneous nephrolithotomy to reduce the number of access tracts in the management of complex renal calculi. *BJU Int* 2005;96:1097–100.
- [19] Kidd CF, Conlin MJ. Ureteroscopically assisted percutaneousrenal access. *Urology* 2003;61:1244–5.
- [20] Hamamoto S, Yasui T, Okada A, Koiwa S, Taguchi K, Itoh Y, et al. Efficacy of endoscopic combined intrarenal surgery in the prone split-leg position for staghorn calculi. *J Endourol* 2015;29:19–24.
- [21] Ibarluzea G, Scoffone CM, Cracco CM, Poggio M, Porpiglia F, Terrone C, et al. Supine Valdivia and modified lithotomy position for simultaneous anterograde and retrograde endourological access. *BJU Int* 2007;100:233–6.

- [22] Neto EAC, Mitre AI, Gomes CM, Arap MA, Srougi M. Percutaneous nephrolithotripsy with the patient in a modified supine position. *J Urol* 2007;178:165–8.
- [23] Manohar T, Jain P, Desai M. Supine percutaneous nephrolithotomy: effective approach to high-risk and morbidly obese patients. *J Endourol* 2007;21:44–9.
- [24] Scoffone CM, Cracco CM, Cossu M, Grande S, Poggio M, Scarpa RM. Endoscopic combined intrarenal surgery in Galdakao-modified supine Valdivia position: a new standard for percutaneous nephrolithotomy? *Eur Urol* 2008;54:1393–403.
- [25] Scoffone CM, Cracco CM. Invited review: the tale of ECIRS (Endoscopic Combined IntraRenal Surgery) in the Galdakao-modified supine Valdivia position. *Urolithiasis* 2018;46:115–23.
- [26] Lai D, He Y, Dai Y, Li X. Combined minimally invasive percutaneous nephrolithotomy and retrograde intrarenal surgery for staghorn calculi in patients with solitary kidney. *PLoS One* 2012;7:e48435. <https://journals.plos.org/plosone/article?id=10.1371/journal.pone.0048435>.
- [27] Zhong W, Zhao Z, Wang L, Swami S, Zeng G. Percutaneous-based management of Staghorn calculi in solitary kidney: combined mini percutaneous nephrolithotomy versus retrograde intrarenal surgery. *Urol Int* 2015;94:70–3.
- [28] Wen J, Xu G, Du C, Wang B. Minimally invasive percutaneous nephrolithotomy versus endoscopic combined intrarenal surgery with flexible ureteroscope for partial staghorn calculi: a randomised controlled trial. *Int J Surg* 2016;28:22–7.
- [29] Xu G, Li X, He Y, He Z. Staged single-tract minimally invasive percutaneous nephrolithotomy and flexible ureteroscopy in the treatment of staghorn stone in patients with solitary kidney. *Urol Res* 2012;40:745–9.
- [30] Zeng G, Zhao Z, Wu W, Zhong W. Combination of debulking single-tract percutaneous nephrolithotomy followed by retrograde intrarenal surgery for staghorn stones in solitary kidneys. *Scand J Urol* 2014;48:295–300.
- [31] Jones DJ, Kellett MJ, Wickham JE. Percutaneous nephrolithotomy and the solitary kidney. *J Urol* 1991;145:477–9. discussion 9–80.
- [32] Wong MY. Evolving technique of percutaneous nephrolithotomy in a developing country: Singapore General Hospital experience. *J Endourol* 1998;12:397–401.
- [33] Nguyen HD, Tan YH, Wong MY. Percutaneous nephrolithotomy in the management of complex upper urinary tract calculi: the Singapore General Hospital experience. *Ann Acad Med Singapore* 2002;31:516–9.
- [34] Shokeir AA, El-Nahas AR, Shoma AM, Eraky I, El-Kenawy M, Mokhtar A, et al. Percutaneous nephrolithotomy in treatment of large stones within horseshoe kidneys. *Urology* 2004;64:426–9.
- [35] Symons S, Biyani CS, Bhargava S, Irvine HC, Ellingham J, Cartledge J, et al. Challenge of percutaneous nephrolithotomy in patients with spinal neuropathy. *Int J Urol* 2006;13:874–9.
- [36] Liatsikos EN, Kallidonis P, Stolzenburg JU, Ost M, Keeley F, Traxer O, et al. Percutaneous management of staghorn calculi in horseshoe kidneys: a multi-institutional experience. *J Endourol* 2010;24:531–6.
- [37] El-Nahas AR, Eraky I, Shokeir AA, Shoma AM, El-Assmy AM, El-Tabey NA, et al. Percutaneous nephrolithotomy for treating staghorn stones: 10 years of experience of a tertiary-care centre. *Arab J Urol* 2012;10:324–9.
- [38] Yan S, Xiang F, Yongsheng S. Percutaneous nephrolithotomy guided solely by ultrasonography: a 5-year study of >700 cases. *BJU Int* 2013;112:965–71.
- [39] Chen L, Sha ML, Li D, Zhuo J, Jiang CY, Zhu YP, et al. Treatment for residual stones using flexible ureteroscopy and holmium laser lithotripsy after the management of complex calculi with single-tract percutaneous nephrolithotomy. *Lasers Med Sci* 2017;32:649–54.
- [40] Kaya E, Ebioglu T, Zor M, Yalcin S, Coguplugil AE, Bedir S. The outcome of percutaneous nephrolithotomy on  $\geq 50$  mm staghorn and multiple calyceal stones. *Turk J Urol* 2018;44:148–52.
- [41] Shen PF, Liu N, Wei WR, Xu P, Li S, Luo YH, et al. Simultaneous ureteroscopic lithotripsy and contralateral percutaneous nephrolithotomy for ureteral calculi combined with renal staghorn calculi. *Int J Urol* 2015;22:943–8.
- [42] Marini F, Martino F, Alfano V, Valente R. Combined therapy of staghorn calculi with ureteronephroscopy (URS) and extracorporeal shock wave lithotripsy (ESWL). *Arch Esp Urol* 1989;42:945–7.
- [43] Dretler SP. Ureteroscopic fragmentation followed by extracorporeal shock wave lithotripsy: a treatment alternative for selected large or staghorn calculi. *J Urol* 1994;151:842–6.
- [44] Mugiya S, Suzuki K, Ushiyama T, Fujita K. Combined treatment of staghorn calculi by fiberoptic transurethral nephrolithotripsy and extracorporeal shock wave lithotripsy. *Int J Urol* 1998;5:129–33.
- [45] Turk C, Skolarikos A, Neisius A, Petrik A, Seitz C, Thomas K. EAU guidelines on urolithiasis, last update March 2019. Available at: <https://uroweb.org/guideline/urolithiasis>. [Accessed 18 March 2019].
- [46] Assimos D, Krambeck A, Miller NL, Monga M, Murad MH, Nelson CP, et al. Surgical management of stones: American Urological Association/Endourological Society guideline, PART II. *J Urol* 2016;196:1161–9.
- [47] Undre S, Olsen S, Mustafa N, Patel A. “Pass the ball!” Simultaneous flexible nephroscopy and retrograde intrarenal surgery for large residual upper-pole staghorn stone. *J Endourol* 2004;18:844–7.
- [48] Giusti G, Proietti S, Rodriguez-Socarras ME, Eisner BH, Saitta G, Mantica G, et al. Simultaneous Bilateral Endoscopic Surgery (SBES) for patients with bilateral upper tract urolithiasis: technique and outcomes. *Eur Urol* 2018;74:810–5.
- [49] Keller EX, De Coninck V, Traxer O. Next-generation fiberoptic and digital ureteroscopes. *Urol Clin North Am* 2019;46:147–63.
- [50] Deng X, Song L, Xie D, Fan D, Zhu L, Yao L, et al. A novel flexible ureteroscopy with intelligent control of renal pelvic pressure: an initial experience of 93 cases. *J Endourol* 2016;30:1067–72.
- [51] Huang J, Xie D, Xiong R, Deng X, Huang C, Fan D, et al. The application of suctioning flexible ureteroscopy with intelligent pressure control in treating upper urinary tract calculi on patients with a solitary kidney. *Urology* 2018;111:44–7.
- [52] Traxer O, Keller EX. Thulium fiber laser: the new player for kidney stone treatment? A comparison with Holmium:YAG laser. *World J Urol* 2019. <https://doi.org/10.1007/s00345-019-02654-5>.