

Traumatic Pseudoaneurysm of the Distal Anterior Cerebral Artery Following Penetrating Brain Injury Caused by a Crossbow Bolt: A Case Report

Daiichiro Ishigami,¹ and Takahiro Ota¹

Traumatic intracranial aneurysms are one possible complication after penetrating brain injury. A 25-year-old man with a history of major depression presented with a crossbow bolt penetrating the head. On arrival, Glasgow Coma Scale score was E4V5M6, with no apparent neurological deficit. Computed tomography (CT) of the head showed the crossbow bolt passing near the corpus callosum, with surrounding contusion. Three-dimensional rotational angiography showed no anterior cerebral artery injuries. The crossbow bolt was removed after bifrontal craniotomy, with no postoperative infection. Postoperative CT angiography (CTA) was repeatedly performed, and a 4 mm aneurysm was observed at the pericallosal artery-right posterior internal frontal artery (PIFA) bifurcation on postoperative day (POD) 35. Trapping and the right PIFA-left cortical branch side-to-side bypass were performed on POD38. A resected specimen confirmed a pathological diagnosis of pseudoaneurysm. The patient did not show any neurological deficit or cognitive dysfunction as of 8 months after admission. Traumatic anterior cerebral artery aneurysm might have formed due to proximity to the falx cerebri. As pseudoaneurysm was detected 4 weeks after trauma in our patient, follow-up CTA or digital subtraction angiography should be performed until at least 4 weeks after injury. In addition, neck clipping is occasionally unfeasible to treat traumatic pseudoaneurysm surgically, and a surgical strategy including bypass revascularization must be planned.

Keywords: penetrating brain injury, anterior cerebral artery, pseudoaneurysm, crossbow, bypass

Introduction

Penetrating brain injury (PBI) is relatively rare in Japan. While more than 30 cases of PBI have been reported in Japan, with causes including nail-gun, chopsticks, umbrella, and tree branches, PBI caused by crossbows has not been reported.

On the other hand, traumatic intracranial aneurysm (TICA) is a rare complication of brain injury, representing less than

1% of all intracranial aneurysms. Globally, 15 case reports of PBI by crossbow bolts have been published, of which only one involved delayed formation of TICA.

We describe herein a case of PBI caused by a crossbow bolt in which pseudoaneurysm appeared late in the distal anterior cerebral artery (ACA) and was successfully treated surgically.

Case Report

The patient was a 25-year-old man who was taking antidepressants for major depression. He discharged a crossbow into his head in a suicide attempt, and was witnessed walking outdoors 5 hrs after the attempt. On presentation, level of consciousness was E4V5M6 according to the Glasgow Coma Scale, and no significant neurological deficits were apparent.

The crossbow bolt had penetrated the head from the right pterion to the left temporal region (Figs. 1A and 1B), with the fletchings buried in the entry site. After cutting off the tip of the crossbow bolt, computed tomography (CT) of the head was performed. The crossbow bolt had passed nearby the corpus callosum, and 3D rotational angiography revealed that the bolt had barely missed the pericallosal artery (Figs. 1C and 1D). After administration of cefazolin, the patient was promptly taken to the operation room for removal of the crossbow bolt.

A bicoronal skin incision with borders including the entry and exit sites of the bolt was created. Prior to the craniotomy, the fletchings buried in the skin were removed. After bifrontal craniotomy, the crossbow bolt was extracted from the exit site while confirming on intraoperative ultrasonography that hematoma adjacent to the tract was not increasing. The bone flap was discarded because of the risk of contamination. The operative field was copiously irrigated, and a subdural intracranial pressure sensor was inserted to detect delayed expansion of the hematoma.

No postoperative expansion of the hematoma was identified. The patient did not show any paralysis, paresthesia, or cognitive dysfunction. Cefazolin was administered for 1 week postoperatively, and no infection occurred. Follow-up CT/CT angiography (CTA) of the head was performed on postoperative day (POD) 1, 8 (Figs. 2A and 2B), and 15. The hematoma gradually disappeared, but the irregularity of the vascular wall was observed at the bifurcation of the pericallosal artery and right posterior internal frontal artery (PIFA). No change in size from POD1 to 15 was identified, but head CTA performed on POD35 showed a 4 mm aneurysm at the bifurcation (Fig. 2C). Catheter angiography showed contrast

¹Department of Neurosurgery, Tokyo Metropolitan Tama Medical Center, Fuchu, Tokyo, Japan

Received: April 6, 2017; Accepted: June 15, 2017
Online November 24, 2017

Copyright© 2018 by The Japan Neurosurgical Society
This work is licensed under a Creative Commons Attribution-NonCommercial-NoDerivatives International License.

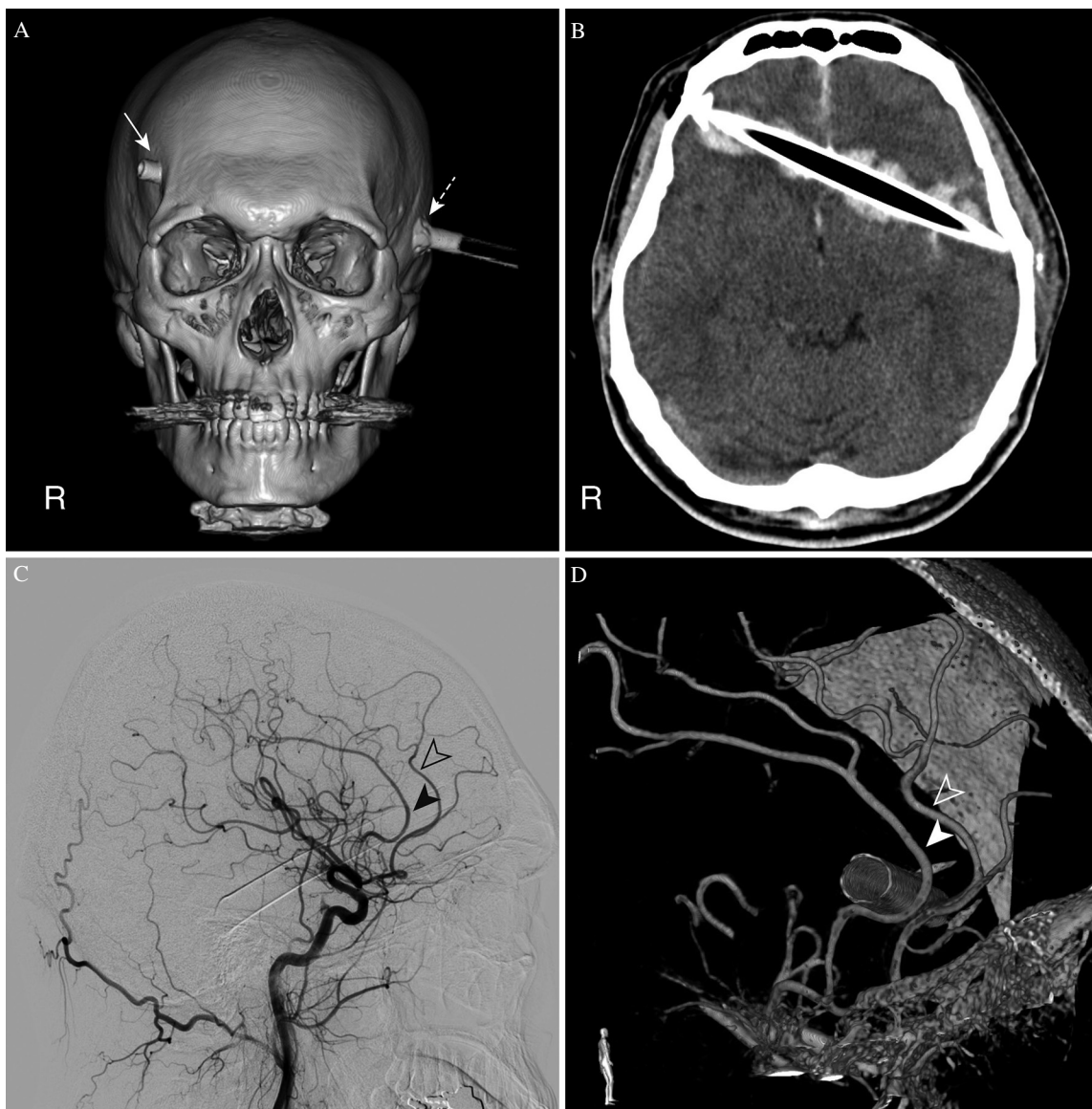


Fig. 1 Preoperative neuroimaging. (A) 3D bone CT reveals the entry (arrow) and exit (dashed arrow) sites of the crossbow bolt. (B) CT imaging demonstrates the crossbow bolt passing nearby the corpus callosum with surrounding contusion. (C, D) Conventional angiography (C) and 3D rotational angiography (D) of the right common carotid artery show the positional relationship between the crossbow bolt and the anterior cerebral arteries (arrowhead: pericallosal artery; blank arrowhead: cortical branches).

medium pooling in the aneurysm, indicating pseudoaneurysm formation (Fig. 2D). Trapping of the pseudoaneurysm and right PIFA-left cortical branch side-to-side bypass surgery was performed on POD38.

We observed the right PIFA via a right interhemispheric approach. After right PIFA-left cortical branch bypass, the aneurysm was trapped and resected (Figs. 3A and 3C). Elastica van Gieson staining of the specimen revealed a lack of internal elastic lamina, confirming the diagnosis of pseudoaneurysm (Fig. 3D).

Postoperative angiography showed anterograde flow through the right PIFA-left cortical branch bypass (Fig. 3B), and N-isopropyl-p-[¹²³I] iodoamphetamine single-photon emission CT showed no reduction of flow in the right medial

frontal lobe. Diffusion-weighted imaging showed no infarction in the right medial frontal lobe, and parenchymal damage was limited to the path of the crossbow bolt in a fluid-attenuated inversion recovery imaging (Figs. 4A and 4B).

Nineteen days after surgery, the patient was transferred to a rehabilitation facility. Cranioplasty was performed 3 months after the initial decompressive craniectomy. Eight months after injury, no neurological deficit or cognitive dysfunction has been identified.

Discussion

Compared to firearm projectiles, an aluminum crossbow bolt with a conical head has a relatively low velocity (up to 58 m/s), but the sharpness and kinetic energy are still sufficient

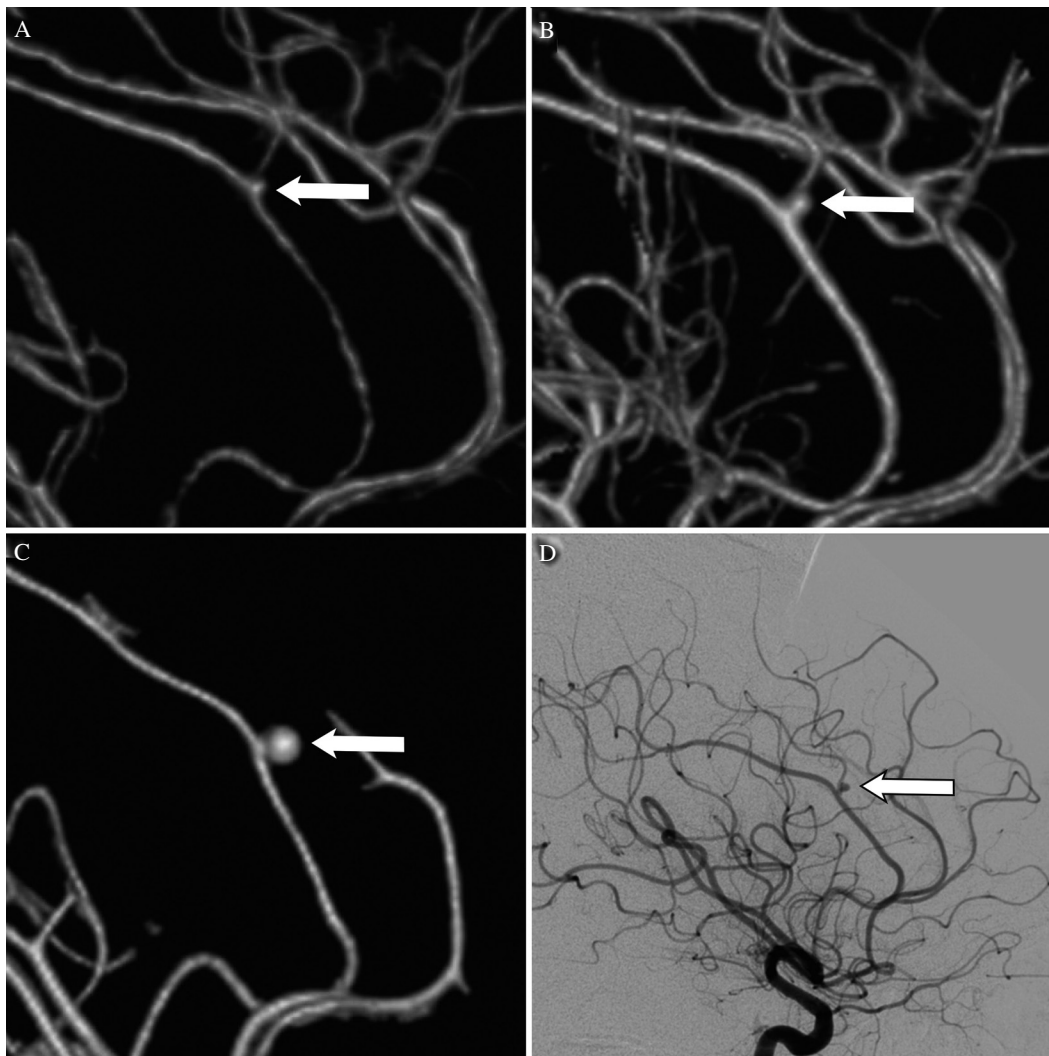


Fig. 2 CT angiography performed on postoperative day (POD) 1 (A), 8 (B), and 35 (C), and digital subtraction angiography performed prior to the bypass surgery (D) (arrow: vascular wall irregularity and pseudoaneurysm at the bifurcation of the pericallosal artery and right posterior internal frontal artery).

to cause penetrating skull injuries. The major risk is that of direct injury to the cerebral parenchyma, and vascular injury is sometimes revealed on removal of the foreign body.¹⁾

The mechanism of penetration for an arrow or bolt is distinct from that of a bullet. Because of the sharp force applied by the bolt, injury is limited to tissues directly in the path of the arrowhead.²⁾ The shaft of the bolt in situ can exert pressure on the wound, functioning as an incomplete tamponade, because the tip of a sports arrow is basically the same diameter as the shaft.³⁾ In our patient, intraparenchymal hematoma was therefore limited to the path of the crossbow bolt.

As shown on 3D rotational angiography (3DRA) (Fig. 1D), the crossbow bolt and origin of the PIFA were separate from each other. A small prominence is recognizable at the origin of the PIFA on 3DRA, indicating that the prominence was formed by forceful stretching of the falx cerebri. We speculate that this traumatic aneurysm appeared as a result of indirect mechanical injury, which has occasionally been reported in the past.⁴⁻⁶⁾

Current surgical management of PBI clearly tends toward minimizing the degree of debridement. No controlled studies have evaluated the relative efficacy of various degrees of debridement in preventing infection and minimizing the development of seizure disorders. Gonul et al.⁷⁾ retrospectively reviewed 148 patients whose penetrating brain injuries were locally debrided and the dura tightly closed without attempts to remove deeper fragments of bone or metal. They reported a discharge mortality rate of 8% and an infection or craniectomy) to minimize complications remains uncertain. Generally recommended procedures are as follows: debridement of necrotic brain tissue; removal of accessible bone or foreign body fragments, only when the neurological risk is not increased; removal of intracranial hematomas exerting significant mass effects; and watertight closure of dural defects.⁷⁾

In our case, the tip of the crossbow bolt was cut off and the shape of the cross-section was irregular and sharp. For this reason, the crossbow bolt was extracted from entrance

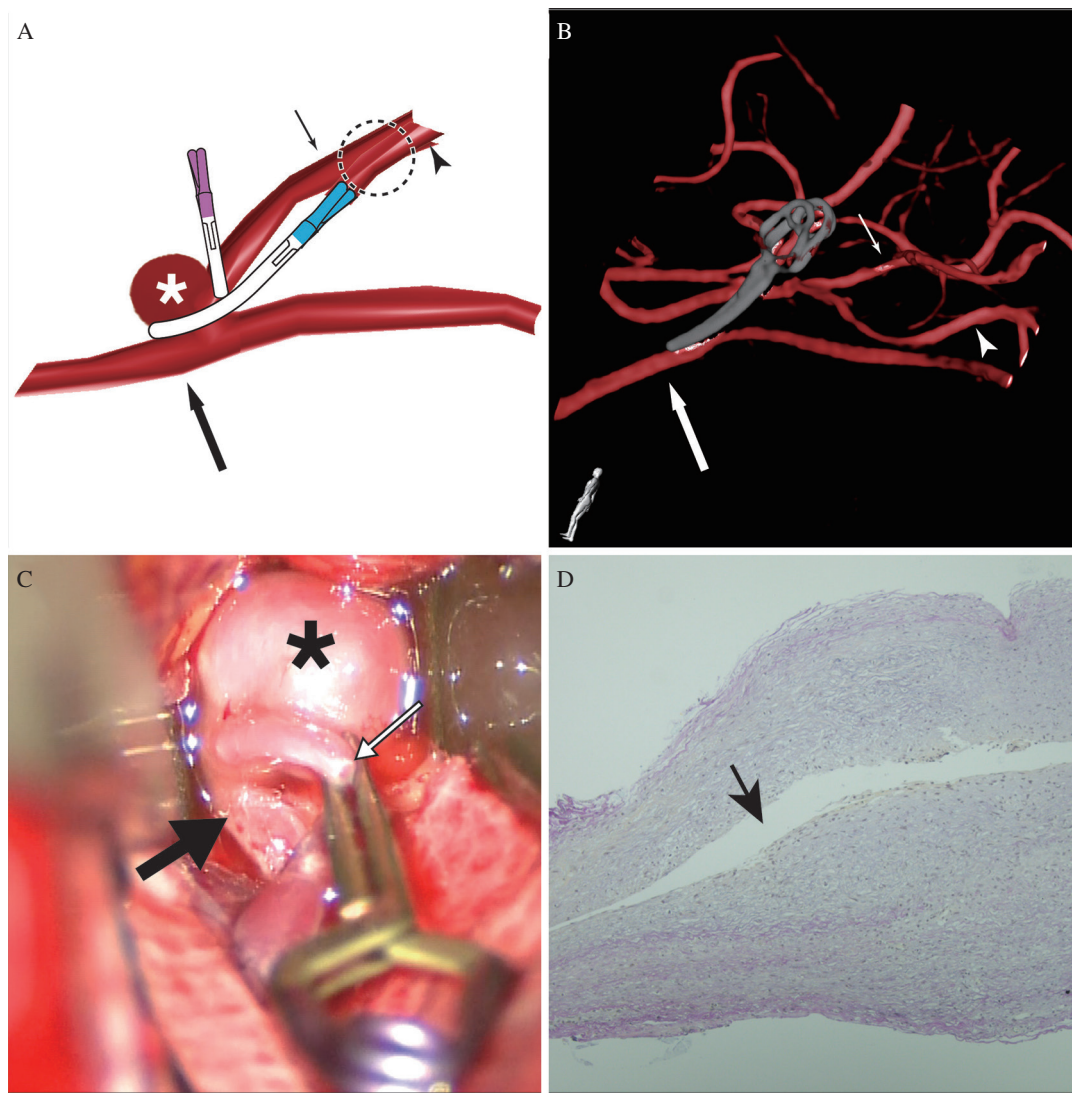


Fig. 3 (A, B) Illustration demonstrating trapping with the right posterior internal frontal artery (PIFA)-left cortical branch side-to-side bypass and postoperative three-dimensional rotational angiography (3DRA) of the right internal carotid artery (asterisk: aneurysm; arrow: pericallosal artery; small arrow: right PIFA; arrowhead: left cortical branch). Successful revascularization with the bypass is seen on 3DRA. (C) Intraoperative view of the pericallosal artery (arrow), PIFA (small arrow) and pseudoaneurysm (asterisk). (D) Elastica van Gieson stain of the resected specimen (magnification, 40×) shows no internal elastic lamina (arrow: aneurysm lumen).

to exit, so that the cross-section did not come into contact with brain tissue. Also, since the crossbow bolt had passed near the ACA, intraoperative ultrasonography was useful in confirming the absence of active bleeding at the time of removal.

Head CT remains the most valuable imaging modality for initial evaluation of foreign objects and assessing the extent of injury, but may be of limited use in evaluating plastic or wood foreign objects. When there is a high index of suspicion for vascular injury, CTA at the very least, and preferably digital subtraction angiography (DSA), may be necessary before surgery for operative planning. In our case, 3DRA perspicuously showed the spatial relationship between the crossbow bolt and ACAs.

The rate of vascular complications after PBI reportedly ranges from 5 to 40%.⁸⁻¹⁰ TICA may present in a delayed

fashion, with a mean presentation typically within 2–3 weeks after injury, but potentially months after injury.¹¹ The most common vascular injury after PBI is development of pseudoaneurysm in peripheral vessels.^{9,12,13} TICA associated with PBI warrants aggressive management to prevent life-threatening complications, as the mortality rate from untreated TICA is reportedly as high as 50%.^{12,13} The present case showed no increase in aneurysm size during the first 2 weeks after PBI, but obvious changes were observed after a month. Follow-up CTA or DSA should therefore be performed until at least 4 weeks after injury.

TICA typically involves the vessels of the anterior circulation, the supraclinoid internal carotid artery, ACA, distal middle cerebral artery and middle meningeal artery.^{14,15} The prevalence of these aneurysms in the ACA is explained by the proximity of the falx to the arteries. Movement induced

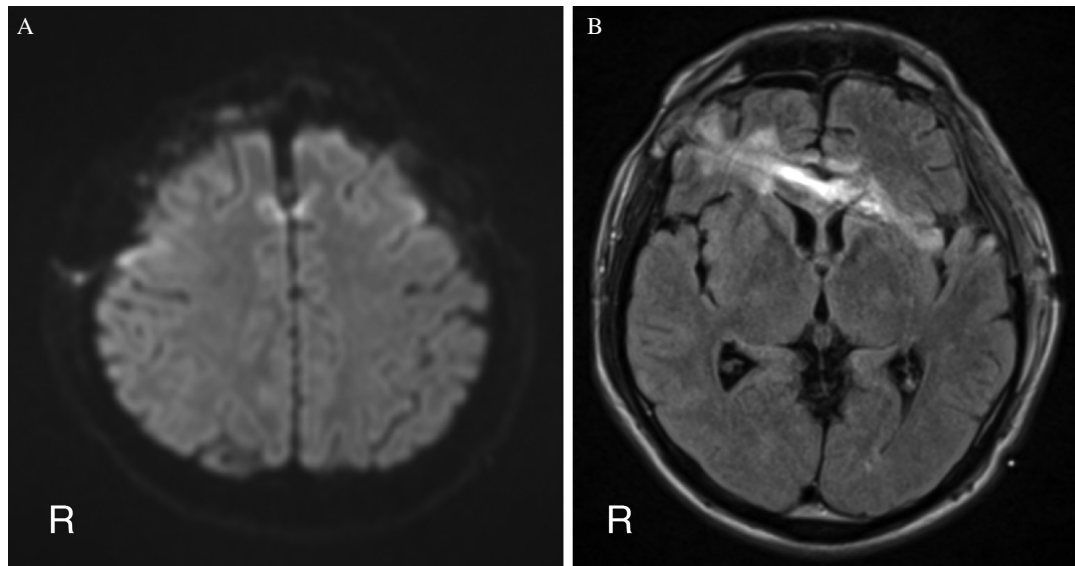


Fig. 4 (A) Postoperative diffusion-weighted imaging shows no infarction in the right medial frontal lobe. (B) Postoperative magnetic resonance imaging (fluid-attenuated inversion recovery): parenchymal damage was limited to the path of the crossbow bolt.

by the injury can lead to stretching and shear injury of the vessel, with damage to the wall and aneurysm formation.^{14,16}

If the TICA bleeds or increases in size, surgical intervention is required. As the lesions are invariably pseudoaneurysms without true vascular layers, simple coil embolization of the outpouched sac may in fact precipitate hemorrhage. Similarly, clip ligation of the sac is inadequate. In many cases, the parent vessel may need to be sacrificed.^{13,17} According to a review by Larson et al.,⁴ 15 of 37 aneurysms (40%) were located in the ACA and its branches, most often in the pericallosal artery. Management options described in that report for ACA aneurysms varied from observation, invariably associated with poor outcomes (including death), to clipping and surgical excision, with endovascular coiling present later in the series. Kumar et al.⁶ reviewed the literature for traumatic ACA aneurysm, and dominance of the open surgical approach in early series and the recent increase and predominance of endovascular options can be clearly seen.

As the lesion was located in the peripheral vasculature, a balloon occlusion test could not be performed. The collateral circulation from the posterior cerebral arteries was therefore unable to be assessed. Considering the possibility of poor collateral flow, we decided to perform revascularization of the PIFA.

The present case required sacrifice of the PIFA, and good results were obtained with trapping and right PIFA-left cortical branch bypass. In the treatment of distal ACA traumatic pseudoaneurysm, trapping and right ACA-left ACA side-to-side bypass seems to represent a useful treatment option.

Conclusion

We encountered a case of pseudoaneurysm formation in the ACA after PBI caused by a crossbow bolt. Use of 3DRA proved helpful in confirming positional relationships between

the bolt and the ACA. Continued follow-up with CTA or DSA for at least 4 weeks is recommended.

Conflicts of Interest Disclosure

The authors report no conflicts of interest (COI) concerning the materials or methods used in this study or the findings specified in this paper. All authors who are members of The Japan Neurosurgical Society (JNS) have registered online Self-reported COI Disclosure Statement Forms through the website for JNS members.

References

- 1) Byard RW, Koszyca B, James R: Crossbow suicide: mechanisms of injury and neuropathologic findings. *Am J Forensic Med Pathol* 20: 347–353, 1999
- 2) Karger B, Sudhues H, Kneubuehl BP, Brinkmann B: Experimental arrow wounds: ballistics and traumatology. *J Trauma* 45: 495–501, 1998
- 3) de Jongh K, Dohmen D, Salgado R, et al.: “William Tell” injury: MDCT of an arrow through the head. *AJR Am J Roentgenol* 182: 1551–1553, 2004
- 4) Larson PS, Reisner A, Morassutti DJ, Abdulhadi B, Harpring JE: Traumatic intracranial aneurysms. *Neurosurg Focus* 8: e4, 2000
- 5) Jung SH, Kim SH, Kim TS, Joo SP: Surgical treatment of traumatic intracranial aneurysms: experiences at a single center over 30 years. *World Neurosurg* 2016
- 6) Kumar A, Jakubovic R, Yang V, Dacosta L: Traumatic anterior cerebral artery aneurysms and management options in the endovascular era. *J Clin Neurosci* 25: 90–95, 2016
- 7) Gönül E, Baysefer A, Kahraman S, et al.: Causes of infections and management results in penetrating craniocerebral injuries. *Neurosurg Rev* 20: 177–181, 1997
- 8) Gutiérrez-González R, Boto GR, Rivero-Garvía M, Pérez-Zamarrón A, Gómez G: Penetrating brain injury by drill bit. *Clin Neurol Neurosurg* 110: 207–210, 2008
- 9) Kazim SF, Shamim MS, Tahir MZ, Enam SA, Waheed S: Management of penetrating brain injury. *J Emerg Trauma Shock* 4: 395–402, 2011
- 10) Williams JR, Aghion DM, Doberstein CE, Cosgrove GR, Asaad WF: Penetrating brain injury after suicide attempt with speargun: case study and review of literature. *Front Neurol* 5: 113, 2014
- 11) Luo W, Liu H, Hao S, Zhang Y, Li J, Liu B: Penetrating brain injury caused by nail guns: two case reports and a review of the literature. *Brain Inj* 26: 1756–1762, 2012

- 12) Cohen JE, Gomori JM, Segal R, et al.: Results of endovascular treatment of traumatic intracranial aneurysms. *Neurosurgery* 63: 476–485; discussion 485–486, 2008
- 13) Sweeney JM, Lebovitz JJ, Eller JL, Coppens JR, Bucholz RD, Abdulrauf SI: Management of nonmissile penetrating brain injuries: a description of three cases and review of the literature. *Skull Base Rep* 1: 39–46, 2011
- 14) Dubey A, Sung WS, Chen YY, et al.: Traumatic intracranial aneurysm: a brief review. *J Clin Neurosci* 15: 609–612, 2008
- 15) Miley JT, Rodriguez GJ, Qureshi AI: Traumatic intracranial aneurysm formation following closed head injury. *J Vasc Interv Neurol* 1: 79–82, 2008
- 16) Yang TC, Lo YL, Huang YC, Yang ST: Traumatic anterior cerebral artery aneurysm following blunt craniofacial trauma. *Eur Neurol* 58: 239–245, 2007
- 17) Darsaut TE, Ashforth RA, Chow MM, Findlay JM: Endovascular management of an embedded intracranial knife. *Can J Neurol Sci* 34: 460–463, 2007

Corresponding author:

Takahiro Ota, MD, PhD, Department of Neurosurgery, Tokyo Metropolitan Tama Medical Center, 2-8-29 Musashidai, Fuchu-shi, Tokyo 183-8524, Japan.

✉ toota-ky@umin.org