



Contents lists available at ScienceDirect

# Indian Pacing and Electrophysiology Journal

journal homepage: [www.elsevier.com/locate/IPEJ](http://www.elsevier.com/locate/IPEJ)

## Safety steps for a non-fluoroscopic approach in right-sided electrophysiology procedures: A point of view<sup>☆</sup>

Franco Zoppo<sup>a,\*</sup>, Claudia Licciardello<sup>b</sup>, Giulia Favaro<sup>b</sup>, Alessandra Scalon<sup>b</sup>, Enrico Bacchiega<sup>c</sup>, Antonio Lupo<sup>d</sup>, Giacomo Mugnai<sup>d</sup>, Francesca Zerbo<sup>d</sup>

<sup>a</sup> U.O.C. Cardiologia, Ospedale Civile Gorizia, Gorizia, Italy

<sup>b</sup> Abbott Medical Italia, Italy

<sup>c</sup> U.O.C. Cardiologia, Hospital San Bortolo, Vicenza, Italy

<sup>d</sup> U.O.C. Cardiologia, Ospedale Civile Mirano, Venezia, Italy

### ARTICLE INFO

#### Article history:

Received 15 January 2019

Received in revised form

13 March 2019

Accepted 20 March 2019

Available online 23 March 2019

#### Keywords:

Supraventricular tachycardia  
Radiofrequency catheter ablation  
Mapping system  
Fluoroscopy exposure reduction

### ABSTRACT

**Background:** Electro-anatomic 3D mapping systems enable the fluoroscopy (FL) exposure to be reduced. In right-heart supraventricular tachycardia (SVT) procedures, FL could potentially be avoided. Our aim was to discuss some steps focusing on safety.

**Methods and results:** The patient cohort comprised 70 consecutive SVT patients who underwent electrophysiologic (EP) catheterization. FL was routinely avoided in all cases (54.2% males, age  $57.2 \pm 13.3$  years): 51 ablations and 19 EP study procedures. The Carto<sup>®</sup>3 (Biosense Webster) mapping system was used in 17/70 cases (24.3%), and the EnSite Precision<sup>™</sup> (Abbott) system in the remaining 53/70 (75.7%). The mean procedure time was  $94.1 \pm 33.2$  min; no FL was used. No major complications occurred. Acute procedural success was achieved in all 51 patients who underwent ablation. Over 3-month follow-up, arrhythmia recurred in 1 patient. There were no significant differences in procedural times between the two mapping systems, except for the time dedicated to the full geometry creation, which was longer for the EnSite Precision<sup>™</sup> system: 10 min (8.5–15 IQR) vs 8 min (5–10 IQR) for the Carto<sup>®</sup> system ( $p < 0.001$ ) mainly due to the sub-diaphragmatic navigation. The following procedural steps were considered critical in order to safely avoid FL use: “loop” advancing of catheters, the use of a fixed intracardiac reference, His signal landmark centered maps and the careful acquisition of sub-diaphragmatic extracardiac geometry.

**Conclusions:** A routine zero X-ray approach by means of electro-anatomic 3D mapping systems is safe and effective in right-atrium procedures. Some *ad-hoc* discussed procedural steps may enhance safety. Copyright © 2019, Indian Heart Rhythm Society. Production and hosting by Elsevier B.V. This is an open access article under the CC BY-NC-ND license (<http://creativecommons.org/licenses/by-nc-nd/4.0/>).

## 1. Introduction

Fluoroscopy (FL) is traditionally used for the visualization of catheters in interventional electrophysiology (EP) procedures. Growing awareness of the radiation injury hazard, however, has prompted most operators to carefully implement all necessary measures to keep the utilization and impact of ionizing radiations

as low as reasonably achievable (ALARA) [1]. The use of electro-anatomic mapping (EA) during ablation allows the exposure to FL of both patients and EP staff to be reduced, without affecting safety and efficacy [2]. The recent literature has reported various experiences of such ablation approaches [3–5]. Our aim was to assess some detailed steps to enhance procedural safety, since we consider that a reliable standard of efficacy has already been achieved. A routine approach to right atrial SVT study and ablation, with the Carto<sup>®</sup>3 (Biosense Webster) and EnSite Precision<sup>™</sup> (Abbott) EA systems, was adopted [6–8].

## 2. Methods

From June 2015 to May 2018, 94 consecutive patients underwent EP catheterization for SVT study and, when applicable,

<sup>☆</sup> This is a single center experience (U.O.C. Cardiologia Mirano, Italy); FZ and EB were previously working in the study Center during the data collection and analysis, though are now employed in different (above mentioned) Cardiology Divisions.

\* Corresponding author.

E-mail address: [francozoppo@gmail.com](mailto:francozoppo@gmail.com) (F. Zoppo).

Peer review under responsibility of Indian Heart Rhythm Society.

ablation in our EP laboratory. Of these, 70 underwent procedures without the use of FL and were included in the present study (54.2% males, age  $57.2 \pm 13.3$  years; see table).

In all cases, we used a minimum of 2 diagnostic catheters, and a further ablation catheter when radiofrequency (RF) therapy was required (a standard 4 mm non-irrigated catheter for AVNRT or an irrigated catheter in the case of other arrhythmias).

All patients underwent cardiac ultrasound check after the procedure (to exclude any pericardial complication) and were monitored during the hospital stay by means of wireless telemetry. They were discharged within the 2nd post-operative day and followed up by means of standard clinical outpatient and ECG assessment up to the 3rd post-procedural month.

Informed consent to undergo the procedure was obtained from all individual participants included in the study. The present study was designed as a retrospective analysis and was approved by our Institutional Ethics Committee.

### 2.1. Procedure, equipment and EP study

All anti-arrhythmic drugs were discontinued at least 5 half-lives before the procedure. In all patients undergoing a procedure with the EnSite Precision™ system, 2 quadripolar diagnostic catheters were used: a standard non-steerable Josephson curve catheter for His mapping and right ventricular pacing maneuvers, and a steerable quadripolar (quadri- or decapolar) catheter, which was used to complete the EA maps and was then positioned along the coronary sinus. In patients undergoing a procedure with the Carto<sup>®</sup>3 system, preliminary mapping was performed directly with an ablation catheter, owing to the features of the system: a proprietary “NAV” catheter is required first, to enable subsequent mapping with other catheters.

The study adopted the standard definitions and ablation criteria used for any conventional EP approach. Specifically, ablation of CTI-dependent flutter was conventionally approached by deploying a continuous line of RF lesions along the CTI. In AVNRT procedures, an A/V EGM ratio of 0.5 was set as the target during slow-pathway mapping. For other atrial tachycardias, standard EP maneuvers were used to detect ablation targets, conventionally at the earliest or mid-to-end-diastolic EGM activities in the case of focal and reentry activation, respectively [9].

### 2.2. Assessment of procedural steps focusing on safety (navigation and mapping)

Our feeling is that avoiding fluoroscopy is more likely to affect safety than efficacy. We tried to identify the main procedural steps encountered and the techniques that allow the use of FL to be safely and effectively avoided:

- 1) **Femoral vein puncture and cannulation.** When performed slightly above the presumed great saphenous/femoral vein junction (along the Poupart ligament line), this may allow straight femoral-iliac vein “upstream” navigation. Regarding this aspect, we should take into account the anatomic variability below the Poupart ligament of the saphenous drainage into the deep femoral vein [3].
- 2) **Extra-cardiac and sub-diaphragmatic navigation.** This feature is offered by both the Carto<sup>®</sup>3 and EnSite Precision™ systems: the former system allows geometry acquisition as low as the “matrix” that is detected by the “NAV” catheter thus, navigation along the femoral-iliac veins at the level of the groin is not possible; the latter system, which is a combined impedance and magnetic-field-based system (when magnetic sensor-enabled proprietary catheters are used) yields a mapping volume

starting from a lower position including the groin region. For the Carto3<sup>®</sup> procedures the acquisition starts as soon as the NAV catheter enter the matrix acquisition area which is roughly at an epigastric level. The wider is the area of the patches application over the patients’ chest and the wider (therefore lower) is the region of the matrix acquisition. Since the patches position is strictly related to the Location Pad, positioned under the patient’s bed (chest area), also the size of the patient chest is important; for instance, in the pediatric population the sub-diaphragmatic navigation is allowed starting from a “lower” area.

During the up-delivery, the first catheter acts as a “scout”, tracing the geometry of the iliac vein and the inferior vena cava route, including their vein branching (Fig. 1). It may be preferable to routinely advance the catheter in a loop shape; this is a safety issue, is easy to do in the case of steerable catheters (but is also feasible when non-steerable catheters are used) and may provide a wider depiction of the geometry and volumes of the sub-diaphragmatic veins. The delivery of further catheters will safely follow this geometry.

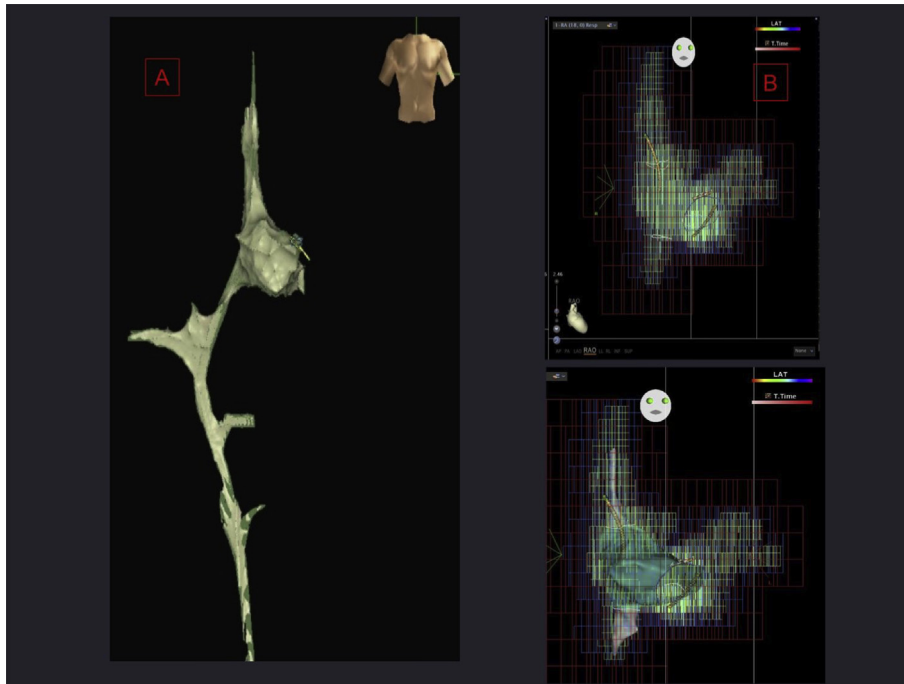
The extracardiac vessels geometry acquisition may also help to implement an alternative subclavian or jugular approach during CS catheter positioning, within the Carto3 matrix area and thus available with both systems.

The Carto3 system uses a magnetic localization technology able to provide an accurate spatial localization of the Biosense Webster catheters that have incorporated a magnetic sensor (called sensor based). The information is obtained in real time from the sensors of the catheters once reworked by the Carto system and are used to calculate the position of the catheter in three-dimensional space.

The currents are measured by surface electrodes (patches) attached to the patient body. An algorithm then calculates the position of each electrode based on the measurement of the current variation measured on each patch; everything is improved by integrating the magnetic technology that allows the creation of a matrix, which allows to view, with the same accuracy of less than mm, all the diagnostic and ablation catheters connected to the system.

The EnSite Precision™ mapping system combines electrical and magnetic data (but only when a sensor-enabled catheter is used). However, this EA system is an impedance-based system, whose functionality is based on the use of three couples of electrodes positioned on the three main axes (x, y, z), which allows the catheters to be located. As the value of the current exchanged between the matching electrodes is fixed, it is possible to calculate the impedance value associated with each single electrode of the catheters in a given position and at any moment during navigation. The differences in the impedance values recorded on the three axes create an impedance gradient; this is fundamental for the development of the 3D-coordinate system, which enables the catheters to be located very accurately (to less than 1 mm) in the patient’s body during navigation.

Owing to this operating principle, any abrupt variation in the impedance value associated to a specific electrode in a specific location results in an abrupt shift of the electrode position in the coordinate system, which is clearly visible graphically. Impedance variations are sometimes small and related to a single electrode of a specific catheter. This situation is common during extracardiac and sub-diaphragmatic navigation, when the catheter moves from the femoral access and comes close to tributaries of the main vessel in which it is navigating. When the electrophysiological diagnostic catheter is advanced, deformations of the tip or of the inter-electrodes space, due to a slight impedance increase, indicate the origins of vein tributaries which can be depicted. This behavior



**Fig. 1.** *Left panels:* Femoral to IVC and RA navigation with the EnSite Precision™ system. Stepwise reconstruction from femoral access to right atrium is performed with a “scout” diagnostic catheter. All tributaries are explored and remain visible as a useful reference when advancing further catheters. *Right panel:* Carto®3 system preliminary geometry during the acquisition of the matrix.

could be helpful not only in detecting vein tributaries, whose impedance value is higher than that of the atrium or of the principal vessel because of the smaller lumen, but also during the identification of the coronary sinus ostium. However, from this point of view any comparison between both mapping systems cannot be made since the impedance related deformations of catheter tip, seen during Ensite navigation, in our experience is based on a non-dedicated feature.

- 3) **His signal-centered maps.** Many useful tips can facilitate comprehension of the size and proportions of the heart chambers during mapping: the boundaries of the right atrium, as indicated by the superior and inferior vena cava markers, the tricuspid valve and the coronary sinus ostium. However, for both 3D systems, the most critical need is to identify the His bundle signal, as this enables to “center” the map.
- 4) Re-check for the **breathing gating after the insertion of a new catheter into the patient's body (for procedures using the EnSite Precision™ system)**. Another necessity is to collect data to compensate for breathing every time that a new catheter is inserted into the heart chamber of interest. Both the EA mapping systems track the patient's respiration and update respiration data throughout the entire procedure. If the patient's breathing becomes irregular, the functions of anatomy acquisition and marker insertion are suspended.
- 5) Use of a stable intracardiac reference and recommendations in the case of realignment

The term “positional reference” refers to the origin of the Cartesian coordinate system used by the EA mapping system for the graphical representation of catheters in the 3D space. For Carto®3 procedures the intracardiac reference is the chosen catheter derived EGM signal, usually located in a stable anatomic region such as the CS, while in the EnSite procedures, also a second choice is possible, using a virtual reference (a point selected by the

mapping system) located in an almost central position in the patient's chest. Both solutions are highly accurate and safe, and selection of one or the other depends on the context, specifically on the form of sedation used during the procedure. In particular, an intracardiac positional reference is typically used during EP studies or the ablation of SVTs: this choice is motivated by the more stable catheter navigation enabled by the use of an intracardiac reference in the event of irregular breathing, which is very common when anesthesiologic support is absent. By contrast, the use of the system reference as the positional reference is more appropriate when the patient is under general anesthesia or in those situations in which the use of an intracardiac reference is not possible owing to lack of stability of the position of the reference catheter.

The disadvantage of using an intracardiac reference is related to potential movements of the catheter, in particular of the electrode selected as the positional reference. Positioning the catheter in the coronary sinus in a distal portion of the vessel is considered a good practice, as this will reduce the risk of shifting. As the catheter must be stable, it might be better to avoid placing it in proximity to vein tributaries or to other structures such as valves, which may eject the catheter. Keeping track of the initial position of the intracardiac CS reference catheter is another useful practice for both systems: this is made possible by the addition of a catheter shadow as soon as the intracardiac reference is chosen, in order to monitor for any movement of the catheter throughout the entire procedure. This process helps not only to verify the stability of the catheter in the vessel, but also to enable corrective action to be taken if the catheter shifts; in the event of shifting, the catheter can be moved and realigned with its position on the previously recorded shadow, in order to restore the initial conditions of navigation and to enable the electro-anatomical map reconstructed up to that time to be re-used. If the catheter selected as the intracardiac reference cannot be repositioned, manual re-alignment is required. This operation can be carried out very precisely by verifying the match between the real-time position of all the anatomical landmarks and the 3D

marker annotated during the initial phase of the anatomical reconstruction (His signal, tricuspid valve, coronary sinus ostium).

- 6) **Mandatory use of all diagnostic and mapping catheters.** Since the ability to visualize all the catheters tips and shafts (a long as electrodes are present) is a common feature of all EA systems, we consider it mandatory to use every diagnostic catheter that would be needed for a complete traditional EP study. Continuously checking that the His signal electro-anatomic tag matches the real-time. His signal catheter mapping catheter and the “frozen” position of the CS catheter shaft enhances the reliability of the geometry acquired.
- 7) **Details of geometry.** Anatomies of special regions, such as the ostium of the coronary sinus, the tricuspid valve and the Koch triangle, may be created very accurately in order to precisely re-navigate after ablation. The pacing or mapping techniques, which are often mandatory, such as entrainment, para-Hisian pacing and slow-pathway tag for Koch pace-mapping, may be reliably tagged and documented for any further re-map or re-do procedures, or even for safety purposes (Fig. 2).

### 3. Statistical methods

Results are reported as means and standard deviations for continuous variables with normal distribution, median and inter-quartile range otherwise (normality of all quantitative variables was checked by means of the Shapiro-Wilk test). Categorical variables are reported as numbers and percentages. Comparisons of continuous data were made by using Student's t-test or, in the case of non-normal distribution, the Mann-Whitney test. Categorical variables were compared by using chi-square or Fisher's exact test, as appropriate. A p value < 0.05 was considered significant. Statistical analysis was performed by means of STATA 13.1 statistics software (StataCorp LP, College Station, TX, USA).

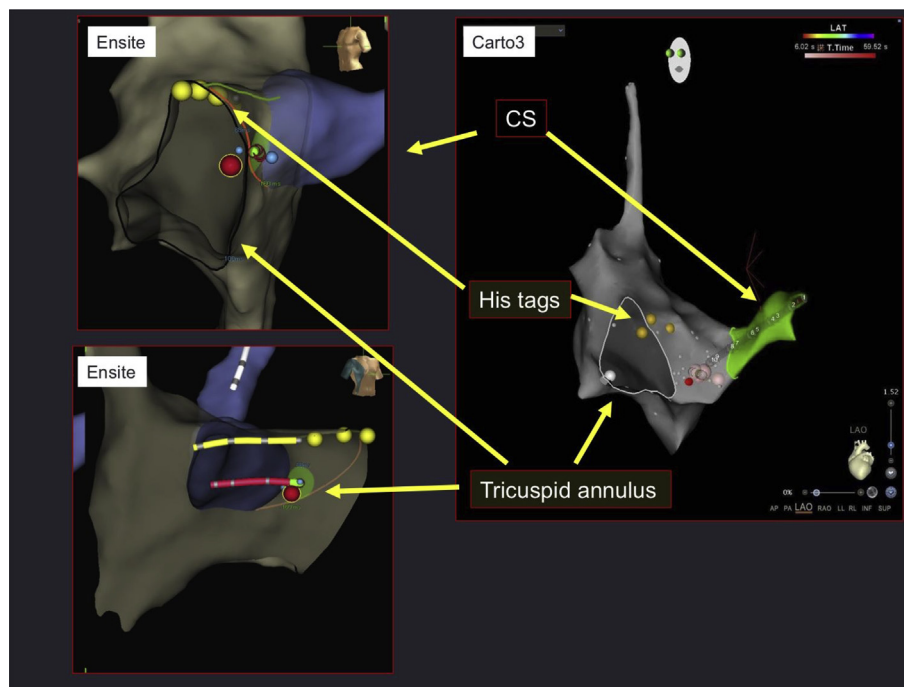
## 4. Results

### 4.1. Procedural data and outcome

In all 70 study patients (54.2% males, age  $57.2 \pm 13.3$  years), the index procedure was performed without the use of FL (Dose area product =  $0 \text{ cGy} \cdot \text{cm}^2$ ). The study population and procedure types are described in Table 1. The Carto<sup>®</sup>3 (Biosense Webster) mapping system was used in 17 cases (24.3%), while the EnSite Precision<sup>™</sup> (Abbott) system was used in the remaining 53 (75.7). All procedural data are shown in Table 1. The mean procedure time was  $94.1 \text{ min} \pm 33.2 \text{ min}$ ; the mean EP study time was  $30.0 \pm 23.4 \text{ min}$ . The median 3D map-creation time was 10 min (8–15 IQR). There were no significant differences in procedural time between the two mapping systems, except for the time dedicated to the full geometry creation, which was longer for the EnSite Precision<sup>™</sup> system: 10 min (8.5–15 IQR) vs 8 min (5–10 IQR) for the Carto<sup>®</sup> system ( $p < 0.001$ ) mainly due to the sub-diaphragmatic navigation. Indeed, when we consider just the atrial geometry acquisition times, this difference is not present. The difference is related to the time spent to navigate and acquire geometry in the groin area during the up-delivery of catheters for EnSite<sup>™</sup> procedures, while for Carto<sup>®</sup> procedures the acquisition time starts as soon as the NAV catheter enter the matrix acquisition area which is roughly at an epigastric level.

In the Carto<sup>®</sup>3 procedures, the sub-diaphragmatic navigation out of regions of matrix acquisition has been performed without the use of fluoroscopy in all the study patients.

In the 51 cases which required ablation, the median RF delivery time was 60 s (34–145 IQR) for AVNRT ( $n = 31, 60.8\%$ ) and 435.5 s (170–744.5 IQR) for other tachycardias (all focal right atrial tachycardias;  $n = 20, 39.2\%$ ). In patients undergone to a Carto<sup>®</sup>3 procedure, the RF delivery applications were slightly higher; this data can be probably explained with the progressive operators learning



**Fig. 2.** Detailed reconstruction and mapping of Koch triangle in AVNRT with both the 3D mapping systems in LAO and RAO views for Ensite and LAO view for Carto 3. The His position (yellow tags) is monitored throughout the procedure. The CS (blue-purple and green colored for Ensite and Carto3 respectively) is positioned in a stable site inside the vessel. The ablation catheter (red) is used for detailed mapping of the slow pathway (blue markers) before applying RF (red marker).

**Table 1**  
Study population and procedural data

	All (N = 70)	Carto (N = 17)	EnSite (N = 53)	p value
<b>Study population</b>				
Male sex (N)	38 (54.3%)	8 (47.1%)	30 (56.6%)	p = 0.49
Age (years)	57.2 ± 13.3	53.4 ± 12.5	58.5 ± 13.4	p = 0.17
AVNRT ablation (N)	31 (44.3%)	10 (58.8%)	21 (39.6%)	p = 0.37
Typical Atrial Flutter ablation (N)	12 (17.1%)	3 (17.6%)	9 (17.0%)	
Focal Right Atrial Tachycardia Ablation (N)	8 (11.4%)	2 (11.8%)	6 (11.3%)	
EP study only (N)	19 (27.2%)	2 (11.8%)	17 (32.1%)	
<b>Procedural data</b>				
Procedure time (min)	94.1 ± 33.2	99.0 ± 22.2	92.6 ± 36.0	p = 0.38
EP study time (min)	30.0 ± 23.4	29.9 ± 19.3	30.0 ± 24.9	p = 0.99
Full Geometry time (min)	10 (8–15)	8 (5–10)	10 (8.5–15)	p < 0.001*
Atrial Geometry time (min)	8 (5–11)	8 (5–10)	8 (5.3–11.8)	p = 0.38
RF time, AVNRT (s)	60 (34–145)	106 (20–211)	59 (35–81)	p = 0.64
RF time Focal Right Atrial Tachycardia (s)	435.5 (170–744.5)	451 (225–749)	420 (160–740)	p = 0.82
RF Applications, AVNRT (N)	4.5 (3–15)	12.5 (3–24)	4 (3–9)	p = 0.35
RF Applications Focal Right Atrial Tachycardia (s)	14 (10–27)	34 (11–35)	14 (7–19)	p = 0.33
Acute success/Total RF procedures	51/51 (100%)	15/15 (100%)	36/36 (100%)	–
Major Complications	0	0	0	–

\*Mann-Whitney test

curve with X zero procedures; in our center the Carto<sup>®</sup> system has been used until the 2016 and was then replaced by the EnSite system.

In the 51 patients who required ablation, the index procedure was acutely effective in all cases. In one patient, AVNRT relapsed early during follow-up; the patient therefore started beta-blocker therapy. On 3-month follow-up examination, all other treated patients were free from arrhythmia recurrence and symptoms. One other patient required a second effective redo procedure, owing to late AVNRT relapse, after the 4th month of follow-up.

#### 4.2. Safety data

No major acute procedural complications occurred. In one patient, a long PR interval (with occasional non-conducted P waves) was recorded at the end of the procedure. On the 3rd post-procedural day, an ECG stress test confirmed good dromotropic competence of the AV node; she was then monitored by an automatic implantable loop recorder (on 12-month follow-up examination, no tachy- or brady-arrhythmias were recorded). No other medium-term complications occurred.

### 5. Discussion

#### 5.1. Main findings

A routine zero X-ray approach by means of the Carto<sup>®</sup>3 or EnSite Precision<sup>™</sup> electro-anatomic 3D mapping systems is feasible, safe and effective in right-atrium procedures.

Even though in our study no complications were found during the catheters navigation, a careful extra-cardiac navigation needs to be addressed.

#### 5.2. General considerations

The International Commission on Radiological Protection (ICRP) strongly recommends reducing X radiation in all diagnostic and interventional procedures (as low as reasonably achievable, as stated in the ALARA principle) [10]. Recent literature encourages this approach.

In 2002, Drago et al. published the first experience of using the Carto<sup>®</sup> system for right-sided accessory pathway ablation in 21 paediatric cases [11]; moreover, in this case series 19/21 procedures

where performed using just a single catheter. This is an important issue in the paediatric population where also the heart instrumentation may affect the procedure safety, beside the X rays exposition. On the other hand, in our opinion, when considering an adult population of patients, the use of more diagnostic catheters may enhance the procedure safety and anatomy depiction. In other words, the risk/benefit ratio related to the “heart instrumentation” is more favourable in the adults as compared with children due to the heart size. This experience was followed by others, in populations of paediatric patients [12,13].

In a recent study by Fernandez-Gomez et al. [14], a completely non-fluoroscopic approach to SVT ablation was assessed, and proved feasible, safe and effective. In that study, the only EA system used was the EnSite, and the results confirmed those of previous studies [14]. The authors state that the operators switched to an “FL-combined” approach in 18 cases, all during the first two years of the study period. The learning curve of all the EP staff may explain this issue.

The right-sided SVT ablation approach mainly poses “electrophysiological” rather than “anatomic” challenges, as the target regions are easily reachable; moreover, a high procedural success rate can be achieved in most cases. For this reason, navigation safety may become the most frequently encountered issue when a “zero-FL” approach is planned. Deployment of the infra-diaphragmatic catheters is often the step which prompts the switch to FL use, which is safer. The availability of femoral-iliac (groin) and inferior vena cava geometries is a helpful feature, as is subclavian geometry routing for “upper” CS catheter delivery.

Another issue that we consider important for safe navigation is that all the diagnostic catheters should be used, as in the case of a traditional FL procedure. Indeed, navigation systems can replace the visualization of catheters navigation and not their use.

When considering left sided procedures, a zero fluoroscopy approach has also been assessed some recent reports, addressing feasibility and safety mostly in pulmonary vein isolation (PVI) procedures. The use of the intracardiac echo (ICE), is increasingly adopted in these procedures. ICE is mainly used to assist with challenging transseptal puncture, left atrium catheter manipulation and to guide AF ablation with 8 mm-tip catheters to monitor over-heating and microbubble formation [15]. Two recent reports evaluated the feasibility and safety of PVI with zero-fluoroscopy use combining 3D mapping with ICE. Ferguson et al. enrolled 21 patients undergoing AF ablation and utilized ICE to perform a double

transseptal puncture. In 19 out of 21 cases, no fluoroscopy was used, whereas in 2 cases 2–16 min of fluoroscopy were required [16]. Reddy et al. combined ICE and a 3D mapping system to perform a completely “fluorless” procedure of PVI in 20 patients [17].

Another strategy has been also described using the real-time 3D transesophageal echocardiography to guide PVI procedure, since it allows point-by-point navigation in the left atrium and visualization of both circular mapping and ablation catheter [18].

Despite these results, we have to consider that ICE requires a higher procedural cost, a dedicated operator and an additional venous puncture; on this basis this approach may add a limited value and probably give an unfavorable risk/benefit ratio in right sided procedures.

To improve the visualization in PVI procedures the “merging” techniques can provide an opportunity to tailor the ablation strategy to an individual’s anatomy. A pre-operative imaging study with CT scan or MRI, may render a more reliable model after chamber reconstruction. However, CT scan is inherently characterized by a significant amount of x-ray exposure. In a recent paper reported by Caponi et al., in PVI population of patients, when comparing PVI procedures guided by CartoXP and CartoMerge, a pre-acquired MRI did not modify the outcome, but permitted a significant reduction of x-ray exposure [19]. Other papers, also addressing the same technology, didn’t show the same results [20].

Again, probably CT or MRI image integration may add just a limited value in right sided procedures.

## 6. Limitations

The present study was designed as a retrospective analysis. The procedural data and outcome of the study population are described, but a comparison with a conventional FL approach was not planned. The main limitations of the present study are therefore its retrospective design, the absence of a control group and the relatively small study population included. Moreover, comparison between the EA systems was not part of the study aim. Finally, follow-up was limited to the 3rd post-procedural month; this may constitute a methodological limitation, as any late arrhythmia relapse would have gone unobserved. Therefore, the efficacy results may be affected, rather than the safety conclusions.

## 7. Conclusions

A routine zero X-ray approach by means of the Carto<sup>®</sup>3 or EnSite Precision<sup>™</sup> electro-anatomic 3D mapping systems is feasible, safe and effective in right-atrium procedures. Some *ad-hoc* discussed procedural steps may enhance safety.

- The authors take responsibility for all aspects of the reliability and freedom from bias of the data presented and their discussed interpretation. Alessandra Scalon is an Abbott Medical Italia employee. The other authors report no relationships that could be construed as a conflict of interest.

## Conflict of interest

None declared.

## References

- [1] Heidebuchel H, Wittkamp FHM, Vano E, et al. Practical ways to reduce radiation dose for patients and staff during device implantations and electrophysiological procedures. *Europace* 2014;16:946–64.
- [2] Casella M, Dello Russo A, Pelargonio G, et al. Near zero fluoroscopic exposure during catheter ablation of supraventricular arrhythmias: the NO-PARTY multicentre randomized trial. *Europace* 2016;18:1565–72.
- [3] Igari K, Hirokawa M, Uchiyama H, et al. Anatomical variation at the sapheno-femoral junction. *Ann Vasc Dis* 2013;6:702–5.
- [4] Razminia M, Willoughby MC, Demo H, et al. Fluorless catheter ablation of cardiac arrhythmias: a 5-year experience. *Pacing Clin Electrophysiol* 2017;40:425–33.
- [5] Bigelow AM, Smith PC, Timberlake DT, et al. Procedural outcomes of fluorless catheter ablation outside the traditional catheterization lab. *Europace* 2017;19:1378–84.
- [6] Swissa M, Birk E, Dagan T, et al. Radiofrequency catheter ablation of atrioventricular node reentrant tachycardia in children with limited fluoroscopy. *Int J Cardiol* 2017;236:198–202.
- [7] Delise P, Sitta N, Bonso A, et al. Pace mapping of Koch’s triangle reduces risk of atrioventricular block during ablation of atrioventricular nodal reentrant tachycardia. *J Cardiovasc Electrophysiol* 2005;16:30–5.
- [8] Knight BP, Zivin A, Souza J, et al. A technique for the rapid diagnosis of atrial tachycardia in the electrophysiology laboratory. *J Am Coll Cardiol* 1999;33:775–81.
- [9] Haissaguerre M, Gaita F, Fischer B, et al. Elimination of atrioventricular nodal reentrant tachycardia using discrete slow potentials to guide application of radiofrequency energy. *Circulation* 1992;85:2162–75.
- [10] Clarke RH, Alexakhin RM, Boice JD, et al. The 2007 recommendations of the international commission on radiological protection. ICRP publication 103. *Ann ICRP* 2007;37:1–332.
- [11] Drago F, Silvetti MS, Di Pino A, et al. Exclusion of fluoroscopy during ablation treatment of right accessory pathway in children. *J Cardiovasc Electrophysiol* 2002;13:778–82.
- [12] Papagiannis J, Tsoutsinos A, Kirvassilis G, et al. Nonfluoroscopic catheter navigation for radiofrequency catheter ablation of supraventricular tachycardia in children. *Pacing Clin Electrophysiol* 2006;29:971–8.
- [13] Smith G, Clark JM. Elimination of fluoroscopy use in a pediatric electrophysiology laboratory utilizing three-dimensional mapping. *Pacing Clin Electrophysiol* 2007;30:510–8.
- [14] Fernandez-Gomez JM, Moriña-Vázquez P, Morales Edel R, et al. Exclusion of fluoroscopy use in catheter ablation procedures: six years of experience at a single center. *J Cardiovasc Electrophysiol* 2014;25:638–44.
- [15] Marrouche NF, Martin DO, Wazni O, Gillinov AM, Klein A, Bhargava M, Saad E, Bash D, Yamada H, Jaber W, Schweikert R, Tchou P, Abdul-Karim A, Saliba W, Natale A. Phased-array intracardiac echocardiography monitoring during pulmonary vein isolation in patients with atrial fibrillation: impact on outcome and complications. *Circulation* 2003;107:2710–6.
- [16] Ferguson JD, Helms A, Mangrum JM, et al. Catheter ablation of atrial fibrillation without fluoroscopy using intracardiac echocardiography and electro-anatomic mapping. *Circul Arrhythm Electrophysiol* 2009;2:611–9.
- [17] Reddy VY, Morales G, Ahmed H, et al. Catheter ablation of atrial fibrillation without the use of fluoroscopy. *Heart Rhythm* 2010;7:1644–53.
- [18] Regoli F, Faletta FF, Scaglione M, et al. Pulmonary vein isolation guided by real-time three-dimensional transesophageal echocardiography. *Pacing Clin Electrophysiol* 2012;35:e76–9.
- [19] Caponi D, Corleto A, Scaglione M, et al. Ablation of atrial fibrillation: does the addition of three-dimensional magnetic resonance imaging of the left atrium to electroanatomic mapping improve the clinical outcome?: a randomized comparison of Carto-Merge vs. Carto-XP three-dimensional mapping ablation in patients with paroxysmal and persistent atrial fibrillation. *Europace Eur Pacing Arrhythm Card Electrophysiol – J Work Groups Card Pacing Arrhythm Card Cell Electrophysiol Eur Soc Cardiol* 2010;12:1098–104.
- [20] Bertaglia E, Bella PD, Tondo C, et al. Image integration increases efficacy of paroxysmal atrial fibrillation catheter ablation: results from the CartoMerge Italian Registry. *Europace Eur Pacing Arrhythm Card Electrophysiol – J Work Groups Card Pacing Arrhythm Card Cell Electrophysiol Eur Soc Cardiol* 2009;11:1004–10.