

Modified double guiding catheter 'Ping Pong' technique to treat large coronary perforation: a case report

Himanshu Gupta¹, Navjyot Kaur ¹, Yashpaul Sharma¹, and Soo Teik Lim^{2*}

¹Advance Cardiac Center, Sector 12, Post Graduate Institute of Medical Education & Research, Chandigarh 160012, India; and ²5 Hospital Drive, Level 2 Pharmacy, National Heart Centre Singapore 169609

Received 13 June 2020; first decision 15 July 2020; accepted 16 April 2021

Background

Despite improvement in available tools and techniques, procedural complications like coronary perforation can occur during percutaneous coronary intervention (PCI). Severe proximal coronary perforations are usually caused by balloon and vessel size mismatch but can also occur with appropriately sized balloons or stents if the coronary vessel has very eccentric calcification or if there is negative remodelling of the vessel.

Case summary

A 74-year-old man with a history of type II diabetes mellitus, hypertension, and chronic coronary syndrome (previous PCI 10 years before) presented with unstable angina of 2 weeks of duration. Coronary angiography revealed a patent stent in left anterior descending artery, significant disease in left circumflex artery and diffuse calcified lesion in dominant right coronary artery (RCA). During angioplasty of RCA, the patient developed severe Ellis grade III perforation, which was successfully managed with modified double guiding catheter 'Ping Pong' technique. In this technique, the already engaged 7 French (F) Amplatz Left 1 guide catheter was used to deliver the bulky covered stent in highly tortuous and calcified RCA while a second 6F guide catheter (Judkin Right) introduced through contralateral femoral access was used for introducing the balloon, which initially sealed the perforation and subsequently acted as a distal anchor to provide strong support to deliver the covered stent.

Conclusion

In a case of severe coronary perforation, modified Ping Pong technique using a small-sized second guide catheter complimentary to the first guide catheter, can be used to deploy bulky covered stent.

Keywords

Modified · Ping Pong · Double guiding catheter · Coronary perforation · Rotablation · Anchor balloon · Case report

Learning points

- Early recognition and immediate balloon occlusion are the most important steps to prevent cardiac tamponade and haemodynamic collapse in a case of severe coronary perforation.
- Double guide catheter technique and its modifications allow controlled delivery of covered stents to perforation site.
- In addition, Ping Pong technique ensures uninterrupted balloon occlusion of the perforation site and allows the use of angioplasty balloon as distal anchor for smooth delivery of bulky covered stents.

* Corresponding author. Tel: 6598630156, Email: lim.soo.teik@singhealth.com.sg, sooteik@yahoo.com

Handling Editor: Julien Adjedj

Peer-reviewers: Mariama Akodad; Christoph Jensen and Felice Gragnano

Compliance Editor: Gemina Doolub

Supplementary Material Editor: Nida Ahmed

© The Author(s) 2021. Published by Oxford University Press on behalf of the European Society of Cardiology.

This is an Open Access article distributed under the terms of the Creative Commons Attribution Non-Commercial License (<http://creativecommons.org/licenses/by-nc/4.0/>), which permits non-commercial re-use, distribution, and reproduction in any medium, provided the original work is properly cited. For commercial re-use, please contact journals.permissions@oup.com

Introduction

Coronary perforation is a relatively uncommon but potentially life-threatening complication in patients undergoing percutaneous coronary intervention (PCI).^{1,2} The risk factors associated with coronary perforation include advanced age, female sex, calcified lesions, tortuous vessel, balloon to artery ratio >1.2, use of cutting balloons, rotational atherectomy, and the intervention in a chronic total occlusion or in a post-coronary artery bypass graft patient.^{3,4} The proximal vessel perforations are usually caused by balloon or stent size mismatch but they can also occur with appropriately sized balloons or stents in a calcified vessel, especially if the calcification is eccentric or if there is negative remodelling of vessel.⁵ These perforations are usually large (Ellis grade III), may cause severe haemodynamic compromise and often require covered stents for successful management.⁵ The distal vessel perforations, on the other hand, are usually small, frequently caused by wire tip migration and can be managed with prolonged balloon inflation or by local delivery of subcutaneous fat, thrombin, or coils.^{5,6}

We hereby present a case, where the index patient had a severe Ellis grade III perforation at proximal right coronary artery (RCA) after balloon pre-dilatation, which was successfully managed with a modified double guiding catheter 'Ping Pong' technique.

Timeline

Clinical presentation	A 74-year-old gentleman; an active smoker with history of type 2 diabetes mellitus, hypertension, and previous percutaneous coronary intervention (PCI) presented with unstable angina of 1 month of duration
Day 1	Presentation to emergency department with multiple episodes of rest angina Evaluation: Electrocardiogram (ECG): ST-T changes in the inferior and lateral leads at rest 2D Echocardiography: Normal left ventricular ejection fraction with inferolateral hypokinesia Cardiac Biomarkers: Normal
Day 2	Haemogram, Coagulogram, Renal function tests, Serum electrolytes: within normal limit Procedure: Underwent Coronary angiography and PCI to right coronary artery (RCA) During PCI to diffusely diseased and calcified RCA, there was severe perforation in the proximal vessel, which was managed successfully with covered stent using modified 'Ping Pong' double catheter technique.
Day 5 (at Day 3 after procedure)	Discharged on dual antiplatelets (Aspirin and Clopidogrel) in stable condition with no fresh ECG changes or echocardiography findings

Case presentation

A 74-year-old man with a history of type II diabetes mellitus, hypertension, and chronic coronary syndrome (previous PCI 10 years before) presented with unstable angina of 2 weeks duration. Resting electrocardiogram (ECG) revealed ST-segment depression in inferior and lateral limb leads. On 2D echocardiography, the left ventricular ejection fraction was normal with inferolateral wall hypokinesia with no significant valvular disease. As the patient had frequent episodes of

rest angina, he was taken up for upfront coronary angiography; which revealed a patent stent in left anterior descending coronary artery, severely diseased and calcified dominant RCA, and a severe lesion in the mid-portion of non-dominant left circumflex artery (LCX) (*Figure 1A–D, Video 1*). Being the dominant and large vessel, it was decided to treat RCA first followed by the LCX. As RCA was heavily calcified and very tortuous, we used a 7 French (F) Amplatz Left 1 (AL 1) guiding catheter through right femoral artery. It ensured good support during PCI and also enabled the use of bigger size rotablation burr, if required. Rotational atherectomy to RCA was performed using 1.25 mm burr followed by a 1.5 mm burr (*Figure 2A and B*). After rotablation, the lesions in mid and proximal RCA were pre-dilated with a 2.5 mm non-compliant (NC) balloon at 16 atmospheres (atm) (*Figure 2C and D*). Immediately after pre-dilation of proximal lesion, the patient developed a severe Ellis grade III perforation in the proximal RCA (*Figure 3A, Video 2*). The pre-dilatation balloon was re-inflated at 6 atm at the site of perforation to stop bleeding; meanwhile a 6F Judkin Right 4 (JR4) guiding catheter was inserted from the contralateral femoral artery access (*Figure 3B*). Simultaneously two 16F patent peripheral venous cannulas were ensured in both upper limbs and significant pericardial effusion was ruled out using 2D echocardiography.

The first guiding catheter was withdrawn slightly and JR4 guide catheter was engaged in the RCA. A Fielder™ coronary wire was introduced into the vessel through JR4 guide catheter, after momentarily deflating the first balloon (*Video 3*). Another 3.0 mm semi-compliant (SC) balloon was advanced into the RCA from 2nd guide

catheter and was inflated at site of perforation after removing the 1st balloon (*Figure 3C*). Since a prolonged balloon inflation of 7 min failed to seal the perforation (*Figure 3D*), we decided to use a covered stent. A 7F guide catheter compatible Graft Master® 3.5 × 19 mm covered stent was introduced through AL1 guide catheter. The 3.0 mm SC balloon, which was used to seal the perforation was deflated and pushed distally into RCA, where it was re-inflated to jail the two coronary guidewires and act as an anchor to provide strong support for covered stent delivery (*Figure 4A, Supplementary material online,*

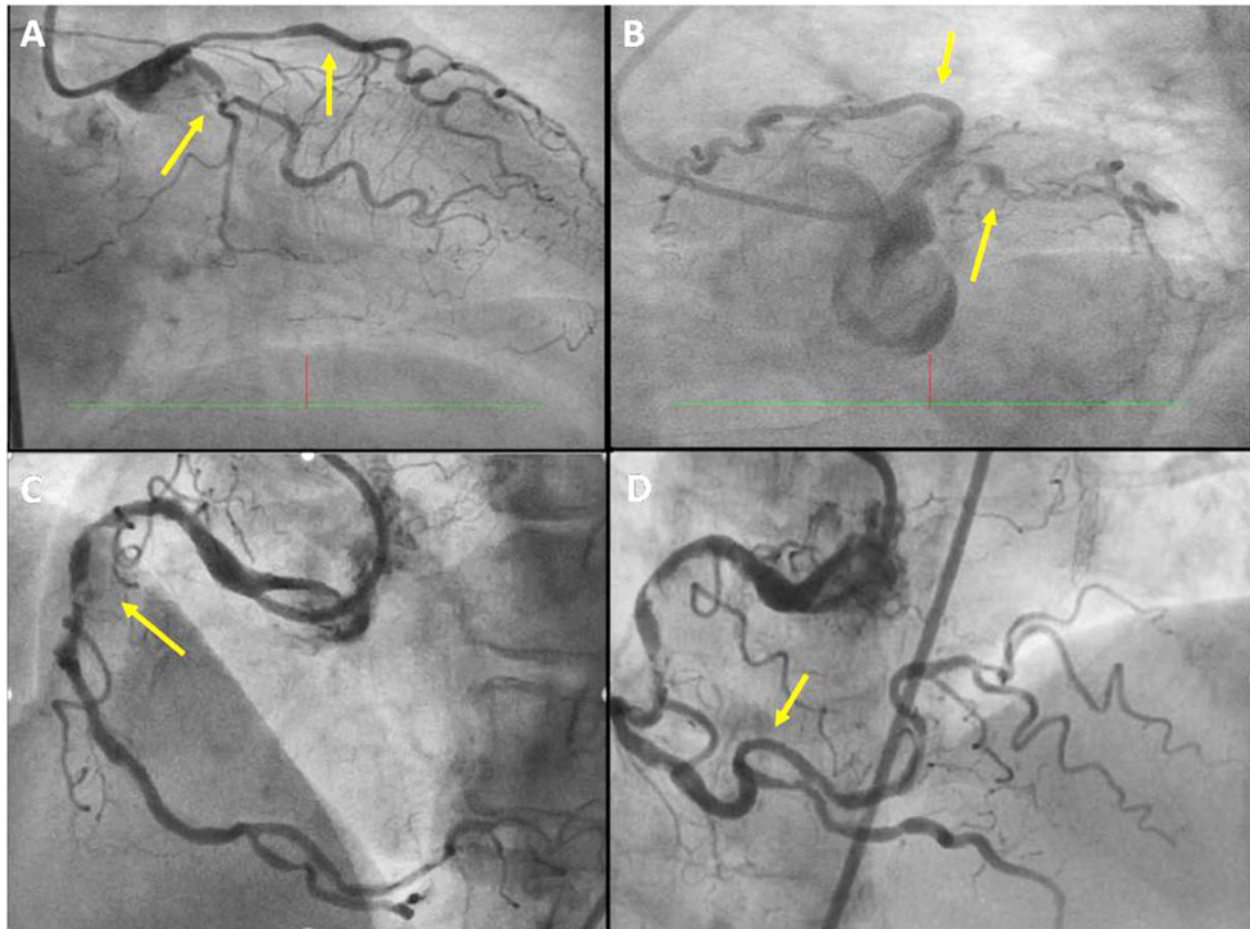
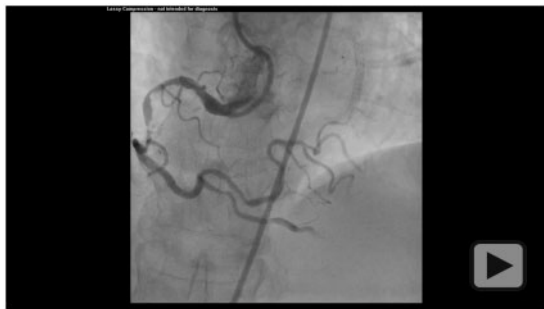

Figure 1 (A and B) Patent stent in mid left anterior descending artery, significant disease in mid left circumflex artery (non-dominant). (C) Diffuse calcified lesion in proximal-mid right coronary artery (dominant). (D) Tortuous and calcified distal right coronary artery.



Video 1 Diagnostic angiogram of right coronary artery.

[Video S1](#)). Before deploying the covered stent, anchor balloon along with the second guidewire were removed from RCA ([Figure 4B](#)). The perforation site was successfully sealed after implantation of the covered stent ([Figure 4C](#)). There was significant disease in RCA, both proximal and distal to the covered stent, which was further stented

with 3.5×30 and 3×30 mm drug-eluting stents and post-dilated with a 4.0 mm NC balloon with a good angiographic result ([Figure 4D](#), [Supplementary material online, Video S2](#)). There was loss of small acute marginal branches after stenting, which was not associated with any chest pain or ECG changes.

Heparin was reversed with protamine at the end of procedure. The Troponin I level post-procedure was 0.09 ng/mL (normal <0.04 ng/mL) and there were no new ischaemic changes on the ECG. Post-procedural serial cardiac ultrasound did not reveal any pericardial effusion. The patient was discharged after 3 days of the procedure on dual antiplatelets (Aspirin and Clopidogrel). At a follow-up of 2 years, he is doing well and is in New York Heart Association Class I.

Discussion

With a reported incidence of 0.1–0.5%, coronary perforation is a rare but life-threatening complication.^{1,2,6} Ellis *et al.* classified coronary perforations into three grades. Grade I is extraluminal crater without extravasation, grade II is contrast extravasation into myocardium or pericardium without any jet and grade III is contrast

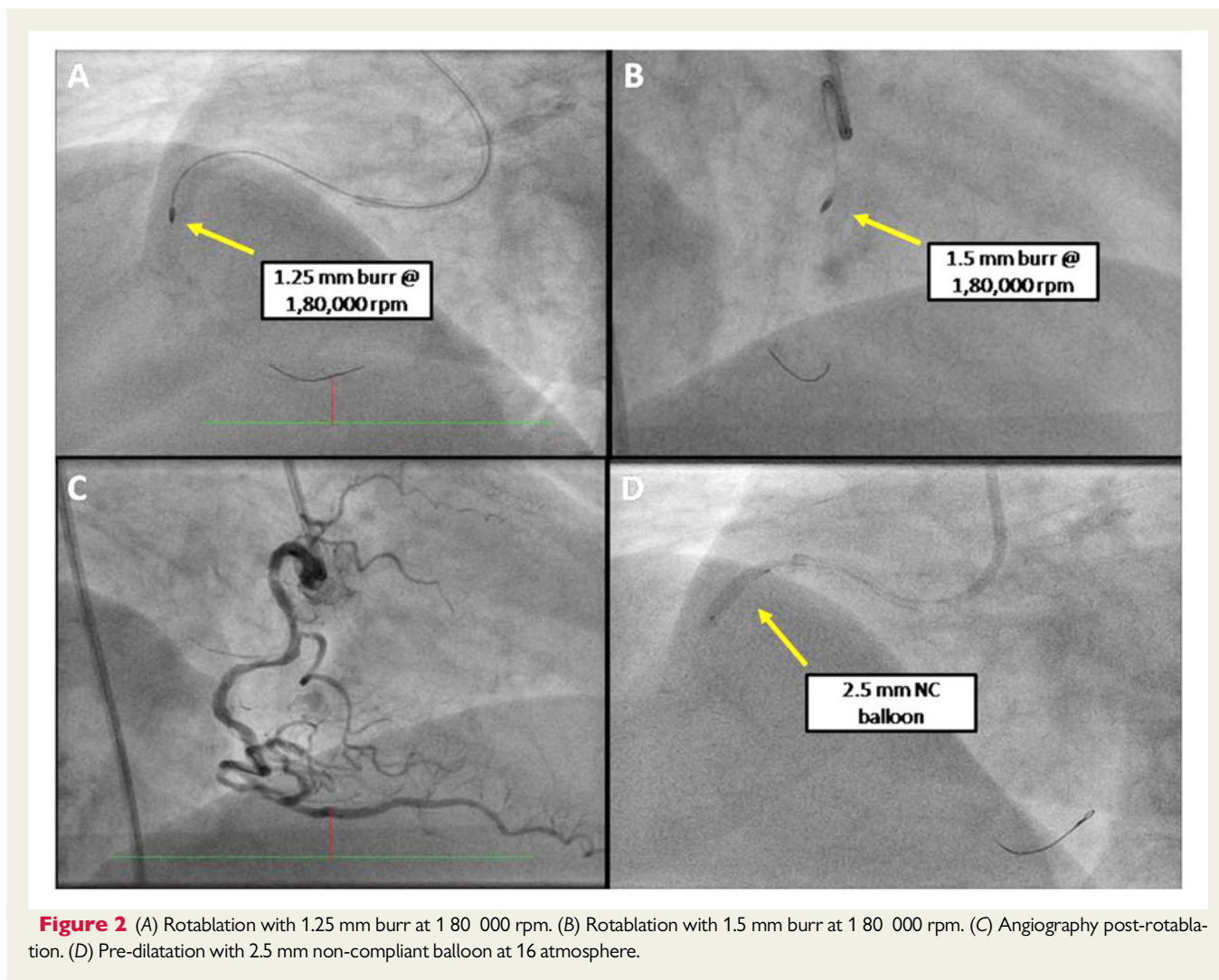


Figure 2 (A) Rotablation with 1.25 mm burr at 1 80 000 rpm. (B) Rotablation with 1.5 mm burr at 1 80 000 rpm. (C) Angiography post-rotablation. (D) Pre-dilatation with 2.5 mm non-compliant balloon at 16 atmosphere.

extravasation with a jet ≥ 1 mm. Ellis grade III perforations are severe and may cause immediate cardiac tamponade, rapid haemodynamic compromise, and death.^{1,6,7}

The emergent management of severe grade III perforation requires prompt recognition and immediate sealing of the perforation site with a balloon, as was done in the index case.^{1,7} This prevents development of significant pericardial effusion and tamponade. Simultaneously two large bore intravenous access should be established to give fluids and inotropes if required and cardiac tamponade should be ruled out with echocardiography. Cardiac tamponade, if present, should be relieved with immediate pericardial drainage.⁸ Fortunately, our patient did not develop cardiac tamponade or haemodynamic instability as the perforation site was immediately sealed with the pre-dilatation balloon. Unlike small distal vessel leaks, the larger proximal vessel perforations seldom respond to prolonged balloon inflation and usually require covered stent implantation.^{5,7} We used a 3.5 mm polytetrafluoroethylene Graftmaster™ covered stent to seal the perforation. Reversal of heparin should be avoided until there is equipment in the coronary vessels but requires an individualistic approach.^{1,2,5,7}

Covered stents have greatly reduced the incidence of tamponade, need for emergent surgery, and mortality associated with coronary

perforations.^{1,3,5,7} Despite improvement in their design, the covered stents still remain bulky and may be difficult to deliver in calcified and tortuous vessels.^{5,8,9} New lower profile covered stents that are 5F guide catheter compatible have been developed but are not readily available in all countries. An upfront use of 8F guide catheter can avoid the need of dual catheters as it can accommodate a covered stent, two wires and an angioplasty balloon, however, 8F guiding catheters are not routinely used in non-chronic total occlusion interventions and also have a limited availability.

The double guide catheter technique has been associated with fewer deaths, lesser surgical explorations, and emergent pericardiocentesis.^{9,10} In the original 'Ping Pong' technique described by Silver et al.,¹¹ a second large guiding catheter is used to deliver the covered stent and the pre-dilatation balloon is used to seal the perforation site. In this case, we modified the original Ping Pong technique and used the 7F AL1 guide catheter to deliver the covered stent; while the subsequently inserted 6F JR4 guide catheter was used for balloon occlusion of the perforation site. This modified double catheter Ping Pong technique allows the use of small and less aggressive second guide catheter, which is also easier to engage and disengage. Also, as the covered stent is advanced over the original coronary wire there

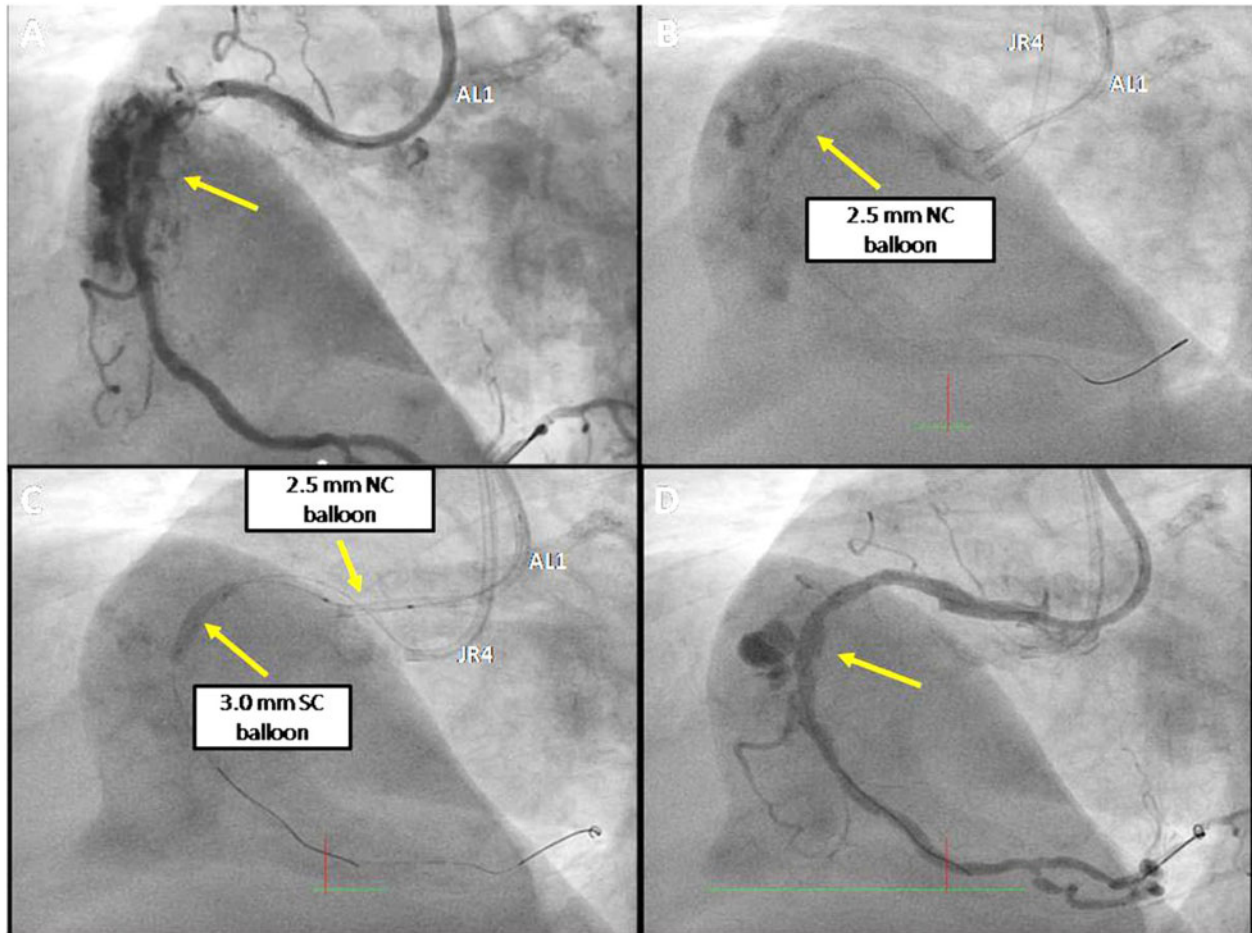
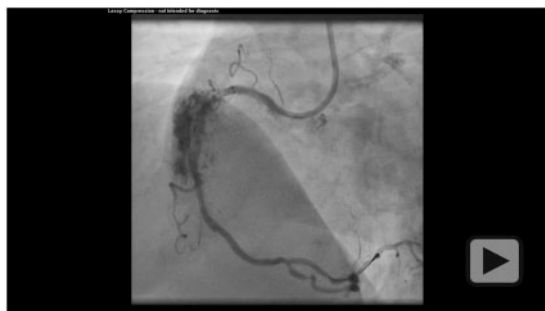
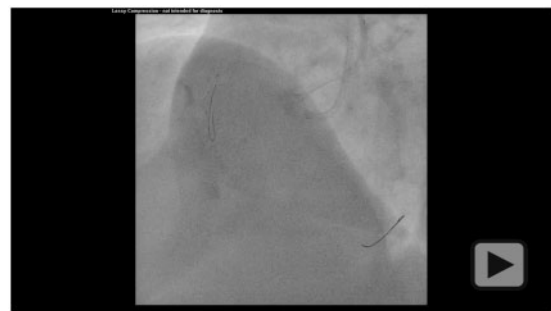
Figure 3 (A) Large right coronary artery perforation after pre-dilatation. (B) Perforation sealed by inflating the pre-dilatation 2.5 mm non-compliant balloon. JR4 guide in aortic root through contralateral femoral access. (C) 3.0 mm semi-compliant balloon loaded through JR4 guide and inflated. Non-compliant balloon (2.5 mm) retracted back. (D) Persistent perforation on repeat angiography.



Video 2 Large right coronary artery perforation.



Video 3 Wiring right coronary artery through second guide (JR4) after momentarily deflating the pre-dilatation balloon.

are less chances of delivering the stent through a false track. The other modification is to use the second balloon as a distal anchor to aid in covered stent delivery. However, the advantage of original technique is that the pre-dilatation balloon is used to seal the site of

perforation and no extra balloon is required. Moreover, if the first guide catheter is not capable of delivering the bulky covered stent, the second larger guide catheter can be used.

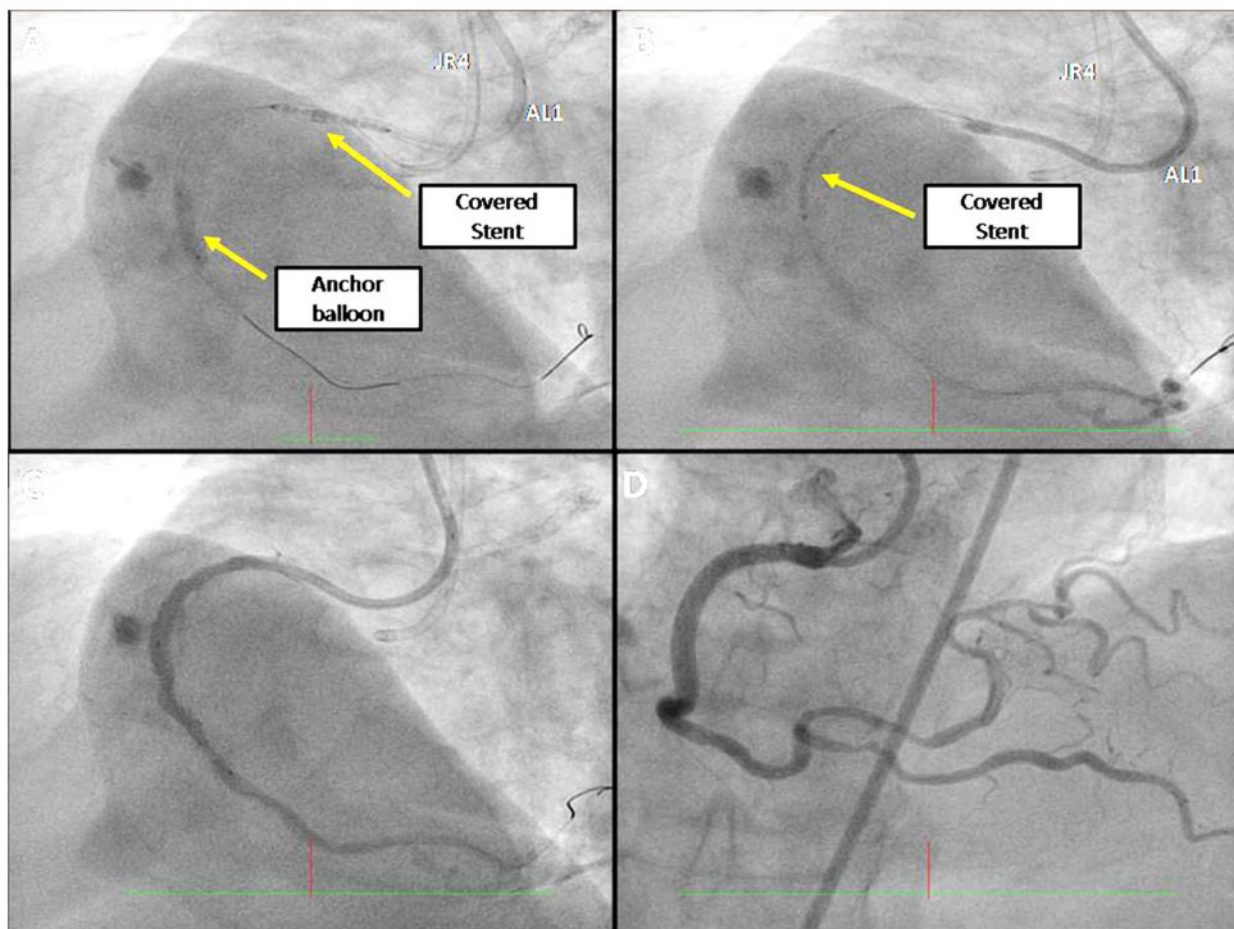


Figure 4 (A) 3.0 mm semi-compliant balloon acts as anchor and the covered stent being delivered through AL1 guide catheter. (B) The covered stent positioned at site of perforation; while the contralateral assembly is removed. (C) Successful closure of perforation post-deployment of covered stent. (D) Right coronary artery after successful percutaneous coronary intervention.

Conclusion

In a case of severe coronary perforation, modified Ping Pong technique using a small-sized second guide catheter complimentary to the first guide catheter, can be used to deploy bulky covered stent.

Lead author biography



Dr Himanshu Gupta: A keen interventionalist with expertise in complicated PCI, LM interventions, and rotational atherectomy.

Supplementary material

Supplementary material is available at *European Heart Journal - Case Reports* online.

Slide sets: A fully edited slide set detailing this case and suitable for local presentation is available online as [Supplementary data](#).

Consent: The authors confirm that written consent for submission and publication of this case report including images and associated text has been obtained from the patient in line with COPE guidance.

Conflict of interest: None declared.

Funding: None declared.

References

- Shimony A, Joseph L, Mottillo S, Eisenberg MJ. Coronary artery perforation during percutaneous coronary intervention: a systematic review and meta-analysis. *Can J Cardiol* 2011;**27**:843–850.
- Kinnaird T, Kwok CS, Kontopantelis E, Kontopantelis E, Ossei-Gerning N, Ludman P et al. Incidence, determinants and outcomes of coronary perforation during percutaneous coronary intervention in the United Kingdom between 2006 and 2013. An analysis of 527121 cases from the British Cardiovascular Intervention Society Database. *Circ Cardiovasc Interv* 2016;**9**:e003449.

3. Dippel EJ, Kereiakes DJ, Tramuta DA, Broderick TM, Shimshak TM, Roth EM et al. Coronary perforation during percutaneous coronary intervention in the era of abciximab platelet glycoprotein IIb/IIIa blockade: an algorithm for percutaneous management. *Catheter Cardiovasc Interv* 2001;**52**:279–286.
4. Kiernan TJ, Yan BP, Ruggiero N, Eisenberg JD, Bernal J, Cubeddu RJ et al. Coronary artery perforations in the contemporary interventional era. *J Interv Cardiol* 2009;**22**:350–353.
5. Giannini F, Candilio L, Mitomo S, Ruparella N, Chieffo A, Baldetti L et al. A practical approach to the management of complications during percutaneous coronary intervention. *JACC Cardiovasc Interv* 2018;**11**:1797–1810.
6. Ellis SG, Ajluni S, Arnold AZ, Popma JJ, Bittl JA, Eigler NL et al. Increased coronary perforation in the new device era. Incidence, classification, management and outcome. *Circulation* 1994;**90**:2725–2730.
7. Al-Lamee R, Ielasi A, Latib A, Godino C, Ferraro M, Mussardo M et al. Incidence, predictors, management, immediate and long-term outcomes following grade III coronary perforation. *JACC Cardiovasc Interv* 2011;**4**:87–95.
8. Eeckhout E, De Palma R. Coronary perforation. *JACC Cardiovasc Interv* 2011;**4**:96–97.
9. Rother J, Trobs M, Ludwig J, Achenbach S, Schlundt S. Treatment and outcome of coronary artery perforations using a dual guiding catheter technique. *Int J Cardiol* 2015;**201**:479–483.
10. Ben-Gal Y, Weisz G, Collins MB, Genereux P, Dangas GD, Teirstein PS et al. Dual catheter technique for the treatment of severe coronary artery perforations. *Catheter Cardiovasc Interv* 2010;**75**:708–712.
11. Silver KH, Bauman WB, Berkovitz KE. Dual-catheter covered stenting: a novel approach to the treatment of coronary artery perforations. *J Invasive Cardiol* 2003;**15**:348–350.