

Minimally invasive cervical pedicle screw fixation via the posterolateral approach for metastatic cervical spinal tumors

Yoshihisa Sugimoto¹⁾, Takahiro Hayashi²⁾ and Takamitsu Tokioka²⁾

1) Department of Orthopaedic Surgery, Okayama City General Medical Center, Okayama, Japan

2) Department of Orthopaedic Surgery, Kochi Health Sciences Center, Kochi, Japan

Abstract:

Background: To avoid lateral misplacement of midcervical pedicle screws, we developed a method for Minimally Invasive Cervical Pedicle Screw (MICEPS) fixation via a posterolateral approach. This intramuscular approach allows for horizontal pedicle screw insertion and reduced intraoperative bleeding. We reviewed our initial experience with MICEPS fixation for patients with cervical metastases.

Methods: This study included 18 consecutive patients who received cervical spinal surgery for metastatic tumor. We treated 12 patients with conventional cervical pedicle screw fixation, and 6 patients with the MICEPS fixation technique. Average follow-up was 14 months (range 3 to 34). We inserted 117 pedicle screws using the navigation system. Average fusion area was 4.9 vertebrae (range 3 to 8). Alpha-angles between a line perpendicular to the posterior cortex of the vertebral body and the screw trajectory in the transverse plane were also measured.

Results: The average surgical time was 250 min (range 151 to 420 min) with the conventional pedicle screw fixation and 234 min (range 154 to 300 min) with the MICEPS fixation. The average total blood loss was 780 mL (range, 180-1430 mL) in the conventional pedicle screw fixation group and 180 mL (range, 70-400 mL) in the MICEPS fixation group. At the level of midcervical (C3-5), average alpha-angles was 52 degrees (range 43 to 62) in MICEPS fixation group, and 39 degrees (range 19 to 55) in conventional cervical pedicle screw group.

Conclusions: The MICEPS fixation technique uses an intramuscular approach, which is minimally invasive and reduces intraoperative bleeding. Intramuscular approach allows for horizontal pedicle screw insertion, and reduced critical screw deviation.

Keywords:

Cervical pedicle screw, Horizontal insertion, Minimally invasive surgery, Navigation

Spine Surg Relat Res 2017; 1(4): 218-221

dx.doi.org/10.22603/ssrr.1.2016-0025

Introduction

Treatment for tumors involving the spinal column is challenging¹⁾. Tumors of the cervical spine, which are rarer than thoracolumbar tumors²⁾, can cause respiratory failure and quadriplegia. Non-operative treatment such as chemotherapy and/or radiotherapy (RT) may be effective in the initial stages of symptomatic cervical metastases but not for patients with severe pain due to progressive vertebral collapse³⁾. The surgical procedure for treating cervical spinal tumors involves two main steps, namely, “neural decompression” and “stabilization.” Stabilization with instrumentation is effective for pain relief and for preventing cervical myelo-

pathy secondary to vertebral collapse^{3,5)}.

Surgical options for treatment of cervical metastases include anterior and posterior approaches as well as a combined approach^{2,5)}. The need for spinal cord decompression usually guides the option selected, in addition to whether spinal stabilization is necessary. Posterior reconstruction using cervical pedicle screws can provide better biomechanical stability^{3,6)}. We usually plan for adjuvant therapy such as chemotherapy and/or RT after surgery.

Abumi et al reported clinical results of pedicle screw fixation for reconstruction of metastatic lesions of the middle and lower cervical spine in 1997⁷⁾. Although cervical pedicle screw fixation is essential for reconstruction in spinal disor-

Corresponding author: Yoshihisa Sugimoto, sugi.ort@gmail.com

Received: December 3, 2016, Accepted: April 20, 2017

Copyright © 2017 The Japanese Society for Spine Surgery and Related Research

ders^{3,6-10}), its use also presents a risk for vertebral artery (VA) injury^{11,12}. To avoid lateral misplacement of midcervical pedicle screws, Tokioka developed a method known as minimally invasive cervical pedicle screw (MICEPS) fixation via the posterolateral approach¹³. MICEPS is classified as minimally invasive spine stabilization (MIST) procedure. This intramuscular approach allows for horizontal pedicle screw insertion and reduces intraoperative bleeding. In the present report, we review our initial experience with MICEPS fixation for patients with cervical metastases as well as the related literature.

Patients and Methods

All patients consented to collection and use of their data for publication. This study included 18 consecutive patients who underwent cervical spinal surgery for metastatic tumors between 2005 and 2015. The average follow-up duration was 14 months (range, 3-34). One patient was alive at the final follow-up (34 months); we followed up 17 of the 18 patients until death. The average fusion area was 4.9 vertebrae (range, 3-8).

We placed a total of 117 pedicle screws in 14 pedicles at C2, 10 pedicles at C3, 14 pedicles at C4, 26 pedicles at C5, 14 pedicles at C6, 5 pedicles at C7, 18 pedicles at T1, and 16 pedicles at T2. Patients underwent surgery when their general medical condition allowed for it. During screw insertion, we used the ARCADIS Orbic 3D isocentric C-arm fluoroscope (Siemens Medical, Munich) and the Stealth Station (Medtronic Surgical Navigation Technologies, Minneapolis, MN) for data acquisition and spinal navigation, respectively.

Conventional cervical pedicle screw fixation

Between March 2005 and November 2011, we treated 12 patients using conventional cervical pedicle screw fixation. These included 5 men and 7 women with an average age at onset of 61 years (range, 43-85). Three patients had cervical metastases from lung cancer, 2 from liver cancer, and 2 from thyroid cancer. One of the 12 patients received preoperative RT and 4 patients received postoperative RT. The average preoperative Tokunashi score¹³ was 6.8 (range, 1-12), and the patients' average preoperative performance status was 3.0 (range, 2-4). We inserted 69 pedicle screws using the navigation system. We performed fixation with posterior decompression in 5 of the 12 patients and anterior corpectomy secondary to posterior fixation in 2 patients.

MICEPS fixation

Between December 2011 and January 2015, we treated 6 patients with the MICEPS fixation technique. These included 2 men and 4 women with an average age of 61 years (range, 39-71) at onset. Four patients had lung cancer, while 2 had breast cancer. Three of these patients received postoperative RT. The average preoperative Tokunashi score was 7.5 (range, 4-12), and the average preoperative performance

status was 2.8 (range, 1-4). We inserted 43 pedicle screws using the navigation system. Of the 6 patients treated with MICEPS fixation, 5 did not require decompression; we performed anterior corpectomy secondary to posterior fixation for 1 patient only.

Technical Note

We made two lateral incisions for screw insertion under navigational guidance. After the nuchal fascia was cut, the lateral mass was exposed with blunt dissection and a finger was inserted between the levator scapulae and splenius muscles. The posterior rami medial branches, which often appear on the multifidus muscle, also needed to be retracted. A self-retaining tubular retractor with illumination applied between the split muscle fibers allowed sustained exposure of the lateral mass. To expose the C2 screw entry point (suboccipital triangle), we retracted the obliquus capitis inferior muscle laterally, greater occipital nerve medially and the VA cranially.

A characteristic of MICEPS fixation is a horizontal screw trajectory in the midcervical spine (Fig. 1). A K-wire (1.4 mm) was inserted using a navigated guide tube and drill driver. When pressure is applied to one side of the vertebra while the pedicle probe is being inserted, the vertebra tends to rotate away from the intended point of placement, causing the probe to be inserted more vertically. The use of a K-wire can prevent this vertebral rotation. We carefully checked the guide-wire's direction and depth using a fluoroscopic lateral image. To avoid VA injury, the surgeon should be able to feel the hardness of the medial cortex through the drill driver. A drill, tap, and cannulated pedicle screw were inserted sequentially over the K-wire (Fig. 2), and the rod was placed onto the screw head. To insert the T1 and T2 pedicle screws, we made an additional small midline skin incision and placed them conventionally. After blunt finger dissection through the muscle, we pushed in the rod to connect the midcervical and thoracic pedicle screws.

From the postoperative fine-cut CT scan acquired for each patient, we classified the medial and lateral deviations of each screw into 4 grades: grade 0, no deviation; grade 1, deviation <2 mm; grade 2, deviation >2 mm and <4 mm; and grade 3, deviation >4 mm. In the present study, we considered critical screw deviation as grade 2 or 3. Alpha-angles between a line perpendicular to the posterior cortex of the vertebral body and the screw trajectory in the transverse plane were also measured (Fig. 1).

Results

The average improvement in performance status after surgery was 2.0 (range, 0-4) in patients who received conventional pedicle screw fixation and 2.5 (range, 1-3) in patients who received MICEPS fixation. The median survival duration was 13.5 months in the conventional pedicle screw fixation group and 9.0 months in the MICEPS fixation group

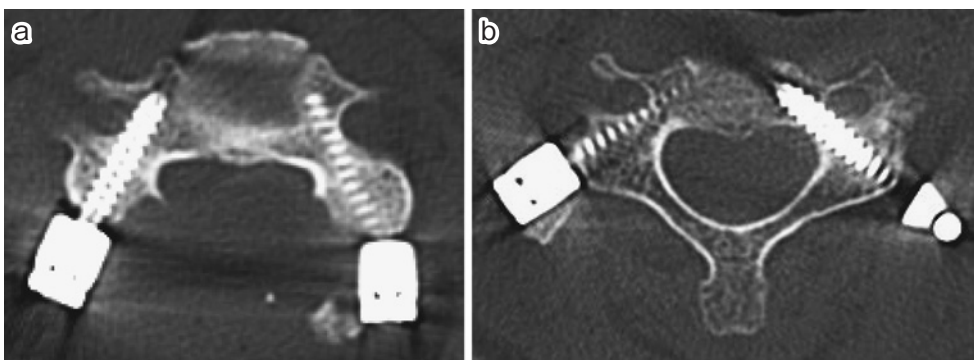


Figure 1. Minimally invasive cervical pedicle screw trajectory. Characteristic of MICEPS fixation is the horizontal screw trajectory in the midcervical spine. a) conventional cervical pedicle screw placement. b) minimally invasive cervical pedicle screw placement.

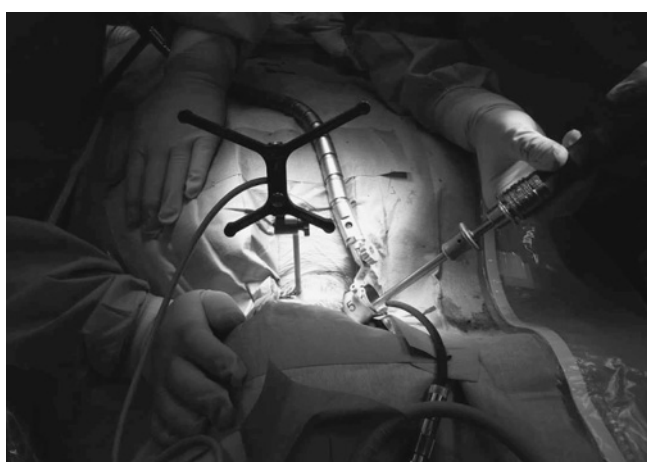

Figure 2. Minimally invasive cervical pedicle screw insertion. Cannulated pedicle screw inserted over the K-wire. Application of a self-retaining tubular retractor with illumination.

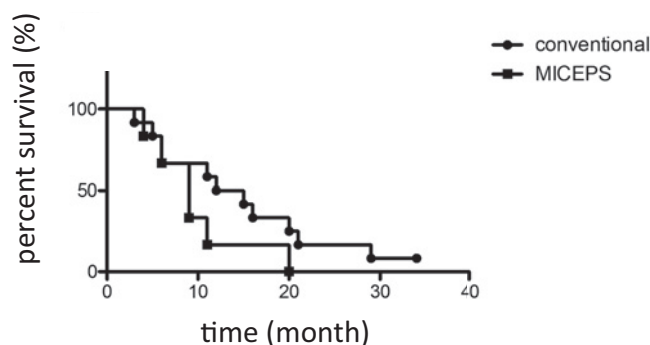


Figure 3. Survival rate.

Discussion

The goal of palliative surgery for metastatic cervical spinal tumor is MIST with early return to daily life¹. Posterior surgery using a pedicle screw system ensures good biomechanical stability^{6,8,12}; however, the considerable posterior exposure poses a risk for massive bleeding. The MICEPS fixation technique involves an intramuscular approach, which is MIST, and it reduces intraoperative bleeding. In this study, the average total blood loss was 780 mL (range, 180-1430 mL) in the conventional pedicle screw fixation group and 180 mL (range, 70-400 mL) in the MICEPS fixation group.

One of the advantages of MICEPS fixation is the horizontal pedicle screw insertion at the midcervical spine¹³, as this helps avoid VA injury^{13,15}. In the present study, the incidence of screw perforation was lower in the MICEPS fixation group than in the conventional cervical pedicle screw group.

In our study, there were no medial perforations in the MICEPS fixation group despite horizontal screw insertion. Average midcervical (C3-5) alpha-angles was 52 degrees (range 43 to 62) in MICEPS fixation group, and 39 degrees (range 19 to 55) in conventional cervical pedicle screw group. When displaced, cervical pedicle screws tend to perforate laterally^{6,11,12}, and a lateral perforation that causes VA injury is a critical complication of cervical pedicle screw insertion¹⁰⁻¹². Yukawa et al. reported that 72% of misplaced screws deviate laterally¹¹. The lateral cortex of the pedicle is

(Fig. 3). The average surgical time was 250 min (range 151 to 420 min) with the conventional pedicle screw fixation and 234 min (range 154 to 300 min) with the MICEPS fixation. The average total blood loss was 780 mL (range, 180-1430 mL) in the conventional pedicle screw fixation group and 180 mL (range, 70-400 mL) in the MICEPS fixation group.

We assessed the positions of all pedicle screws by using computed tomography. In the conventional pedicle screw fixation group, 57 of 69 screws were classified as grade 0 or 1 and 12 were classified as grade 2 or 3. In the MICEPS fixation group, 39 of 43 screws were grade 0, and 4 of 43 screws were grade 1 with a medial deviation; there were no critical screw deviations (Table 1). At the level of midcervical (C3-5), average alpha-angles was 52 degrees (range 43 to 62) in MICEPS fixation group, and 39 degrees (range 19 to 55) in conventional cervical pedicle screw group. In the conventional cervical pedicle screw group, postoperative progressive quadriplegia occurred due to epidural hematoma, but after removal of the hematoma, it improved. In this study, no patient developed deep wound infection after surgery.

Table 1. Pedicle Screw Perforation in Both Groups.

		C2	C3	C4	C5	C6	C7	Th1	Th2	Total
Conventional CPS	No. of screws	12	10	12	12	6	3	8	6	69
	Grade 0 or 1	11	7	11	8	5	1	8	6	57
	Grade 2 or 3	1	3	1	4	1	2			12
MICEPS	No. of screws	2		2	14	8	2	10	10	48
	Grade 0 or 1	2		2	14	8	2	10	10	48
	Grade 2 or 3									0

CPS: cervical pedicle screw

MICEPS: Minimally Invasive Cervical Pedicle Screw

substantially thinner than the medial cortex^{6,16,17}. Panjami et al. showed that the medial cortical shell is 1.4 to 3.6 times as thick as the lateral cortical shell¹⁶.

Conventional posterior fixation is a better surgical procedure than MICEPS fixation for patients with static spinal cord compression, anterior tumor resection, or laminectomy. However, MICEPS fixation is indicated for three categories of patients: (1) those at risk for vertebral collapse due to cervical metastasis, (2) those with vertebral collapse but not static spinal cord compression, and (3) those needing augmentation after corpectomy. Posterior decompression was performed for some patients who underwent conventional screw fixation, which can influence total bleeding and post-operative neurological recovery. Limitation of this study is small sample size. There is no evaluation for paravertebral muscle injury in this procedure. The rate of decompression was different in two groups, it may influence both intraoperative bleeding and surgical time.

Conflicts of Interest: The authors declare that there are no conflicts of interest.

References

- Aebi M. Spinal metastasis in the elderly. *Eur Spine J.* 2003;12 (Suppl 2):S202-213.
- Cho W, Chang UK. Neurological and survival outcomes after surgical management of subaxial cervical spine metastases. *Spine.* 2012;37(16):E969-977.
- Oda I, Abumi K, Ito M, et al. Palliative spinal reconstruction using cervical pedicle screws for metastatic lesions of the spine: a retrospective analysis of 32 cases. *Spine.* 2006;31(13):1439-1444.
- Rao J, Tiruchelvarayan R, Lee L. Palliative surgery for cervical spine metastasis. *Singapore Med J.* 2014;55(11):569-573.
- Quan GM, Vital JM, Pointillart V. Outcomes of palliative surgery in metastatic disease of the cervical and cervicothoracic spine. *J Neurosurg Spine.* 2011;14(5):612-618.
- Abumi K, Shono Y, Ito M, et al. Complications of pedicle screw fixation in reconstructive surgery of the cervical spine. *Spine.* 2000;25(8):962-969.
- Abumi K, Kaneda K. Pedicle screw fixation for nontraumatic lesions of the cervical spine. *Spine.* 1997;22(16):1853-63.
- Abumi K, Kaneda K, Shono Y, et al. One-stage posterior decompression and reconstruction of the cervical spine by using pedicle screw fixation systems. *J Neurosurg.* 1999;90(1 Suppl):19-26.
- Ishikawa Y, Kanemura T, Yoshida G, et al. Intraoperative, full-rotation, three-dimensional image (O-arm)-based navigation system for cervical pedicle screw insertion. *J Neurosurg Spine.* 2011; 15(5):472-478.
- Hojo Y, Ito M, Suda K, et al. A multicenter study on accuracy and complications of freehand placement of cervical pedicle screws under lateral fluoroscopy in different pathological conditions: CT-based evaluation of more than 1,000 screws. *Eur Spine J.* 2014;23 (10):2166-2174.
- Yukawa Y, Kato F, Ito K, et al. Placement and complications of cervical pedicle screws in 144 cervical trauma patients using pedicle axis view techniques by fluoroscope. *Eur Spine J.* 2009;18(9): 1293-1299.
- Neo M, Sakamoto T, Fujibayashi S, et al. The clinical risk of vertebral artery injury from cervical pedicle screws inserted in degenerative vertebrae. *Spine.* 2005;30(24):2800-2805.
- Komatsubara T, Tokioka T, Sugimoto Y, et al. Minimally Invasive Cervical Pedicle Screw Fixation by a Posterolateral Approach for Acute Cervical Injury. *Clin Spine Surg.* 2016;Jul 11. [Epub ahead of print]
- Tokuhashi Y, Matsuzaki H, Oda H, et al. A revised scoring system for preoperative evaluation of metastatic spine tumor prognosis. *Spine.* 2005;30(19):2186-2191.
- Sugimoto Y, Ito Y, Tomioka M, et al. Vertebral rotation during pedicle screw insertion in patients with cervical injury. *Acta Neurochir (Wien).* 2010;152(8):1343-1346.
- Panjabi MM, Shin EK, Chen NC, et al. Internal morphology of human cervical pedicles. *Spine.* 2000;25(10):1197-1205.
- Yusof MI, Ming LK, Abdullah MS. Computed tomographic measurement of cervical pedicles for transpedicular fixation in a Malay population. *J Orthop Surg (Hong Kong).* 2007;15(2):187-190.

Spine Surgery and Related Research is an Open Access article distributed under the Creative Commons Attribution - NonCommercial - NoDerivatives 4.0 International License. To view the details of this license, please visit (<https://creativecommons.org/licenses/by-nc-nd/4.0/>).