

## General Urology

## Splenogonadal Fusion: A Genetic Disorder?—Report of a Case and Review of the Literature

Cinzia Chiaramonte\*, Fortunato Siracusa, Giuseppe Li Voti

Dipartimento Materno – Infantile, Chirurgia Pediatrica, Università di Palermo, Italy

## ARTICLE INFO

## Article history:

Received 10 January 2014

Accepted 13 January 2014

## Keywords:

Splenogonadal fusion

Testis

Accessory spleen

## ABSTRACT

Splenogonadal fusion is a rare congenital anomaly in which there is fusion between the spleen and gonad, epididymis or vas. We treated a patient with scrotal mass. A discontinuous fusion between the spleen and epididymis was found; after frozen section mass was excised sparing testis. Although rare, the splenogonadal fusion should be considered in the differential diagnosis of scrotal masses in children, and orchiectomy should be avoided. Moreover, examination of siblings showed a brother affected from accessory spleen. This finding, not reported previously to our knowledge, suggests a possible familiarity of this disorder.

© 2014 The Authors. Published by Elsevier Inc. Open access under [CC BY-NC-ND license](http://creativecommons.org/licenses/by-nc-nd/4.0/).

## Introduction

Splenogonadal fusion (SGF), abnormal connection between spleen and gonad or derivatives of the mesonephros, is a rare congenital anomaly. SGF is more frequent in men, 9:1 or 5:1, according to various authors and as reported by Alvarez.<sup>1</sup> The real incidence is unknown and probably underestimated.

Two types of SGF are described as follows: in continuous type (55%) the normal spleen is connected to the gonad with a cord of splenic tissue or a fibrous band containing small islands of ectopic spleen; in discontinuous type (45%) ectopic splenic tissue is attached to the gonad, but has not connection with the orthotopic spleen. Presentation is usually as scrotal mass or as an incidental finding during orchiopexy or inguinal hernia repair. In most cases reported until recently, the diagnosis was made at pathologic examination of the removed testicle or at autopsy (16.8%). Most anomalies are associated with the continuous type of SGF, including limb defects: splenogonadal fusion limb defect (SGFLD syndrome),

micrognathia, and skull anomalies. To support the hypothesis of genetic disorders, we present a proband case of a discontinuous SGF between the spleen and epididymis in a child and the study of the family.

## Case presentation

A 12-year-old child with a left small scrotal mass was referred to our institution. On physical examination, the mass was located in the cefaled end of epididymis.

Ultrasound examination revealed normal testes on both sides and ipoechogenic mass 1 × 1 cm attached to left epididymis (Fig. 1). At operation, an encapsulated dark purple red mass was found attached to the head of the left epididymis. Frozen section showed normal splenic tissue. Accessory splenic tissue was not found in spermatic cord (Fig. 2).

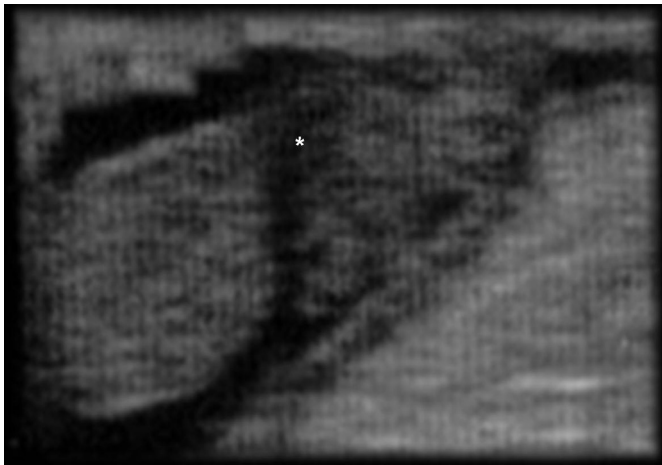
Postoperatively, ultrasound examination revealed that the orthotopic spleen was normal. We also performed abdominal and scrotal echographic examinations in parents and siblings. In a brother 14-year-old, an accessory little spleen (1.1 cm diameter) was found near to the splenic hilum (Fig. 3).

## Discussion

SGF, first described in 1883 by Boestrem, represents 10% of scrotal masses. Different incidence in both sexes may be subsequent to a missed diagnosis because of ovary location and lack of symptoms. In the 4 cases reported in female patients, splenic tissue was

\* Corresponding author. Tel.: +39-91-304469, +39-3472993493; fax: +39-916555472.

E-mail address: [c.chiaramonte@virgilio.it](mailto:c.chiaramonte@virgilio.it) (C. Chiaramonte).



**Figure 1.** Preoperative ultrasound showing hypoecogenic mass located in the head of the epididymis.

adjacent to the ovary or mesovarium. Diagnosis may occur at any age (1–81 years): most reported patients (82%) are younger than 30 years, but 50% of SGF have been described in children.<sup>1</sup>

In 1889, Pommer described a case associated with limb defects, micrognathia, anal atresia, and other congenital abnormalities. Antenatal ultrasound diagnosis is reported in 2 cases.<sup>2</sup> Unusual cases of right SGF were also described.<sup>3</sup>

A teratogenic insult occurring between 5 and 8 weeks of fetal life, when the spleen, gonads, limb buds, and mandible are developing has been postulated. Adhesion or lack of apoptosis at the interface between the splenic primordium and contiguous genital ridge may occur. Precursor structures of shoulder bones are very close: this is probably related to limbs malformations. The right-sided cases may be because of situs inversus.

Colonization by splenic cells of an abnormal suspensory ligament of testis has been also suggested.

The few cases of intragonadal spleen may be a consequence of induction of hemopoietic potencies in gonadal mesenchyma.

De Ravel 97 reported tetra-amelia and SGF in Roberts syndrome and Alessandri in 2010 described a genetic mutation (RAB 23) in a family with Carpenter syndrome and SGF.<sup>4</sup>

Accessory spleen in a sibling, not previously reported to our knowledge, suggests familial predisposition of this disorder.

Up to now, approximately 160 cases have been reported, mainly in the form of single case the majority was based on autopsy findings.<sup>1</sup>

Continuous type is associated with major congenital abnormalities (oro—facial and limb developmental abnormalities: SGFLD syndrome), cryptorchidism, spina bifida, cardiac defects, diaphragmatic hernia, hypoplastic lung, and anorectal abnormalities. Association with cryptorchidism is the most common (31%) particularly on the left side (65%).<sup>5</sup>

Most patients presented a scrotal mass located close to the upper testicular pole, or the fusion was an incidental finding at herniorrhaphy. There have been some unusual presentations, including bowel obstruction caused by the intraperitoneal cord, traumatic rupture of the ectopic splenic tissue, or association with an intra-abdominal seminoma and an intra-abdominal non-seminomatous germ cell testicular tumor.

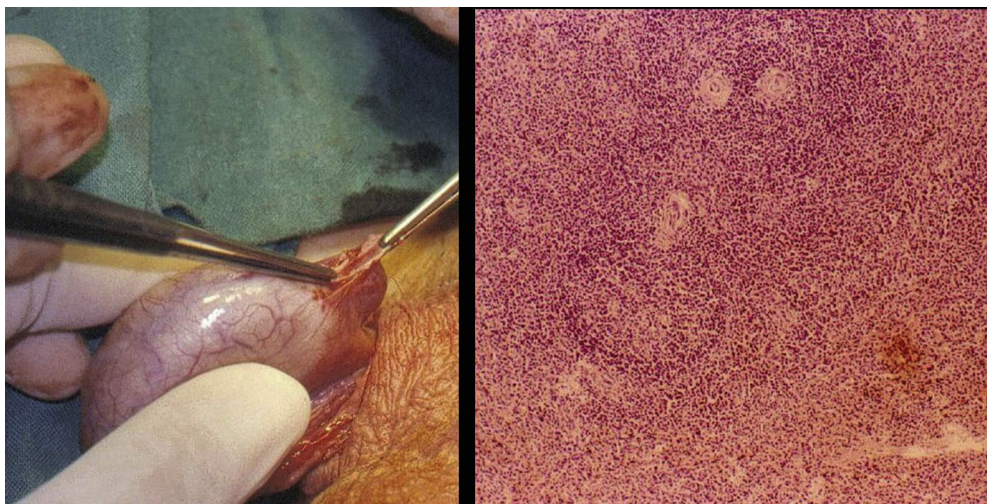
Differential diagnosis with paratesticular solid mass (ie, rhabdomyosarcoma, lymphoma) may be difficult when the mass is intimately attached to the gonad. MRI is helpful in selected cases in which ultrasound is not diagnostic.

In patients noted preoperatively to have an extratesticular scrotal mass a nuclear liver spleen scan may confirm the diagnosis.

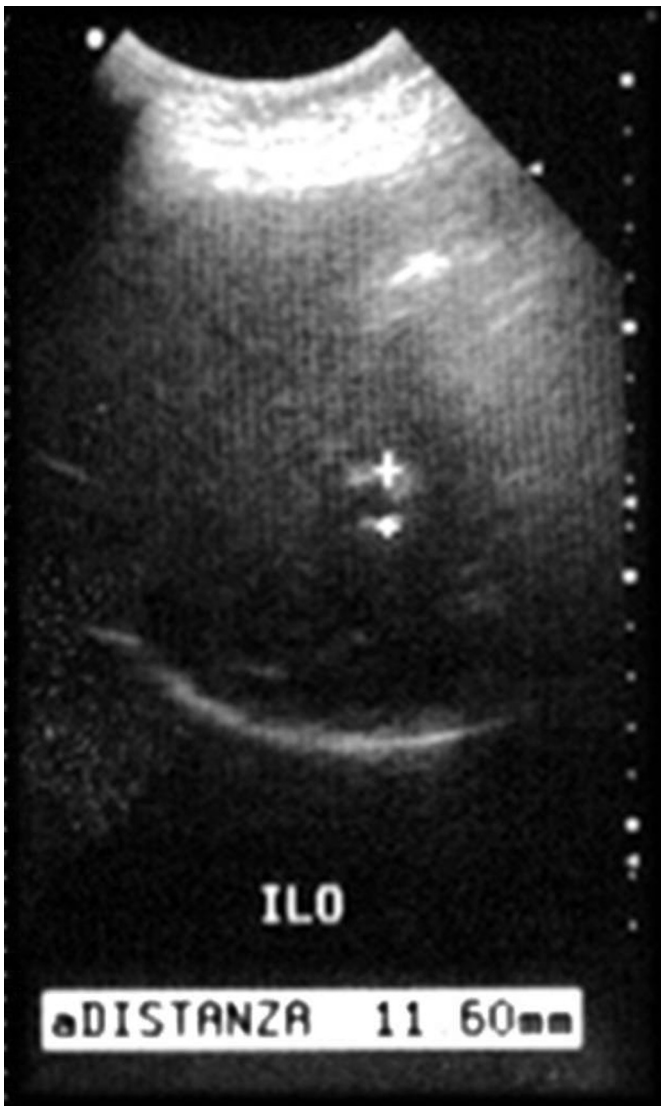
Abdominal and gonadal ultrasonography should be performed in siblings of patients and in patients with accessory spleen. Gonadal ultrasonography should be performed also in patients with hemolytic anemia or idiopathic thrombocytopenic purpura to prevent recurrence after splenectomy as symptoms of hypersplenism could recur. Moreover, accessory and ectopic splenic tissue may be involved mumps, leukemia, mononucleosis, and even malaria.

Treatment of SGF involves excision of ectopic spleen and sparing of the testis; however, an orchietomy was performed in 37% of cases reported.<sup>6</sup>

Laparoscopy was shown to be an excellent method for the diagnosis and treatment of SGF associated with intra-abdominal cryptorchidism.



**Figure 2.** Left: intraoperative appearance of mass. Right: photomicrograph of the mass showing normal splenic tissue.



**Figure 3.** Splenic ultrasound in the sibling: a little accessory spleen near the splenic hilum.

In few patients, splenic tissue has been found fused to the testicle and was not possible perform excision. As frozen sections of the mass shows the splenic nature, decision to leave in situ the splenic remnant is reasonable. Primary male infertility has been reported in a 25-year-old patient with a left SGF and a right undescended testis. In this case, ectopic splenic tissue within the unyielding tunica albuginea must have compressed the testis tissue during development with loss of function: in fact the left testicular biopsy showed no evidence of spermatogenesis.<sup>7</sup>

### Conclusion

SGF is a rare developmental anomaly usually presenting scrotal mass. Preoperative or intraoperative awareness of the condition may allow excision of the scrotal spleen and testicular sparing. SGF associated with limb defect is a well-known syndrome (SGFLD). Probably a genetic disorder underlies the anomaly: SGF is anyway an accessory spleen, in our opinion accessory spleen discovered in a SGF patient's brother supports the hypothesis of genetic pattern of disorder. Additional investigation of SGF patient's siblings may help to answer some of the unresolved questions related to familial and inheritance feature of this pathology.

### References

1. Alvarez Maestro M, López-Tello J, Domínguez Franjo P, et al. Splenogonadal fusion. Report of a case and review of the literature. *Actas Urol Esp.* 2010;34:293–295.
2. Basbug M, Akgun H, Ozgun MT, et al. Prenatal sonographic findings in a fetus with splenogonadal fusion limb defect syndrome. *J Clin Ultrasound.* 2009;37:298–301.
3. Brash J, Roscher AA. Unusual presentation on the right side of ectopic testicular spleen. *Int Surg.* 1987;72:233–234.
4. Alessandri JL, Dagonneau N, Laville JM, et al. RAB23 mutation in a large family from Comoros Islands with Carpenter syndrome. *Am J Med Genet A.* 2010;152A:982–986.
5. Braga LH, Braga MM. Laparoscopic diagnosis and treatment of splenogonadal fusion associated with intra-abdominal cryptorchidism in a child. *Pediatr Surg Int.* 1999;15:465–466.
6. Hikedá A, Nakatsu H, Suzuki Y. Case of splenogonadal fusion in an adult. *Int. J. Urol.* 2010;17:826–827.
7. Al-Marhoon M, Matthew J, Nirmala V. Splenogonadal fusion associated with primary male infertility. *BJU.* 2000;86:560–561.