

Received: 2021.05.18

Accepted: 2021.08.11

Available online: 2021.08.28

Published: 2021.10.05

# Six Cases of Hemoptysis with Angiogenesis from Non-Bronchial Systemic Arteries

## Authors' Contribution:


Study Design A  
Data Collection B  
Statistical Analysis C  
Data Interpretation D  
Manuscript Preparation E  
Literature Search F  
Funds Collection G

ABCDEF 1 **Takumi Fukaya**  
ABCDE 2,3 **Hajime Kasai**  
ABCD 2 **Toshihiko Sugiura**  
BD 2 **Jun Nagata**  
BD 2 **Kenichi Suzuki**  
BD 2 **Kana Ohashi**  
BD 2 **Nozomi Tanaka**  
BD 2 **Mitsuhiro Abe**  
BD 2 **Masaki Suga**  
ADE 2 **Seiichiro Sakao**  
ADE 2 **Takuji Suzuki**

1 Department of Medicine, School of Medicine, Chiba University, Chiba, Japan

2 Department of Respiriology, Graduate School of Medicine, Chiba University, Chiba, Japan

3 Health Professional Development Center, Chiba University Hospital, Chiba, Japan

**Corresponding Author:** Hajime Kasai, e-mail: daikasai6075@yahoo.co.jp**Financial support:** None declared**Conflict of interest:** None declared**Case series****Patients:** Male, 73-year-old • Female, 79-year-old • Male, 45-year-old • Male, 76-year-old • Female, 63-year-old • Male, 43-year-old**Final Diagnosis:** Aspergillus fumigatus infection • hereditary haemorrhagic telangiectasia • lymphangioleiomyomatosis • tuberculosis**Symptoms:** Hemoptysis**Medication:** —**Clinical Procedure:** Angiography • CT scan • embolization**Specialty:** Pulmonology • Radiology**Objective:** Unusual clinical course**Background:** Although bronchial arteries are the most common cause of hemoptysis, other systemic arteries can cause hemoptysis and are potential pitfalls for successful embolization.**Case Reports:** We present 6 cases of hemoptysis showing vascularization from systemic arteries other than bronchial arteries that presented to our department between 2013 and 2020. Chronic inflammatory diseases such as tuberculosis and pulmonary aspergillosis were the underlying diseases in 4 of the 6 cases. In all 6 cases, the lesions were close to the pleura. The abnormal non-bronchial systemic arteries were the internal thoracic artery in 4 cases, intercostal artery in 2 cases, lateral thoracic artery in 2 cases, and the subclavian, thyrocervical, and inferior phrenic arteries in 1 case each, all of which formed a shunt with the pulmonary artery. Additionally, depending on the location of the lesion, the non-bronchial systemic arteries near the lesion proliferated into the lung parenchyma through the adherent pleura.**Conclusions:** When lesions are in contact with the pleura, various non-bronchial systemic arteries near the lesion can develop in the pulmonary parenchyma via the adherent pleura, which can cause hemoptysis. In patients with hemoptysis, it may be useful to evaluate chest contrast-enhanced computed tomography and angiography, while always accounting for the potential involvement of non-bronchial systemic arteries to ensure a safer and more reliable treatment.**Keywords:** Bronchial Arteries • Embolization, Therapeutic • Hemoptysis • Neovascularization, Physiologic • Pleura • Radiography**Full-text PDF:** <https://www.amjcaserep.com/abstract/index/idArt/933187>


1936



—



8



16

## Background

Hemoptysis can be a life-threatening condition [1,2]. Bronchial arteries are the most common source of hemoptysis, accounting for 90% of cases [3]. However, a variety of other systemic arteries, such as the intercostal artery, internal thoracic artery, subclavian artery, and inferior phrenic artery, can also cause hemoptysis [4,5]. Although non-bronchial systemic supply is a relatively well-known phenomenon, the clinical features of hemoptysis related to systemic arteries other than bronchial arteries are still potential pitfalls for successful embolization.

We present 6 cases of hemoptysis presenting with vascularization from systemic arteries other than bronchial arteries that were recorded at our department between 2013 and 2020.

## Case Reports

### Case 1 (Figures 1, 2A, 3)

A 73-year-old man with a history of tuberculosis was admitted urgently to the hospital with hemoptysis. The patient had multiple cavitary lesions throughout the left lung and a fungus ball on the dorsal side due to chronic pulmonary aspergillosis. The left intercostal artery, inferior phrenic artery, and lateral thoracic artery proliferated around the lesion through the adherent pleura (Figure 2A). The inferior phrenic artery was not embolized because a mild shunt was observed between the inferior phrenic artery and pulmonary artery on angiography. However, the intercostal artery and lateral thoracic artery were embolized in 2 sessions, as both required a different approach. The left intercostal artery was selectively embolized with a gelatin sponge on the day of admission. The lateral thoracic artery was consequently not embolized because the hemoptysis was controlled after embolization. There was no recurrence of hemoptysis 1 month prior to discharge.

### Case 2 (Figures 1, 2B, 4)

A 79-year-old woman was admitted to the hospital after hemoptysis. She had chronic pulmonary aspergillosis after pulmonary tuberculosis. She had been hospitalized for hemoptysis multiple times in the past. Plain chest computed tomography (CT) showed an aspergilloma in the upper lobe of the right lung. Contrast-enhanced CT showed dilated and tortuous vessels around the aspergilloma that were thought to be branches from the bronchial, subclavian, or lateral thoracic arteries (Figure 2B). On the day of admission, she had hemoptysis again and was intubated. The bronchial artery was embolized first; subsequently, the subclavian and lateral thoracic arteries were embolized as they required a different approach. The day after admission, bronchial artery embolization with

gelatin sponge particles was performed on the right bronchial artery. She showed hemoptysis twice after the procedure. Therefore, on day 6, the right bronchial artery, the right lateral thoracic artery, and the branch of the right subclavian artery were embolized with gelatin sponge and coils. However, the blood sputum persisted, and on day 16, she had hemoptysis again. Thereafter, her condition gradually improved, and she was eventually extubated on day 34. There was no recurrence of hemoptysis for a month after extubation, and she was transferred for rehabilitation.

### Case 3 (Figures 1, 2C, 5)

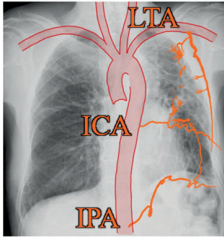

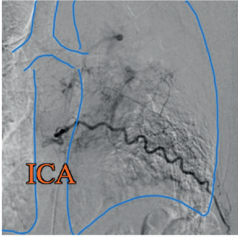
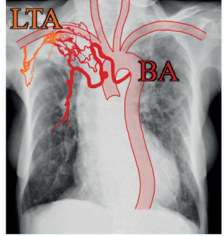
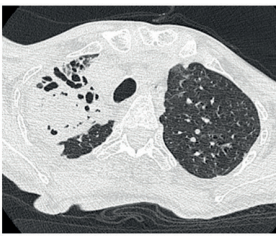
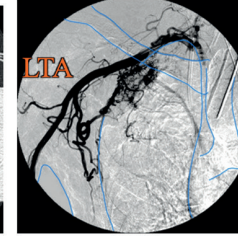
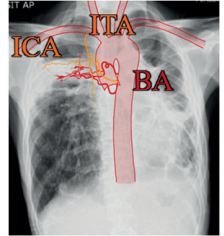
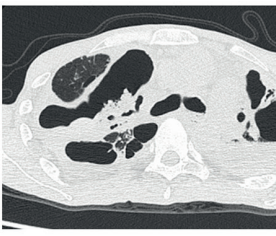
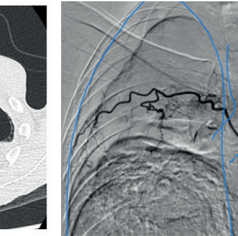
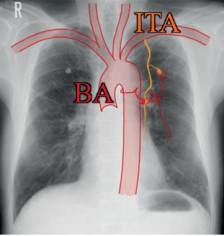
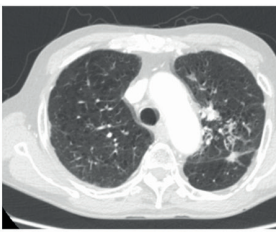
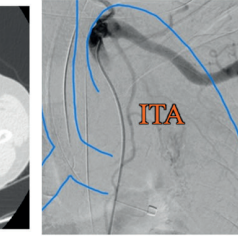
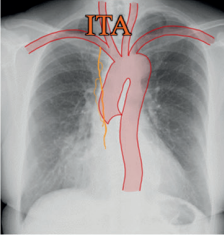


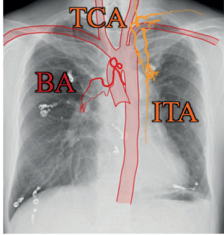
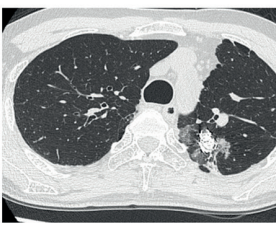
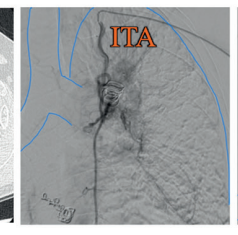
A 45-year-old man with invasive pulmonary aspergillosis after pulmonary tuberculosis was transferred to our hospital with hemoptysis. The patient had cysts with bilateral fluid accumulation in the upper lobes of the lungs, and there were dilated vessels along the pleura on the ventral and dorsal sides of the cyst (Figure 2C). Angiography confirmed that those dilated vessels were 2 bronchial arteries, an intercostal artery, and an internal thoracic artery to the right upper lobe, which shunted to the pulmonary artery. The internal thoracic artery was not embolized because it was distant from the dorsal lesion and required a different approach than did the bronchial and intercostal arteries. The right bronchial artery and the right intercostal artery were embolized with gelatin sponge on the day of admission. On day 16, the patient was transferred to the previous hospital again. He died from hemoptysis due to worsening pulmonary aspergillosis 1.5 years later.

### Case 4 (Figures 1, 2D, 6)

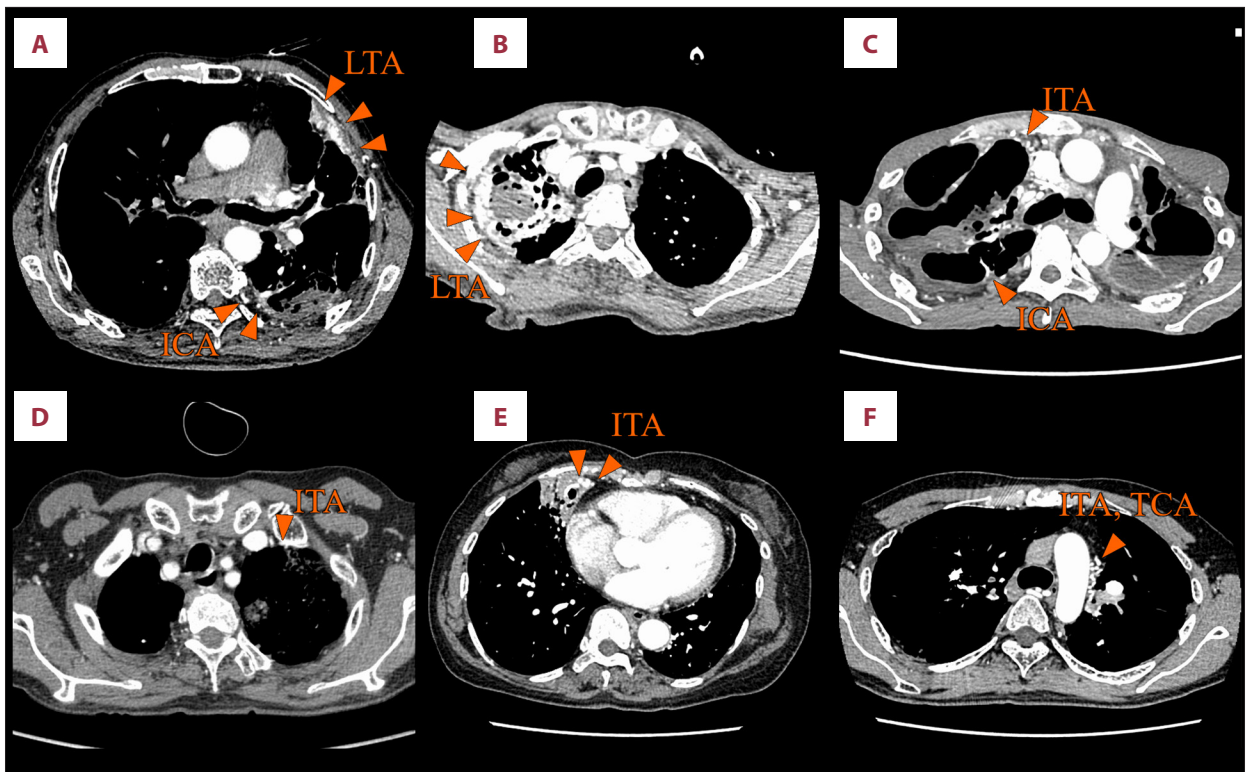
A 76-year-old man with a history of pulmonary tuberculosis and renal cancer was admitted urgently to our hospital with recurrent hemoptysis. The patient had tortuous vessels along the pleura on the anterior side of the left lung upper lobe (Figure 2D). Angiography confirmed that these vessels were the left bronchial artery and the left internal thoracic artery shunted to the pulmonary artery. On the day of admission, bronchial artery embolization with gelatin sponge was performed on the left bronchial artery. The left internal thoracic artery could not be embolized because of difficulty in inserting the catheter. The patient was discharged on day 22 and showed no recurrence of hemoptysis 4 years after discharge.

### Case 5 (Figures 1, 2E, 7)

A 63-year-old woman who was followed up for lymphangioleiomyomatosis was admitted to our hospital with hemoptysis. The patient had dilated vessels along the pleura on the anterior side of the right lung middle lobe (Figure 2E), and 3-dimensional (3D) images of contrast-enhanced chest CT showed a suspected shunt from the right internal thoracic artery to

Case	Age/sex	Chest X-ray shema	Chest CT and angiography	
1	73/Male			
2	79/Female			
3	45/Male			
4	76/Male			
5	63/Female			
6	43/Male			

**Figure 1.** Basic information and imaging findings of the 6 cases. All figures were made with GoodNotes 5®, developed by Time Base Technology Limited (London, United Kingdom). BA – bronchial artery; ICA – intercostal artery; IPA – inferior phrenic artery; ITA – internal thoracic artery; LTA – lateral thoracic artery; TCA – thyroid carotid artery.



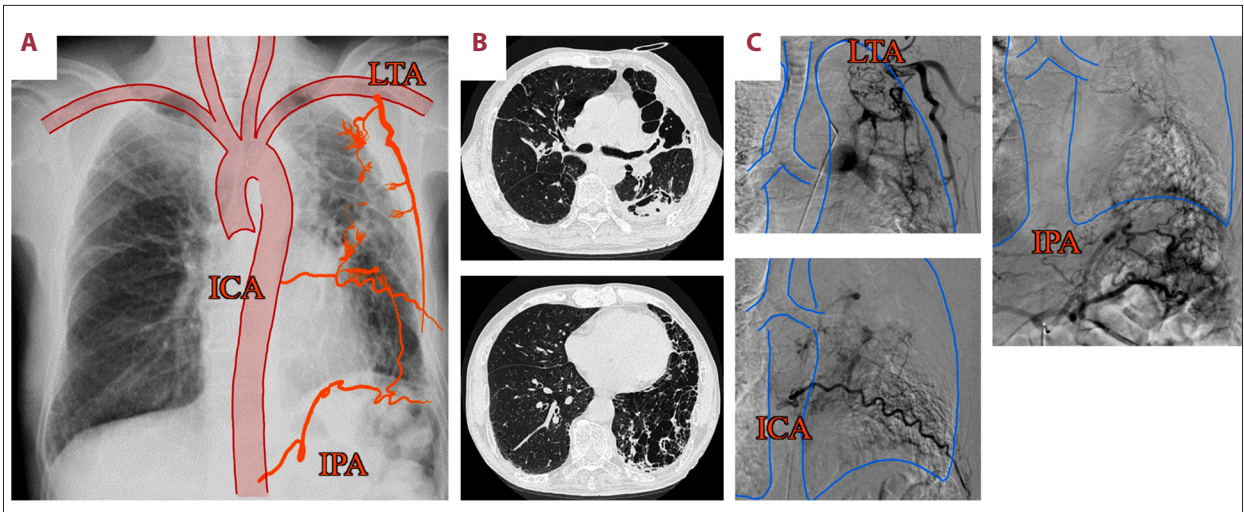
**Figure 2.** Contrast-enhanced computed tomography (CT) findings and the prediction of non-bronchial systemic arterial supply. (A) Contrast-enhanced CT shows pleural thickening and dilated vascular structures, indicating non-bronchial arterial supply in the left lung upper lobe in case 1 (triangle). (B) Contrast-enhanced CT shows pleural thickening and dilated vascular structures, indicating non-bronchial arterial supply in the right lung upper lobe in case 2 (triangle). (C) Contrast-enhanced CT shows pleural thickening and dilated vascular structures, indicating non-bronchial arterial supply in the right lung upper lobe in case 3 (triangle). (D) Contrast-enhanced CT shows dilated and tortuous vascular structures, indicating non-bronchial arterial supply in the left lung upper lobe in case 4 (triangle). (E) Contrast-enhanced CT shows dilated and tortuous vascular structures, indicating non-bronchial arterial supply in the right lung middle lobe in case 5 (triangle). (F) Contrast-enhanced CT shows dilated and tortuous vascular structures within hypertrophic extrapleural fat adjacent to the medial side of the left lung upper lobe, indicating non-bronchial arterial supply in case 6 (triangle). ICA – intercostal artery; ITA – internal thoracic artery; LTA – lateral thoracic artery; TCA – thyroid carotid artery.

the pulmonary artery. The patient refused arterial embolization and was treated with hemostatic agents. On the day of admission, the patient was started on carbazochrome (90 mg/day) and tranexamic acid (750 mg/day). On day 7, the bloody sputum was no longer produced. The patient was discharged on day 9 and showed no recurrence of hemoptysis 3 years after discharge.

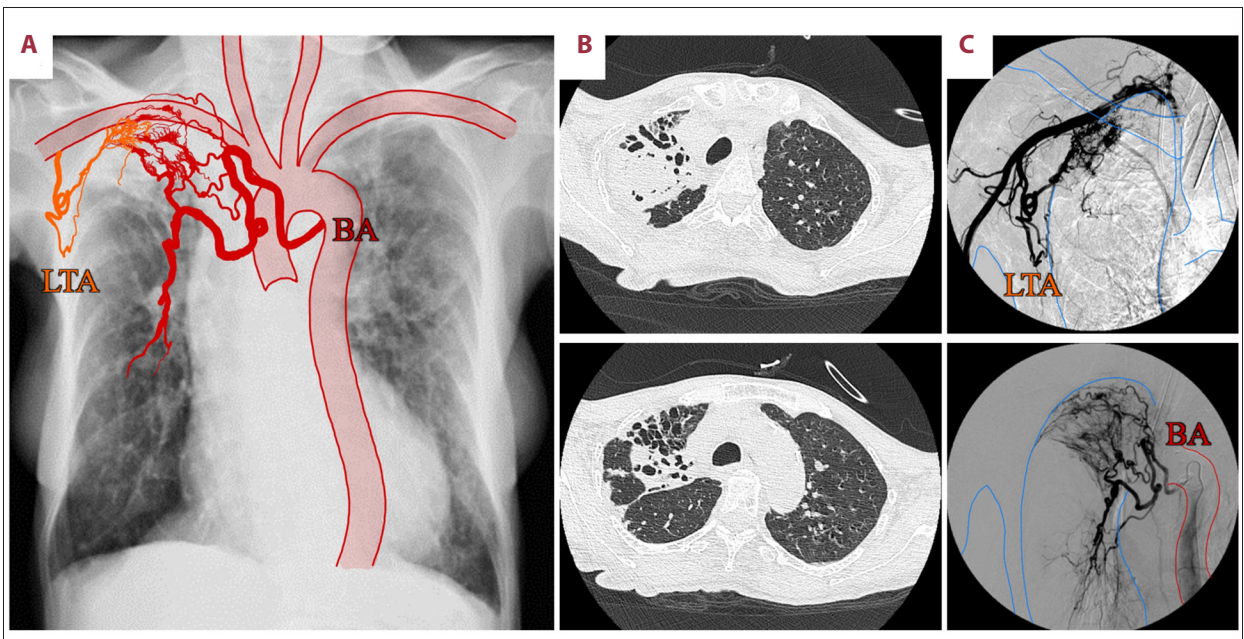
### Case 6 (Figures 1, 2F, 8)

A 43-year-old man with multiple pulmonary arteriovenous malformations (PAVM) due to hereditary hemorrhagic telangiectasia was admitted to the hospital to undergo bronchial artery embolization for hemoptysis. He had undergone left lower lobe anteromedial basal segmentectomy and 3 transcatheter coil embolizations for PAVM 7 years previously. Six years prior to admission, the patient had a history of hemoptysis treated by embolization of the left bronchial artery. Contrast-enhanced

chest CT showed an untreated PAVM at the superior segment and the posterior basal segment of the right lower lobe, with marked dilatation of the bronchial arteries. Bronchial artery embolization with coils was performed on the right bronchial artery, and the patient was discharged the next day. Two months later, the patient showed hemoptysis again and was admitted to our hospital. Chest CT showed worsening of the infiltrating shadow in the area where the coil was implanted in the left upper lobe apicoposterior segment. Contrast-enhanced chest CT showed dilated vessels within hypertrophic extrapleural fat adjacent to the medial side of the left upper lobe (Figure 2F). Both 3D and 4D images of contrast-enhanced chest CT and angiography confirmed that these vessels were branches of the left internal thoracic artery and the left thyroid carotid artery. The branches of the left internal thoracic artery and the left thyroid carotid artery were embolized with coils on the day of admission. The day after the embolization, the patient was discharged. The patient showed no recurrence of hemoptysis 3 years after discharge.



**Figure 3.** (A) Chest radiography combined with a schema showing increased vascularity. (B) Chest computed tomography shows multiple cavitory lesions in contact with the pleura throughout the left lung and a fungus ball on the dorsal side of the left lung upper lobe. (C) Angiography shows proliferation of the lateral thoracic artery, intercostal artery, and inferior phrenic artery flowing into the lesion. ICA – intercostal artery; IPA – inferior phrenic artery; LTA – lateral thoracic artery.

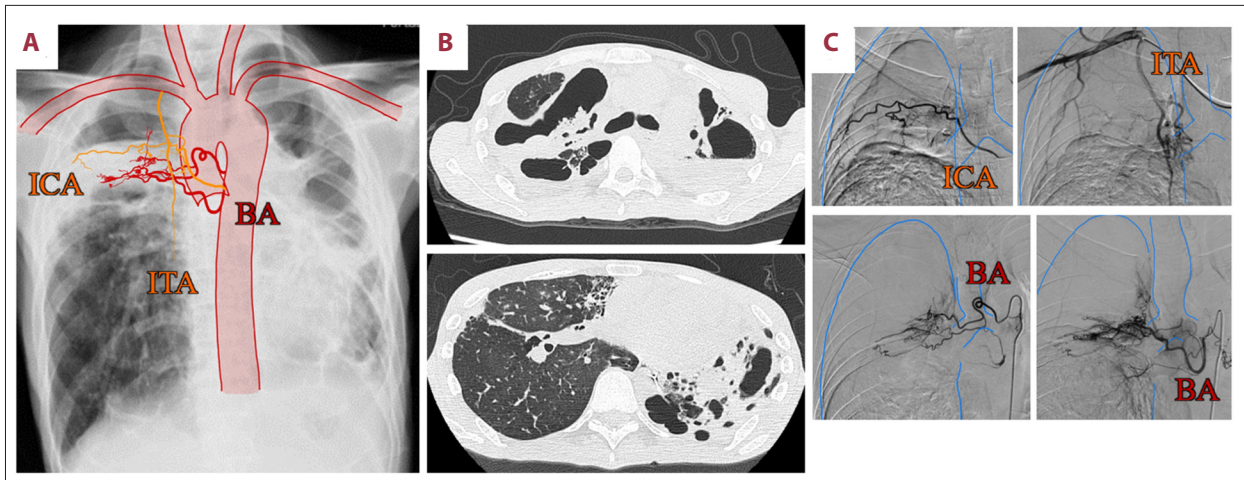


**Figure 4.** (A) Chest radiography combined with a schema showing increased vascularity. (B) Chest computed tomography shows an infiltrative shadow with aspergilloma in contact with the pleura at the apex of the right lung. (C) Angiography shows proliferation of the lateral thoracic artery, and the bronchial artery flowing into the lesion. BA – bronchial artery; LTA – lateral thoracic artery.

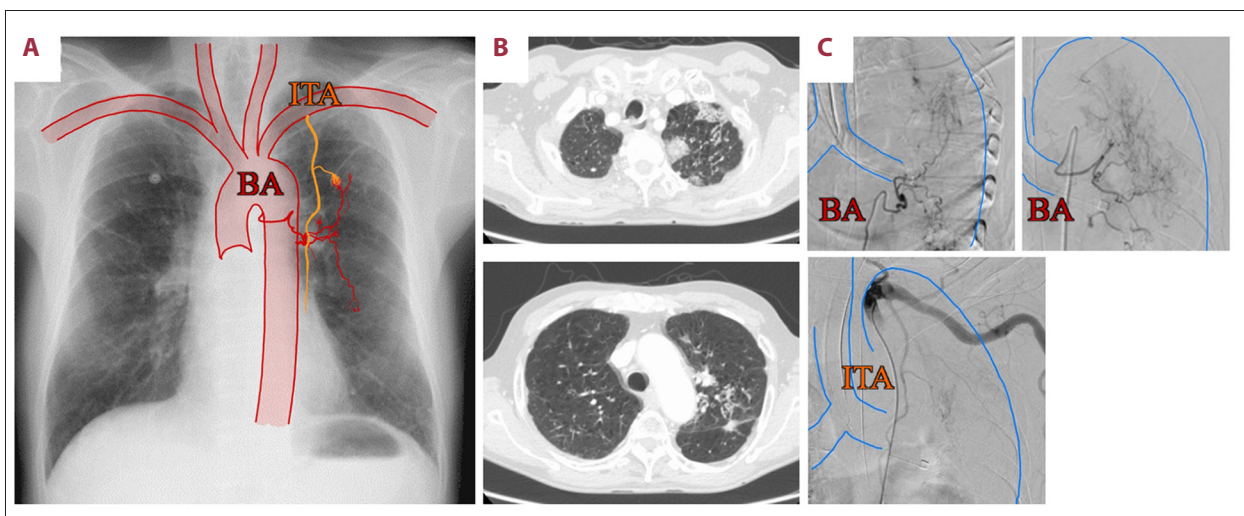
## Discussion

The 6 cases described above reveal several noteworthy findings. Lesions close to the pleura and adhesions between the visceral and the parietal pleurae may allow various systemic arteries other than the bronchial artery to pass through the pleura into the lung parenchyma. The non-bronchial systemic

arteries that have proliferated through the pleura into the pulmonary parenchyma can form a shunt with the pulmonary artery and cause hemoptysis. Contrast-enhanced chest CT and angiography can be useful to identify such non-bronchial systemic arteries that may cause hemoptysis. For a safer and more reliable treatment of hemoptysis, it may be helpful



**Figure 5.** (A) Chest radiography combined with a schema showing increased vascularity. (B) Chest computed tomography shows cysts with fluid accumulation in the bilateral upper lobes of the lung. (C) Angiography shows proliferation of the intercostal artery, internal thoracic artery, and bronchial artery flowing into the lesion. BA – bronchial artery; ICA – intercostal artery; ITA – internal thoracic artery.

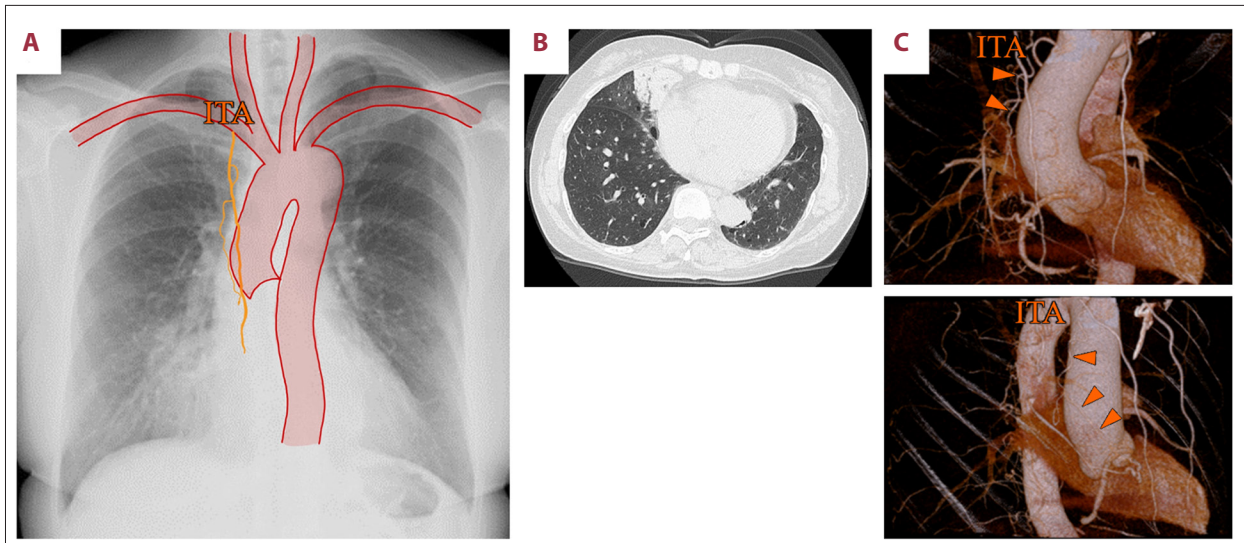


**Figure 6.** (A) Chest radiography combined with a schema showing increased vascularity. (B) Chest computed tomography shows an infiltrative shadow close to the pleura in the upper lobe of the left lung. (C) Angiography shows proliferation of the bronchial artery and internal thoracic artery flowing into the lesion. BA – bronchial artery; ITA – internal thoracic artery.

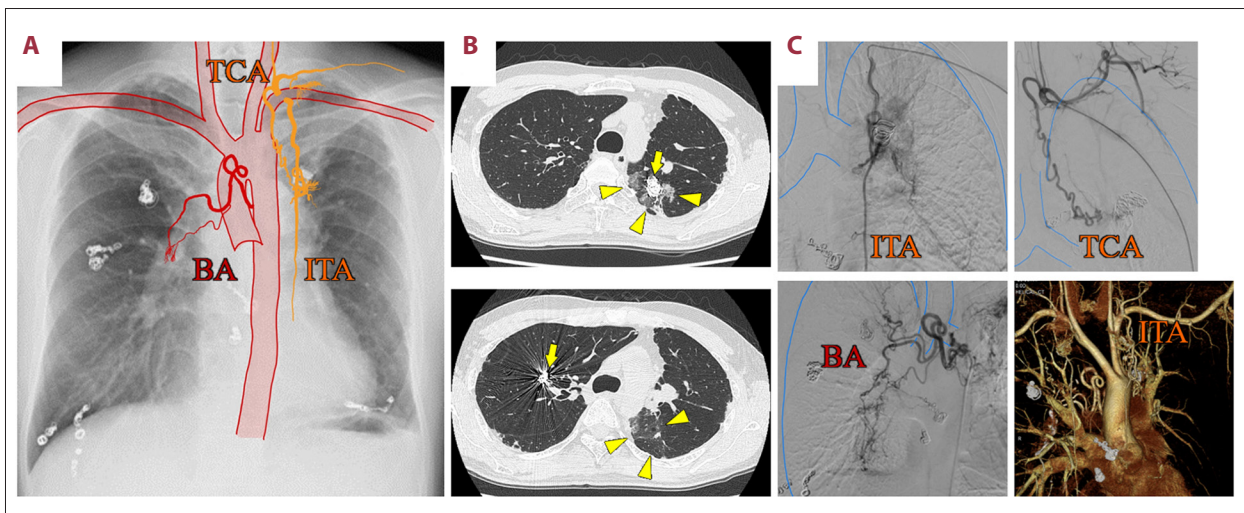
to evaluate contrast-enhanced chest CT while always suspecting non-bronchial systemic artery involvement.

In addition to the bronchial arteries, various systemic arteries around the lungs can also cause hemoptysis. In conditions where the pulmonary circulation is impaired, such as hypoxic vasoconstriction, intravascular thrombosis, and vasculitis, bronchial arteries often proliferate and expand to gradually replace the pulmonary circulation [6-8]. The angiogenic factors produced in chronic inflammatory diseases of the lung promote angiogenesis and microvascular remodeling [9]. The resulting new collateral vessels have fragile walls and are prone to rupture, which can cause hemoptysis [10]. In chronic inflammatory

diseases of the lung, non-bronchial systemic arteries can also reach the lung parenchyma through pleural adhesions formed during the inflammatory process and anastomose with the pulmonary artery circulation [8]. In our cases, chronic inflammatory diseases such as tuberculosis and pulmonary aspergillosis were the underlying diseases in 4 out of 6 cases. In all 6 cases, the lesions were close to the pleura (Figure 1). The abnormal non-bronchial systemic arteries in our cases were the internal thoracic artery in 4 cases, the intercostal artery in 2 cases, the lateral thoracic artery in 2 cases, and the subclavian, thyrocervical, and inferior phrenic arteries in 1 case each, all of which formed a shunt with the pulmonary artery. In addition, the proliferating non-bronchial systemic arteries



**Figure 7.** (A) Chest radiography combined with a schema showing increased vascularity. (B) Chest computed tomography (CT) shows a ground-glass opacity associated with hemorrhage in contact with the pleura on the right lung middle lobe medial segment. (C) Three-dimensional CT shows a suspected shunt from the right internal thoracic artery (triangle) to the pulmonary artery. ITA – internal thoracic artery.



**Figure 8.** (A) Chest radiography combined with a schema showing increased vascularity. (B) Chest computed tomography (CT) shows treated pulmonary arteriovenous malformations at the left and right upper lobe (arrow). Two months after the initial embolization, chest CT shows a worsening infiltrating shadow in contact with the pleura in the left lung upper lobe (triangle). (C) Angiography shows proliferation of the bronchial artery, internal thoracic artery, and thyroid carotid artery flowing into the lesion. Four-dimensional CT also shows the dilated and tortuous left ITA flowing into the lesion. ITA – internal thoracic artery; TCA – thyroid carotid artery.

depended on the location of the lesion. Therefore, when the lesion is in the lung parenchyma, especially when it is close to the pleura, it may be more likely to cause proliferation of non-bronchial systemic arteries near the lesion. Such non-bronchial systemic arteries can form a shunt with the pulmonary artery, which can cause hemoptysis. It is difficult to show the course of multiple tiny vessels using CT. While angiography can show the vessels in detail, it can show the vessels only

individually. Therefore, there has been no report showing the whole picture of the course of multiple abnormal vessels in a single figure. In the present study, the complexity of chronic inflammatory lesions and vascular growth in contact with the chest wall was clarified by combining the abnormal vascularization and lesions in a single schematic diagram in each case. When performing arterial embolization, it is important to pay attention to the complex vascularization around the lesion.

Recognizing the presence of non-bronchial systemic arteries that can cause hemoptysis can be helpful for safer and more reliable treatment of hemoptysis. The treatment of hemoptysis includes bronchial artery embolization, surgery, and bronchoscopy [11]. Bronchial artery embolization is the most effective treatment for hemoptysis [12,13]. Incomplete embolization of the non-bronchial systemic artery can lead to recurrent hemoptysis after embolization [14]. Yoon et al reported that contrast-enhanced CT findings of pleural thickening adjacent to lesions in the lung parenchyma and enlarged vascular structures within the extrapleural fat indicate the involvement of non-bronchial systemic arteries in patients with hemoptysis [15]. In all our cases, contrast-enhanced CT showed pleural thickening and dilated and tortuous vessels (Figure 2). Even in cases where a non-bronchial systemic artery was difficult to evaluate by contrast-enhanced CT, it could be identified by angiography. Thus, contrast-enhanced CT and angiography can be useful to identify the presence of such non-bronchial systemic arteries that can cause hemoptysis. Pre-evaluation of the non-bronchial systemic artery by CT can minimize the contrast load and fluoroscopic radiation dose in angiography [16]. Additionally, the detailed evaluation of the vascular course using CT and angiography before arterial embolization might increase the procedure's safety and reduce its risk of complications. Moreover,

there were no complications observed in any of the 5 patients who underwent arterial embolization. Therefore, for safer and more reliable treatment of hemoptysis, it may be helpful to evaluate contrast-enhanced CT, while always suspecting non-bronchial systemic artery involvement.

## Conclusions

Here, we presented 6 cases of hemoptysis showing vascularization from systemic arteries other than the bronchial arteries. When the lesions are in contact with the pleura, various non-bronchial systemic arteries near the lesion can develop in the pulmonary parenchyma via the adherent pleura, which can cause hemoptysis. In patients with hemoptysis, it can be helpful to evaluate contrast-enhanced chest CT and angiography and always account for the involvement of non-bronchial systemic artery for a safer and more reliable treatment.

## Declaration of Figures Authenticity

All figures submitted have been created by the authors who confirm that the images are original with no duplication and have not been previously published in whole or in part.

## References:

1. Knott-Craig CJ, Oosthuizen JG, Rossouw G, et al. Management and prognosis of massive hemoptysis. Recent experience with 120 patients. *J Thorac Cardiovasc Surg.* 1993;105:394-97
2. Sakr L, Dutau H. Massive hemoptysis: An update on the role of bronchoscopy in diagnosis and management. *Respiration.* 2010;80:38-58
3. Yoon W, Kim JK, Kim YH, et al. Bronchial and nonbronchial systemic artery embolization for life-threatening hemoptysis: A comprehensive review. *Radiographics.* 2002;22:1395-409
4. Ponnuswamy I, Sankaravadeivelu ST, Maduraimuthu P, et al. 64-detector row CT evaluation of bronchial and non-bronchial systemic arteries in life-threatening haemoptysis. *Br J Radiol.* 2012;85:e666-72
5. Zhang J, Zheng L, Zhao T, et al. A retrospective analysis of risk factors in recurrent hemoptysis patients with non-bronchial systemic artery feeding. *Ann Transl Med.* 2020;8:1593
6. Malik AB, Tracy SE. Bronchovascular adjustments after pulmonary embolism. *J Appl Physiol Respir Environ Exerc Physiol.* 1980;49:476-81
7. Deffebach ME, Charan NB, Lakshminarayan S, Butler J. The bronchial circulation. Small, but a vital attribute of the lung. *Am Rev Respir Dis.* 1987;135:463-81
8. Bruzzi JF, Rémy-Jardin M, Delhay D, et al. Multi-detector row CT of hemoptysis. *Radiographics.* 2006;26:3-22
9. McDonald DM. Angiogenesis and remodeling of airway vasculature in chronic inflammation. *Am J Respir Crit Care Med.* 2001;164:S39-45
10. Larici AR, Franchi P, Occhipinti M, et al. Diagnosis and management of hemoptysis. *Diagn Interv Radiol.* 2014;20:299-309
11. Kathuria H, Hollingsworth HM, Vilvendhan R, Reardon C. Management of life-threatening hemoptysis. *J Intensive Care.* 2020;8:23
12. Rémy J, Arnaud A, Fardou H, et al. Treatment of hemoptysis by embolization of bronchial arteries. *Radiology.* 1977;122:33-37
13. Shigemura N, Wan IY, Yu SC, et al. Multidisciplinary management of life-threatening massive hemoptysis: A 10-year experience. *Ann Thorac Surg.* 2009;87:849-53
14. Ando T, Kawashima M, Masuda K, et al. Exacerbation of chronic pulmonary aspergillosis was associated with a high rebleeding rate after bronchial artery embolization. *Respir Investig.* 2019;57:260-67
15. Yoon W, Kim YH, Kim JK, et al. Massive hemoptysis: Prediction of nonbronchial systemic arterial supply with chest CT. *Radiology.* 2003;227:232-38
16. Noë GD, Jaffé SM, Molan MP. CT and CT angiography in massive haemoptysis with emphasis on pre-embolization assessment. *Clin Radiol.* 2011;66:869-75