

HOSTED BY



ELSEVIER

Contents lists available at ScienceDirect

Chinese Journal of Traumatology

journal homepage: <http://www.elsevier.com/locate/CJTEE>

Original article

Comparative study of multiple cancellous screws versus sliding hip screws in femoral neck fractures of young adults

Mayank Gupta, Rajendra Kumar Arya*, Satish Kumar, Vijay Kumar Jain, Skand Sinha, Ananta Kumar Naik

Department of Orthopedics, Post Graduate Institute of Medical Education and Research, Dr Ram Manohar Lohia Hospital, New Delhi 110001, India

ARTICLE INFO

Article history:

Received 30 September 2015

Received in revised form

3 November 2015

Accepted 20 November 2015

Available online 13 May 2016

Keywords:

Femoral neck fractures

Bone screws

Young adult

ABSTRACT

Purpose: Both cannulated cancellous screw (CCS) and sliding hip screw (SHS) are used in femoral neck fracture fixations, but which is superior is yet to be determined. This study was aimed to compare the clinicoradiological outcome of femoral neck fracture treated with SHS or CCS in young adults.

Methods: Adults (16–60 years) with femoral neck fracture were divided into Group 1 fixed with SHS and Group 2 fixed with three CCS after closed reduction. Pain relief, functional recovery and postoperative radiographs at 6 weeks, 3 months, 6 months and then yearly for upto 4 years were analyzed.

Results: Group 1 ($n = 40$) achieved radiological union at mean of 7.6 months, with the union rate of 87.5% ($n = 35$), avascular necrosis (AVN) rate of 7.5% ($n = 3$) and mean Harris Hip Score (HHS) of 86.15 at the end of 4 years. In Group 2 ($n = 45$) these parameters were union at 7.1 months, union rate of 82.22% ($n = 37$), AVN rate of 6.67% ($n = 3$) and HHS of 88.65. Comparative results were statistically insignificant.

Conclusion: There is no significant difference in clinicoradiological outcome between the two implants.

© 2016 Daping Hospital and the Research Institute of Surgery of the Third Military Medical University.

Production and hosting by Elsevier B.V. This is an open access article under the CC BY-NC-ND license (<http://creativecommons.org/licenses/by-nc-nd/4.0/>).

Introduction

Femoral neck fracture has always been 'the unsolved fracture' as far as treatment and results are concerned.¹ Most femoral neck fractures occur in elderly individuals where much attention has been focused, while the same fracture in young adults has been less considered. A fracture of the femoral neck in a young adult differs from the same fracture in an older patient in many respects. They account for only 2%–3% in young population where they usually result from high energy trauma² and hence are more difficult to treat and are associated with more complications like nonunion and osteonecrosis.³

Treatment options include arthroplasty in older individuals but for young patients anatomical reduction and internal fixation have to be relied upon. Mostly cannulated cancellous screws (CCS) or a sliding hip screw (SHS) are used for osteosynthesis of these fractures. Fixation with both CCS and SHS has achieved good results, but which method is superior is yet to be determined. There has been a paucity of randomized trials directly comparing SHS (along

with a derotation screw) and three CCS in femoral neck fractures at any level. Also to date no studies have compared the two implants with respect to the anatomical type of femoral neck fractures separately. To fill this lacuna in the present knowledge, this study was aimed to compare the clinicoradiological outcome of femoral neck fracture treated with SHS or CCS in young adults.

Materials and methods

A prospective comparative study was done in our department to evaluate the results of fixation of femoral neck fracture for four year duration from June 2010 to December 2014. The study was conducted after taking clearance from the review board of our institution and university. All patients with a fracture of the femoral neck sustained within the last 3 weeks, as diagnosed on a plain radiograph of the pelvis with both hips in anteroposterior view, falling in the age group of 16–60 years were taken as cases. The exclusion criteria were patients with polytrauma, life threatening injuries or with other injuries in the same limb. The patients were divided into two groups by a simple randomization method. Group 1 was designated as the SHS group and Group 2 as the CCS group and the implant for fixation was accordingly decided.

After taking appropriate consent from the patients, investigations required for anesthesia for the contemplated surgical

* Corresponding author. Tel.: +91 98 68164333.

E-mail address: draryark@gmail.com (R.K. Arya).

Peer review under responsibility of Daping Hospital and the Research Institute of Surgery of the Third Military Medical University.

procedure were done to assess their fitness. The delay between trauma and surgery was noted. All patients received intravenous ceftriaxone (1 g) and gentamicin sulfate (80 mg) before the procedure and for at least 72 h postoperatively. Under regional anesthesia or general anesthesia the procedure was carried out on a standard orthopedic fracture table in supine position. Closed reduction was achieved under fluoroscopic control. Only the fractures treated by closed reduction were included. Fractures requiring open reduction were excluded from the study. Fixation with SHS was done through standard lateral approach using a Richard's screw and 4 hole 135° angled barrel plate which was fixed to the proximal femoral shaft with cortical screws. A 6.5 mm cannulated cancellous partially threaded derotation screw was inserted superiorly before reaming for the SHS. Fixation with CCS was done using three 6.5 mm partially threaded screws inserted parallel in an inverted triangle configuration through small stab incisions or using a small lateral incision. Intraoperative blood loss, operative time and incision size were noted in both the groups. Under the supervision of physiotherapists, toe-touch weight bearing mobilization was started using crutches or walker on the second or third day postoperatively in both the groups and the patients were followed up at 6 weeks, 3 months, 6 months and then yearly for up to four years after the operation to note the clinicoradiological outcome.

Clinical outcome was assessed in the terms of pain relief and functional recovery using the Harris Hip Score (HHS). Radiological union was assessed using plain radiographs of the pelvis in an anteroposterior view with hips in 15°–20° internal rotation and lateral frog-leg views of the involved hip. Radiographically visible trabeculations across the fracture line were considered as union, whereas no radiographically visible trabeculations across the fracture line, or redisplacement of the fracture or progressive displacement requiring a second operation were considered nonunion. When sound bony union was achieved as ensured by the radiograph, full weight bearing was allowed. Complications were recorded like infection, implant failure in the form of breakage of the implant, loosening or migration of the implant, nonunion and avascular necrosis (AVN). Any patient requiring a second procedure in the form of revision surgery, osteotomy or arthroplasty were included only upto the follow-up for the primary procedure. Data of the patients who died postoperatively or were lost to follow-up were included upto the last follow-up available. Statistical test was performed using the SPSS version 15.0 software.

Results

The total number of patients included in this study was 85. Forty patients belonged to Group 1 and 45 to Group 2. Various clinicoradiological parameters are shown in Table 1. Around 90% of the patients had fractures due to high energy trauma like fall from height or stairs or motor vehicle accidents and 10% had a trivial trauma like slip on floor.

The intraoperative parameters including mean blood loss, incision size and operative time were found to be statistically significant between the two groups. Radiological union was achieved at a mean of 7.6 months in Group 1 and 7.1 months in Group 2 (Figs. 1 and 2). There was no statistically significant difference between the two groups in mean delay between trauma and surgery, postoperative Garden alignment index, and union rate (Table 1). Additionally there was no significant difference in the functional outcome between the two groups taking into account the HHS at each postoperative visit at 6 weeks, 3 months, 6 months, 1 year, 2 years and 4 years.

Considering postoperative complications (Fig. 3, Table 2), two patients in Group 1 but none in Group 2 had infection. Both patients

Table 1
Various clinicoradiological parameters in Group 1 and Group 2.

Parameters	Group 1	Group 2	p value
Number of patients	40	45	
Mean age (years)	40.7 (16–60)	39.3 (16–60)	
Male: female	23:17	32:13	
Fracture type			
Subcapital	12 (30%)	13 (28.9%)	
Transcervical	20 (50%)	25 (55.6%)	
BASICERVICAL	8 (20%)	7 (15.5%)	
Garden's classification			
Type 1	0	1 (22.2%)	
Type 2	2 (5%)	2 (44.4%)	
Type 3	23 (57.5%)	28 (62.2%)	
Type 4	15 (37.5%)	14 (31.2%)	
Mean preoperative delay (d)	4.5 (8 h–17 d)	2.5 (6 h–9 d)	=0.104
Mean intraoperative blood loss (ml)	200 (100–400)	67.4 (30–150)	<0.001
Mean operative time (min)	111 (45–240)	61.6 (30–120)	<0.001
Average incision size (cm)	12.6 (8–20)	3.9 (2.5–5.5)	<0.001
Average follow-up (months)	40.7 (1.5–48)	39.3 (1.5–48)	
Mean Garden alignment index			
Anteroposterior	165°	167°	=0.451
Lateral	166°	165°	=0.689
Radiological union (months)	7.6	7.1	=0.652
Union rate	87.5% (n = 35)	82.22% (n = 37)	=0.09
Mean Harris Hip Score (at 48 months)	86.15	88.65	=0.46

had a late infection and implants were removed at 1 year. One attained union but other showed nonunion and excision arthroplasty was performed in this patient. Implant related complications, backing-out of screws, screw bending, or screw cut-out were found in 5 patients in Group 1 and 4 patients in Group 2. Three patients in Group 1 had backing-out of derotation screw but attained union after which it was removed and 2 patients had Richard screw cut-out through the neck and one was treated with hemiarthroplasty. During second surgery the head was found completely hollow and non salvageable due to the Richard screw cut-out at 6 weeks and the other was the same patient who had persistent infection for which excision arthroplasty was performed at 1 year. In Group 2, two patients had CCS backing-out but attained union. At an average of 9 months one patient had CCS backing-out with nonunion for which valgus osteotomy and fixation with angled blade plate were carried out at 6 months, but this procedure also failed and later hemiarthroplasty was performed at 1 year. One patient had CCS backing-out, CCS bending, nonunion and AVN but was lost to follow-up at 1 year. One patient in Group 2 died due to some reasons not related to the surgery before 6 months of postoperative period. Three patients showed radiologically visible changes of AVN in Group 1 at an average of 24 months duration and 3 in Group 2 at an average of 12 months. All differences were insignificant statistically ($p = 0.809$). In Group 1 all AVN patients were managed conservatively. Two patients in Group 2 who had AVN along with nonunion were lost to follow-up at 12 months and the third was managed conservatively.

Discussion

Results after fixation of femoral neck fractures primarily depend upon age of the patient, amount of displacement, adequacy of reduction and adequacy of internal fixation. Determination of chronological and physiological age of the patient is important to formulate a treatment plan. Internal fixation is favored than arthroplasty in young patients considering the need for revision of arthroplasty in their lifetime and also preservation of the native bone.^{4,5}

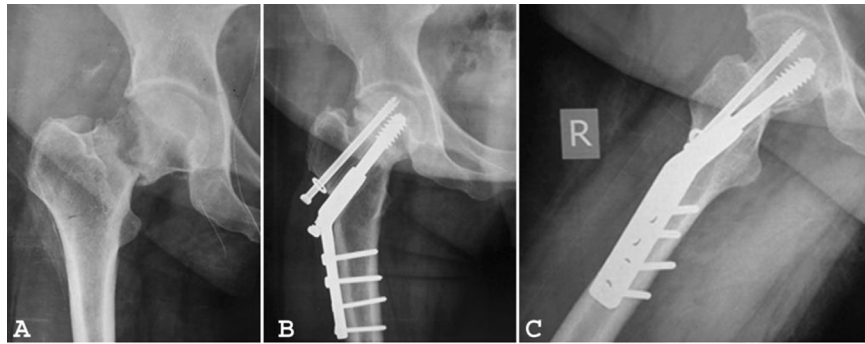


Fig. 1. A: Preoperative radiograph of a patient showing a transcervical neck fracture. B: Anteroposterior radiograph at 1 year after fixation with sliding hip screw along with a derotation screw showing union. C: Lateral radiograph at 1 year after fixation with sliding hip screw along with a derotation screw showing union.

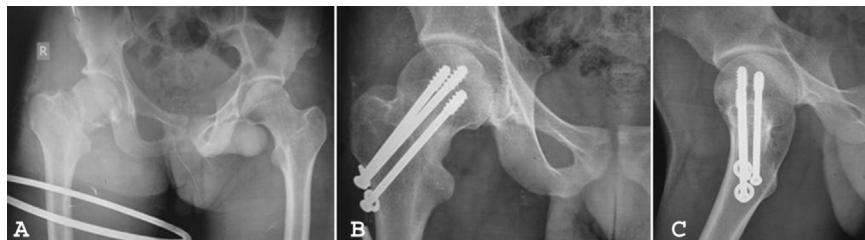


Fig. 2. A: Anteroposterior radiograph of the pelvis with both hips of a patient showing right sided transcervical femoral neck fracture. B: Anteroposterior radiograph at 1 year after fixation with cannulated cancellous screws showing union. C: Lateral radiograph at 1 year after fixation with cannulated cancellous screws showing union.

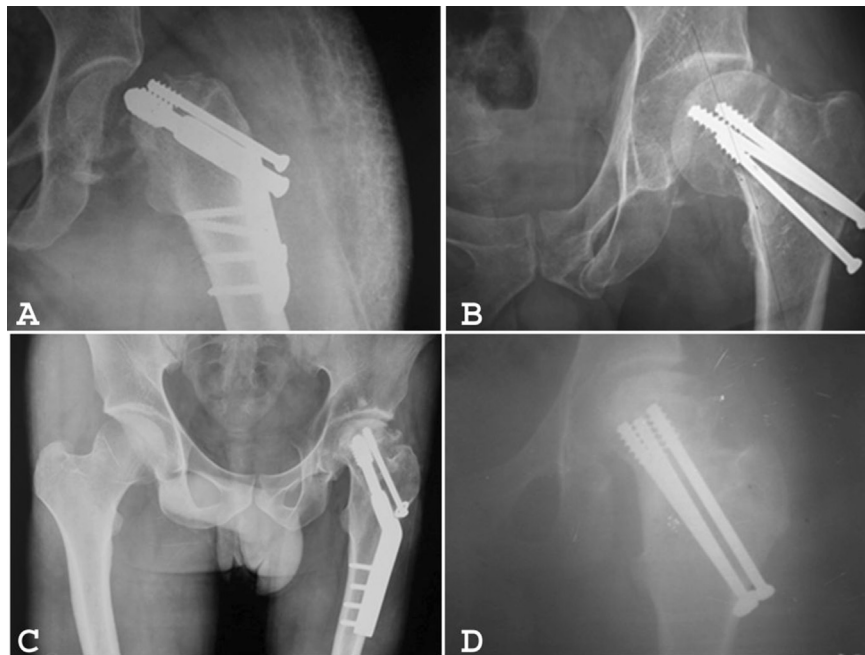

Fig. 3. A: Cutting through of the sliding hip screw from the femoral neck at 6 weeks after fixation. B: Implant failure 6 weeks after fixation with CCS. C: Avascular necrosis in a patient detected 2 years after fixation with sliding hip screw. The fracture has united. D: Avascular necrosis in a patient detected 1 year after fixation with CCS. The fracture has united.

Table 2
Postoperative complications in two groups.

Complication	Group 1 (n = 40)	Group 2 (n = 45)
Infection	2 (5%)	0
Nonunion	5 (12.5%)	8 (17.78%)
AVN	3 (7.5%)	3 (6.67%)
Implant related	5 (12.5%)	4 (8.89%)

The method of internal fixation has an effect on the rates of union and osteonecrosis in femoral neck fractures. The two implants which have been traditionally used but have not been widely compared for these fractures are SHS and CCS. Currently the most common fixation technique described for femoral neck fractures is lag screw fixation using three CCS. In a review of femoral neck fractures in young patients, Kyle determined that the most consistent results were obtained with internal fixation using

multiple cancellous screws.⁶ The position of screws should be parallel which induces compressive forces that stimulate healing.^{7,8} Arnold et al reported that a lack of parallelism with multiple pins may prevent impaction until pin fracture occurred.⁹ SHS overcomes the complication of lack of parallelism associated with CCS, as well as allows effective intraoperative compression; however its use alone has not been previously recommended as poor fixation and loss of reduction may occur due to lack of control of the proximal fragment which may spin during the insertion of the lag screw. Rau et al observed this complication in 20% of their cases.¹⁰ Thus derotation screw should be inserted before SHS in neck fractures. SHS and derotation screw combination comprises a multiplicity of screws, required for rotational stability and sliding capacity, and controlled impaction. SHS performed better in osteoporotic bone and was less sensitive to decline in bone mineral density. CCS failure may occur with bending and vertical shear loads, i.e. with weight bearing. SHS has shown greater fracture stability and superior biomechanical properties as compared to CCS in cadaveric models.

CCS insertion is more biological as it causes limited disruption of femoral head blood supply and can be inserted using minimally invasive surgery.¹¹ These small diameter screws can retain more viable bone after insertion which optimizes vascularity and may reduce the risk of AVN.¹² The CCS fixation method, which has lower operation times, also shortens anesthesia time and thus prevents the possible complications of anesthesia. In the present study the blood loss during cannulated screw fixation in Group 2 was lower than in the Group 1 in which SHS was applied. It has been reported earlier that use of cannulated screws for femoral neck fractures causes lower blood loss during operation.¹¹ In addition several studies have reported that application of SHS for these fractures causes prolonged operation and more blood loss, which supports the results of our study.^{12,13}

The functional results according to HHS were found to be similar in both groups at each postoperative visit in our study. Kaplan et al also concluded that there were no significantly different statistical results according to HHS between the groups of patients treated with either SHS or CCS.¹³ Kuokkanen et al also evaluated their functional results according to this scoring system. They also concluded that there was no difference in the functional outcome between the two implants. But their study included only undisplaced fractures.¹⁴

The overall nonunion rate in our study was 15.29% and AVN rate was 7% combining both groups. A recent meta-analysis on complications of femoral neck fractures in young adults involving 564 fractures estimated the overall nonunion rates to be 8.9% and AVN rate to be 23%.¹⁵ This high nonunion rate in our study may possibly be multifactorial, as most of our patients were injured due to high velocity trauma, had displaced fractures and had surgical delay. The nonunion rate in SHS group was 12.5% and in the CCS group was 17.78% in our study. In a recent study by Kaplan et al, the nonunion rates were 9% for the SHS group and 3% for the CCS group.¹³ These were also not statistically significant as in our study. Almost all AVN occurred in displaced fractures (Garden types 3 or 4) in our study. The AVN rate was 7.5% with SHS and 6.67% with CCS. The difference in AVN rate was statistically insignificant among the two groups. Hence, AVN is directly related to the amount of fracture

displacement rather than the fixation method used. Stromqvist et al found that the method of fixation influenced the vascularization of the femoral head. They showed that SHS fixation was associated with a higher number of avascular femoral heads than CCS.^{16,17} However our study does not support this hypothesis.

There were limitations in present study. Firstly, the surgeries were performed by different surgeons with differing operative skills and this could have affected the treatment outcome. Secondly, sample size was relatively small. Also we believe that because the cases were done with closed reduction and not open reduction and internal fixation, the reductions probably were not as accurate as they could have been and this has led to a high nonunion rate which is much higher than other series in the literature. We suggest that further studies with more number of patients should be done to consolidate our findings.

We conclude that CCS does have an advantage over SHS in terms of blood loss, operating time and incision size but there is no significant difference between the two implants in their clinicoradiological outcome. Femoral neck fracture still remains 'the unsolved fracture' as it has rightly been previously called.

References

- Dickson JA. The unsolved fracture of protest against defeatism. *J Bone Jt Surg Am.* 1953;35:805–822.
- Robinson CM, Court-Brown CM, Mc Queen MM, et al. Hip fractures in adults younger than 50 years of age. Epidemiology and results. *Clin Orthop Relat Res.* 1995;312:238–246.
- Dedrick DK, Mackenzie JR, Burney RE. Complications of femoral neck fracture in young adults. *J Trauma.* 1986;26:932–937.
- Shah AK, Eissler J, Radomisli T. Algorithms for the treatment of femoral neck fractures. *Clin Orthop Relat Res.* 2002;399:28–34.
- Schmidt AH, Swiontkowski MF. Femoral neck fractures. *Orthop Clin North Am.* 2002;33:97–111.
- Kyle RF. Operative techniques of fixation for femoral neck fractures in young adults. *Tech Orthop.* 1986;1:33.
- Swiontkowski MF, Winquist RA, Hansen Jr ST. Fractures of the femoral neck in patients between the ages of twelve and forty-nine years. *J Bone Jt Surg Am.* 1984;66:837–846.
- Skinner PW, Powles D. Compression screw fixation for displaced subcapital fracture of the femur. Success or failure? *J Bone Jt Surg Br.* 1986;68:78–82.
- Arnold WD, Lyden JP, Minkoff J. Treatment of intracapsular fractures of the femoral neck. With special reference to percutaneous Knowels pinning. *J Bone Jt Surg Am.* 1974;56:254–262.
- Rau FD, Manoli 2nd A, Morawa LG. Treatment of femoral neck fractures with the sliding compression screw. *Clin Orthop Relat Res.* 1982;163:137–140.
- Swiontkowski MF, Winquist RA. Displaced hip fractures in children and adolescents. *J Trauma.* 1986;26:384–388.
- Madsen F, Linde F, Anderson E, et al. Fixation of displaced femoral neck fractures. A comparison between sliding screw plate and four cancellous bone screws. *Acta Orthop Scand.* 1987;58:212–216.
- Kaplan T, Akesen B, Demirag B, et al. Comparative results of percutaneous cannulated screws, dynamic compression type plate and screw for the treatment of femoral neck fractures. *Ulus Travma Acil Cerrahi Derg.* 2012;18:65–70.
- Kuokkanen H, Korkkala O, Antti-Poika I, et al. Three cancellous bone screws versus a screw-angle plate in the treatment of garden I and II fractures of the femoral neck. *Acta Orthop Belg.* 1991;57:53–57.
- Damany DS, Parker MJ, Chojnowski A. Complications after intracapsular hip fractures in young adults. A meta-analysis of 18 published studies involving 564 fractures. *Injury.* 2005;36:131–141.
- Stromqvist B, Hansson LI, Nilsson LT, et al. Two-year follow-up of femoral neck fractures: comparison of osteosynthesis methods. *Acta Orthop Scand.* 1984;55:521–525.
- Stromqvist B, Hansson LI, Palmer J, et al. Scintimetric evaluation of nailed femoral neck fractures with special reference to type of osteosynthesis. *Acta Orthop Scand.* 1983;54:340–347.