



# Magnetoencephalographic study of hand and foot sensorimotor organization in 325 consecutive patients evaluated for tumor or epilepsy surgery



Ronald B. Willemse<sup>a,\*</sup>, Arjan Hillebrand<sup>b</sup>, Hanneke E. Ronner<sup>b</sup>, W. Peter Vandertop<sup>a</sup>, Cornelis J. Stam<sup>b</sup>

<sup>a</sup> Neurosurgical Center Amsterdam, VU University Medical Center, Amsterdam, The Netherlands

<sup>b</sup> Department of Clinical Neurophysiology and MEG Center, VU University Medical Center, Amsterdam, The Netherlands

## ARTICLE INFO

### Article history:

Received 14 August 2015

Received in revised form 30 October 2015

Accepted 4 November 2015

Available online 7 November 2015

### Keywords:

Brain mapping

Brain neoplasms

Cortical reorganization

Epilepsy

Magnetoencephalography

## ABSTRACT

**Objectives:** The presence of intracranial lesions or epilepsy may lead to functional reorganization and hemispheric lateralization. We applied a clinical magnetoencephalography (MEG) protocol for the localization of the contralateral and ipsilateral S1 and M1 of the foot and hand in patients with non-lesional epilepsy, stroke, developmental brain injury, traumatic brain injury and brain tumors. We investigated whether differences in activation patterns could be related to underlying pathology.

**Methods:** Using dipole fitting, we localized the sources underlying sensory and motor evoked magnetic fields (SEFs and MEFs) of both hands and feet following unilateral stimulation of the median nerve (MN) and posterior tibial nerve (PTN) in 325 consecutive patients. The primary motor cortex was localized using beamforming following a self-paced repetitive motor task for each hand and foot.

**Results:** The success rate for motor and sensory localization for the feet was significantly lower than for the hands (*motor\_hand* 94.6% versus *motor\_feet* 81.8%,  $p < 0.001$ ; *sensory\_hand* 95.3% versus *sensory\_feet* 76.0%,  $p < 0.001$ ). MN and PTN stimulation activated 86.6% in the contralateral S1, with ipsilateral activation  $< 0.5\%$ . Motor cortex activation localized contralaterally in 76.1% (5.2% ipsilateral, 7.6% bilateral and 11.1% failures) of all motor MEG recordings. The ipsilateral motor responses were found in 43 (14%) out of 308 patients with motor recordings (range: 8.3–50%, depending on the underlying pathology), and had a higher occurrence in the foot than in the hand (*motor\_foot* 44.8% versus *motor\_hand* 29.6%,  $p = 0.031$ ). Ipsilateral motor responses tended to be more frequent in patients with a history of stroke, traumatic brain injury (TBI) or developmental brain lesions ( $p = 0.063$ ).

**Conclusions:** MEG localization of sensorimotor cortex activation was more successful for the hand compared to the foot. In patients with neural lesions, there were signs of brain reorganization as measured by more frequent ipsilateral motor cortical activation of the foot in addition to the traditional sensory and motor activation patterns in the contralateral hemisphere. The presence of ipsilateral neural reorganization, especially around the foot motor area, suggests that careful mapping of the hand and foot in both contralateral and ipsilateral hemispheres prior to surgery might minimize postoperative deficits.

© 2015 The Authors. Published by Elsevier Inc. This is an open access article under the CC BY-NC-ND license (<http://creativecommons.org/licenses/by-nc-nd/4.0/>).

## 1. Introduction

Magnetoencephalography (MEG) in combination with magnetic resonance imaging (MRI) has developed from a research tool into a useful and accepted clinical modality in the management of patients with epilepsy and brain tumors (Anderson et al., 2014; Castillo et al., 2004; Ganslandt et al., 1999; Knowlton, 2008). Using information obtained

from MEG in the pre-surgical evaluation of epilepsy increases the success rate of epilepsy surgery (Knowlton, 2008), and MEG identification of the sensorimotor cortex has been validated by several groups using intraoperative measurements as a support to neurosurgical planning and intraoperative guidance of resection (Castillo et al., 2004; Ganslandt et al., 1999; Korvenoja et al., 2006; Schiffbauer et al., 2002; Tarapore et al., 2012).

Localization of the somatosensory cortex is typically achieved using dipole fitting applied to the 1st main peak of the somatosensory evoked field (SEF) following electrical stimulation of the median (MN) or posterior tibial nerve (PTN). (Hari and Forss, 1999; Hari et al., 1996) The changes in oscillatory power in the beta band and mu rhythm following

\* Corresponding author at: Department of Neurosurgery, 2F 01, VU University Medical Center, de Boelelaan 1117, 1081 HV, Amsterdam, The Netherlands.

E-mail addresses: [r.willemse@vumc.nl](mailto:r.willemse@vumc.nl) (R.B. Willemse), [a.hillebrand@vumc.nl](mailto:a.hillebrand@vumc.nl) (A. Hillebrand), [he.ronner@vumc.nl](mailto:he.ronner@vumc.nl) (H.E. Ronner), [wp.vandertop@vumc.nl](mailto:wp.vandertop@vumc.nl) (W. Peter Vandertop), [cj.stam@vumc.nl](mailto:cj.stam@vumc.nl) (C.J. Stam).

limb movement are typically localized using beam-former approaches (Cheyne et al., 2006; Hillebrand and Barnes, 2005), and have been shown to provide reliable preoperative localization of the hand motor cortex in patients with epilepsy and brain tumors (Nagarajan et al., 2008).

Localization of the hand primary motor and sensory cortex has been studied extensively using MEG, but less is known about the reliability of somatosensory and motor responses of the foot in a clinical setting, especially in the presence of intracranial lesions (Hari et al., 1996; Mäkelä et al., 2001; Nakamura et al., 1998; Willemse et al., 2007, 2010).

The clinical utility of MEG to map the sensorimotor cortex in surgical candidates depends on the ability to accurately and reliably lateralize and/or localize the primary sensorimotor cortex. In healthy subjects, the strongest activation is typically found contralateral to the side of stimulation or executed movement (Kakigi et al., 2000; Stippich et al., 2007). However, patients with brain lesions may have altered topographic organization of cortical functions, which can affect the results of non-invasive pre-surgical functional mapping (Lee et al., 2009; Staudt, 2010); the occurrence of such reorganization for patients with epilepsy is less clear, and may be related to underlying pathology. It is conceivable that different lesions affect the somatosensory network in different ways. Therefore, knowledge about the structural, as well as functional, changes in the network in the presence of intracranial lesions or epilepsy has clinical significance for pre-surgical planning.

In this paper, we retrospectively evaluated the results of our clinical MEG protocol in a large group of patients, eligible for epilepsy or tumor surgery, with respect to the success rate in locating the contralateral foot primary sensorimotor cortex in comparison to the hand. In addition, we studied whether differences between sensorimotor responses of the hand and foot could be related to underlying pathology.

## 2. Methods

The procedures with respect to recording and analysis of responses following electrical median nerve stimulation and hand movements have been described previously by Hillebrand et al. (2013).

### 2.1. Patients

Patients were referred from the VU University Medical Center but also externally from the University Medical Center Utrecht, Utrecht; Kempenhaeghe, Academic Center for Epileptology, Sleep Medicine and Neurological Learning & Development Disability, Heeze and SEIN, Dutch Epilepsy Clinics Foundation, The Netherlands. All 407 consecutive patients referred for clinical MEG from April 2010 until March 2014 were evaluated. All patients had at least MEG recordings with at least analysis of spontaneous activity. The majority of patients also had an additional motor and/or sensory paradigm tested as part of the routine clinical workup. Exclusion of 82 patients who had no sensory or motor paradigm tested, resulted in 325 patients for further analysis. The patients' diagnosis is summarized in Table 1.

As the patients were not subjected to procedures and were not required to follow rules of behavior other than routine clinical care, approval of the study by the institutional review board (Medical Ethical Research Committee, VU University Medical Center, Amsterdam, The Netherlands) and informed consent was not required according to the Dutch health law of February 26, 1998 (amended March 1, 2006), i.e. Wet medisch-wetenschappelijk onderzoek met mensen (WMO; Medical Research Involving Human Subjects Act), Division 1, Section 1.2.

### 2.2. MEG recordings

MEG recordings were obtained using a 306-channel whole-head neuro-magnetometer (Elekta Neuromag Oy, Helsinki, Finland) with subjects lying inside a magnetically shielded room during MEG recordings (Vacuumschmelze GmbH, Hanau, Germany). The head position

**Table 1**  
Diagnosis for all patients.

Diagnosis	N <sub>all</sub> (%)	N <sub>included</sub> (%)
Non-lesional epilepsy	168 (41.3)	134 (41.2)
Focal cortical dysplasia	50 (12.3)	45 (13.8)
Low grade glioma	50 (12.3)	39 (12)
Mesiotemporal gliosis	40 (9.8)	26 (8)
Stroke	19 (4.7)	18 (5.5)
DNET	11 (2.7)	9 (2.8)
Cavernoma	11 (2.7)	7 (2.2)
Traumatic brain injury	5 (1.2)	4 (1.2)
Developmental disorder	5 (1.2)	4 (1.2)
Tuberous sclerosis	5 (1.2)	2 (0.6)
High grade glioma	4 (1.0)	1 (0.3)
Cyst	4 (1.0)	4 (1.2)
Other	35 (8.6)	32 (9.8)
Total	407 (100)	325 (100)

DNET: dysembryoplastic neo-epithelial tumor.

relative to the MEG sensors was recorded continuously using the signals from four or five head-localization coils. The positions of the coils, as well as the outline of the participants scalp (~500 points), were digitized using a 3D digitizer (3Space Fastrak, Polhemus, Colchester, VT, USA). This scalp surface was used for co-registration with the patients anatomical MRI.

### 2.3. Anatomical MRI and co-registration

Structural MR-images were available from previous studies or otherwise acquired with a 1.5 or 3.0 T MR scanner, where the axial slice distance varied from 1.5 to 3 mm. Co-registration of these T1-weighted MRIs with the MEG data was achieved by using surface matching software developed by one of the authors (AH), resulting in an estimated co-registration accuracy of approximately 4 mm (Whalen et al., 2008). A single best fitting sphere was fitted to the outline of the scalp as obtained from the co-registered MRI, which was used as a volume conductor model for the dipole fitting and beam-former analysis described below.

### 2.4. Somatosensory stimulation

MEG responses to electrical stimulation of the left and right median nerve (MN) and the left and right posterior tibial nerve (PTN) were recorded. Constant current square wave pulses (2 Hz, 0.2 ms duration, 500 epochs) were delivered trans-cutaneous at the wrist (MN) and the ankle (PTN) just above motor threshold.

### 2.5. Motor task

Subjects performed voluntary hand movements consisting of slow, unilateral, self-paced repetitive non-clenching opening and closing of the hand at about 1 Hz. The movements were performed for 15 repeats of 10 s movement followed by 10 s without movement. With foot movements patients were instructed to alternate flexion and extension at the ankle at about 1 Hz. Movement instructions were presented to the subject using a brief tone (movement) or brief burst of white noise (no movement). Movements were monitored on camera. Left and right movements of the hand and foot were performed in separate runs.

### 2.6. Analysis

The MEG recordings were analyzed according to standard clinical procedures for pre-surgical mapping of somatosensory and motor cortex by an experienced MEG/EEG technician, and evaluated by a team consisting of two experienced clinical neurophysiologists (HR and CJS), MEG/EEG technicians and physicists (AH).

## 2.7. Dipole fitting

Somatosensory evoked fields were offline-averaged (from  $-100$  ms to  $+150$  ms with respect to stimulus onset). In accordance with our standard procedure for localization of early SEF responses, the evoked response was low-pass filtered at 70 Hz and high-pass filtered at 0.5 Hz, after baseline correction based on the window from  $-50$  to 0 ms. A single equivalent current dipole (ECD) was fitted to the peak of the SEF of the contralateral hemisphere during the first prominent deflection (using xfit, version 5.5.18, Elekta Neuromag, Oy, Helsinki, Finland).

## 2.8. Beamformer analysis

The MEG data for the motor task were band-pass filtered from 13 to 30 Hz (beta band) before sources were reconstructed using a dual-state beamformer (beamformer, Elekta Neuromag, Oy, Helsinki, Finland). A grid covering the entire brain, using a spacing of 5 mm, was used for the localization of changes in neuronal power (Hillebrand et al., 2005). A scalar beamformer implementation was used, which determines the optimal current orientation for each voxel (Sekihara et al., 2004). The 10 s preceding each auditory cue to start (hand or foot) movements were used for the control period and the 10 s following the auditory cue were used for the active period. Approximately 10 s of data, taken from the beginning of the recording (before the task was started), were used to estimate the noise covariance. Taking this noise covariance and the data co-variances from the active and passive periods, the pseudo-t metric was computed for each voxel in the source grid (Vrba and Robinson, 2001).

## 2.9. Statistical analysis

Results are presented for each of the (maximum four) sensory and (maximum four) motor paradigms as a contra- (C), ipsi- (I) or bilateral (B) result and failures were defined as MEG recordings with uninterpretable results. The success rate of the MEG recordings for each paradigm was defined as the number of MEG recordings with an interpretative result (C-, I- or B) divided by the total number of performed MEG recordings, i.e. excluding the MEG recordings with failures.

Paired proportions were analyzed by means of McNemar's test, significance was set at  $p < 0.05$  (IBM SPSS Statistics, version 22).

## 3. Results

Of the 325 patients, 168 (51.7%) were male (mean age: 29.3 yrs, range 3.7–65.5) and 74 (22.8%) were under the age of 17 (43 males (58.1%); mean age: 11.4; range 3.7–16.8). The distribution of the MEG recordings in all patients is shown in Table 2. The majority of patients ( $N = 291$ ; 89.5%) had a sensory and motor paradigm recorded. Seventeen (5.2%) patients only had data with sensory stimulation and 17 (5.2%) patients only had motor data available. In total, 1025 sensory and 1042 motor MEG recordings were performed.

The localization and lateralization results for all sensory and motor recordings are shown in Table 2, including the number of failures and success rates.

### 3.1. Somatosensory MEG

Somatosensory MEG recordings localized the contralateral primary sensory cortex in 86.6% of all recordings (mean MN 95.1% versus mean PTN 75.0%). Ipsilateral sensory responses were rare (0.5%); four patients were identified with five ipsilateral responses. One patient had a lobar hemi-microcephaly (see Fig. 1), one had non-lesional epilepsy (NLE), one had mesial temporal sclerosis (MTS) and one had a left frontal oligodendroglioma WHO grade II. Failures occurred in 132 (12.9%) of the sensory MEG recordings. MEG recordings after MN

**Table 2**

Number of MEG recordings, localization results, failures and success rate (%) after sensory stimulation and during motor tasks of the extremities.

	C (%)	I (%)	B (%)	Failure (%)	Total (%)	Success %
<b>Sensory MEG</b>						
MN-L	282 (95.6)	1 (0.3)	0	12 (4.1)	295 (100)	95.9
MN-R	282 (94.6)	0 (0.0)	0	16 (5.4)	298 (100)	94.6
PTN-L	163 (75.8)	3 (1.4)	0	49 (22.8)	215 (100)	77.2
PTN-R	161 (74.2)	1 (0.5)	0	55 (25.3)	217 (100)	74.7
Total	888 (86.6)	5 (0.5)	0 (0.0)	132 (12.9)	1025 (100)	87.1
<b>Motor MEG</b>						
HL	238 (82.1)	12 (4.1)	27 (9.3)	13 (4.5)	290 (100)	95.5
HR	239 (80.5)	12 (4.0)	26 (8.8)	20 (6.7)	297 (100)	93.3
FL	154 (68.1)	18 (8.0)	15 (6.6)	39 (17.3)	226 (100)	82.7
FR	162 (70.7)	12 (5.2)	11 (4.8)	44 (19.2)	229 (100)	80.8
Total	793 (76.1)	54 (5.2)	79 (7.6)	116 (11.1)	1042 (100)	88.9

C: contralateral; I: ipsilateral; B: bilateral; MN: median nerve; PTN: posterior tibial nerve; L: left; R: right; HL: left hand; HR: right hand; FL: left foot; FR: right foot.

stimulation had a significantly ( $p < 0.001$ ) higher success rate (95.3%) compared to PTN stimulation (76.0%).

### 3.2. Motor MEG

Localization following hand movement was more successful (94.6%) than for foot movement (81.8%;  $p < 0.001$ ). Motor tasks resulted in contralateral localization in 76.1% of the recordings; 5.2% of the MEG recordings had ipsilateral motor results, 7.6% bilateral activation patterns and 11.1% failures. Hand movements resulted in a mean of 4.1% ipsilateral and 9.1% bilateral responses, and foot movements had a mean of 6.6% ipsi- and 5.7% bilateral responses.

### 3.3. Ipsilateral motor recordings

Of the 308 patients who had motor recordings, 43 (14%) patients (28 male; mean age: 32.6 yrs; range 7.8–64.7) had one or more ipsilateral responses. The distribution of the different localization results is shown in Table 3, where it can be seen that the incidence of ipsilateral motor responses varied between 8.3–50% for different patient groups.

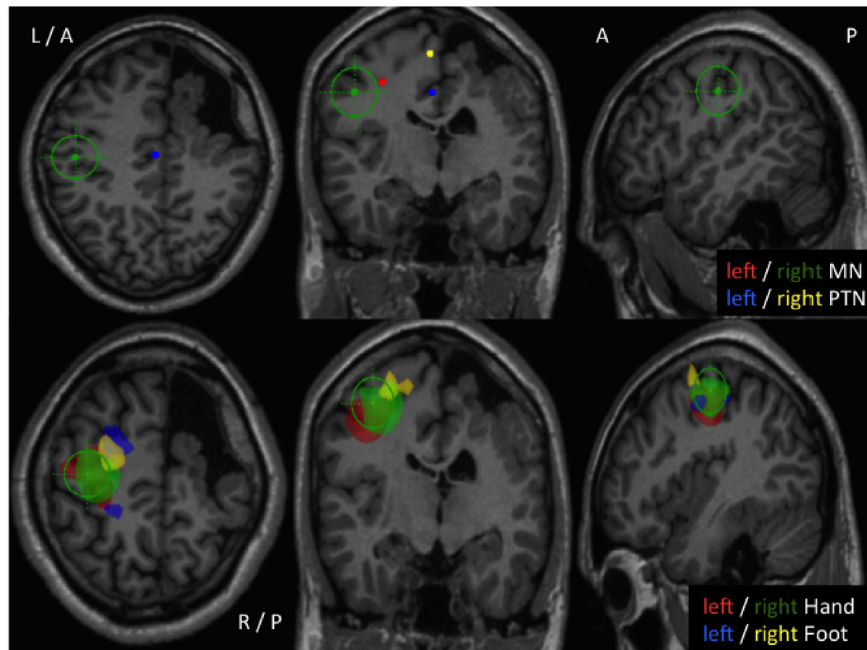
Patients with a history of stroke, TBI or a developmental disorder had a relatively high occurrence of ipsilateral results. However, the comparison of this combined patient group (stroke, TBI and developmental disorder) versus the group with slow- or non- (growing) lesions (NLE, FCD, MTS and LGG) did not reach statistical significance ( $p = 0.063$ ). The occurrence of ipsilateral results in patients with NLE is similar to patients with lesional epilepsy (MTS, DNET, FCD).

Table 4 shows the distribution of the MEG results between the hand and foot in the patients with ipsilateral motor responses.

Motor tasks of the foot showed significantly ( $p = 0.031$ ) more ipsilateral responses than for the hand. Ipsilateral responses of the hand were equally distributed between left- and right hand motor tasks. Left foot movement resulted in significantly more ipsilateral responses (9.6%) versus right foot movement (6.5%,  $p = 0.046$ ). Examples of ipsilateral hand and foot responses are shown in Fig. 2.

## 4. Discussion

In the present study we used MEG to assess the functional organization of the hand and foot sensorimotor cortex in a heterogeneous group of patients evaluated for epilepsy or tumor surgery. Somatosensory responses after PTN stimulation are less successful than MN responses and ipsilateral somatosensory results are rare. MEG motor recordings localize the contralateral M1 in the majority of cases but also show ipsi- and bilateral M1 activation with differential occurrence in patient groups, especially with foot movements.



**Fig. 1.** Axial (left), coronal (middle) and sagittal (right) MR images corresponding to a 35-year-old male with a left-sided motor weakness since the age of six months with symptomatic therapy-resistant epilepsy with right-sided lobar hemi-microencephaly of the frontal lobe and insular region, in addition to polymicrogyric pachygyria. The only ipsilateral median nerve (MN) result in the patient group was found in this patient, who also had ipsilateral activation after posterior tibial nerve (PTN) stimulation and for both hand and foot motor responses. *Top panels:* results of MN and PTN stimulation on both sides showing ipsilateral MN and PTN responses. *Lower panels:* task-related power decreases in the beta band during self-paced hand and foot movements with localization in the ipsilateral hemisphere for both hand and foot movements. L: left; R: right; A: anterior; P: posterior.

4.1. Ipsilateral somatosensory cortex localization

The most reliably elicited somatosensory responses are the early responses (N20m and P40m for MN and PTN stimulation respectively), which usually cause a contralateral response at S1. MN stimulation gives robust results and has been validated with structural and intraoperative cortical stimulation mapping (Ganslandt et al., 1999; Schiffbauer et al., 2002).

In our study, we also found robust contralateral results after MN and PTN stimulation. However, few patients (and only 0.5% of the MEG recordings) showed ipsilateral somatosensory responses. In adults, ipsilateral somatosensory responses have been described with MEG in normal subjects (Korvenoja et al., 1995, 1999), as well as in patients (Kanno et al., 2003). In a large group of 482 heterogeneous patients,

2.9% of the patients showed an ipsilateral MN response, but no relation could be established between the underlying disease and the presence of an ipsilateral response, which is in accordance with our results. Ipsilateral MN responses have also been described in cerebral palsy (Guzzetta et al., 2007; Wilke et al., 2009), as in one of our patients (Fig. 1).

It has been hypothesized that an ipsilateral response is a normal variant in the population (Kanno et al., 2003) but another possible explanation for this rare occurrence is a lack of transcallosal inhibition of the ipsilateral S1 area after unilateral somatosensory stimulation (Hlushchuk and Hari, 2006). Others, using either a different source model (MEG) or imaging modality (fMRI), found that unilateral MN stimulation can activate both the left and right S1 in healthy subjects (Korvenoja et al., 1999; Sutherland and Tang, 2006). However, as usually the single ECD model is used for clinical MEG applications, as in our study, we can only make comparisons with previous studies using the same model.

There are only a few studies with PTN-evoked magnetic responses in the presence of intracranial pathology (Schiffbauer et al., 2002; Willemse et al., 2007), and ipsilateral PTN responses have not been described previously with MEG. We found four ipsilateral PTN responses in three patients with different pathology and the only ipsilateral MN response was also found in one of these patients (Fig. 1). It is unclear whether this lateralization reflects functional reorganization or whether other factors may contribute. For MN SEFs, we know that tactile interference can reduce the contralateral response and can increase the ipsilateral response, possibly via excitatory transcallosal pathways (Schnitzler et al., 1995). We do not know whether this is also true for the foot and whether patients induced this involuntarily. Others

**Table 3**  
Number of patients (N) with ipsilateral motor responses (N<sub>ipsi</sub>).

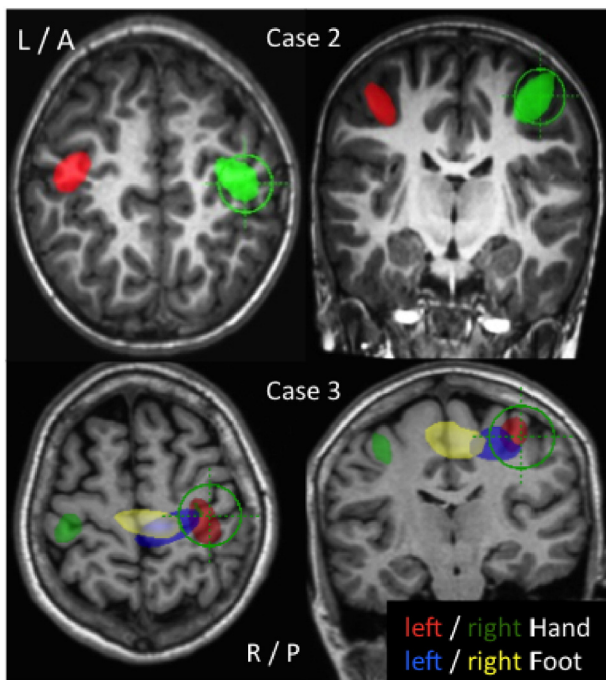
Diagnosis	Patients		N <sub>ipsi</sub>	% of N
	N	%		
NLE	128	41.6	14	10.9
FCD	42	13.6	5	11.9
LGG	36	11.7	4	11.1
MTS	24	7.8	2	8.3
Stroke	18	5.8	5	27.8
DNET	8	2.6	1	12.5
Cavernoma	7	2.3	1	14.3
TBI	4	1.3	2	50.0
Develop. disorder	4	1.3	2	50.0
Cyst	4	1.3	0	0.0
Tuberous sclerosis	2	0.6	0	0.0
HGG	1	0.3	0	0.0
Other	30	9.7	7	23.3
	<b>308</b>	<b>100</b>	<b>43</b>	<b>14.0</b>

NLE: nonlesional epilepsy; LGG: low grade glioma; FCD: focal cortical dysplasia; MTS: mesiotemporal sclerosis; DNET: dysembryoplastic neo-epithelial tumor; TBI: traumatic brain injury; Develop. disorder: developmental disorder; HGG: high-grade glioma.

**Table 4**  
Distribution of MEG results in the patients with ipsilateral motor recordings.

MEG recording	N	N <sub>ipsi</sub> (%)
Hand	81	24 (29.6)
Foot	67	30 (44.8)





**Fig. 2.** Axial (left) and coronal (right) MR images showing two examples of task-related power decreases in the beta band, demonstrating ipsilateral motor responses in Cases 2 and 3 during hand or foot movements. Case 2: 9-year-old female with intractable and non-lesional epilepsy showing pronounced ipsilateral cortical responses for both hands with localization in the hand area. Foot movements, despite good performance, show no cortical response (not shown). Case 3: 36-year-old female with focal cortical dysplasia in the depth of the central sulcus of the left hemisphere shows a contralateral response of both hands and the left foot. Right foot movements show an ipsilateral response at the medial wall of the primary motor cortex. L: left; R: right; A: anterior; P: posterior.

however, have concluded that ipsilateral responses after PTN stimulation might also be explained by its location, adjacent to the inter-hemispheric fissure (Kakigi et al., 1995).

Our data confirm that ipsilateral somatosensory cortical activation is rare, and that somatosensory cortical activation remains in the lesioned hemisphere, even in the presence of lesions, in contrast to motor activation (Wilke et al., 2009).

#### 4.2. Ipsilateral hand responses

Unilateral hand movements usually give the strongest activation patterns in contralateral M1 (cM1). Ipsilateral motor cortex involvement during unilateral voluntary movements has been reported with MEG studies (Cheyne et al., 2006; Kristeva et al., 1991; Taniguchi et al., 2000) and has also been demonstrated using beamformer analysis in healthy subjects (Jurkiewicz et al., 2006) and patients with intracranial lesions (Nagarajan et al., 2008; Taniguchi et al., 2004; Willemse et al., 2010). Exclusive ipsilateral activity was found in the sensorimotor cortex, the premotor cortex (PMC) and the inferior parietal lobule (IPL) during movement of the affected hand in brain tumor patients with mostly high-grade gliomas around the central sulcus, and it was hypothesized that recruitment of ipsilateral motor areas was needed to maintain effective movement of the affected hand (Taniguchi et al., 2004). Using fMRI, Tozakidou et al. (2013) found an increased occurrence of ipsilateral M1 activation in a large group of patients with tumors of the central region, especially in fast-growing lesions such as grade IV gliomas and metastases (Tozakidou et al., 2013). In our study, we only had one patient with a high-grade glioma and hence we were not able to confirm these findings. We only found exclusive ipsilateral activation in a small proportion of the datasets, which is in accordance with the findings of others (Nagarajan et al., 2008; Willemse et al., 2010).

Enhanced ipsilateral activity has been described in the presence of pathology (Carpentier et al., 2001; Stoeckel and Binkofski, 2010). Carpentier et al. showed with fMRI in a heterogeneous group of patients with different types of tumors, arteriovenous malformations and epileptogenic cortical malformations, that ipsilateral activation was more pronounced in the latter group (Carpentier et al., 2001). It is generally accepted that such lesions, acquired in the pre- and perinatal period can be compensated easier by the immature brain than the adult brain, with ipsilateral takeover of motor functions (Stoekel and Binkofski, 2010). This could explain the findings from Carpentier et al., but also the increased ipsilateral responses in our patients with developmental disorders. Patients with a history of stroke and TBI have also shown frequent ipsilateral responses, which could be explained by a disruption of inter-hemispheric inhibition as described in stroke patients using the recovered hand (Cao et al., 1998) or TBI patients with corpus callosum lesions (Takeuchi et al., 2012).

The majority of our patients had lesional (MTS, FCD), or non-lesional epilepsy and data about ipsilateral motor responses in these patient groups are rare, but could be potentially interesting for resective epilepsy surgery around motor areas. We only found one report of an ipsilateral response in MTS (Chlebus et al., 2004) and one case report with FCD (Maegaki et al., 1995). Recently, Mäkelä et al. described two patients from a group of 19 patients with intractable epilepsy, with unexpected motor cortex localization, of whom one had a history of a large perinatal vascular infarction in the left hemisphere and ipsilateral hand motor cortex representation in the right hemisphere (Mäkelä et al., 2013). Motor cortex plasticity in the presence of epilepsy could be the result of functional network alterations in lesional, perilesional but also remote neocortical areas as has been described in MTS and FCD (Caciagli et al., 2014). It is conceivable that patients with NLE, which is a heterogeneous group with different epileptogenic mechanisms, also show functional reorganization comparable to epileptic patients with structural lesions.

In healthy adults, there is increasing evidence that upper limb function relies on the balanced control of cM1 and ipsilateral M1 (iM1) and it is assumed that iM1 assists cM1 by modulating the extent of transcallosal inhibition (Allison et al., 2000; Ferbert et al., 1992; Kobayashi et al., 2003; van Wijk et al., 2012; Ziemann et al., 1999). Before activation of both primary motor cortices in unilateral movements there is evidence that ipsilateral PMC activity precedes activity in cM1 (Huang et al., 2004; Liuzzi et al., 2010), which may explain bilateral activity found in fMRI studies. It is possible that the ipsilateral responses in our study are related to PMC activity instead of M1 activity, because they are in close anatomical relationship with overlap in temporal dynamics, or that the result is an average of both, which makes it difficult to disentangle these sources. Finally, participation of the ipsilateral sensorimotor cortex in unilateral limb movements by the partially uncrossed descending fibers of the corticospinal tract recently has been reconsidered as a compensatory pathway in stroke patients (Bradnam et al., 2013).

#### 4.3. Ipsilateral foot responses

We found an increased occurrence of ipsilateral responses after foot movements. This could not be explained by previous M/EEG studies on lower limb movements which indicated bilateral activity over the sensorimotor areas after voluntary movements (Müller-Putz et al., 2007; Pfurtsceller et al., 1997; Pittaccio et al., 2011) or the contribution of the PMC and supplementary motor area (SMA) (Pittaccio et al., 2013).

Comparable fMRI studies however, have shown that active ankle dorsiflexion was associated with a greater relative contribution of iM1 and PMC than finger movements (Cicarelli et al., 2005; Sahyoun et al., 2004), suggesting a more significant role of iM1 in the motor planning of lower limb movements than for similar hand movements. These findings may explain the increased ipsilateral foot responses in our study and previous findings in patients with perirolandic lesions

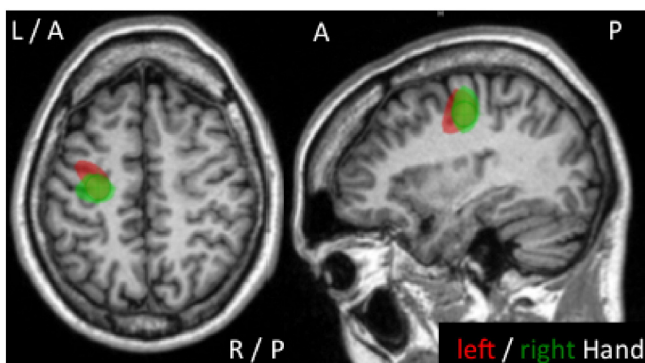
(Willemse et al., 2010). Another possible explanation could be related to task complexity, where ipsilateral activation, especially in M1, has been considered to reflect the degree of task complexity for the upper limb (Verstynen et al., 2005). A comparable study with respect to the lower limb found significant differences between ipsilateral sensorimotor activity during large-amplitude (40°) dorsiflexion at 0.5 Hz, compared with small amplitude (15°) dorsiflexion, suggesting that larger amplitude dorsiflexion is a more difficult task (MacIntosh et al., 2004). Our patients were instructed to perform ankle dorsiflexion and plantar flexion in the most comfortable way at about 1 Hz, however we do not consider foot movements more complex than hand movements as a possible explanation for the increased ipsilateral foot responses.

The previous studies were all performed in healthy subjects and our results may indicate functional plasticity in the presence of disease. However, since EMG was not performed in our study, we cannot rule out the possibility of subtle mirror movements of the contralateral limb as another explanation. Future investigation of foot motor function is required to elucidate the clinical value of ipsilateral motor responses.

Our results demonstrate that the motor network in a large heterogeneous population of patients with lesions or epilepsy (or both) mostly show expected contralateral responses, but also that ipsilateral motor responses may occur. This may have implications for surgical planning in order to avoid post-operative motor deficits (see example in Fig. 3).

#### 4.4. Limitations of the study

The results of motor mapping with a beamformer approach depend on thresholding the pseudo-*t* value at each voxel location. Usually motor activity of the hand shows a strong contralateral activity peak and a weak ipsilateral activity peak, depending on the threshold. Inversely, the occurrence of ipsilateral responses in our group, does not rule out the possibility of a concurrent contralateral responses as well. For practical purposes, we choose the side of the strongest activity and the results of bilateral responses, i.e. nearly equal responses were not evaluated as a separate group. Furthermore, the clinical imaging protocol only evaluated decreases in beta band spectral power, information on a possible increase in beta band power is therefore lacking in the analyses presented here. An increase of beta band power can be found in sensorimotor areas following voluntary movement and somatosensory stimulation (Neuper et al., 2006), but the clinical value with respect to localization of motor execution is unclear.



**Fig. 3.** Axial (left), and sagittal (right) MR images of a 40-year-old patient with recurrent motor seizures (epilepsia partialis continua) of the left hand since the age of two, due to cortical dysplasia in the hand area of the right motor cortex. The MEG motor findings suggested functional reorganization with lateralization of the left hand to the left hemisphere (task-related power decreases in the beta band during self-paced movements of the left hand (red) and right hand (green)). Identification of the epileptogenic focus was necessary with invasive techniques. The MEG results supported additional functional mapping as well and therefore, subdural grid monitoring of the right hemisphere was performed, showing an extensive and scattered area for motor hand function. Surgery was performed with premotor removal of tissue and multiple subpial transections of the right hand motor cortex. Postoperatively, the patient had no neurological deficits of the left arm and a significant seizure reduction. L: left; R: right; A: anterior; P: posterior.

The spatial resolution of MEG with respect to source localization of midline structures such as the foot sensorimotor cortex is an important issue. Detectability of sources in foot sensorimotor cortex by MEG, may be compromised by their depth, yet these sources have a favorable orientation (Hillebrand and Barnes, 2002).

Beamformer analysis offers further improvements in spatial resolution compared to dipole fitting (see Appendix in Hillebrand and Barnes, 2003) (Hillebrand and Barnes, 2003), and the spatial resolution was optimized through the use of a large number of channels, a long covariance window, and the use of a bandwidth that matched the frequency distribution of the signals of interest (Brookes et al., 2008). However, despite these efforts and the fact that the majority of patients showed foot activation at the expected contralateral foot motor cortex, we cannot rule out the possibility of false foot-lateralization in some cases.

Even in this large group of 325 patients the number of patients with signs of functional reorganization is too small for reliable statistical inferences. Future studies in larger patient groups with stroke, TBI and developmental disorders will have to show whether the observed trend towards increased ipsilateral responses in these patient groups is a consistent finding.

The failures of the MEG recordings could be attributed to some technical constraints (e.g. the presence of a vagal nerve stimulator or stimulation artifacts) or patient-related factors, such as fear for electrical stimulation, restlessness or mirror movements.

Data about handedness were only partially available and not analyzed. Although handedness is known to affect hemispheric asymmetry (Solodkin et al., 2001; Verstynen et al., 2005), this is usually related to task complexity. Simple motor tasks, as in our study, elicit similar responses in both hands, which were also found in our study as well as in other studies with intracranial lesions (Cheyne et al., 2006; Nagarajan et al., 2008; Willemse et al., 2010). With respect to the results of sensory stimulation, sensory dominance has not been established with electrical median nerve or pneumatically driven finger stimulation (Chen et al., 2012; Zhu et al., 2007).

## 5. Conclusion

A clinical imaging protocol using MEG with respect to sensorimotor cortex activation has a high success rate with respect to identification of the contralateral sensorimotor cortex.

Functional reorganization in the primary somatosensory cortex is rare, but can occur in the primary motor cortex in patients with intracranial lesions and non-lesional epilepsy, especially during foot movements. The presence of ipsilateral neural reorganization, especially around the foot motor area, may support clinicians to perform careful mapping of the hand and foot in both hemispheres prior to surgery, to minimize postoperative deficits.

## Acknowledgments

We thank N. Sijmsma, K. Plugge, N. Akemann, M. van der Hoek and P. Ris for the MEG recordings and our external referrals from University Medical Center Utrecht, Utrecht, The Netherlands (Dr FS Leijten; Drs. P.H. Gosselaar; Prof Dr K. Braun; Dr M Engelsman; Prof Dr O van Nieuwenhuizen; Dr F Jansen; Dr C Ferrier; Drs T Snijders; Dr PB Augustijn; Dr Braakman; Dr C Haaxma), Kempenhaeghe, Academic Center for Epileptology, Sleep Medicine and Neurological Learning & Development Disability, Heeze, The Netherlands (Drs. GL Wagner; Dr. B Gunning; Dr J Arends; Drs AJ Colon; Dr M van Erp; Dr B Kornips) and SEIN, Dutch Epilepsy Clinics Foundation, The Netherlands (Dr C Deckers; Dr DN Velis; Dr R Debets; Dr R Thijs; Dr M Jongasma; Drs Y Geerts; Dr HCE van Lambalgen; Dr H Geesink; Drs J Stapert; Dr J Zwemmer).

Financial support/Conflict of interest

The authors report no conflict of interest concerning the materials or methods used in this study or the findings specified in this paper.

## References

- Allison, J.D., Meador, K.J., Loring, D.W., Figueroa, R.E., Wright, J.C., 2000. Functional MRI cerebral activation and deactivation during finger movement. *Neurology* 54, 135–142.
- Anderson, C.T., Carlson, C.E., Li, Z., Raghavan, M., 2014. Magnetoencephalography in the preoperative evaluation for epilepsy surgery. *Curr. Neurol. Neurosci. Rep.* 14, 446.
- Bradnam, L.V., Stinear, C.M., Byblow, W.D., 2013. Ipsilateral motor pathways after stroke: implications for non-invasive brain stimulation. *Front. Hum. Neurosci.* 7, 184.
- Brookes, M.J., Vrba, J., Robinson, S.E., Stevenson, C.M., Peters, A.M., Barnes, G.R., Hillebrand, A., Morris, P.G., 2008. Optimising experimental design for MEG beamformer imaging. *Neuroimage* 39, 1788–1802.
- Caciagli, L., Bernhardt, B.C., Hong, S.-J., Bernasconi, A., Bernasconi, N., 2014. Functional network alterations and their structural substrate in drug-resistant epilepsy. *Front. Neurosci.* 8, 411.
- Cao, Y., D'Olhaberriague, L., Vikingstad, E.M., Levine, S.R., Welch, K.M., 1998. Pilot study of functional MRI to assess cerebral activation of motor function after poststroke hemiparesis. *Stroke* 29, 112–122.
- Carpentier, A.C., Constable, R.T., Schlosser, M.J., de Lotbinière, A., Piepmeyer, J.M., Spencer, D.D., Awad, I.A., 2001. Patterns of functional magnetic resonance imaging activation in association with structural lesions in the rolandic region: a classification system. *J. Neurosurg.* 94, 946–954.
- Castillo, E.M., Simos, P.G., Wheless, J.W., Baumgartner, J.E., Breier, J.I., Billingsley, R.L., Sarkari, S., Fitzgerald, M.E., Papanicolaou, A.C., 2004. Integrating sensory and motor mapping in a comprehensive MEG protocol: clinical validity and replicability. *Neuroimage* 21, 973–983.
- Chen, A.C.N., Theuvsen, P.J., de Munck, J.C., Peters, M.J., van Ree, J.M., Lopes da Silva, F.L., 2012. Sensory handedness is not reflected in cortical responses after basic nerve stimulation: a MEG study. *Brain Topogr.* 25, 228–240.
- Cheyne, D., Bakhtazad, L., Gaetz, W., 2006. Spatiotemporal mapping of cortical activity accompanying voluntary movements using an event-related beamforming approach. *Hum. Brain Mapp.* 27, 213–229.
- Chlebus, P., Brzdil, M., Hlustik, P., Míkl, M., Pazourková, M., Krupa, P., 2004. Handedness shift as a consequence of motor cortex reorganization after early functional impairment in left temporal lobe epilepsy – an fMRI case report. *Neurocase* 10, 326–329.
- Ciccarelli, O., Toosy, A.T., Marsden, J.F., Wheeler-Kingshott, C.M., Sahyoun, C., Matthews, P.M., Miller, D.H., Thompson, A.J., 2005. Identifying brain regions for integrative sensorimotor processing with ankle movements. *Exp. Brain Res.* 166, 31–42.
- Ferbert, A., Priori, A., Rothwell, J.C., Day, B.L., Colebatch, J.G., Marsden, C.D., 1992. Interhemispheric inhibition of the human motor cortex. *J. Physiol.* 453, 525–546.
- Ganslandt, O., Fahlbusch, R., Nimsky, C., Kober, H., Moller, M., Steinmeier, R., Romstock, J., Vieth, J., 1999. Functional neuronavigation with magnetoencephalography: outcome in 50 patients with lesions around the motor cortex. *Neurosurg. Focus* 6, e3.
- Guzzetta, A., Bonanni, P., Biagi, L., Tosetti, M., Montanaro, D., Guerrini, R., Cioni, G., 2007. Reorganisation of the somatosensory system after early brain damage. *Clin. Neurophysiol.* 118, 1110–1121.
- Hari, R., Forss, N., 1999. Magnetoencephalography in the study of human somatosensory cortical processing. *Philos. Trans. R. Soc. Lond. B Biol. Sci.* 354, 1145–1154.
- Hari, R., Nagamine, T., Nishitani, N., Mikuni, N., Sato, T., Tarkiainen, A., Shibasaki, H., 1996. Time-varying activation of different cytoarchitectonic areas of the human SI cortex after tibial nerve stimulation. *Neuroimage* 4, 111–118.
- Hillebrand, A., Barnes, G.R., 2002. A quantitative assessment of the sensitivity of whole-head MEG to activity in the adult human cortex. *Neuroimage* 16, 638–650.
- Hillebrand, A., Barnes, G.R., 2003. The use of anatomical constraints with MEG beamformers. *Neuroimage* 20, 2302–2313.
- Hillebrand, A., Barnes, G.R., 2005. Beamformer analysis of MEG data. *Int. Rev. Neurobiol.* 68, 149–171.
- Hillebrand, A., Singh, K.D., Holliday, I.E., Furlong, P.L., Barnes, G.R., 2005. A new approach to neuroimaging with magnetoencephalography. *Hum. Brain Mapp.* 25, 199–211.
- Hillebrand, A., Fazio, P., de Munck, J.C., van Dijk, B.W., 2013. Feasibility of clinical magnetoencephalography (MEG) functional mapping in the presence of dental artefacts. *Clin. Neurophysiol.* 124, 107–113.
- Hlushchuk, Y., Hari, R., 2006. Transient suppression of ipsilateral primary somatosensory cortex during tactile finger stimulation. *J. Neurosci.* 26, 5819–5824.
- Huang, M.-X., Harrington, D.L., Paulson, K.M., Weisend, M.P., Lee, R.R., 2004. Temporal dynamics of ipsilateral and contralateral motor activity during voluntary finger movement. *Hum. Brain Mapp.* 23, 26–39.
- Jurkiewicz, M.T., Gaetz, W.C., Bostan, A.C., Cheyne, D., 2006. Post-movement beta rebound is generated in motor cortex: evidence from neuromagnetic recordings. *Neuroimage* 32, 1281–1289.
- Kakigi, R., Koyama, S., Hoshiyama, M., Shimojo, M., Kitamura, Y., Watanabe, S., 1995. Topography of somatosensory evoked magnetic fields following posterior tibial nerve stimulation. *Electroencephalogr. Clin. Neurophysiol.* 95, 127–134.
- Kakigi, R., Hoshiyama, M., Shimojo, M., Naka, D., Yamasaki, H., Watanabe, S., Xiang, J., Maeda, K., Lam, K., Itomi, K., Nakamura, A., 2000. The somatosensory evoked magnetic fields. *Prog. Neurobiol.* 61, 495–523.
- Kanno, A., Nakasato, N., Hatanaka, K., Yoshimoto, T., 2003. Ipsilateral area 3b responses to median nerve somatosensory stimulation. *Neuroimage* 18, 169–177.
- Knowlton, R.C., 2008. Can magnetoencephalography aid epilepsy surgery? *Epilepsy Curr.* 8, 1–5.
- Kobayashi, M., Hutchinson, S., Schlaug, G., Pascual-Leone, A., 2003. Ipsilateral motor cortex activation on functional magnetic resonance imaging during unilateral hand movements is related to interhemispheric interactions. *Neuroimage* 20, 2259–2270.
- Korvenoja, A., Wikstrom, H., Huttunen, J., Virtanen, J., Laine, P., Aronen, H.J., Seppäläinen, A.M., Ilmoniemi, R.J., 1995. Activation of ipsilateral primary sensorimotor cortex by median nerve stimulation. *Neuroreport* 6, 2589–2593.
- Korvenoja, A., Huttunen, J., Salli, E., Pohjonen, H., Martinkauppi, S., Palva, J.M., Lauronen, L., Virtanen, J., Ilmoniemi, R.J., Aronen, H.J., 1999. Activation of multiple cortical areas in response to somatosensory stimulation: combined magnetoencephalographic and functional magnetic resonance imaging. *Hum. Brain Mapp.* 8, 13–27.
- Korvenoja, A., Kirveskari, E., Aronen, H.J., Avikainen, S., Brander, A., Huttunen, J., Ilmoniemi, R.J., Jääskeläinen, J.E., Kovala, T., Mäkelä, J.P., Salli, E., Seppä, M., 2006. Sensorimotor cortex localization: comparison of magnetoencephalography, functional MR imaging, and intraoperative cortical mapping. *Radiology* 241, 213–222.
- Kristeva, R., Cheyne, D., Deecke, L., 1991. Neuromagnetic fields accompanying unilateral and bilateral voluntary movements: topography and analysis of cortical sources. *Electroencephalogr. Clin. Neurophysiol.* 81, 284–298.
- Lee, H.W., Shin, J.S., Webber, W.R.S., Crone, N.E., Gingis, L., Lesser, R.P., 2009. Reorganisation of cortical motor and language distribution in human brain. *J. Neurol. Neurosurg. Psychiatry* 80, 285–290.
- Liuzzi, G., Hörniss, V., Hoppe, J., Heise, K., Zimmerman, M., Gerloff, C., Hummel, F.C., 2010. Distinct temporospatial interhemispheric interactions in the human primary and premotor cortex during movement preparation. *Cereb. Cortex* 20, 1323–1331.
- MacIntosh, B.J., Mraz, R., Baker, N., Tam, F., Staines, W.R., Graham, S.J., 2004. Optimizing the experimental design for ankle dorsiflexion fMRI. *Neuroimage* 22, 1619–1627.
- Maegaki, Y., Yamamoto, T., Takeshita, K., 1995. Plasticity of central motor and sensory pathways in a case of unilateral extensive cortical dysplasia: investigation of magnetic resonance imaging, transcranial magnetic stimulation, and short-latency somatosensory evoked potentials. *Neurology* 45, 2255–2261.
- Mäkelä, J.P., Kirveskari, E., Seppä, M., Hämäläinen, M., Forss, N., Avikainen, S., Salonen, O., Salenius, S., Kovala, T., Randell, T., Jääskeläinen, J., Hari, R., 2001. Three-dimensional integration of brain anatomy and function to facilitate intraoperative navigation around the sensorimotor strip. *Hum. Brain Mapp.* 12, 180–192.
- Mäkelä, J.P., Vitikainen, A.-M., Lioumis, P., Paetau, R., Ahtola, E., Kuusela, L., Valanne, L., Blomstedt, G., Gaily, E., 2013. Functional plasticity of the motor cortical structures demonstrated by navigated TMS in two patients with epilepsy. *Brain Stimul.* 6, 286–291.
- Müller-Putz, G.R., Zimmermann, D., Graimann, B., Nestinger, K., Korisek, G., Pfurtscheller, G., 2007. Event-related beta EEG-changes during passive and attempted foot movements in paraplegic patients. *Brain Res.* 1137, 84–91.
- Nagarajan, S., Kirsch, H., Lin, P., Findlay, A., Honma, S., Berger, M.S., 2008. Preoperative localization of hand motor cortex by adaptive spatial filtering of magnetoencephalography data. *J. Neurosurg.* 109, 228–237.
- Nakamura, A., Yamada, T., Goto, A., Kato, T., Ito, K., Abe, Y., Kachi, T., Kakigi, R., 1998. Somatosensory homunculus as drawn by MEG. *Neuroimage* 7, 377–386.
- Neuper, C., Wörtz, M., Pfurtscheller, G., 2006. ERD/ERS patterns reflecting sensorimotor activation and deactivation. *Prog. Brain Res.* 159, 211–222.
- Pfurtscheller, G., Neuper, C., Andrew, C., Edlinger, G., 1997. Foot and hand area mu rhythms. *Int. J. Psychophysiol.* 26, 121–135.
- Pittaccio, S., Zappasodi, F., Viscuso, S., Mastroianni, F., Ercolani, M., Passarelli, F., Molteni, F., Besseghini, S., Rossini, P.M., Tecchio, F., 2011. Primary sensory and motor cortex activities during voluntary and passive ankle mobilization by the SHADE orthosis. *Hum. Brain Mapp.* 32, 60–70.
- Pittaccio, S., Zappasodi, F., Tamburro, G., Viscuso, S., Marzetti, L., Garavaglia, L., Tecchio, F., Pizzella, V., 2013. Passive ankle dorsiflexion by an automated device and the reactivity of the motor cortical network. *Conf. Proc. IEEE Eng. Med. Biol. Soc.* 2013, 6353–6356.
- Sahyoun, C., Floyer-Lea, A., Johansen-Berg, H., Matthews, P.M., 2004. Towards an understanding of gait control: brain activation during the anticipation, preparation and execution of foot movements. *Neuroimage* 21, 568–575.
- Schiffbauer, H., Berger, M.S., Ferrari, P., Freudenstein, D., Rowley, H.A., Roberts, T.P.L., 2002. Preoperative magnetic source imaging for brain tumor surgery: a quantitative comparison with intraoperative sensory and motor mapping. *J. Neurosurg.* 97, 1333–1342.
- Schnitzler, A., Salmelin, R., Salenius, S., Jousmäki, V., Hari, R., 1995. Tactile information from the human hand reaches the ipsilateral primary somatosensory cortex. *Neurosci. Lett.* 200, 25–28.
- Sekihara, K., Nagarajan, S.S., Poeppel, D., Marantz, A., 2004. Asymptotic SNR of scalar and vector minimum-variance beamformers for neuromagnetic source reconstruction. *IEEE Trans. Biomed. Eng.* 51, 1726–1734.
- Solodkin, A., Hlustik, P., Noll, D.C., Small, S.L., 2001. Lateralization of motor circuits and handedness during finger movements. *Eur. J. Neurol.* 8, 425–434.
- Staud, M., 2010. Reorganization after pre- and perinatal brain lesions. *J. Anat.* 217, 469–474.
- Stippich, C., Blatow, M., Durst, A., Dreyhaupt, J., Sartor, K., 2007. Global activation of primary motor cortex during voluntary movements in man. *Neuroimage* 34, 1227–1237.
- Stoeckel, M.C., Binkofski, F., 2010. The role of ipsilateral primary motor cortex in movement control and recovery from brain damage. *Exp. Neurol.* 221, 13–17.
- Sutherland, M.T., Tang, A.C., 2006. Reliable detection of bilateral activation in human primary somatosensory cortex by unilateral median nerve stimulation. *Neuroimage* 33, 1042–1054.
- Takeuchi, N., Ouchida, Y., Izumi, S.-I., 2012. Motor control and neural plasticity through interhemispheric interactions. *Neural Plast.* 2012, 823285.
- Taniguchi, M., Kato, A., Fujita, N., Hirata, M., Tanaka, H., Kihara, T., Ninomiya, H., Hirabuki, N., Nakamura, H., Robinson, S.E., 2000. Movement-related desynchronization of the cerebral cortex studied with spatially filtered magnetoencephalography. *Neuroimage* 12, 298–306.



- Taniguchi, M., Kato, A., Ninomiya, H., Hirata, M., Cheyne, D., Robinson, S.E., Maruno, M., Saitoh, Y., Kishima, H., Yoshimine, T., 2004. Cerebral motor control in patients with gliomas around the central sulcus studied with spatially filtered magnetoencephalography. *J. Neurol. Neurosurg. Psychiatry* 75, 466–471.
- Tarapore, P.E., Tate, M.C., Findlay, A.M., Honma, S.M., Mizuiri, D., Berger, M.S., Nagarajan, S.S., 2012. Preoperative multimodal motor mapping: a comparison of magnetoencephalography imaging, navigated transcranial magnetic stimulation, and direct cortical stimulation. *J. Neurosurg.* 117, 354–362.
- Tozakidou, M., Wenz, H., Reinhardt, J., Nennig, E., Riffel, K., Blatow, M., Stippich, C., 2013. Primary motor cortex activation and lateralization in patients with tumors of the central region. *Neuroimage (Amst)* 2, 221–228.
- van Wijk, B.C.M., Beek, P.J., Daffertshofer, A., 2012. Differential modulations of ipsilateral and contralateral beta (de)synchronization during unimanual force production. *Eur. J. Neurosci.* 36, 2088–2097.
- Verstynen, T., Diedrichsen, J., Albert, N., Aparicio, P., Ivry, R.B., 2005. Ipsilateral motor cortex activity during unimanual hand movements relates to task complexity. *J. Neurophysiol.* 93, 1209–1222.
- Vrba, J., Robinson, S.E., 2001. Signal processing in magnetoencephalography. *Methods* 25, 249–271.
- Whalen, C., Maclin, E.L., Fabiani, M., Gratton, G., 2008. Validation of a method for coregistering scalp recording locations with 3D structural MR images. *Hum. Brain Mapp.* 29, 1288–1301.
- Wilke, M., Staudt, M., Juenger, H., Grodd, W., Braun, C., Krägeloh-Mann, I., 2009. Somatosensory system in two types of motor reorganization in congenital hemiparesis: topography and function. *Hum. Brain Mapp.* 30, 776–788.
- Willemse, R.B., de Munck, J.C., van't Ent, D., Ris, P., Baayen, J.C., Stam, C.J., Vandertop, W.P., 2007. Magnetoencephalographic study of posterior tibial nerve stimulation in patients with intracranial lesions around the central sulcus. *Neurosurgery* 61, 1209–1217 (discussion 1217–8).
- Willemse, R.B., de Munck, J.C., Verbunt, J.P.A., van 't Ent, D., Ris, P., Baayen, J.C., Stam, C.J., Vandertop, W.P., 2010. Topographical organization of mu and beta band activity associated with hand and foot movements in patients with perirolandic lesions. *Open Neuroimaging J.* 4, 93–99.
- Zhu, Z., Disbrow, E.A., Zumer, J.M., McGonigle, D.J., Nagarajan, S.S., 2007. Spatiotemporal integration of tactile information in human somatosensory cortex. *BMC Neurosci.* 8, 21.
- Ziemann, U., Ishii, K., Borgheresi, A., Yaseen, Z., Battaglia, F., Hallett, M., Cincotta, M., Wassermann, E.M., 1999. Dissociation of the pathways mediating ipsilateral and contralateral motor-evoked potentials in human hand and arm muscles. *J. Physiol.* 518 (Pt 3), 895–906.