

Exploring a Tumor Spectrum in a Patient with Familial Angiolipomatosis

Abstract

Angiolipomas are uncommon spinal tumors which differ from their cutaneous counterparts in having larger caliber vascular stroma. Although slow growing, they can cause rapid spinal cord compression and sudden-onset sensorimotor symptoms due to vascular engorgement, hemorrhage, or thrombosis. The goal of surgery is spinal decompression, and favorable outcome is the rule. We report a patient with spinal angiolipoma, vertebral hemangioma along with subcutaneous lipomas and angiolipomas, exhibiting the entire histopathological spectrum of these related soft-tissue tumors. Analysis of his family tree revealed a hereditary predilection. Familial angiolipomatosis is an uncommon genetic condition which has not been reported to occur with spinal angiolipomas thus far.

Keywords: Angiolipoma, familial angiolipomatosis, spinal angiolipoma

Introduction

Lipomas, angiolipomas, and hemangiomas represent a continuous histopathological spectrum of related tumors.^[1] These tumors are benign and slow growing in nature. The main differentiating factor between them is the ratio between vascular and adipose components. The vascular fraction comprises <10% of tumor mass in lipomas, 15%–40% in angiolipomas,^[2] whereas hemangiomas consist almost entirely of malformed vasculature with scanty intervening stroma.

Lipomas and angiolipomas occur sporadically, but have been found to have a familial incidence as well. Familial angiolipomatosis is usually included within the broader spectrum of familial lipomatosis, mirroring the classification of the tumors they encompass.^[3]

While an overwhelming majority of hemangiomas are sporadic, an autosomal dominant pattern has been described.^[4] In spite of similarities between lipomas, angiolipomas, and hemangiomas, individual cases where these three histological types occur together are uncommon and as per our literature review have never been reported.

We describe a patient of familial angiolipomatosis who presented with a dorsal extradural angiolipoma, with

asymptomatic multiple subcutaneous lipomas, angiolipomas, and a large lumbar vertebral hemangioma, representing the spectrum of histopathologically related soft-tissue tumors within the same patient.

Case Report

A 32-year-old man presented with a 20-day history of progressively severe imbalance on walking with bilateral lower limb weakness, gradually increasing numbness extending from the upper abdomen to both lower limbs, and dysesthesia on walking. He also complained of straining at micturition with a weak urinary stream over the last 20 days. On inquiry, he had multiple painless soft-tissue swellings over his left forearm and abdomen, with a family history of similar swellings in his father and two brothers.

On general examination, his swellings were well defined, nonfluctuant, and not associated with tenderness, pruritis, or overlying skin changes. On neurological examination, there was increased tone with Grade 4 power in both lower limbs. Hyperreflexia was elicited in bilateral lower limbs with ill-sustained ankle clonus, bilateral Babinski's sign, and absent abdominal reflex. There was partial sensory loss for touch and pinprick below D6 levels and impaired proprioception in both lower limbs.

Spinal magnetic resonance imaging (MRI) demonstrated a large extradural lesion

Shradha Maheshwari, Eham Lalit Arora¹

Department of Neurosurgery Surgery, Dr. RN Cooper Hospital and HBT Medical College, ¹Department of General Surgery, Grant Government Medical College and Sir JJ Group of Hospitals, Mumbai, Maharashtra, India

Address for correspondence:
Dr. Eham Lalit Arora,
Department of General Surgery, 6th Floor, JJ Hospital Campus, Grant Government Medical College and Sir JJ Group of Hospitals, Byculla, Mumbai - 400 008, Maharashtra, India.
E-mail: ehamarora@gmail.com

Access this article online

Website: www.asianjns.org

DOI: 10.4103/ajns.AJNS_295_17

Quick Response Code:



How to cite this article: Maheshwari S, Arora EL. Exploring a tumor spectrum in a patient with familial angiolipomatosis. Asian J Neurosurg 2019;14:886-9.

This is an open access journal, and articles are distributed under the terms of the Creative Commons Attribution-NonCommercial-ShareAlike 4.0 License, which allows others to remix, tweak, and build upon the work non-commercially, as long as appropriate credit is given and the new creations are licensed under the identical terms.

For reprints contact: reprints@medknow.com

extending from D5 to D8 levels causing severe compression of the cord. The lesion was hyperintense on both T1-weighted imaging (T1WI) and T2WI, with multiple flow voids within the lesion. On fat suppression images, the lesion showed suppression suggesting fatty component in the lesion; however, there was intense contrast enhancement suggestive of spinal epidural angiolioma or spinal arteriovenous malformations (AVM). A hemangioma in L1 vertebral body was also discovered incidentally in the imaging [Figures 1 and 2].

A spinal digital subtraction angiography (DSA) confirmed the diagnosis of an angiolioma with multiple vessels feeding the lesion from right D5 and bilateral D6 and D7 intercostal arteries. There was no early venous drainage, hence ruling out the possibility of an AVM, while supporting the diagnosis of an angiolioma.

Ultrasonography of the forearm swellings revealed three ovoid, well-defined, hyperechoic lesions within the ventral forearm space suggestive of lipomas. A Doppler scan revealed venous flow within peripherally arranged vessels without evidence of intralésional flow in some lesions, most likely representing angiolioma. A histopathological diagnosis could not be obtained to confirm this, as the swelling was not excised.

Embolization of the spinal lesion was deferred in view of the diffuse nature of the feeders. Standard D5–D8 laminectomy was performed. A reddish yellow tumor was identified in the epidural region merging with the normal epidural fat at both the edges. It was friable, soft, and extremely vascular with interspersed spongy and hemorrhagic areas. Vascular supply of the lesion consisted of multiple large epidural feeders which made hemostasis challenging. The tumor was slowly devascularized by coagulating the intercostal feeders and was radically excised to achieve decompression of the cord. Complete excision of the tumor was achieved, which was confirmed on postoperative MRI. Histopathological examination of the excised mass revealed fibrofatty tissue embedded within numerous dilated vessels, lined by single flattened epithelium along with few areas of hyalinization, consistent with an angiolioma.

The patient had immediate postoperative improvement of his weakness, dysesthesia, and urinary complaints and was mobilized on the 2nd postoperative day.

At 6 months' follow-up examination, the patient had Grade 5 power in both lower limbs and complete recovery of sensory deficits. There were no urinary or bowel complaints. At 1-year follow-up, there were no major complaints; however, the multiple subcutaneous swellings had increased in size and number.

Discussion

Angioliomas are considered a histological subtype of lipomas, accounting for 5%–17% of all lipomatous lesions.^[5] These are benign, slow-growing lesions composed of mature adipocytes admixed with abnormal blood vessels, which are usually of capillary size.^[6] Multiple lipomatous lesions in individuals are more likely to be angioliomas, whereas isolated lesions are most commonly simple lipomas.^[4]

Spinal angiolioma is an extremely scarce entity constituting 0.04%–1.2% of all spinal tumors,^[7] with just over 100 cases reported in literature.^[8] However, its clinical and pathological features lean toward hemangiomatous tumors, meriting its distinction from cutaneous angioliomas.^[6]

They are most commonly located at the dorsal and lower cervical region along the midline, conforming to the last site of closure of embryonic neural arch at its rostral end.^[9] These lesions commonly present as sudden-onset weakness and sensory loss in the lower limbs.^[10] The rapid symptom progression may be attributed to vascular engorgement, intralésional hemorrhage, sudden thrombosis, change in capillary caliber, or vascular steal phenomenon.^[7,8,10-13] Vascular engorgement may have been the most likely culprit in our case which was characterized by significant intraoperative blood loss during tumor removal.

Like simple lipomas, spinal angioliomas are hyperintense on both T1WIs and T2WIs.^[14] Provezale and McLendon reported that large hypointense foci within spinal angioliomas on noncontrast T1WIs are correlated with increased vascularity and most lesions enhance with gadolinium administration, whereas T2WI can be variable, but are commonly hyperintense.^[15,16] Thus, a conspicuous differentiating feature of angioliomas on MRI is an intense contrast enhancement which is not seen with lipomas.

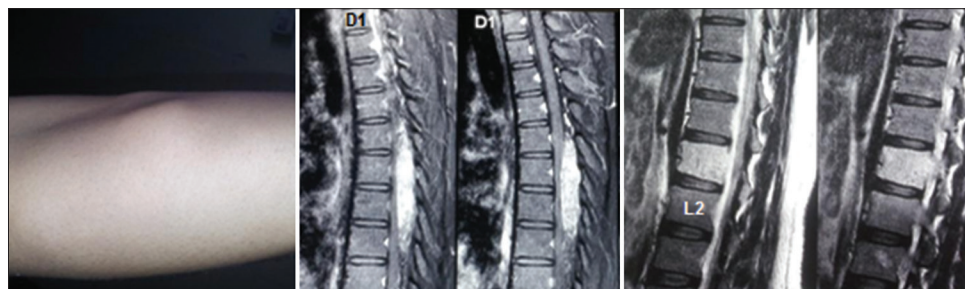


Figure 1: Spectrum of lesions seen in this patient. From left to right: Subcutaneous angiolioma, dorsal epidural angiolioma, and vertebral hemangioma

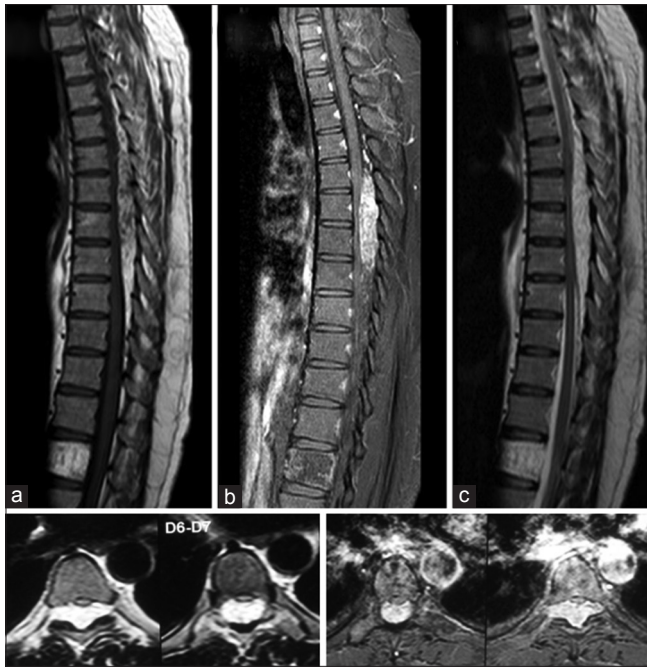

Figure 2: Sagittal and axial cuts of magnetic resonance imaging showing large, extradural, contrast-enhancing lesion extending from D5 to D8 with hemangioma in L1 vertebral body. (a) T1-weighted images. (b) Fat-suppressed postcontrast image. (c) T2-weighted images

DSA helps in delineating the vascular supply and in differentiating spinal angioliomatosis from AVMs. Embolization is not indicated as the feeders are diffuse and may jeopardize the normal supply of the cord. Total surgical excision is considered the best line of management in these cases.^[17]

Spinal angioliomatosis have a significantly higher caliber of vascular component in comparison with their cutaneous counterparts and therefore, may even be considered a distinct entity.^[6,18]

Familial multiple angioliomatosis is a rare and benign condition which is transmitted in an autosomal recessive fashion, although certain cases of autosomal dominant inheritance have been noted.^[19] It has been traditionally included within the broader definition of familial multiple lipomatosis.^[3] The patient at hand is among the second generation within the family to be affected. No third-generation family members are symptomatic thus far, the oldest member being 14 years of age. However, one must note that most cutaneous angioliomatosis arise after the second decade of life, and one cannot rule out the possibility of third-generation family members also suffering from the condition [Figure 3].

Hemangiomas and lipomas are two ends of a continuous histopathological spectrum, where angioliomatosis form the intermediate variety. Lipomas are tumors of mature adipocytes without cellular atypia and are the most common soft-tissue tumors of adulthood.^[20] Angioliomatosis are considered a rarer subtype of lipomas where mature

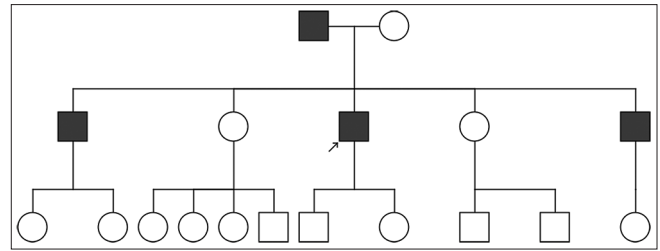


Figure 3: Pedigree chart of the family

adipocytes are dispersed within a prominent vascular stroma. Hemangiomas are endothelial tumors consisting of malformed blood vessels. The more vascular, invasive, and aggressive spinal angioliomatosis would represent a shift toward the hemangioma end of the spectrum. Despite their histopathological correlation and their common mesenchymal origin, these tumors have markedly varied pathogenesis not only between themselves, but also between subtypes of the same tumor. Notably, genetic aberrations seen in cutaneous lipomas are not present in angioliomatosis.^[21] Given their mottled pathologic origin, the simultaneous occurrence of multiple tumor types within the same patient seems striking, more so when considering the familial nature of his affliction. There is only one case reported in literature which describes the occurrence of spinal angioliomatosis in a case of familial lipomatosis.^[22] Our patient is unique in that he probably represents a case of familial angioliomatosis with multiple subcutaneous lesions, presenting with an associated dorsal angioliomatosis as well as a lumbar vertebral hemangioma.

Conclusion

While lipomas, angioliomatosis, and hemangiomas represent a continuous histological spectrum of mesenchymal tumors, they differ greatly in their pathogenesis. Spinal angioliomatosis are uncommon neoplasms, the origin of which is uncertain. Although they are considered conspicuously dissimilar to their cutaneous counterparts, we report the coincidence of both spinal and cutaneous lesions in this case of familial angioliomatosis with lumbar vertebral hemangioma. Their coexistence in a singular patient with close histopathological features makes us hypothesize that the three lesions are nothing but natural progression of a single tumor type - either a hemangioma’s vascular component gradually regresses to form an angioliomatosis and eventually lipoma or a lipoma acquires progressive vascularity to reverse the aforementioned trend.

Declaration of patient consent

The authors certify that they have obtained all appropriate patient consent forms. In the form, the patient has given his consent for his images and other clinical information to be reported in the journal. The patient understand that his name and initials will not be published and due efforts will be made to conceal identity, but anonymity cannot be guaranteed.

Financial support and sponsorship

Nil.

Conflicts of interest

There are no conflicts of interest.

References

- Pagni CA, Canavero S. Spinal epidural angioliomatosis: Rare or unreported? *Neurosurgery* 1992;31:758-64.
- Hemavathy S, Roy S, Kiresur A. Intraosseous angioliomatosis of the mandible. *J Oral Maxillofac Pathol* 2012;16:283-7.
- Abbasi NR, Brownell I, Fangman W. Familial multiple angioliomatosis. *Dermatol Online J* 2007;13:3.
- Blei F, Walter J, Orlov SJ, Marchuk DA. Familial segregation of hemangiomas and vascular malformations as an autosomal dominant trait. *Arch Dermatol* 1998;134:718-22.
- Kacar S, Kuran S, Temucin T, Odemis B, Karadeniz N, Sasmaz N, *et al.* Rectal angioliomatosis: A case report and review of literature. *World J Gastroenterol* 2007;13:1460-5.
- Hattori H. Epidural angioliomatosis is histologically distinct from its cutaneous counterpart in the calibre and density of its vascular component; a case report with review of the literature. *J Clin Pathol* 2005;58:882-3.
- Andaluz N, Balko G, Bui H, Zuccarello M. Angioliomatosis of the central nervous system. *J Neurooncol* 2000;49:219-30.
- Oge HK, Söylemezoglu F, Rousan N, Ozcan OE. Spinal angioliomatosis: Case report and review of literature. *J Spinal Disord* 1999;12:353-6.
- Liebeskind AL, Azar-Kia B, Batnitzky S, Schechter MM. Intraspinous lipomas. *Neuroradiology* 1974;7:198-200.
- Hungs M, Paré LS. Spinal angioliomatosis: Case report and literature review. *J Spinal Cord Med* 2008;31:315-8.
- Boockvar JA, Black K, Malik S, Stanek A, Tracey KJ. Subacute paraparesis induced by venous thrombosis of a spinal angioliomatosis: A case report. *Spine (Phila Pa 1976)* 1997;22:2304-8.
- Labram EK, el-Shunnar K, Hilton DA, Robertson NJ. Revisited: Spinal angioliomatosis – three additional cases. *Br J Neurosurg* 1999;13:25-9.
- Preul MC, Leblanc R, Tampieri D, Robitaille Y, Pokrupa R. Spinal angioliomatosis. Report of three cases. *J Neurosurg* 1993;78:280-6.
- Samdani AF, Garonzik IM, Jallo G, Eberhart CG, Zahos P. Spinal angioliomatosis: Case report and review of the literature. *Acta Neurochir (Wien)* 2004;146:299-302.
- Provenzale JM, McLendon RE. Spinal angioliomatosis: MR features. *AJNR Am J Neuroradiol* 1996;17:713-9.
- Preul MC, Leblanc R. MRI in the diagnosis of spinal extradural angioliomatosis. *Br J Neurosurg* 1993;7:328.
- Leu NH, Chen CY, Shy CG, Lu CY, Wu CS, Chen DC, *et al.* MR imaging of an infiltrating spinal epidural angioliomatosis. *AJNR Am J Neuroradiol* 2003;24:1008-11.
- Stanford University School of Medicine. Surgical Pathology Criteria – Lipoma Variant: Angioliomatosis; 2016. Available from: <http://www.surgpathcriteria.stanford.edu/softfat/lipoma/angioliomatosis.html>. [Last accessed on 2016 Apr 28].
- Cina SJ, Radentz SS, Smialek JE. A case of familial angioliomatosis with Lisch nodules. *Arch Pathol Lab Med* 1999;123:946-8.
- Bancroft LW, Kransdorf MJ, Peterson JJ, O'Connor MI. Benign fatty tumors: Classification, clinical course, imaging appearance, and treatment. *Skeletal Radiol* 2006;35:719-33.
- Sciot R, Akerman M, Dal Cin P, De Wever I, Fletcher CD, Mandahl N, *et al.* Cytogenetic analysis of subcutaneous angioliomatosis: Further evidence supporting its difference from ordinary pure lipomas: A report of the CHAMP Study Group. *Am J Surg Pathol* 1997;21:441-4.
- Bordet R, Ghawche F, Destée A. Epidural angioliomatosis and multiple familial lipomatosis. *Rev Neurol (Paris)* 1991;147:740-2.