ESC European Society of Cardiology
European Heart Journal - Case Reports (2025) **9**, ytaf019
https://doi.org/10.1093/ehjcr/ytaf019

GRAND ROUND
Heart failure

Successful treatment of immune checkpoint inhibitor-associated fulminant myocarditis with abatacept and ruxolitinib: a case report

Elena Wadden [1], Carol Lai[2], Petros Grivas[1,3], Shailender Bhatia[1,3], Andrew J. Portuguese[3,4], Joe-Elie Salem[5], Javid J. Moslehi[6], and Richard K. Cheng[7]*

[1]Division of Cardiology, University of Washington Medical Center, 1959 NE Pacific Street, Health Sciences Building, Seattle, WA 98195, USA; [2]Department of Cardiology, Straub Medical Center, 888 S King St, Honolulu, HI 96813, USA; [3]Clinical Research Division, Fred Hutchinson Cancer Center, P.O. Box 19024, Seattle, WA 98109, USA; [4]Division of Hematology and Oncology, University of Washington School of Medicine, 825 Eastlake Ave. E, Seattle, WA 98109, USA; [5]Department of Pharmacology, Sorbonne Université, INSERM, AP-HP, CIC-1901, Pitié-Salpêtrière Hospital, Paris, France; [6]Section of Cardio-Oncology and Immunology, University of California San Francisco, Smith Cardiovascular Research Building, 535 Mission Bay Blvd. South, San Francisco, CA 94158 , USA; and [7]Division of Cardiology, University of Washington Medical Center, 1959 NE Pacific Street, Health Sciences Building, Suite #A506D Box 356422 Seattle, WA 98195, USA

Received 30 June 2024; revised 23 September 2024; accepted 13 January 2025; online publish-ahead-of-print 17 February 2025

Background Immune checkpoint inhibitors (ICIs) are a class of cancer immunotherapy with growing indications for treatment of various malignancies. Immune checkpoint inhibitors are monoclonal antibodies that block inhibitory pathways in immune cells, including cytotoxic T lymphocyte antigen-4 (CTLA4), programmed death 1 receptor (PD1), and programmed cell death ligand-1 (PDL1), to activate the immune system. However, these agents can disrupt self-tolerance and lead to immune-related adverse events. Fulminant myocarditis, a feared complication of ICIs, can be highly fatal, and there is a need for effective treatment options.

Case summary A 70-year-old patient with recurrent metastatic disease of urothelial carcinoma subsequently developed fulminant myocarditis after receiving eight cycles of pembrolizumab. He developed cardiogenic shock and required inotropes and a percutaneous microaxial flow pump placement for temporary mechanical circulatory support. He received methylprednisolone initially and then was started on second-line immunosuppression agents, ruxolitinib and abatacept, for steroid-refractory myocarditis. Abatacept is thought to inhibit activation of T-cell CTLA4 and PD1/PDL1 pathways and reverse ICI-activated pathways. Ruxolitinib is a Janus kinase inhibitor that impairs immune activation through suppressing cytokine sensing and production and T-cell activation. After these treatments, the patient subsequently clinically improved and his myocarditis resolved.

Discussion This case highlights ICI myocarditis refractory to corticosteroids leading to treatment with second-line immunosuppression. As immunotherapies are increasingly applied to a broader range of cancers, further research is needed to evaluate the optimal treatment strategy for ICI-related myocarditis and other immune-related adverse events.

Keywords Abatacept • Immunotherapy • Myocarditis • Cardiomyopathy • Ruxolitinib • Case report

ESC curriculum 6.9 Cardiac dysfunction in oncology patients • 7.3 Critically ill cardiac patient • 6.4 Acute heart failure

* Corresponding author. Tel: +206 221 6507, Fax: +206 616 8188, Email: rkcheng@uw.edu
Handling Editor: Emmanouil Androulakis
Peer-reviewers: Takeshi Kitai; Abdelsalam Bensaaud
Compliance Editor: Sibghat Tul Llah
© The Author(s) 2025. Published by Oxford University Press on behalf of the European Society of Cardiology.
This is an Open Access article distributed under the terms of the Creative Commons Attribution-NonCommercial License (https://creativecommons.org/licenses/by-nc/4.0/), which permits non-commercial re-use, distribution, and reproduction in any medium, provided the original work is properly cited. For commercial re-use, please contact reprints@oup.com for reprints and translation rights for reprints. All other permissions can be obtained through our RightsLink service via the Permissions link on the article page on our site—for further information please contact journals.permissions@oup.com.

Learning points

- Immune checkpoint inhibitors (ICIs) are monoclonal antibodies that block inhibitory pathways in immune cells but can disrupt self-tolerance and lead to immune-related adverse events.
- Immune checkpoint inhibitor myocarditis, although infrequent with a roughly 1% incidence rate, can be highly fatal with a mortality rate of 25–50%. Second-line immunosuppression regimens such as abatacept and ruxolitinib are emerging treatments and may be an effective treatment strategy for steroid-refractory ICI myocarditis.

Primary specialties involved other than cardiology

Oncology.

Summary figure

Timeline of clinical course. Timeline of patient presentation and clinical course begins with index presentation to the hospital with the development of acute fulminant myocarditis and summarizes subsequent key events, biomarkers, and cardiac imaging findings following initial admission.

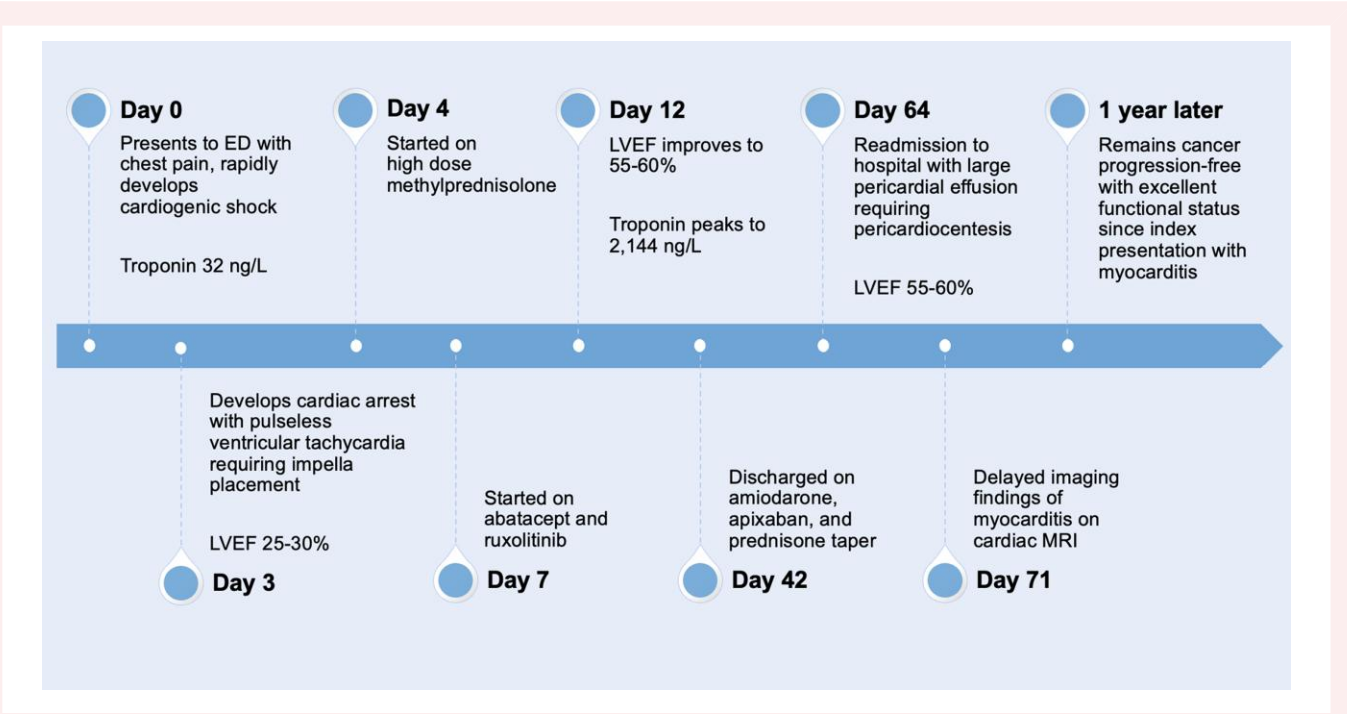

Introduction

Immune checkpoint inhibitors (ICIs) are a class of cancer immunotherapy with growing indications for treatment of various malignancies. Immune checkpoint inhibitors are monoclonal antibodies that block inhibitory pathways in immune cells, including cytotoxic T lymphocyte antigen-4 (CTLA4), programmed death 1 receptor (PD1), and programmed cell death ligand-1 (PDL1), to activate the immune system. However, these agents can disrupt self-tolerance and lead to immune-related adverse events. Fulminant myocarditis, which although infrequent with a roughly 1% incidence rate, can be highly fatal with a mortality rate of 25–50%.[1] Treatment guidelines generally recommend stopping ICI, supportive management, and corticosteroid therapy.[2] However, fatality rate has remained high.[1] There is an urgent need for effective treatment options for severe fulminant myocarditis.

Case

A 70-year-old male with past medical history of chronic kidney disease, Hodgkin's lymphoma (in remission), hyperlipidaemia, hypertension, and benign prostatic hypertrophy was diagnosed with recurrent metastatic disease 2 years after right nephroureterectomy for urothelial carcinoma. At the time of diagnosis of metastatic disease, Eastern Cooperative Oncology Group Performance Status was 1. Computed tomography scan of chest, abdomen, and pelvis showed a right retroperitoneal infiltrating pericaval soft tissue mass, with biopsy confirming metastatic recurrence. He initially received 3 cycles of gemcitabine and carboplatin, and follow-up imaging showed stable disease.

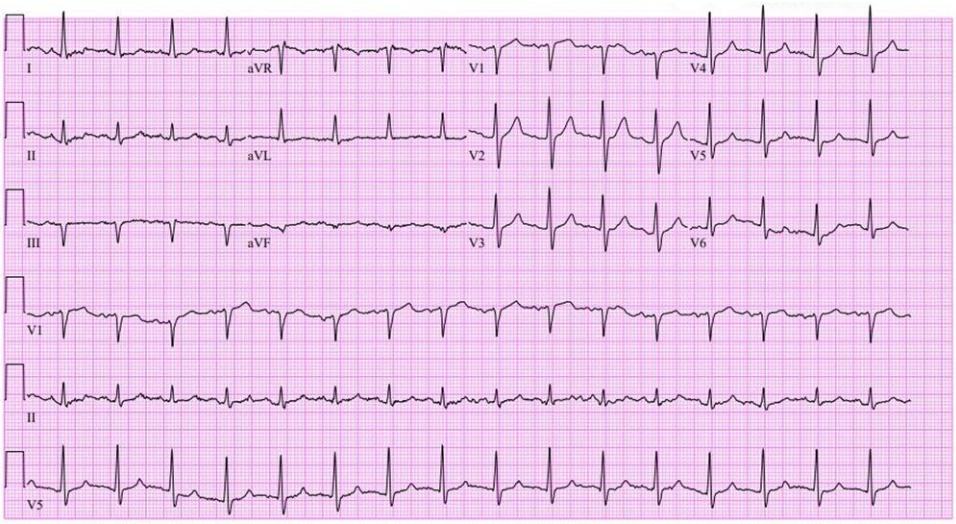

Figure 1 Electrocardiogram at time of presentation showed normal sinus rhythm with question of inferior infarction with Q wave in lead III and possibly in AVF.

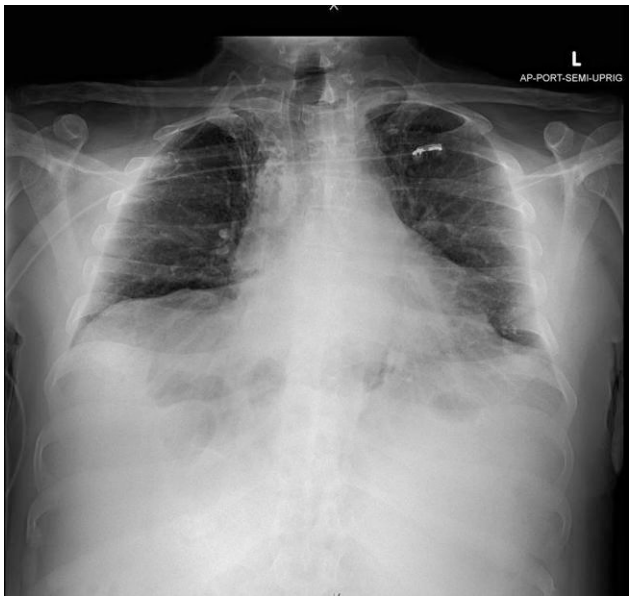

Figure 2 Chest radiograph at time of presentation showed clear lungs, calcified right upper and lower paratracheal lymph nodes, and no evidence of pulmonary oedema.

His treatment was subsequently switched to pembrolizumab, receiving 8 doses total at 200 mg/dose every 21 days. Follow-up imaging showed partial response with regression of the pericaval mass.

Approximately 2 weeks after receiving his eighth dose of pembrolizumab, he presented to the emergency room with new-onset chest pain. Electrocardiogram (ECG) showed sinus rhythm (*Figure 1*), but high-sensitivity troponin T was elevated at 32 ng/L (ref < 20 ng/L). Chest radiograph showed clear lungs (*Figure 2*). He rapidly decompensated with peak elevation in troponin to 2144 ng/L and developed cardiogenic shock with severe left ventricular (LV) dysfunction (*Figures 3–5*, Supplementary material online). On examination, temperature was 36.2°C, the blood pressure was 81/48 mmHg, pulse was 120 beats per minute, his respiratory rate was 19 breaths per minute, and saturation was 96% on ambient air. He required inotropes and a percutaneous microaxial flow pump placement for temporary mechanical circulatory support (MCS) and then had sustained ventricular tachycardia resulting in cardiac arrest requiring several rounds of cardiopulmonary resuscitation and pericardial tamponade requiring urgent pericardiocentesis.

After cardiac arrest, he was admitted to the intensive care unit, intubated and paralyzed, with temporary MCS support and on multiple

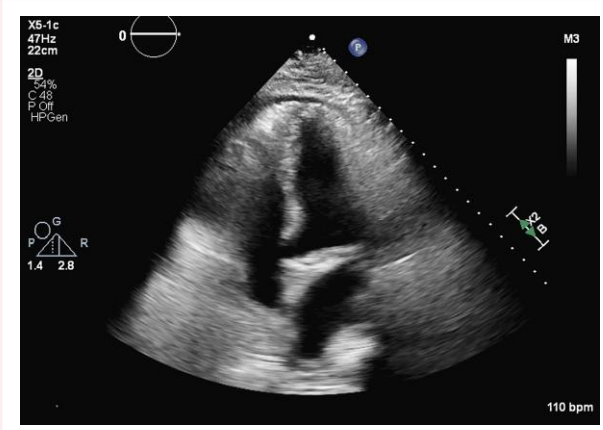

Figure 3 Apical four-chamber view on transthoracic echocardiogram.

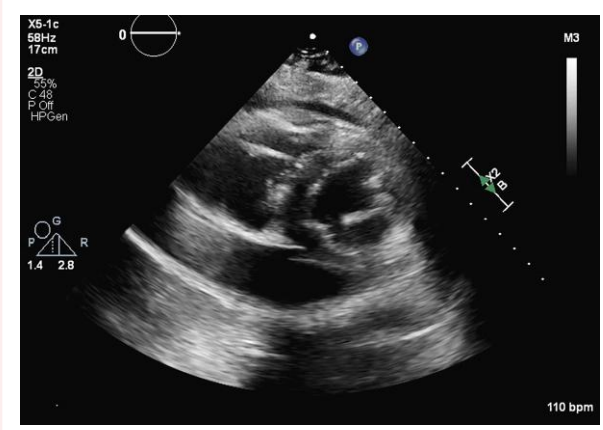

Figure 4 Short-axis view on transthoracic echocardiogram.

inotropes. Admission transthoracic echocardiogram (TTE) showed decreased LV ejection fraction of 25% (from baseline of 55–60%). He additionally underwent left heart catheterization, which showed normal coronary arteries. Other work-up was negative for infectious causes.

Due to his rapidly progressive severe heart failure symptoms resulting in cardiogenic shock, a presumptive diagnosis of fulminant ICI myocarditis was made. He was started on 500 mg IV BID methylprednisolone. Despite first-line high-dose steroid administration, he remained in cardiogenic shock requiring Impella support after treatment with steroids alone. An endomyocardial biopsy was not performed at the time of admission due to the lack of procedural access for endomyocardial biopsy at the hospital, his clinical instability at the time of presentation, and increased risk due to the need for systemic anticoagulation for his temporary MCS. Seven days after admission, abatacept was started at 20 mg/kg administered on Days 0, 5, and 12, as well as ruxolitinib at 15 mg twice daily for 1 month. No clinically significant side effects were noted, and he improved clinically. Cardiac magnetic resonance imaging (MRI) after initiating treatment (Day 20) showed recovery of LV ejection fraction to 54%, subendocardial late gadolinium enhancement (LGE) in the inferolateral LV but without evidence of active myocardial inflammation or myocarditis based on T2 imaging sequences.

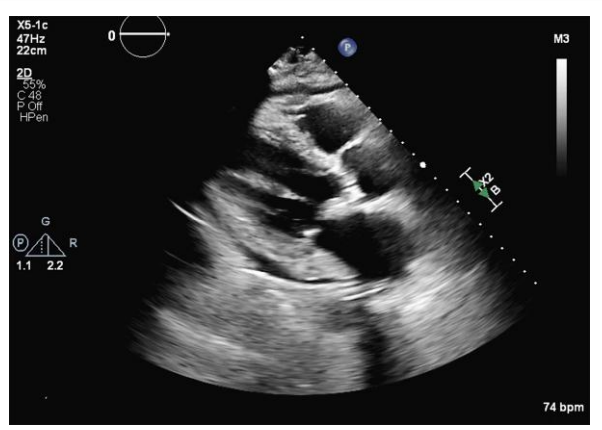

Figure 5 Parasternal long-axis view on transthoracic echocardiogram.

The patient was eventually discharged around 6 weeks after admission on amiodarone, apixaban, and prednisone taper. However, 2 months after his index presentation with cardiogenic shock, he developed chest pain and was found to have pulmonary embolism and recurrent pericardial tamponade requiring repeat pericardiocentesis. Repeat cardiac MRI showed full thickness LGE in the basal inferolateral wall with elevation in native T1 mapping of 1124 ms; T2 quantification was limited due to artefact. Due to concern for stuttering myocarditis, he was treated with solumedrol IV again and discharged on oral corticosteroids with a slow taper plan. Since then, he remains stable from a cardiac standpoint, without evidence of cancer progression and excellent functional status with the most recent follow-up 18 months since his index presentation with myocarditis.

Discussion

We present a case of ICI-associated myocarditis presenting with cardiogenic shock that demonstrated a remarkable and moderate-term sustained response to combination treatment with corticosteroids, abatacept and ruxolitinib. Our case highlights several emerging concepts relevant to this toxicity: (i) administration of abatacept as rescue therapy for ICI-associated myocarditis that did not respond to high-dose steroids; (ii) addition of the JAK inhibitor ruxolitinib, which may enhance efficacy of abatacept by exerting rapid additive and synergistic effect; (iii) the delay in cardiac MRI findings consistent with myocarditis that has been previously described[3] and (iv) the severity of cardiogenic shock that resolved with treatment.

Based on the 2022 European Society of Cardiology's (ESC) guidelines, the patient met clinical criteria for ICI myocarditis based on receiving ICI therapy 2 weeks before developing (i) a new troponin elevation with (ii) meeting a minimum of two minor criteria including clinical syndrome (fatigue, myalgias, chest pain, shortness of breath, palpitations, and cardiogenic shock), ECG abnormalities including ventricular arrhythmia, and an acute severe decline in LV systolic function (demonstrated with TTE), in addition to suggestive cardiac MRI findings.[4] While eosinophilic myocarditis and giant cell myocarditis were on the differential for fulminant myocarditis, based on the clinical features and history of ICI exposure, the presumptive diagnosis of fulminant ICI myocarditis was most likely and in alignment with the ESC guidelines. Eosinophilic myocarditis was considered but thought to be less likely as this patient did not have peripheral eosinophilia and the cardiac MRI did not demonstrate diffuse subendocardial LGE that is often seen with eosinophilic myocarditis. Additionally, if the patient had eosinophilic myocarditis or giant cell

myocarditis, up-front steroids can also be considered in the treatment paradigm. We excluded acute coronary syndrome as there was no coronary artery disease on cardiac catheterization, in addition to a systemic infectious work-up to rule out infectious aetiology for myocarditis.

Although an endomyocardial biopsy would be ideal for confirming the diagnosis and excluding other potential causes of fulminant myocarditis, such as eosinophilic or giant cell myocarditis, it was not performed in this case due to the patient's haemodynamic instability, limited access to the procedure at the treating centre, and the need for systemic anticoagulation with temporary MCS. The lack of endomyocardial biopsy reflects real-world clinical practice in many instances, where procedural risks or logistical constraints may limit access. In such cases, clinicians must remain vigilant in excluding alternative diagnoses before proceeding with treatment for presumed ICI myocarditis.

For initial treatment of fulminant ICI-associated myocarditis, the ESC guidelines have a Class I recommendation on initial treatment with methylprednisolone 500–100 mg IV per day for the first 3–5 days.[4] A case series of 126 patients with ICI-related myocarditis showed that patients who received high-dose corticosteroids (methylprednisolone 500–1000 mg/day) compared with low-dose (<60 mg/day) corticosteroids had a 73% lower risk of major adverse cardiovascular events (MACEs).[5] Additionally, patients receiving corticosteroids within 24 h of admission had a MACE rate of 7.0% compared with those initiating treatment between 24 and 72 h (34.3%) and those initiating treatment at >72 h (85.1%) ($P < 0.001$). The reduction in risk of MACE for shorter time of initiation and higher initial dose suggests that myocardial damage may be attenuated by early and intensive corticosteroid therapy.

In addition to corticosteroids, the role of immunosuppressive therapies targeting T lymphocytes in ICI myocarditis remains unclear. In accordance, the ESC guidelines acknowledge the lack of data to recommend a specific second-line immunosuppression regimen and recommend multidisciplinary discussion.[4] While exact indications are not well defined, escalation of therapy is frequently considered in the following scenarios: (i) first-line therapy in severe cases of fulminant myocarditis with multiorgan dysfunction and (ii) cases refractory to initial high-dose corticosteroids alone. The optimal timing or sequencing of these therapies requires further study. An emerging option is the use of abatacept, as a CTLA4 immunoglobulin fusion protein-binding CD80/CD86 on antigen-presenting cells and prevents ligands from interacting with T-cell co-stimulatory receptor CD28.[6] By inhibiting activation of T-cell CTLA4 and PD1/PDL1 pathways, T cells specifically reverse ICI-activated pathways. A CTLA4/PD1 genetic knockout mice model showed that abatacept led to a significant reduction in cardiac immune activation and increased survival rates in ICI myocarditis.[7] A first clinical case of ICI-induced fulminant myocarditis demonstrated successful treatment with abatacept via receptor occupancy and tailored dosing based on a threshold of occupancy of CD86RO $\geq$ 80%.[8] This concept was further expanded recently in a prospective ICI myocarditis case series, showing that high-dose abatacept was necessary to reach these objectives (in general three injections of 20 mg/kg within the first 2 weeks as a starting dose).[9] Currently, abatacept is in clinical trials for use in mild–moderate (NCT05335928) and severe ICI myocarditis cases (NCT05195645).[10] Abatacept is appealing on a mechanistic level as it directly opposes the pathway of T-cell activation by ICI by inhibiting T-cell interaction with antigen-presenting cells.

Despite the promising immune mechanism of abatacept, an important consideration is the addition of ruxolitinib as an adjunctive treatment for ICI-related myocarditis. Abatacept is thought to have a slow onset, with a mouse model demonstrating that myocardial immune infiltration was attenuated after 10 weeks of abatacept but minimal at 2 weeks.[7] Therefore, in rapid development of fulminant myocarditis, the use of faster-acting immunosuppressive agents or combinations may be appropriate. In addition to corticosteroids, other fast-acting combinations should be considered. Ruxolitinib is a Janus kinase (JAK) inhibitor that impairs immune activation through suppressing cytokine sensing and production and T-cell activation. A CTLA4/PD1 mouse model of ICI myocarditis demonstrated that JAK2 and JAK-STAT signalling pathways were substantially upregulated in cardiac tissue compared with control mice.[9] Based on these findings, a study of 30 patients with ICI-related myocarditis and concurrent myositis leading to respiratory failure found that patients receiving both abatacept and ruxolitinib had a myotoxicity-related fatality of 3.4% compared with 60% in the standard of care cohort ($P < 0.001$).[9] These preliminary data suggest that ruxolitinib may likely enhance efficacy of abatacept by exerting rapid additive and/or synergistic effect by decreasing CD86 expression on macrophages and inactivating T cells. The exact mechanism, toxicity, and efficacy of this combination require further investigation in prospective trials.

This case also highlights diagnostic imaging challenges with ICI myocarditis. Magnetic resonance imaging allows for the evaluation of myocardial oedema, inflammation, and fibrosis and remains an important and standard imaging modality for the diagnosis of myocarditis, although endomyocardial biopsy is the ultimate diagnostic method (not done in this case due to the rapid development and clinical deterioration). The patient's initial cardiac MRI on Day 20 demonstrated focal LGE but did not fulfill other diagnostic criteria for acute inflammation,[11] but a repeat cardiac MRI on Day 70 demonstrated findings consistent with active myocarditis. The delayed imaging findings are in alignment with an ICI-related myocarditis registry, which showed LGE in 48% and T2 elevation in 28% of patients on initial presentation.[3] In the registry, the presence of LGE was 21.6% when MRI was performed within 4 days of admission and then rose to 72% when performed on Day 4 or later. Because myocardial fibrosis and scarring manifesting as LGE are considered a subacute or chronic feature of myocardial inflammation in myocarditis, imaging detection of LGE in patients with ICI-related myocarditis may be delayed.

To conclude, we present a case of fulminant ICI myocarditis presenting with cardiogenic shock that was refractory to standard first-line high-dose corticosteroids, but that was effectively treated with abatacept plus ruxolitinib. Many questions remain including whether biomarkers can predict the development of such adverse events, which patients may benefit from therapy beyond corticosteroids as first-line treatment, what the optimal first-line and salvage/rescue therapy should be in these patients, and what the long-term complications and prognostic implications are of this treatment. As immunotherapies are increasingly applied to a broader range of cancers, further research is needed to evaluate the optimal treatment strategy for ICI-related myocarditis and, also, other immunotherapy-related adverse events.

Lead author biography

Dr Elena Wadden is an internal medicine resident at University of Washington.

Supplementary material

Supplementary material is available at *European Heart Journal – Case Reports* online.

Consent: The patient consented to the publication of this case report in compliance with the COPE guidelines.

Conflict of interest: P.G. (last 2 years): consulting: Aadi Bioscience, AbbVie, Asieris Pharmaceuticals, Astellas, AstraZeneca, BostonGene, Bristol Myers Squibb, CG Oncology, Dyania Health, Fresenius Kabi, G1 Therapeutics, Gilead Sciences, Guardant Health, ImmunityBio, Janssen, Lucence, Merck KGaA, MSD, Pfizer, PureTech, Roche, SeaGen, Silverback Therapeutics, and Strata Oncology and research funding to institution: ALX Oncology, Acrivon Therapeutics, Bavarian Nordic, Bristol Myers Squibb, Debiopharm Group, Genentech, G1 Therapeutics, Gilead Sciences, GSK, Merck KGaA, Mirati Therapeutics, MSD, Pfizer, QED Therapeutics. J.J.M.: consulting: Novartis, Bristol-Myers Squibb, Deciphera, Takeda, AstraZeneca, Regeneron, Kiniksa Pharmaceuticals, Daiichi Sankyo, BeiGene, IQVIA, AskBio, Labcorp, Paladin, Bitterroot Bio, Repare Therapeutics, and Cytokinetics. J.-E.S. participated to advisory boards or consultancy from BMS, Novartis, Banook, EISAI, Bayer, IPSEN, AstraZeneca, and BeiGene. He has patents related to the treatment of ICI-related immune adverse events. J.J.M. and J.-E.S. are co-inventors of a patent related to the use of abatacept in the treatment of ICI myocarditis. S.B.: advisory board/consultant (with honorarium): Bristol-Myers Squibb and Incyte; research grants (to institution): Bristol-Myers Squibb, EMD-Serono, Merck, Novartis, Immune Design, Incyte, Oncosec, Nantkwest, Exicure, Nektar, Amphivena, Checkmate, Xencor, and 4SC; and stock/equity: Moderna. The other authors report no relevant conflicts of interest.

Funding: This publication was partially funded by the Alpha Phi Foundation.

Data availability

Non-identifiable data underlying this article will be made available upon reasonable request to the corresponding author.

References

1. Nguyen LS, Cooper LT, Kerneis M, Funck-Brentano C, Silvain J, Brechot N, et al. Systematic analysis of drug-associated myocarditis reported in the World Health Organization pharmacovigilance database. *Nat Commun* 2022;**13**:25.
2. Schneider BJ, Naidoo J, Santomasso BD, Lacchetti C, Adkins S, Anadkat M, et al. Management of immune-related adverse events in patients treated with immune checkpoint inhibitor therapy: ASCO guideline update. *J Clin Oncol* 2021;**39**:4073–4126.
3. Zhang L, Awadalla M, Mahmood SS, Nohria A, Hassan MZO, Thuny F, et al. Cardiovascular magnetic resonance in immune checkpoint inhibitor-associated myocarditis. *Eur Heart J* 2020;**41**:1733–1743.
4. Lyon AR, López-Fernánde T, Couch LS, Asteggiano R, Aznar MC, Bergler-Klei J, et al. 2022 ESC guidelines on cardio-oncology developed in collaboration with the European Hematology Association (EHA), the European Society for Therapeutic Radiology and Oncology (ESTRO) and the International Cardio-Oncology Society (IC-OS): developed by the task force on cardio-oncology of the European Society of Cardiology (ESC). *Eur Heart J* 2022;**43**:4229–4361.
5. Zhang L, Zlotoff DA, Awadalla M, Mahmood SS, Nohria A, Hassan MZO, et al. Major adverse cardiovascular events and the timing and dose of corticosteroids in immune checkpoint inhibitor-associated myocarditis. *Circulation* 2020;**141**:2031–2034.
6. Salem JE, Allenbach Y, Vozy A, Brechot N, Johnson DB, Moslehi JJ, et al. Abatacept for severe immune checkpoint inhibitor-associated myocarditis. *N Engl J Med* 2019;**380**:2377–2379.
7. Wei SC, Meijers WC, Axelrod ML, Anang NAAS, Screever EM, Wescott EC, et al. A genetic mouse model recapitulates immune checkpoint inhibitor-associated myocarditis and supports a mechanism-based therapeutic intervention. *Cancer Discov* 2021;**11**:614–625.
8. Nguyen LS, Bretagne M, Arrondeau J, Zahr N, Ederhy S, Abbar B, et al. Reversal of immune-checkpoint inhibitor fulminant myocarditis using personalized-dose-adjusted abatacept and ruxolitinib: proof of concept. *J Immunother Cancer* 2022;**10**:e004699.
9. Salem JE, Bretagne M, Abbar B, Leonard-Louis S, Ederhy S, Redheuil A, et al. Abatacept/ruxolitinib and screening for concomitant respiratory muscle failure to mitigate fatality of immune-checkpoint inhibitor myocarditis. *Cancer Discov* 2023;**13**:1100–1115.
10. Reynolds KL, Zlotoff DA, Mooradian M, Zubiri L, Ridker P, Neilan TG. Abatacept for immune checkpoint inhibitor associated myocarditis (ATRIUM): Phase 3, investigator-initiated, randomized, placebo-controlled study to evaluate the efficacy and safety of abatacept compared to placebo in hospitalized patients with immune checkpoint inhibitor associated myocarditis. *J Clin Oncol* 2023;**41**:TPS2680.
11. Ferreira VM, Schulz-Menger J, Holmvang G, Kramer CM, Carbone I, Sechtem U, et al. Cardiovascular magnetic resonance in nonischemic myocardial inflammation: expert recommendations. *J Am Coll Cardiol* 2018;**72**:3158–3176.