



OPEN ACCESS

# Transdermal rotigotine patch in Parkinson's disease with a history of intestinal operation

Takashi Ogawa, Genko Oyama, Nobutaka Hattori

Department of Neurology,  
Juntendo University Faculty of  
Medicine, Tokyo, Japan

**Correspondence to**  
Dr Genko Oyama,  
g\_oyama@juntendo.ac.jp

Accepted 30 May 2018

## SUMMARY

A 42-year-old Japanese man with a history of small intestine resection and familial Mediterranean fever was referred to our hospital for a second opinion on parkinsonism. At the age of 35, the patient attended a hospital due to impaired left-hand movement and resting tremor. He was previously diagnosed with multiple system atrophy based on the lack of effectiveness of levodopa treatment. With suspicion of malabsorption due to his history of ileostomy, a levodopa challenge test with levodopa intravenous infusion was conducted, and revealed a 65% improvement in Movement Disorder Society-sponsored revision of the Unified Parkinson's Disease Rating Scale part III. Therefore, diagnosis of Parkinson's disease was made and a transdermal rotigotine patch was selected as a treatment. This treatment dose-dependently improved the patient's symptoms. The transdermal drug delivery should be considered when patients show dose failure due to malabsorption.

## BACKGROUND

There are few reports of transdermal drugs improving Parkinson's disease (PD) in patients who have significant malabsorption.

## CASE PRESENTATION

A 42-year-old, right-handed Japanese man with a history of small intestine resection due to superior mesenteric artery obstruction was referred to our hospital for a second opinion on parkinsonism. The patient did not have family history of PD, but had a history of familial Mediterranean fever.

At the age of 35, the patient visited a hospital due to impaired left-hand movement and resting tremor. He was diagnosed with multiple system atrophy because of the lack of effectiveness of levodopa/carbidopa (up to 500 mg/day) and pramipexol (up to 1.5 mg) treatment and based on imaging findings, such as bilateral decrease of dopamine transporter imaging, normal 123I-Meta-iodobenzylguanidine (MIBG) myocardial scintigraphy and normal magnetic resonance imaging. Despite taking levodopa/carbidopa (100/10) 500 mg, his symptoms did not improve. The patient developed right-hand tremor and bradykinesia in both legs, which affected his daily activities. Neurological examination on admission revealed left-side dominant parkinsonism without evidences of autonomic dysfunction, dementia, or pyramidal tract sign.

We suspected malabsorption of levodopa/carbidopa because of his history of ileostomy. A levodopa challenge test with levodopa intravenous infusion

was conducted, and revealed a 65% improvement (43 to 15 points) in Movement Disorder Society-sponsored revision of the Unified Parkinson's Disease Rating Scale (MDS-UPDRS) with 200 mg levodopa intravenous infusion. Diagnosis of PD was made according to the diagnostic criteria of the UK Parkinson's Disease Society Brain Bank.

## TREATMENT

A transdermal rotigotine patch was selected as treatment to bypass gastrointestinal absorption of medication. We gradually increased rotigotine from 2 mg/24 hours to 16 mg/24 hours.

## OUTCOME AND FOLLOW-UP

This treatment dose-dependently improved the patient's symptoms (figure 1). Ultimately, the patient's parkinsonism was well controlled with only rotigotine, and his MDS-UPDRS score improved from 44 to 11 points.

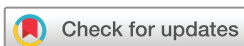## DISCUSSION

In the present case, levodopa responsiveness was masked by malabsorption due to a previous small intestinal operation, which was revealed by a levodopa infusion test. Subsequently, transdermal drug delivery resolved this problem.


PD can be comorbid with gastrointestinal issues, such as gastroparesis, constipation and small intestinal bacterial overgrowth, with a prevalence ranging from 3.7% to 16.7%.<sup>1</sup> These comorbidities may cause malabsorption of anti-Parkinsonian medications, possibly working in combination with the intake of high-protein foods and antacids, such as proton pump inhibitors.<sup>2</sup> This absorption problem may lead to motor fluctuations such as "delayed on", "wearing off" and drug failure ("no on") in advanced stages of the disease. Furthermore, malabsorption may lead to diagnostic delay or misdiagnosis in the early stages of disease.<sup>3</sup>

Gastrointestinal problems can be induced by surgery such as resection of the digestive tract or a severe gastrointestinal ulcer. It is difficult to control parkinsonism in the perioperative period and other states in which intake is impaired. To date, levodopa infusion, amantadine infusion, subcutaneous administration of apomorphine and transdermal administration of rotigotine have been reported to successfully control parkinsonism in the perioperative period.<sup>4</sup> In addition, liquid formulations of levodopa such as Meledopa may be an option for patients with gastrointestinal problems.<sup>5</sup>

The use of a transdermal rotigotine patch is one method for avoiding absorption problems.



**To cite:** Ogawa T, Oyama G, Hattori N. *BMJ Case Rep* Published Online First: [please include Day Month Year]. doi:10.1136/bcr-2017-223722



**Figure 1** Clinical course of patient. Patient was hospitalised for 15 days. Patient showed malabsorption of levodopa/carbidopa. Rotigotine treatment was prescribed and dosage was gradually increased. The patient no longer takes levodopa/carbidopa. Movement Disorder Society-sponsored revision of the Unified Parkinson's Disease Rating Scale (MDS-UPDRS) part III score improved from 44 to 11 points.

A transdermal rotigotine patch provides continuous delivery of dopamine agonist to the blood, bypassing gastrointestinal absorption issues. Dafotakis and colleagues<sup>6</sup> reported a PD case in which the akinetic crisis was due to multiple severe esophageal fissures and ulcers. This case was ultimately improved with the use of rotigotine patches 16 mg/24 hours (total drug content: 36 mg). In conclusion, transdermal drug delivery should be considered when patients show dose failure due to malabsorption.

### Learning points

- ▶ Drug malabsorption is an important contributing factor to motor fluctuations in Parkinson's disease.
- ▶ Gastrointestinal problems can be induced by surgery especially in the digestive tract.
- ▶ Transdermal drugs need to be considered when patients have significant malabsorption.

**Contributors** TO and GO drafted the manuscript. NH reviewed the manuscript and provided suggestions. All authors read and approved the final manuscript.

**Funding** The authors have not declared a specific grant for this research from any funding agency in the public, commercial or not-for-profit sectors.

**Competing interests** None declared.

**Patient consent** Obtained.

**Provenance and peer review** Not commissioned; externally peer reviewed.

**Open access** This is an open access article distributed in accordance with the Creative Commons Attribution Non Commercial (CC BY-NC 4.0) license, which permits others to distribute, remix, adapt, build upon this work non-commercially, and license their derivative works on different terms, provided the original work is properly cited and the use is non-commercial. See: <http://creativecommons.org/licenses/by-nc/4.0/>

© BMJ Publishing Group Ltd (unless otherwise stated in the text of the article) 2018. All rights reserved. No commercial use is permitted unless otherwise expressly granted.

### REFERENCES

- 1 Sung HY, Park JW, Kim JS. The frequency and severity of gastrointestinal symptoms in patients with early Parkinson's disease. *J Mov Disord* 2014;7:7–12.
- 2 Mukherjee A, Biswas A, Das SK. Gut dysfunction in Parkinson's disease. *World J Gastroenterol* 2016;22:5742–52.
- 3 Gerlach OH, Winogrodzka A, Weber WE. Clinical problems in the hospitalized Parkinson's disease patient: systematic review. *Mov Disord* 2011;26:197–208.
- 4 Fasano A, Visanji NP, Liu LW, *et al*. Gastrointestinal dysfunction in Parkinson's disease. *Lancet Neurol* 2015;14:625–39.
- 5 Stocchi F, Marconi S. Factors associated with motor fluctuations and dyskinesia in Parkinson Disease: potential role of a new melevodopa plus carbidopa formulation (Sirio). *Clin Neuropharmacol* 2010;33:198–203.
- 6 Dafotakis M, Sparing R, Juzek A, *et al*. Transdermal dopaminergic stimulation with rotigotine in Parkinsonian akinetic crisis. *J Clin Neurosci* 2009;16:335–7.

Copyright 2018 BMJ Publishing Group. All rights reserved. For permission to reuse any of this content visit <http://group.bmj.com/group/rights-licensing/permissions>.  
BMJ Case Report Fellows may re-use this article for personal use and teaching without any further permission.

Become a Fellow of BMJ Case Reports today and you can:

- ▶ Submit as many cases as you like
- ▶ Enjoy fast sympathetic peer review and rapid publication of accepted articles
- ▶ Access all the published articles
- ▶ Re-use any of the published material for personal use and teaching without further permission

For information on Institutional Fellowships contact [consortiasales@bmjgroup.com](mailto:consortiasales@bmjgroup.com)

Visit [casereports.bmj.com](http://casereports.bmj.com) for more articles like this and to become a Fellow