

## ELECTROPHYSIOLOGY

### CASE REPORT: CLINICAL CASE: CARDIO-OBSTETRICS 2023

# Prolactin Inhibition to Treat Postpartum Arrhythmic Storm



Miriam Compagnone, MD,<sup>a</sup> Alessandro Marinelli, MD,<sup>a</sup> Gianni Dall'Ara, MD, PhD,<sup>a</sup> Matteo Ziacchi, MD, PhD,<sup>b</sup> Simone Grotti, MD,<sup>a</sup> Leonardo Ciurlanti, MD,<sup>b</sup> Fabio Felice Tarantino, MD,<sup>a</sup> Luciano Potena, MD,<sup>c</sup> Mauro Biffi, MD,<sup>b</sup> Marcello Galvani, MD<sup>a,d,e</sup>

## ABSTRACT

Postpartum electrical storm due to torsade de pointes is a rare but life-threatening condition. The uniqueness of this case lies in the use of cabergoline to suppress postpartum ventricular arrhythmias in absence of heart disease. Timely multidisciplinary management is crucial to achieve final diagnosis, deliver proper treatment and improve prognosis. (J Am Coll Cardiol Case Rep 2024;29:102211) © 2024 The Authors. Published by Elsevier on behalf of the American College of Cardiology Foundation. This is an open access article under the CC BY-NC-ND license (<http://creativecommons.org/licenses/by-nc-nd/4.0/>).

A 36-year-old woman was admitted to the hospital because of unexplained recurrent syncope without prodromal symptoms. Five days prior, she had undergone a successful delivery and was breastfeeding. On admission, her vital signs were normal, and she was well perfused, with no peripheral edema. A 12-lead electrocardiogram (ECG) showed sinus rhythm with normal QTc segment duration (Bazett formula) but frequent monomorphic short coupled premature ventricular contractions (PVCs) (Figure 1A). The PVCs had a left bundle branch block morphology with left superior axis, potentially

from the right ventricular apex. During observation, the woman went into cardiac arrest caused by torsade de pointes (TdP) (Figures 1B and 1C).

## MEDICAL HISTORY

The patient was a primipara, and the pregnancy was uneventful. There was a family history of sudden cardiac death, with the patient's mother dying unexpectedly at age 34 years. The patient was taking no medication at home.

## DIFFERENTIAL DIAGNOSIS

The differential diagnosis included peripartum cardiomyopathy, spontaneous coronary dissection, and type 2 long QT syndrome (LQT2).

## INVESTIGATIONS

Laboratory tests excluded electrolyte, acid-base, and thyroid disorders. Her high-sensitivity troponin-T

## LEARNING OBJECTIVES

- To learn management of postpartum arrhythmic events in absence of heart disease.
- To understand the TdP treatment with cabergoline in postpartum setting.

From the <sup>a</sup>Cardiology Unit, Morgagni Pierantoni Hospital, Forlì, Italy; <sup>b</sup>Cardiology Unit, Cardio-Thoracic and Vascular Department, S. Orsola University Hospital, University of Bologna, Bologna, Italy; <sup>c</sup>Heart Failure and Transplant Unit, S. Orsola University Hospital, University of Bologna, Bologna, Italy; <sup>d</sup>Department of Medicine and Surgery of University of Bologna, Bologna, Italy; and the <sup>e</sup>Cardiovascular Research Unit, Fondazione Cardiologica M.Z. Sacco, Forlì, Italy.

The authors attest they are in compliance with human studies committees and animal welfare regulations of the authors' institutions and Food and Drug Administration guidelines, including patient consent where appropriate. For more information, visit the [Author Center](#).

Manuscript received November 29, 2023; accepted December 8, 2023.

**ABBREVIATIONS  
AND ACRONYMS****CPR** = cardiopulmonary resuscitation**ECG** = electrocardiogram**ES** = electrical storm**PVC** = premature ventricular contractions**TdP** = torsade de pointes

level was normal, as was a fast transthoracic echocardiogram study. Emergency angiography showed patent, healthy coronary arteries with no signs of spontaneous coronary dissection. A right ventricular biopsy excluded inflammatory and infiltrative disorders. Cardiac magnetic resonance showed normal biventricular function, volumes, and wall thickness (Figure 2) without wall edema or late gadolinium enhancement. A whole-body computed tomography scan was also normal.

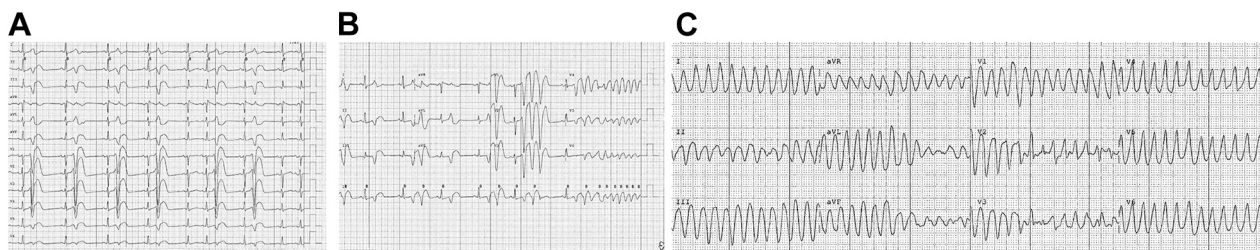
**MANAGEMENT**

The cardiac arrest was treated with cardiopulmonary resuscitation (CPR) and a single DC shock. Magnesium sulfate infusion was administered, but the non-sustained TdP persisted. She was transferred to the catheterization laboratory, where she experienced multiple recurrent TdP episodes with cardiac arrest (>50 episodes) requiring prolonged CPR, repeated DC shocks, and orotracheal intubation under general anesthesia. Intravenous amiodarone, lidocaine, and metoprolol were used without success, and overdrive pacing through a temporary pacemaker failed to prevent electrical storm (ES) episodes. An intra-aortic balloon pump was placed to improve her hemodynamic status. The Impella left ventricular assist device was not used because of potentially marked ventricular arrhythmic susceptibility triggered by contact between catheter and endocardium. In addition, complete biventricular hemodynamic support, needed in case of protracted circulatory arrest, was not available. A percutaneous stellate ganglion block was also performed but proved ineffective. After prolonged CPR, during a phase of relative stability, the patient was transferred to a tertiary heart center.

She underwent an electrophysiological study with biventricular electroanatomic mapping. A drug test with ajmaline was also performed, which showed no alterations to suggest Na channel modification. A focus of triggered activity was identified in the right septal apical area and was successfully treated by transcatheter radiofrequency ablation. However, 2 days after the procedure, the patient experienced further TdP relapses. Despite persistently normal QTc intervals, LQT2 was suspected. Accordingly, propranolol was tested<sup>1</sup> but was discontinued after being poorly tolerated. A genetic test was also performed, with negative results. Afterward, intravenous verapamil, flecainide, and isoproterenol were also proved ineffective in suppressing the arrhythmias. In view of the temporal association between her postpartum state and the onset of ES, a cause-and-effect association was suspected. Therefore, in agreement with the gynecologists, cabergoline was used to inhibit lactation, resulting in successful suppression of the ES. An implantable subcutaneous cardiac defibrillator was placed for secondary prevention, and the patient was discharged in good clinical condition.

**DISCUSSION**

This was a case of ES caused by recurrent postpartum TdP in a patient without structural heart disease. It is a medical emergency that can frequently lead to hemodynamic instability and tends to have a poor prognosis.<sup>2,3</sup> Treatment is not standardized, and there is substantial heterogeneity among centers.<sup>3</sup> The underlying causes should be investigated to provide targeted treatment, but this is not always possible, especially while conditions are acute and unstable. Owing to the prominent role of increased adrenergic tone, intravenous  $\beta$ -blockers alone or combined with amiodarone are the most common

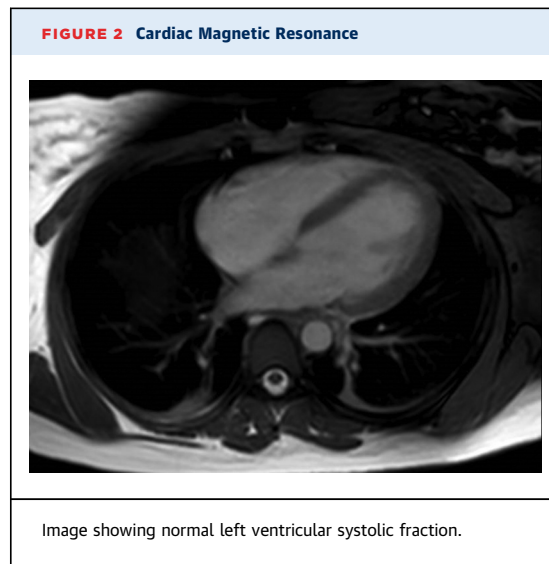
**FIGURE 1** 12-Lead Electrocardiogram

(A) Frequent premature monomorphic short-coupled premature ventricular contractions; the coupling interval was 280 msec. (B, C) Torsade de pointes episode, with typical gradual change in the amplitude and twisting of the QRS complexes around the isoelectric line.

first-line treatment options.<sup>2,3</sup> Selected patients may benefit from autonomic modulation via percutaneous stellate ganglion block or sympathetic denervation.<sup>2</sup> Sedation and general anesthesia play a crucial role in supporting vital functions and decreasing adrenergic stress. In cases of TdP, intravenous magnesium is an effective treatment even in the absence of hypomagnesemia, and in refractory cases, particularly if associated with bradycardia, the arrhythmia can be suppressed by increasing the underlying heart rate using isoprenaline or transvenous pacing.<sup>2</sup> When ES persists unresponsive to medical treatment, catheter ablation should be considered. Currently, urgent catheter ablation is a Class I, Level of Evidence: B recommendation;<sup>2</sup> however, in the vast majority of centers, this treatment is available only during the day and on workdays.<sup>3</sup> Early referral to centers that can guarantee advanced circulatory support (eg, venoarterial extracorporeal membrane oxygenation) and fast access to ventricular ablation is of paramount importance, as is identifying the underlying cause. However, the causes of ES are often not fully understood, especially during peripartum.<sup>4</sup> In general, during pregnancy ES is typically associated with hemodynamic decompensation of a pre-existing structural heart disease (eg, cardiomyopathy, valvular or congenital heart disease, pulmonary hypertension) or is due to specific pathological entities that typically occur at the end of pregnancy or in the following months.<sup>5</sup> By contrast, new-onset ES is extremely rare in the absence of structural heart disease. Baseline 12-lead ECG characteristics have a high diagnostic yield for underlying arrhythmic disorders (eg, Brugada and early repolarization pattern, catecholaminergic polymorphic ventricular tachycardia, short or long QT syndrome). However, as shown in our case, the ECG can be completely normal. Despite ES being extremely rare in the peripartum, more benign rhythm disorders (eg, PCVs) are quite common. The main proarrhythmic mechanisms in peripartum include<sup>5,6</sup>:

1. increased heart rate
2. increased blood volume, resulting in cardiac chamber enlargement with a risk of re-entrant phenomena or stretch-sensitive ion-channel activation
3. increased sympathetic activity, which may contribute to abnormal automaticity, reentry, or triggered activity
4. rapid changes in hormone levels during pregnancy or after delivery

Previous studies have demonstrated how decreased progesterone levels may contribute to



heightened arrhythmogenic risk during the postpartum period and how oxytocin prolongs the QT interval even in healthy subjects.<sup>6,7</sup> In fact, progesterone is able to modify membrane potential response to  $Ca^{2+}$  oscillations and reduce the likelihood of triggered activity.<sup>7</sup> Furthermore, both oxytocin and prolactin have been proved to affect repolarization and contribute to an increased propensity for arrhythmic events in LQT2.<sup>7</sup> During pregnancy, circulating prolactin rises progressively, and its action is inhibited by high plasma levels of placental estrogen and progesterone. After delivery, there is a drop in these hormones and an increased release of prolactin resulting from the newborn's breastfeeding. In our case, the high prolactin level may have increased ventricular vulnerability with a proarrhythmic effect. This hypothesis derives from these conditions:

1. the inefficacy of standard treatment
  2. the temporal relation between the ES onset and breastfeeding
  3. the complete cessation of malignant arrhythmic events after use of a prolactin inhibitor
- To date, the role of postpartum hormones in triggering ES is not completely understood, and further studies are needed.

#### FOLLOW-UP

At the 1-year follow-up visit, the patient's progress was uneventful, with the implantable subcutaneous cardiac defibrillator interrogation reporting no syncope, no shocks, or recurrence of ventricular arrhythmic events.

## CONCLUSIONS

---

Life-threatening arrhythmic events occurring in the peripartum setting may have multiple causes, which must be investigated quickly while making complex treatment choices. A well-established network among centers with different levels of care and a multidisciplinary team approach are key factors in ensuring the best diagnostic and therapeutic options.

## FUNDING SUPPORT AND AUTHOR DISCLOSURES

---

This research was funded by Fondazione Cardiologica M.Z. Sacco, Forlì, Italy. The authors have reported that they have no relationships relevant to the contents of this paper to disclose.

**ADDRESS FOR CORRESPONDENCE:** Dr Miriam Compagnone, Cardiology Unit, Morgagni Pierantoni Hospital Forlì, Via Carlo Forlanini 34 - 47121 Forlì, Italy. E-mail: [miriam.compagnone@icloud.com](mailto:miriam.compagnone@icloud.com).

---

## REFERENCES

1. Chockalingam P, Crotti L, Girardengo G, et al. Not all beta-blockers are equal in the management of long QT syndrome types 1 and 2: higher recurrence of events under metoprolol. *J Am Coll Cardiol*. 2012;60(20):2092-2099.
2. Zeppenfeld K, Tfelt-Hansen J, de Riva M, et al. 2022 ESC guidelines for the management of patients with ventricular arrhythmias and the prevention of sudden cardiac death. *Eur Heart J*. 2022;43:3997-4126.
3. Baldi E, Conte E, Zeppenfeld K, et al. Contemporary management of ventricular electrical storm in Europe: results of a European Heart Rhythm Association Survey. *Europace*. 2022;25:1277-1283.
4. Enriquez AD, Economy KE, Tedrow UB. Contemporary management of arrhythmias during pregnancy. *Circ Arrhythm Electrophysiol*. 2014;7:961-967.
5. Tamirisa KP, Elkayam U, Briller JE, et al. Arrhythmias in pregnancy. *J Am Coll Cardiol EP*. 2022;8:120-135.
6. Bodi I, Sorge J, Castiglione A, et al. Postpartum hormones oxytocin and prolactin cause proarrhythmic prolongation of cardiac repolarization in long QT syndrome type 2. *Europace*. 2019;21:1126-1138.
7. Odening KE, Choi BR, Liu GX, et al. Estradiol promotes sudden cardiac death in transgenic long QT type 2 rabbits while progesterone is protective. *Heart Rhythm*. 2012;9:823-832.

---

**KEY WORDS** arrhythmic storm, cardiac arrest, postpartum, torsade de pointes