

Histocytological specificities of adrenal cortex in the New World Monkeys, *Aotus lemurinus* and *Saimiri boliviensis*

Toru TACHIBANA¹⁾, Ken Takeshi KUSAKABE^{1)*}, Sayuri OSAKI¹⁾, Takeshi KURAIISHI²⁾, Shosaku HATTORI²⁾, Midori YOSHIZAWA³⁾, Chieko KAI²⁾ and Yasuo KISO¹⁾

¹⁾Laboratory of Basic Veterinary Science, The United Graduate School of Veterinary Science, 1677-1 Yoshida, Yamaguchi 753-8515, Japan

²⁾Amami Laboratory of Injurious Animals, Institute of Medical Science, The University of Tokyo, 802 Teyasu, Setouchi-cho, Ohshima-gun, Kagoshima 894-1531, Japan

³⁾Graduate School of Agricultural Science, Utsunomiya University, 350 Mine-machi, Utsunomiya, Tochigi 321-8505, Japan

(Received 14 May 2015/Accepted 12 August 2015/Published online in J-STAGE 28 August 2015)

ABSTRACT. The New World monkey *Aotus* spp. (night monkeys) are expected for use of valuable experimental animal with the close species of *Saimiri* spp. (squirrel monkeys). *Saimiri* is known to show spontaneous hypercortisolemia, although few reports in *Aotus*. We compared basic states of blood steroid hormones and histological structure of the adrenal glands in two monkeys. Serum cortisol and ACTH levels were statistically lower in *Aotus* than *Saimiri*. Conversely, *Aotus* adrenocortical area showed significant enlargement, especially at the zona fasciculata. Electron microscopic observation at *Aotus* fasciculata cells revealed notable accumulation of large lipid droplets and irregular shapes of the mitochondrial cristae. These results suggest potential differences in cellular activities for steroidogenesis between *Aotus* and *Saimiri* and experimental usefulness in adrenocortical physiology and pathological models.

KEY WORDS: adrenal cortex, *Aotus*, cortisol, *Saimiri*

doi: 10.1292/jvms.15-0290; *J. Vet. Med. Sci.* 78(1): 161–165, 2016

Aotus spp., commonly called as “night monkeys or owl monkeys”, are inhabiting at the Central and South America and taxonomically belong to the Platyrrhini infraorder, the Cebidae family and the Aotinae subfamily. They have been expected to be applied as an experimental animal, because of the calm behavior, easy manageability and interesting biological traits. For example, *Aotus* has been known to have high sensitivity to the *Plasmodium vivax* and regarded as an useful experimental model for malaria researches [6]. Secondly, they show unstable phenotypes on the chromosomal karyotypes (2n=52, 53 and 54), due to translocations of Y chromosome to autochromosomes [9]. Furthermore, *Aotus* shows a clear life cycle of nocturnal behavior, which is a sole trait in the Platyrrhini infraorder. They have specific histological phenotypes in eyeballs, suggesting a unique evolutionary history and biological adaptation [5]. It is considered that *Aotus* keeps distinct profiles for usage of the biological application.

The *Saimiri* spp., commonly called as “squirrel monkeys” and a taxonomical close species to the *Aotus*, have been also regarded for experimental availability. They are known to be high level of serum cortisol spontaneously and show low binding ability of the glucocorticoid receptor against dexa-

methasone [3], so they are expected as a research model for glucocorticoids resistance and endocrine diseases. On the other hand, these two types of monkeys have quite different features of the usual behavior, i.e., *Aotus* shows very gentle, and calm activity and *Saimiri* can be easily agitated to become intensively excited. In general, systemic cortisol production is associated with the biological activity and animal behavior. Our preliminary tests clarified the different cortisol levels between *Aotus* and *Saimiri*, and indicated biological independency of *Aotus*. In the present study, we additionally found differences in serum steroids, histological structure of the adrenal glands and ultrastructure of the adrenocortical cells. These data suggest intrinsic and cytological differences in the steroidogenesis between both monkeys. *Aotus* and *Saimiri* may become a useful model for endocrinological studies, such as steroidogenetic regulation, organogenesis of the adrenals and adrenal pathogenesis.

Aotus lemurinus and *Saimiri boliviensis*, breeding at the facility of Amami Laboratory of Injurious Animals, Institute of Medical Science, The University of Tokyo, were used for sample collection. Adult females from *Aotus* (4–15 years old, 980 ± 109 g body weight and 5 individuals) and *Saimiri* (5–6 years old, 678 ± 32.8 g body weight and 4 individuals) were used for experiments. Sexual maturation ages are known around 3 and 2.5 years, respectively, in *Aotus* [7] and *Saimiri* [4]. Monkeys were deeply anesthetized with 50 mg/ml ketamine and 2% xylazine, and whole blood was collected from heart. Sera were separated for steroid hormone measurements (conducted by SRL, Tokyo, Japan) and ACTH (conducted by Yamaguchi University Animal Medical Center). Animal welfare was preserved following the guideline of the care and use of laboratory animals at

*CORRESPONDENCE TO: KUSAKABE K.T., Laboratory of Basic Veterinary Science, The United Graduate School of Veterinary Science, 1677-1 Yoshida, Yamaguchi 753-8515, Japan.
e-mail: kusakabe@yamaguchi-u.ac.jp

©2016 The Japanese Society of Veterinary Science

This is an open-access article distributed under the terms of the Creative Commons Attribution Non-Commercial No Derivatives (by-nc-nd) License <http://creativecommons.org/licenses/by-nc-nd/3.0/>.

Table 1. Serum levels of steroid hormones

Animal	Cortisol ($\mu\text{g/ml}$)	ACTH (pg/ml)	Estradiol (pg/ml)	Progesterone (ng/ml)
<i>Aotus</i>	$32.7 \pm 9.01^*$ (5)	$35.7 \pm 2.20^*$ (3)	181 ± 84.9 (4)	47.7 ± 50.5 (4)
<i>Saimiri</i>	156 ± 59.1 (4)	58.1 ± 0.50 (3)	149 ± 103 (3)	171 ± 113 (3)
Human ^{a)}	4.0–18.3	7.2–63.3	F: 20–350 O: 50–550 L: 45–300	F: <0.92 O: <2.36 L: 1.28–29.6

* $P < 0.05$, ** $P < 0.01$, vs. *Saimiri*. Figures in parentheses present sample number. a) Reference data for non-pregnant, menstrual-aged women (from the guideline of Japanese Society of Laboratory Medicine), F: Follicular, O: Ovulation, L: Luteal stages.

the Institute of Medical Science, The University of Tokyo (experimental No. 2013-328).

After confirmation of euthanasia, adrenals were collected and fixed with neutral-buffered 10% formalin. Paraffin sections and H&E staining were conducted along with conventional methods. Using 4 transversal sections, the areas of the whole adrenal, cortex and medulla were measured. Data were represented as parts per hundred (%) in the whole area of adrenal glands. The thickness of each cortex area (zona glomerulosa, fasciculata and reticularis) was measured using 4 transversal sections, along with the randomly marked 5 lines through the adrenal cortex. For the morphometric measurements, Biozero microscope system and BZ-II analyzer software were used (Keyence, Osaka, Japan).

For electron microscopic analysis, samples were trimmed and doubly fixed with 2.5% glutaraldehyde in 0.1 M phosphate buffer (PB; pH 7.4) and then with 1% osmium in 0.1 M PB (pH 7.4). Specimens were embedded in the epoxy resin along with conventional methods, and sections were prepared using EM UC7i (Leica Microsystems, Wetzlar, Germany). Ultra-thin sections were stained with 5% uranyl acetate and 2% lead citrate, and observed using an H-7600 electron microscope (Hitachi High-Technologies, Tokyo, Japan).

Measurement data were represented as mean \pm standard deviation. Two-sided Student's *t*-test was conducted for statistical comparison between two monkeys.

Serum cortisol levels were very high at the both *Aotus* and *Saimiri* as compared with the human level (Table 1). On the other hand, serum cortisol and ACTH levels were statistically lower in *Aotus* than *Saimiri*. Serum progesterone level was lower in *Aotus* than *Saimiri*, but no statistical difference was detected between them. Serum estradiol showed no statistical difference between both monkeys and was in the range of human estradiol levels.

Adrenal glands of both monkeys could be classified morphologically into pyramidal and oval outline shapes (Fig. 1A). *Aotus* adrenals showed tendency to be larger in size and weight as compared with *Saimiri* (Table 2), but there were no statistical differences. Rates of adrenal weight per body weight were almost the same level between two monkeys and in similar range of the human (5–7 g unilateral weight). On the surface of both adrenals, 1–2 deep grooves were often found, suggested to be made by the pressure of several vessels to adrenals (Fig. 1B, arrow). Incidences of deep groove retention were 40% in *Aotus* and 25% in *Saimiri*.

Histological studies of adrenals revealed significant differences of the morphometric size between monkeys. Rates of cortex area in the whole adrenals were larger in *Aotus* than *Saimiri* (Table 3). In compensatory style, rates of medulla area were small in *Aotus*. The histological structures were normal in each adrenal region of both monkeys (Fig. 1D and 1E). Pathological changes, such as neoplasm or malformation, were not found. Morphometric assays also revealed statistical differences in the thickness of adrenocortical regions (Table 3). *Aotus* adrenals showed significant small size of the zona glomerulosa and large size of zona fasciculata as compared with *Saimiri*. The thickness of the whole adrenal cortex was $792 \pm 99.9 \mu\text{m}$ (*Aotus*) and $598 \pm 58.5 \mu\text{m}$ (*Saimiri*) ($P < 0.01$).

On the electron microscopic analyses (Fig. 2), abundant numbers of the lipid droplets were remarkable in the adrenocortical cells of *Aotus* zona fasciculata. Other cytoplasmic organelles also showed differences between two species. Basically, mitochondria showed mixed composite phenotypes for the lamellar and tubal cristae at both monkeys (arrowheads in Fig. 2C and 2D). Especially in *Saimiri*, these cristae aligned in parallel and regularly, and the lumen sizes were uniform. However, in *Aotus*, the lumen sizes were uneven, and crista showed irregular alignments. In the *Aotus* fasciculata cells, fusion of the lipid droplets and vesicular lysosomal bodies were observed. In *Saimiri*, glycogen granules were abundant in the cytoplasm.

This study showed new biological traits of *Aotus* as wide area of zona fasciculata in the adrenal cortex, although the tissue expansion was not accompanied with up-regulation of cortisol production. Thickness of *Aotus* adrenal cortex seemed to be caused by the accumulation of lipid droplets. Previous reports suggested that enzymatic up-regulation, such as 17 α -hydroxylase, 3 β -hydroxysteroid dehydrogenase, 21-hydroxylase and 11 β -hydroxylase, may be the reason for high level of blood cortisol in the New world monkeys [3]. However, it is possible that *Aotus* has different activity patterns for converting enzymes in the adrenal cortex. During steroidogenesis, cholesterol transportation is essential to the matrix of mitochondria, and mitochondrial inner membrane becomes the reactive loci for converting enzymes [10]. Structural difference of mitochondrial inner membranes between *Aotus* and *Saimiri* may reflect diversity of activities of steroid converting enzymes.

Otherwise, *Aotus* adrenocortical cells contained a large

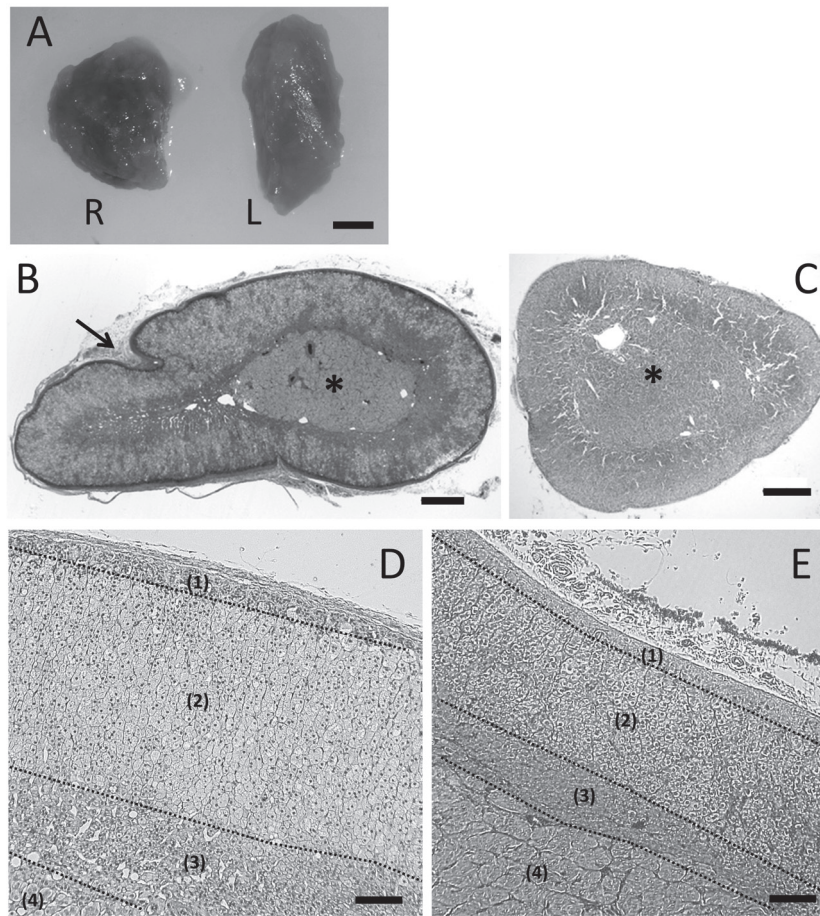


Fig. 1. Adrenal glands of *Aotus* (A). Outline of right (R) and left (L) adrenals shows pyramidal and oval shapes, respectively. Transversal sections of *Aotus* (B, D) and *Saimiri* (C, E) adrenal glands (H&E stain). *Aotus* adrenals showed large area of the cortex (B), accompanied with deep vascular groove (arrow) and the acentric positioned medulla (asterisks, compare with C). In the cortex regions of *Aotus* (D), expansion of zona fasciculata is notable as compared with *Saimiri* (E). Numbers in parentheses represent zona glomerulosa (1), zona fasciculata (2) zona reticularis (3) and medulla region (4). Scale bars=2 mm (A), 0.5 mm (B, C), 100 μ m (D, E).

Table 2. Measurements of adrenals

Animal	Size (mm) ^{a)}	Weight (mg)	Rate of adrenal weight per body weight	Outline shapes of adrenals ^{b)}
<i>Aotus</i>	Right L: 7.9 \pm 0.7 S: 7.0 \pm 1.0 T: 3.6 \pm 0.4	84.3 \pm 11.7	0.010%	P: 4/5 O: 1/5
	Left L: 10.5 \pm 2.7 S: 6.2 \pm 0.8 T: 3.6 \pm 0.9	93.9 \pm 5.2	0.011%	P: 2/5 O: 3/5
<i>Saimiri</i>	Right L: 8.7 \pm 0.1 S: 6.0 \pm 0.4 T: 3.6 \pm 0.3	74.2 \pm 0.8	0.008%	P: 0/4 O: 4/4
	Left L: 8.9 \pm 1.4 S: 5.3 \pm 0.1 T: 4.4 \pm 0.3	78.4 \pm 7.4	0.008%	P: 2/4 O: 2/4

a) L: Long axis; S: Short axis; T: Thickness. b) No. of adrenals showing oval (O) or pyramidal (P) shapes /No. of adrenals observed.

Table 3. Morphometric assays of adrenal glands

Animal	Rate of the section area (%) [#]	Thickness of the cortex regions (μm)		
		Glomerulosa	Fasciculata	
<i>Aotus</i>	Cortex	86.5 \pm 3.39*	43.1 \pm 8.50**	
	Medulla	12.6 \pm 3.42*	454 \pm 92.9*	
			Reticularis	296 \pm 107
			Total	792 \pm 99.9**
<i>Saimiri</i>	Cortex	71.4 \pm 2.07	83.7 \pm 4.43	
	Medulla	29.9 \pm 3.25	304 \pm 81.1	
			Reticularis	210 \pm 43.0
			Total	598 \pm 58.5

[#] Excluding areas of large blood sinuses and capsule regions. * $P < 0.05$, ** $P < 0.01$, vs. *Saimiri*.

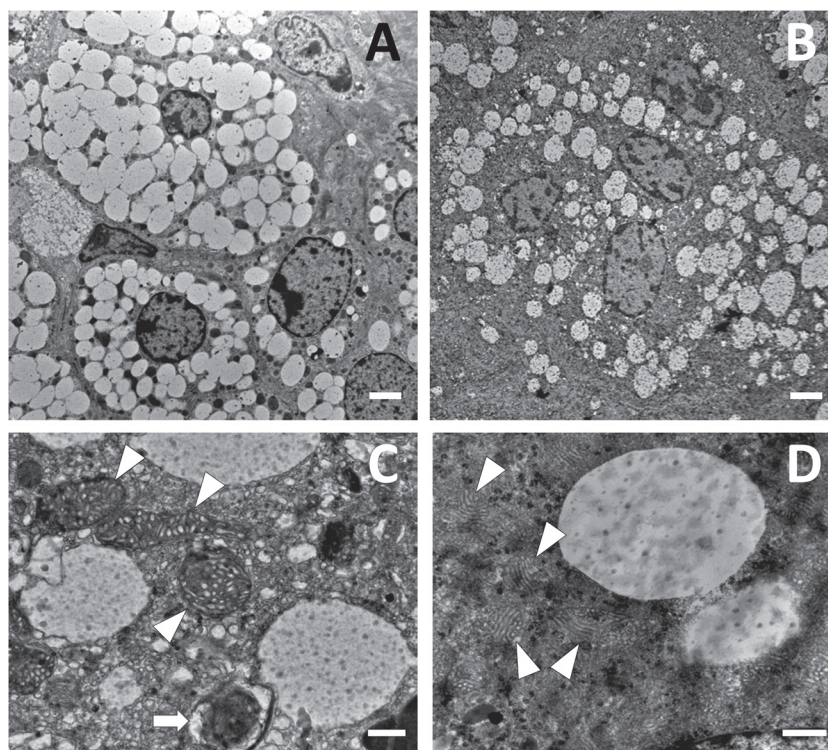


Fig. 2. Electron microscope photographs of the adrenocortical cells at the zona fasciculata in *Aotus* (A, C) and *Saimiri* (B, D). Arrowheads and arrow respectively indicate mitochondria and vesicular body. Scale bars=2 μm (A, B), 500 nm (C, D).

amount of the lipid droplets, which seemed to be stable in cytoplasm and associated with restriction of the serum cortisol level. On the surface of lipid droplets, specific protein, perilipin, localizes and is suggested to keep membrane stability and regulate lipolysis pathway [1, 2]. Perilipin is also found in the adrenocortical cells [8]. Stability and lipolysis of lipid droplets in the adrenocortical cells may be associated with intracellular transportation of cholesterol and early stages of the steroidogenesis processes. Evaluation of these processes and analysis of related molecules in the *Aotus* adrenals may be available for understanding of cortisol production and applied researches for the hypercortisolemia treatments.

We found new biological traits of adrenal glands in the *Aotus* by comparison with the *Saimiri*. Comparison studies

using these genetically close monkeys were expected for the study of enzymatic or cytological steroidogenic regulation and developmental process of the adrenal tissue. Finding of appropriate biomarkers, e.g. perilipin, may be applicable for monitoring adrenocortical cell activity and evaluation for adrenocortical hyperfunction diseases. For these trials, *Aotus* and *Saimiri* have a possibility to become a useful research tool for basic clinical studies.

ACKNOWLEDGMENTS. We appreciate Prof. M. Okuda, Yamaguchi University Animal Medical Center, for kind help of ACTH measurement. This study was supported by the Grant for Joint Research Project of the Institute of Medical Science, The University of Tokyo.

REFERENCES

1. Brasaemle, D. L. 2007. The perilipin family of structural lipid droplet proteins: stabilization of lipid droplets and control of lipolysis. *J. Lipid Res.* **48**: 2547–2559. [[Medline](#)] [[CrossRef](#)]
2. Brasaemle, D. L., Rubin, B., Harten, I. A., Gruia-Gray, J., Kimmeli, A. R. and Londos, C. 2000. Perilipin A increases triacylglycerol storage by decreasing the rate of triacylglycerol hydrolysis. *J. Biol. Chem.* **275**: 38486–38493. [[Medline](#)] [[CrossRef](#)]
3. Chrousos, G. P., Loriaux, D. L., Tomita, M., Brandon, D. D., Renquist, D., Albertson, B. and Lipsett, M. B. 1986. The New World primates as animal models of glucocorticoid resistance. pp. 129–143. *In: Steroid Hormone Resistance: Mechanisms and Clinical Aspects* (George, P., Chrousos, D., Lynn, L. and Lipsett, M. B. eds.), Plenum Press, New York.
4. Corner, B. D. and Richtsmeier, J. T. 1992. Cranial growth in the squirrel monkey (*Saimiri sciureus*): a quantitative analysis using three dimensional coordinate data. *Am. J. Phys. Anthropol.* **87**: 67–81. [[Medline](#)] [[CrossRef](#)]
5. Dyer, M. A., Martins, R., Filhod, M. S., Muniz, J. A. P. C., Silveira, L. C. L., Cepko, C. L. and Finlay, B. L. 2009. Developmental sources of conservation and variation in the evolution of the primate eye. *Proc. Natl. Acad. Sci. U.S.A.* **106**: 8963–8968. [[Medline](#)] [[CrossRef](#)]
6. Geiman, Q. M. and Meagher, M. J. 1967. Susceptibility of a New World monkey to *Plasmodium falciparum* from man. *Nature* **215**: 437–439. [[Medline](#)]
7. Gozalo, A. and Montoya, E. 1990. Reproduction of the owl monkey (*Aotus nancymai*) (Primate: Cebidae) in captivity. *Am. J. Primatol.* **21**: 61–68. [[CrossRef](#)]
8. Servetnick, D. A., Brasaemle, D. L., Gruia-Gray, J., Kimmel, A. R., Wolff, J. and Londos, C. 1995. Perilipins are associated with cholesteryl ester droplets in steroidogenic adrenal cortical and Leydig cells. *J. Biol. Chem.* **270**: 16970–16973. [[Medline](#)] [[CrossRef](#)]
9. Stanyon, R., Garofalo, F., Steinberg, E. R., Capozzi, O., Di Marco, S., Nieves, M., Archidiacono, N. and Mudry, M. D. 2011. Chromosome painting in two genera of south american monkeys: species identification, conservation, and management. *Cytogenet. Genome Res.* **134**: 40–50. [[Medline](#)] [[CrossRef](#)]
10. White, P. C. and Speiser, P. W. 2000. Congenital adrenal hyperplasia due to 21-hydroxylase deficiency. *Endocr. Rev.* **21**: 245–291. [[Medline](#)]