



Contents lists available at ScienceDirect

International Journal of Surgery Case Reports

journal homepage: www.casereports.com

Diagnosis and perioperative management of ruptured AAA mimicking symptomatic groin hernia



Holger Jan Klein*, Daniel Becker, Zoran Rancic

Division of Cardiovascular Surgery, University Hospital Zurich, Switzerland

ARTICLE INFO

Article history:

Received 15 September 2015

Received in revised form

21 November 2015

Accepted 21 November 2015

Available online 27 November 2015

Keywords:

Ruptured abdominal aortic aneurysm

Inguinal hernia

EVAR

ABSTRACT

INTRODUCTION: Ruptured abdominal aortic aneurysm (RAAA) can infrequently present as symptomatic groin hernia. This misleading form of presentation often leads to erroneous preoperative management resulting in poor survival.

CASE PRESENTATION: Two patients with RAAA mimicking symptomatic groin hernia underwent different preoperative managements pointing out the importance of the principles of hypotensive haemostasis in the scope of this emergency scenario.

CONCLUSION: Computed Tomography Angiography (CTA) remains the recommended diagnostic tool—for both safe diagnosis of the ruptured aneurysm and precise preoperative planning. Endovascular aortic repair of the RAAA—if feasible—is the treatment of choice. This rare form of RAAA manifestation should call physicians attention—especially in patients with known abdominal aortic aneurysms in their preceding medical history.

© 2015 The Authors. Published by Elsevier Ltd. on behalf of IJS Publishing Group Ltd. This is an open access article under the CC BY-NC-ND license (<http://creativecommons.org/licenses/by-nc-nd/4.0/>).

1. Introduction

Ruptured abdominal aortic aneurysm (RAAA) typically manifests in about 75% of the patients with severe abdominal or back pain, hemodynamic impairment and a pulsating abdominal mass [1]. Another very rare presentation is RAAA mimicking symptomatic inguinal hernia [2–4]. Presence of inguinal hernia is associated with abdominal aortic aneurysms in up to 41% [5]. We present two patients with ruptured aortoiliac aneurysms mimicking symptomatic groin hernia—wishing to alert physicians' awareness of this manifestation. Furthermore, we would like to discuss how to manage a patient with RAAA, which was thought to be an inguinal hernia at first sight. The patient consented to publication of this report.

2. Case presentation

2.1. Patient I

A 78-year-old gentleman was referred to a regional hospital with suspected incarcerated inguinal hernia due to persistent pain in his lower abdomen and left groin. Urgent surgical repair was initiated. Intraoperative finding of blood in the left spermatic cord

was of concern. There were no signs of an incarcerated hernia. To identify the cause of bleeding, laparoscopy was performed, which showed a retroperitoneal haematoma from the left psoas muscle to the midline. Consecutively, performed abdominal ultrasound showed an aneurysmatic abdominal aorta of 45 mm with a dilated left kidney pelvis. Because of suspected ruptured aneurysm, the patient was immediately referred to a tertiary vascular centre. During the transport, blood pressure was 90/60 mmHg, heart rate 95/min, with restricted fluid administration (2.5l of colloids).

After patients' arrival at the hospital, thoracoabdominal Computed Tomography Angiography (CTA) showed a contained rupture of a left common iliac artery aneurysm (7 × 6 cm) with huge retroperitoneal haematoma and compression of the left ureter (Fig. 1). There was no radiological evidence for an incarcerated inguinoscrotal hernia (Fig. 2). Morphology of the aneurysm was suitable for endovascular aneurysm repair (EVAR). Endovascular treatment included coil embolization of both internal iliac arteries with infrarenal stentgraft implantation to both external iliac arteries. Final angiography showed complete exclusion of the aneurysm. The patient spent 36 h in the intensive care unit (ICU) and left the hospital on the 13th postoperative day.

2.2. Patient II

A 73-year-old male presented with severe pain in his left groin and lower abdomen. His general practitioner suspected an incarcerated hernia and referred him to a regional hospital. The patient collapsed at the counter. Performed ultrasound showed RAAA

* Corresponding author at: University Hospital Zurich, Division of Cardiovascular Surgery, Raemistrasse 100, 8091 Zurich, Switzerland. Fax: +41 44 255 8977.

E-mail addresses: klein.holger@googlemail.com, holger.klein@usz.ch (H.J. Klein), daniel.becker@usz.ch (D. Becker), zoran.rancic@usz.ch (Z. Rancic).

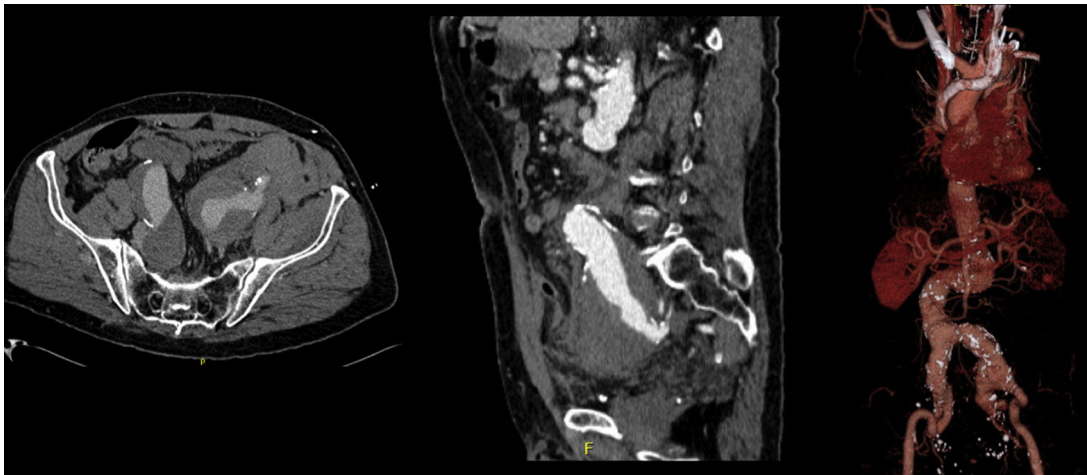


Fig. 1. Contained rupture of a left common iliac artery aneurysm with huge retroperitoneal hematoma.

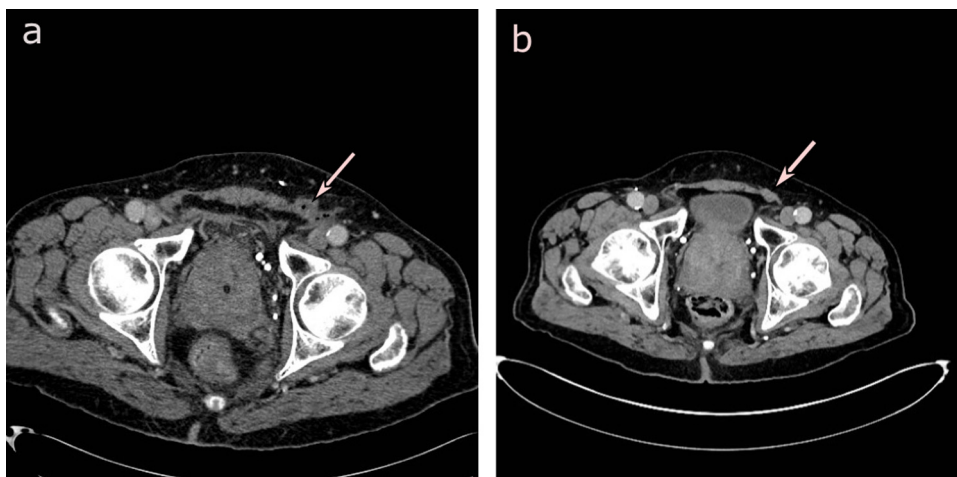


Fig. 2. (a) Preoperative CT angiography showing a dilated left inguinal canal containing haematoma/blood without evidence for an incarcerated inguinoscrotal hernia (arrow). (b) Postoperative CT angiography showing an intact inguinal canal (arrow).

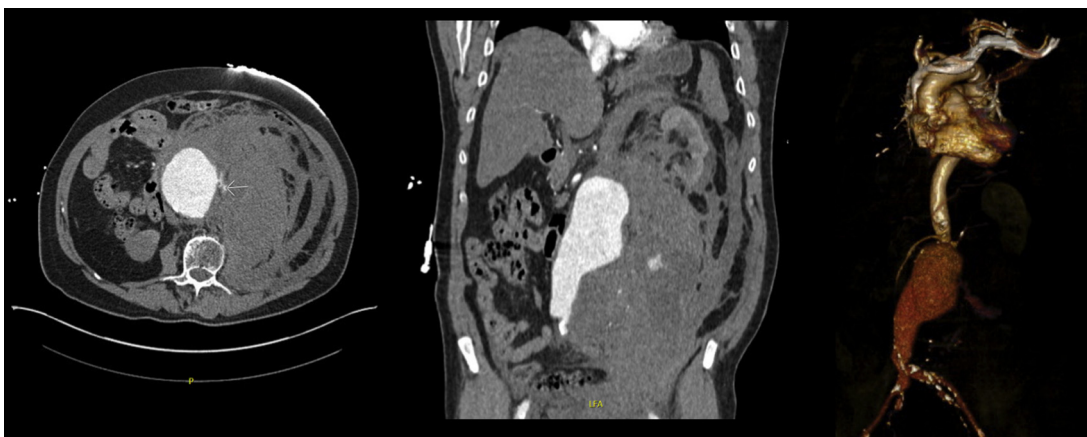


Fig. 3. Ruptured infrarenal aneurysm with huge retroperitoneal haematoma.

(Ø 7.5 cm) with signs of intraperitoneal bleeding. Consecutively, patient's general condition deteriorated, with blood pressure of 80/60 mmHg. First line therapy in this hospital was volume substitution (4 litres of colloids). During referral time to our hospital, the patient was given additional 1.5l of colloids. Immediately performed thoracoabdominal CTA showed a ruptured infrarenal

aneurysm (10 × 10 cm) with huge retroperitoneal haematoma and signs of intraperitoneal bleeding (Fig. 3). Furthermore, CTA depicted the presence of a bilateral inguinal hernia (Fig. 4). The aneurysm was feasible for endovascular treatment via a percutaneous access in local anaesthesia (Table 1).

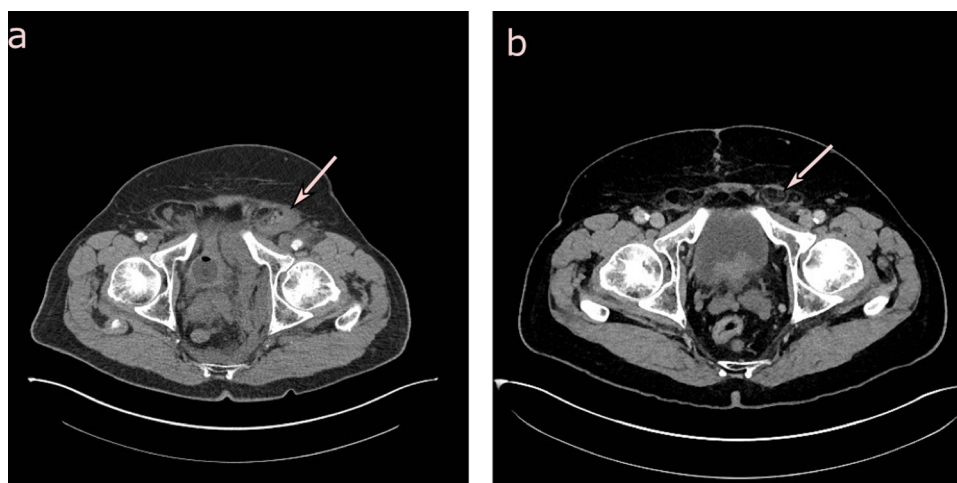


Fig. 4. (a) Preoperative CT angiography showing a bilateral dilated inguinal canal containing hernia with surrounding fat—on the left side with haematoma/blood (arrow). (b) Postoperative CT angiography showing the bilateral dilated inguinal canal with hernia content (arrow).

Table 1
Characteristics of aneurysm and treatment.

	Patient I	Patient II
Size and location of RAAA	Ø 7 cm, left internal iliac artery	Ø 10 cm, infrarenal aorta
Initial diagnostic of RAAA	Intraoperative laparoscopy/ultrasound	Ultrasound
Definitive diagnostic of RAAA	CTA	CTA
Presence of hernia	No	Yes
Time between initial diagnosis and admission to our hospital	4.5 h	2.5 h
Vital signs at admission	RR 90/60 mmHg, f 95/min	RR 110/70 mmHg, f 90/min
Prehospital amount of fluid resuscitation	2.5l	5.5l
Use of vasopressors	No	Yes
Principles of hypotensive haemostasis applied	Yes	No
Type of EVAR	Gore®Excluder®AAA endoprosthesis	Medtronic Endurant Stentgraft®
ICU stay (days)	2	25
In hospital stay (days)	13	33
In hospital repair of hernia	–	No
Hernia repair after discharge	–	No

Because of obvious abdominal compartment syndrome (urinary bladder pressure of 25 mmHg), decompression laparotomy was performed. Laparotomy was temporary closed with a Bogotá VAC®. The patient spent 25 days in the ICU. He showed prolonged recovery with several complications like postoperative non-STEMI, cardiac dysrhythmia, transient ischaemic liver insufficiency and nephropathy with temporary dialysis. After multiple VAC changes and use of ABRA® system the abdomen was closed at the 30th postoperative day. Altogether the patient stayed in our hospital for 33 days.

3. Discussion

Ruptured aortoiliac aneurysms can present as a neurological, urological, orthopaedic disorder, or even as a cardiac problem [6]. Rarely, RAAA can mimic incarcerated inguinal hernia, typically presenting as painful lump in the groin [7]. Literature search reveals in total 18 patients with ruptured aortoiliac aneurysms initially presenting as symptomatic/incarcerated hernia [2–4,8–12]. The fact that rupture of abdominal aneurysm appears as symptomatic hernia should not be surprising: First, there is increased activity of matrix metalloproteinases and their inhibitors in both abdominal wall (responsible for weakness of abdominal wall with subsequent hernia) and aortic walls (responsible for weakness of aortic wall and subsequent aneurysm formation) [13]. Second, there are anatomical features: The abdominal aorta and the urogenital organs develop retroperitoneal, so that the peritoneum and the transverse fascia provide a potential channel between the scrotum and the kidney [3]. In case of RAAA the blood from the rupture site

will reach the groin region through a persistent processus vaginalis or by re-opening the (partially) obliterated channel between the scrotum and the kidney. Of note, increased pressure in the inguinal canal might cause acute incarceration of a previously reducible inguinal hernia [6].

Clinical diagnosis of RAAA is difficult and often missed—especially in atypical presentations [6]. The pathognomonic triad (abdominal/back pain, hypotension, pulsatile abdominal mass) is present in no more than 75% of the cases [1]. In both our patients, general practitioner's initial diagnosis was a symptomatic inguinal hernia. Both cases finally turned out to be RAAA. This atypical presentation often undergoes erroneous preoperative management which frequently delays surgical treatment resulting in poor survival [10]. Thus we suggest, that patients with suspected symptomatic inguinal hernia combined with hypotension (leading to collapse) or the presence of blood in the spermatic cord while surgical hernia repair should immediately receive thoracoabdominal CTA for both diagnosing the RAAA and optimal preoperative planning. Likewise, patients with known abdominal aortic aneurysm and unclear presentation of spontaneous symptomatic hernia should at least undergo ultrasound in order to define the status of aneurysm and detect potential presence of retro-/intrapertitoneal haematoma.

In case of suspected rupture of AAA, one basic principle of management should implicitly be followed: hypotensive haemostasis—either through permissive hypovolemia or controlled hypotension. This important concept is meanwhile implemented in the University Hospital of Zurich algorithm for

treatment of RAAA [14]. Briefly, in patients with suspected or confirmed bleeding from RAAA it is recommended to lower the systolic blood pressure (SBP) to 70–90 mmHg. If the patient is hemodynamically unstable, either catecholamine therapy or fluids should be administered. The rationale for this strategy is a diminution of blood loss through the ruptured site reducing the need for transfusions and the risk reduction for coagulopathy and imminent abdominal compartment syndrome. Eventually, this concept reduces overall perioperative mortality [14,15]. In the first patient presented, restrictive fluid administration (2.5 l over 4.5 h) did not result in abdominal compartment syndrome—in contrast to the second patient, where the use of vasopressors and excessive colloidal resuscitation (5.5 l over 2.5 h) led to abdominal compartment syndrome. The postoperative course of second patient showed longer ICU as well as prolonged overall in-hospital stay.

Treatment of RAAA by endovascular mean showed no inferiority over open repair of RAAA in international randomized trials (AJAX, ECAR, IMPROVE), while it proved to be superior in collected world experience and meta-analyses [16,17]. The defined standard operating procedure and clear algorithm are basis for successful treatment with 30-day mortality of 17% (ZH). In literature, mortality rate in patients presenting with RAAA and symptomatic/incarcerated hernia treated by open surgery is comparatively high with up to 50% [2,3,8]. The main reasons for this high mortality consist in irreversible shock, anuria, continuous blood loss at suture line and sepsis with multisystem organ failure [3]. To our knowledge, we present the first two cases in literature with RAAA initially mimicking symptomatic groin hernia with subsequent repair by EVAR showing good long-term results.

Finally we heeded Haldipur et al. advice of not repairing the inguinal hernia at the same time as RAAA repair as this may contribute to an abdominal compartment syndrome—leading itself to further potentially life threatening complications and a possible disruption of the hernia repair [18].

4. Conclusion

Patients with known abdominal aortic aneurysm and unclear presentation of spontaneous symptomatic hernia should urgently undergo further diagnostics (e.g. ultrasound) to rule out a potential rupture of the aneurysm. If RAAA mimicking symptomatic groin hernia is present, CTA for diagnosis and preoperative planning is strongly recommended. Preoperative work-up should take into account the principles of hypotensive haemostasis. Endovascular aortic repair of the RAAA—if feasible—is the treatment of choice. Coinciding inguinal hernias should not be repaired at the same time as RAAA repair for the reason of lessening the risk of imminent abdominal compartment syndrome.

Conflicts of interest

There is no conflict of interest to declare.

Sources of funding

None.

Open Access

This article is published Open Access at sciedirect.com. It is distributed under the [IJSCR Supplemental terms and conditions](#), which permits unrestricted non commercial use, distribution, and reproduction in any medium, provided the original authors and source are credited.

Consent

Written informed consent was obtained from the patient for publication of this case report and accompanying images. A copy of the written consent is available for review by the Editor-in-Chief of this journal on request.

Author's contribution

Study design: Zoran Rancic.

Data collection: Holger Klein, Daniel Becker.

Writing: Holger Klein Zoran Rancic.

References

- [1] Y.W. Tsai, J.B. Blodgett, G.S. Wilson, R.J. Lucas, O.C. Tuncader, Ruptured abdominal aortic aneurysm. Pathognomonic triad, *Vasc. Surg.* 7 (4) (1973) 232–237.
- [2] E.W. Grabowski, D.B. Pilcher, Ruptured abdominal aortic aneurysm manifesting as symptomatic inguinal hernia, *Am. Surg.* 47 (7) (1981) 311–312.
- [3] H. Khaw, V.S. Sottiurai, C.C. Craighead, R.C. Batson, Ruptured abdominal aortic aneurysm presenting as symptomatic inguinal mass: report of six cases, *J. Vasc. Surg.* 4 (4) (1986) 384–389.
- [4] J.C. Louras, J.P. Welch, Masking of ruptured abdominal aortic aneurysm by incarcerated inguinal hernia, *Arch. Surg.* 119 (3) (1984) 331–332.
- [5] B. Lehnert, F. Wadouch, High coincidence of inguinal hernias and abdominal aortic aneurysms, *Ann. Vasc. Surg.* 6 (2) (1992) 134–137.
- [6] A. Banerjee, Atypical manifestations of ruptured abdominal aortic aneurysms, *Postgrad. Med. J.* 69 (807) (1993) 6–11.
- [7] J.T. Jenkins, P.J. O'Dwyer, Inguinal hernias, *BMJ* 336 (7638) (2008) 269–272.
- [8] R.F.J. Merchant Jr., H.T. Cafferata, R.G. DePalma, Pitfalls in the diagnosis of abdominal aortic aneurysm, *Am. J. Surg.* 142 (6) (1981) 756–758.
- [9] K. Moissinac, T. Boon Chong Se, N.C. Liew, G. Yunus, Abdominal aortic aneurysm rupture masquerading as strangulated inguinal hernia, *Am. J. Emerg. Med.* 19 (7) (2001) 604–605.
- [10] M.S. Nair, M.M. Uzzaman, T.A. Wahab, A. Athow, Incarcerated inguinal hernia: atypical presentation of an abdominal aortic aneurysm, *Hernia* 14 (6) (2010) 651–653.
- [11] L.W. Shockley, Ruptured abdominal aortic aneurysm presenting as bilateral symptomatic inguinal hernias, *Am. J. Emerg. Med.* 9 (5) (1991) 522–523.
- [12] E.A. Rettedal, O. Vennesland, Ruptured abdominal aortic aneurysm: a rare form of presentation, *Tidsskr Nor Laegeforen.* 113 (12) (1993) 1470.
- [13] G.A. Antoniou, I.K. Tentes, S.A. Antoniou, G.S. Georgiadis, A.D. Giannoukas, C. Simopoulos, et al., Circulating matrix metalloproteinases and their inhibitors in inguinal hernia and abdominal aortic aneurysm, *Int. Angiol.* 30 (2) (2011) 123–129.
- [14] D. Mayer, T. Pfammatter, Z. Rancic, L. Hechelhammer, M. Wilhelm, F.J. Veith, et al., 10 years of emergency endovascular aneurysm repair for ruptured abdominal aortoiliac aneurysms: lessons learned, *Ann. Surg.* 249 (3) (2009) 510–515.
- [15] D. Mayer, Z. Rancic, C. Meier, T. Pfammatter, F.J. Veith, M. Lachat, Open abdomen treatment following endovascular repair of ruptured abdominal aortic aneurysms, *J. Vasc. Surg.* 50 (1) (2009) 1–7.
- [16] F.J. Veith, M. Lachat, D. Mayer, M. Malina, J. Holst, M. Mehta, et al., Collected world and single center experience with endovascular treatment of ruptured abdominal aortic aneurysms, *Ann. Surg.* 250 (5) (2009) 818–824.
- [17] M. Mehta, J. Henretta, M. Glickman, D. Deaton, T.C. Naslund, B. Gray, et al., Outcome of the pivotal study of the Aptus endovascular abdominal aortic aneurysms repair system, *J. Vasc. Surg.* 60 (2) (2014) 275–285.
- [18] N. Haldipur, M. Donlon, S. Singh, J.D. Beard, Repairing hernias at the same time as ruptured abdominal aortic aneurysms may increase the risk of abdominal compartment syndrome, *Eur. J. Vasc. Endovasc. Surg.* 25 (3) (2003) 279–280.