



## Pull-through insertion of EndoArt for complex eyes

Mohammed M. Abusayf<sup>a,d</sup>, Gavin S. Tan<sup>a,b,c</sup>, Jodhbir S. Mehta<sup>a,b,c,\*</sup>

<sup>a</sup> Singapore National Eye Center, Singapore

<sup>b</sup> Tissue Engineering and Cell Therapy Group, Singapore Eye Research Institute, Singapore

<sup>c</sup> Ophthalmology Academic Clinical Program, Duke-NUS Graduate Medical School, Singapore

<sup>d</sup> Department of Ophthalmology, College of Medicine, King Saud University, Riyadh, Saudi Arabia

### ARTICLE INFO

#### Keywords:

EndoArt  
Complex eyes  
Descemet membrane endothelial keratoplasty (DMEK)  
Descemet stripping automated endothelial keratoplasty (DSAEK)

### ABSTRACT

**Purpose:** To report an alternative technique to implant the EndoArt using a pull-through insertion. This technique is helpful in complex eyes, especially in eyes with unstable iris lens diaphragm.

**Observation:** We present a case of advanced pseudophakic bullous keratopathy with aniridia, previous vitrectomy, and tube implants in which the initial attempt to implant the EndoArt failed, and the device was lost to the vitreous cavity. An alternative surgical technique, a pull-through insertion, was used to implant a second device successfully. The patient was followed over a period of 1 year. Corneal edema gradually improved over time, and all epithelial bullae resolved. The central corneal thickness (CCT) decreased from 911 μm to 691 μm.

**Conclusion and Importance:** EndoArt is a treatment for endothelial failure in complex eyes. In addition, the pull-through insertion technique can help improve control over the implant in very complicated eyes.

### 1. Introduction

Corneal endothelial decompensation is the leading indication for corneal transplantation.<sup>1</sup> The current gold standard in treatment is endothelial keratoplasty (EK).<sup>1</sup> However, endothelial failure remains higher in complex eyes such as aniridia, aphakia, post-glaucoma surgeries, complex anterior segment abnormalities, silicone oil in the anterior chamber (AC), previous corneal graft failure and/or post vitrectomy.<sup>2,3,6</sup> Primary and secondary graft failure rates have been reported to be around (11.5–44%) and (16–77%) in complex eyes undergoing EK.<sup>2,3,6,7</sup> In addition, with a global shortage of corneal donors, prolonged use of steroids, and complex surgical techniques required in such eyes for novice and experienced surgeons, particularly for DMEK, all of these are still challenges to be addressed.<sup>1–5</sup> The EndoArt (EyeYon Medical, Israel) is a device composed of a flexible, 50 μm thin artificial biomaterial that matches the cornea's posterior curvature and functions as a fluid barrier of the posterior stroma, replacing the diseased endothelium. It has shown promising results in cases of chronic corneal edema with an improved CCT.<sup>5</sup>

The published surgical technique to implant the EndoArt is either to use an intraocular lens (IOL) cartridge to inject the device through the main corneal wound into the AC as shown by Auffarth et al., or it can be inserted directly into the AC through the main corneal wound with a

sliding motion using a cyclodialysis spatula as shown in the instructional video on the manufacturer's web page.<sup>5,14</sup> This is followed by spreading out the device over the iris tissue. Then, a gas bubble is injected to support the adherence of the device. This technique is suitable for eyes with intact iris lens diaphragm. However, in more complex eyes, it might be challenging to implant the device into the AC without losing the device to the vitreous cavity or losing the correct orientation. In this case report, we report an alternative technique to implant the EndoArt using a pull-through insertion that might be helpful in complex eyes especially in eyes with unstable iris lens diaphragm.

### 2. Case report

A Forty-eight years old male was referred to the cornea service due to pseudophakic bullous keratopathy in his left eye. The patient was a known case of juvenile open-angle glaucoma in his right eye and traumatic aphakic glaucoma in his left eye. Between November 2009 to January 2011, he underwent multiple procedures to control the pressure in his left eye, including two transscleral cyclophotocoagulation (TCP), three glaucoma drainage implants (GDI) with revisions as well as pars plana vitrectomy (PPV) for inferior retinal detachment repair. In 2014, the patient underwent secondary IOL fixation of a single-piece foldable acrylic IOL (Acrysof, SA60AT, Alcon Inc, Fort Worth, Tex.) to the sclera

\* Corresponding author. Singapore National Eye Center, 11 Third Hospital Avenue, Singapore, 168751, Singapore.

E-mail address: [jodhbir.s.mehta@singhealth.com.sg](mailto:jodhbir.s.mehta@singhealth.com.sg) (J.S. Mehta).

<https://doi.org/10.1016/j.ajoc.2023.101878>

Received 15 March 2023; Received in revised form 29 May 2023; Accepted 13 June 2023

Available online 23 June 2023

2451-9936/© 2023 Published by Elsevier Inc. This is an open access article under the CC BY-NC-ND license (<http://creativecommons.org/licenses/by-nc-nd/4.0/>).

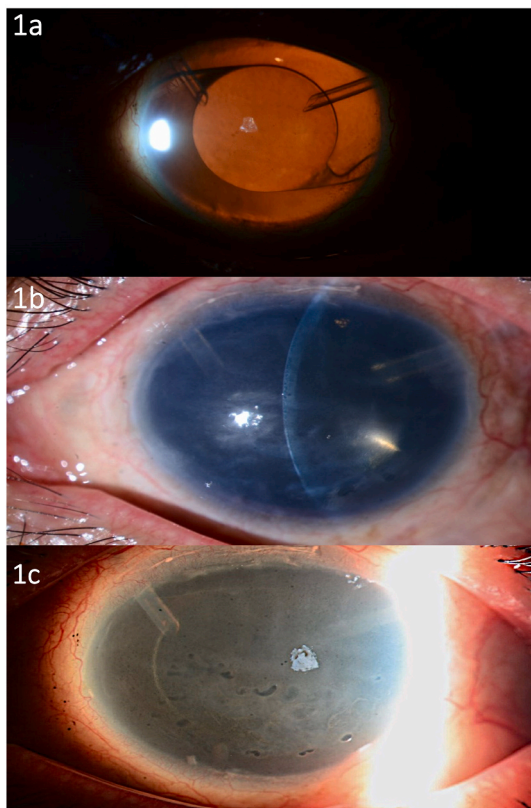
using 10-0 prolene sutures under nasal and temporal scleral flaps (Fig. 1a). In 2016, he had a third TCP procedure. All previous surgical interventions were done elsewhere prior to referral to our service.

On clinical exam, intraocular pressure (IOP) was controlled in both eyes. Vision was 20/25 and counting fingers (CF) in the right and left eye, respectively. Slit lamp (SL) exam of the right eye showed a superior cystic bleb, clear cornea, deep quiet AC, and early cataract. Left eye showed inferior epithelial bullae, diffuse significant stromal edema with minimal stromal scarring, DM folds and deep AC. A scleral fixated IOL (SFIOL) was centered, with no apparent tilt, with one superior nasal tube in front of the lens and one superior temporal tube behind the lens, and with traumatic aniridia, no tube corneal touch was evident with (Fig. 1b and c). The right eye vertical cup to disc ratio (C/D) was 0.8. While the view to the left eye posterior pole was hazy but the retina was grossly flat with advanced disc cupping. 24-2 Humphrey visual field of the left eye had previously shown an advanced field defect. CCT in the left eye measured 911  $\mu\text{m}$ . The visual potential in the left eye was 20/100. Retrieval of his previous medical records has shown that the SFIOL was stable for many years. After detailed consultation, the patient agreed to undergo implantation of the EndoArt.

Surgical Technique (Video 1).

Supplementary video related to this article can be found at <https://doi.org/10.1016/j.ajoc.2023.101878>

A 7 mm corneal marking was applied to the central corneal surface to outline the peripheral extent of Descemet's membrane (DM) excision. Epithelial debridement was performed to improve visualization. Two paracentesis incisions were made at 1 o'clock and 5 o'clock, and a 2.6-mm clear corneal incision was made at 3 o'clock. An AC maintainer was inserted into the AC through the 5 o'clock paracentesis. Using a reverse Sinsky hook, the DM was scored and peeled from the posterior stroma



**Fig. 1.** Preoperative SL photos of the left eye.  
a) Prior to corneal decompensation in 2015. Retroillumination technique showing a clear cornea, scleral fixated single piece IOL and two tube implants.  
b) After decompensation in May 2022. Slit. c) After decompensation. Sclerotic scatter.

through the 1 o'clock paracentesis under BSS, creating a 7.0-mm descemetorhexis. DM was removed through the main wound. The superior nasal tube was flushed with air to tamponade against early loss of gas postoperatively.

EndoArt was held using Kelman Mcpherson forceps and spread over the cornea to ensure correct orientation through an irreversible F letter. In addition, the polarity of the device can be used in which the concave surface must face toward the vitreous cavity. The device was inserted into the AC through the main corneal wound with a sliding motion using a cyclodialysis spatula up against (Fig. 2, d). The AC maintainer flow was reduced. A reverse Sinsky hook was used to assist the unfolding of the device through the 1 o'clock paracentesis. However, once fully unfolded in the center of the AC, the AC maintainer flow in addition to loss of purchase with the reverse Sinsky hook, allowed the device to move to inferior nasal side of the AC. With no iris or lens support in this area, the device escaped into the vitreous cavity (Fig. 2).

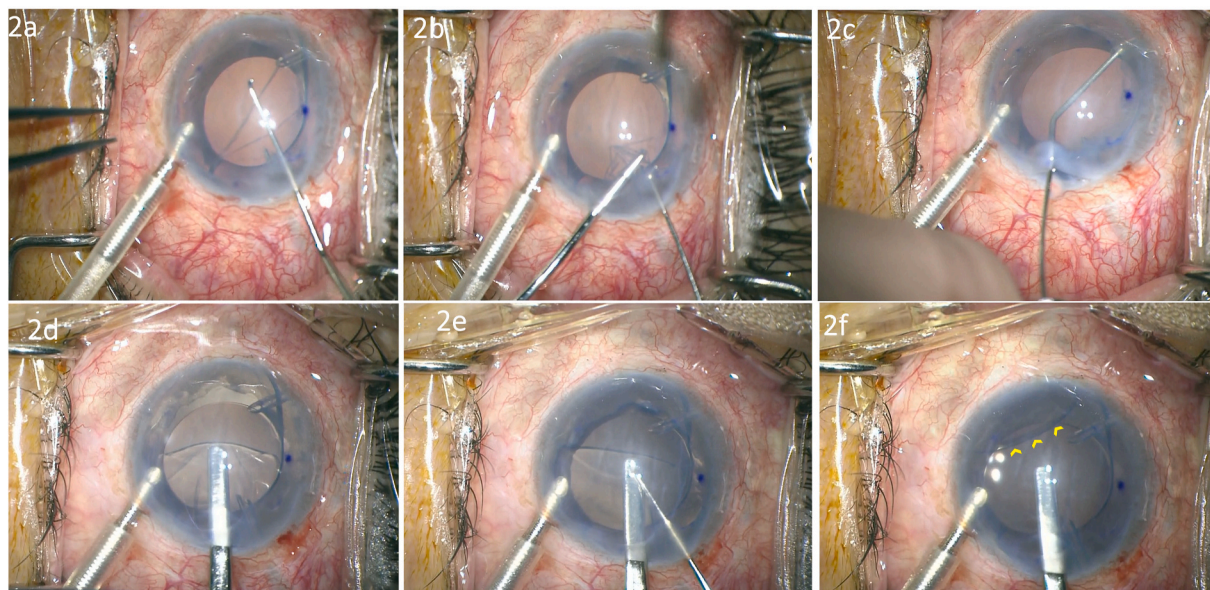
A nasal paracentesis was created at 3 o'clock. A second EndoArt was spread on the cornea to ensure correct orientation using the above mentioned methods. Then, using a cyclodialysis spatula up against the device, the nasal edge of the implant was inserted into the AC just beyond the inner lips of the main wound. A 27 gauge curved DMEK forceps (ASICO, AE-4937) was introduced through the nasal paracentesis to grab the device at the nasal edge. After that, the device was pulled into the AC. Once fully inserted into the AC, the EndoArt was held in the desired place and the correct orientation till an air bubble was injected, with the AC maintainer turned off. Following, the implant was released gently (Fig. 3, a-c). One 10-0 Nylon suture was used to anchor the device to the stroma. The main wound was secured with one suture. Finally, Air 12% C3F8 exchange was done (Fig. 3, d-f).

At one day postoperatively, the EndoArt was partially detached, part of the gas bubble had escaped to the vitreous cavity, and the SFIOL was subluxated inferiorly. The patient was booked for PPV to remove the dislocated EndoArt, fixate the IOL, and rebubbling on the same day. Intraoperatively, three 25 gauge trans pars plana trocars were placed. The dislocated EndoArt implant to the vitreous cavity was elevated to the AC and removed through a corneal paracentesis. Next, the nasal haptic was elevated into the AC. A nasal scleral flap was created 180° aligned with the temporal in place haptic suture complex. CV-8 Poly-tetrafluoroethylene (ePTFE) derived Gore-tex suture was used to lasso the nasal haptic in a 2-2-2 knot. Afterward, the suture was externalized, 3 mm behind the limbus, under the nasal scleral flap. Tension and centration were adjusted. The flap was secured to the bed using one 10-0 nylon suture. Trocars were removed. All sclerotomies, peritomy, and corneal wounds were closed and secured with sutures. Finally, three adjunctive 10-0 nylon sutures were placed to anchor the partially detached EndoArt to the corneal stroma and improve adherence. Finally, 12% C3F8 was injected to fill the AC. A bandage contact lens was placed at the end of the procedure. On the next day, the EndoArt was attached and in the correct orientation, and the IOL was in place.

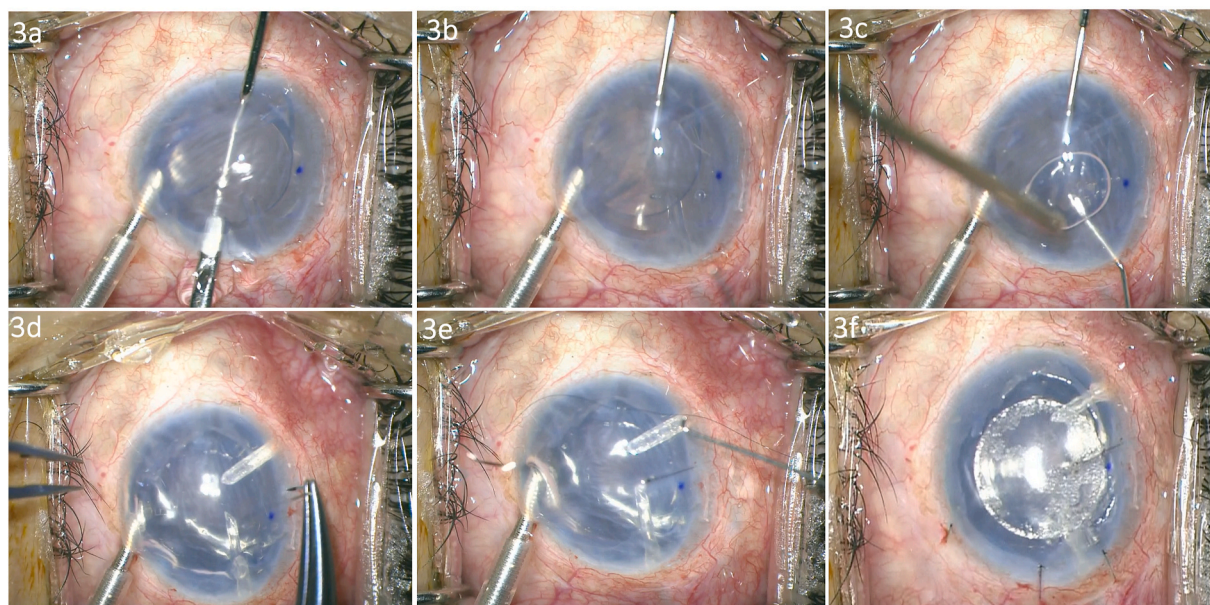
The postoperative topical regimen included a topical antibiotic drop four times daily for two weeks and a low-dose corticosteroid drop four times daily as a long term treatment. This study adhered to the tenets of the Declaration of Helsinki and was approved by the Institutional Review Board/Ethics Committee at the Singapore National Eye Center.

### 3. Results

The patient was followed over 1 year. Corneal edema gradually improved over time, and all epithelial bullae resolved. Intraocular pressure was controlled over all visits. Three 10-0 Nylon anchoring sutures were removed at month 3 (Fig. 4a). The last suture was removed at month 4 (Fig. 4b). At month 7, visual acuity improved to 20/400 with glasses and 20/100 with pinhole (PH). On the last visit, Month 12, SL exam of the left eye exam showed mild corneal edema, deep AC, attached centered and in the correct orientation EndoArt (Fig. 4, c). The CCT decreased from 911  $\mu\text{m}$  to 691  $\mu\text{m}$ . Peripheral corneal thickness also



**Fig. 2.** Intraoperative photos. A pushing technique is used to deliver the device into the AC. a) Descemetorhexis. b) DM removal. c) Tube flushing with air. d) The implant is pushed into the AC using a cyclodialysis spatula. e) Reverse Sinskey hook to assist in unfolding. f) The implant is dislocated to the inferior nasal side of the AC (arrowheads).



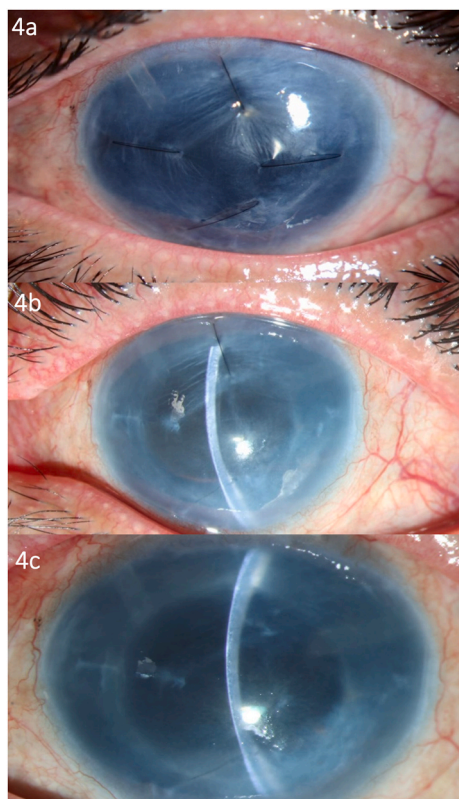
**Fig. 3.** Intraoperative photo showing the pull-through technique. a) An intraocular forceps is pulling the device into the AC. b) Endoart is held in the desired place and the correct orientation. c) Air bubble support before the implant is released. d) Nylon suture is used to anchor the implant to the stroma. e) Anchoring suture is in place. f) Full gas fill.

improved, as evident on optical coherent tomography (OCT) (Fig. 5, a-e).

**4. Discussion and conclusion**

DSAEK surgery evolved from Taco folding to pull-through insertion.<sup>10</sup> Taco folding techniques have the disadvantage of tissue apposition, inversion of the graft, higher endothelial cell loss, loss of AC, and iris prolapse, especially in eyes with shallow anterior chambers.<sup>9,11,13</sup> Alternative surgical techniques and devices (e.g., suture pull-through, Busin glide, sheets glide, and Endoglide) were introduced to overcome the abovementioned difficulties, using a pull-through insertion.<sup>8,9</sup>

Though they allowed for smooth controlled delivery of an unfolded graft into the AC, they did not prevent tissue damage against a small wound. The Busin glide is typically used as a carrier, to pull the graft through the corneal incision, the Endoglide, a modified sheet glide, was designed to further overcome the inherent problems with the previously mentioned techniques.<sup>9</sup> DMEK is the most advanced EK surgery.<sup>12</sup> Current methods of DMEK graft insertion can be divided, based on graft orientation insertion into the AC, endothelium-in, or endothelium-out.<sup>1</sup> Surgical devices used in all these methods protect the DMEK graft from the small surgical wound. This revolution in EK surgery has reduced graft failure rates and widened the indication for EK in complex eyes (1, 6, 8). However, survival rates are still inferior to ‘normal’ eyes (2). EndoArt is

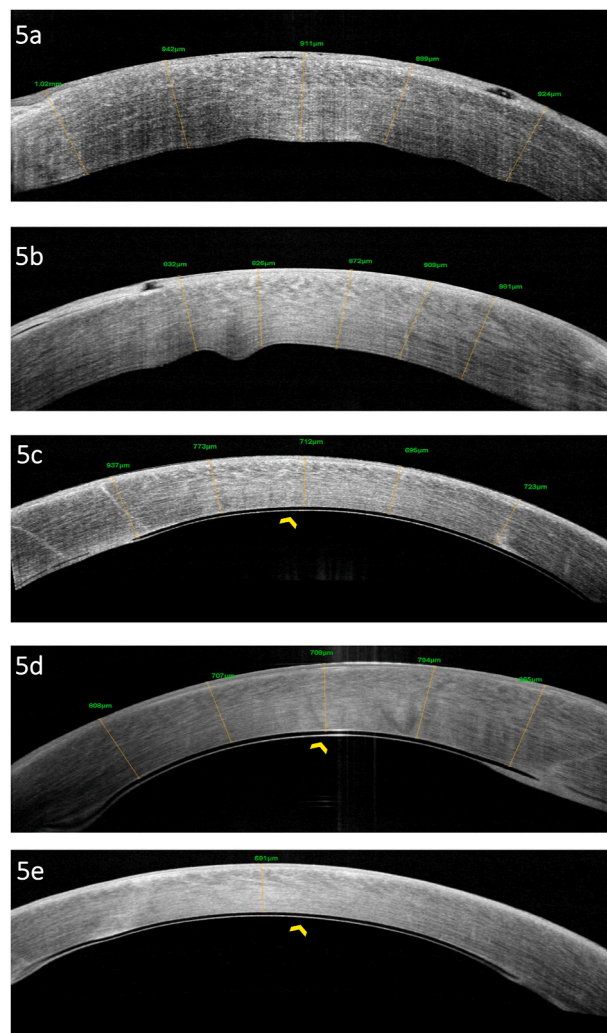


**Fig. 4.** Postoperative SL photos of the left eye. a) Postoperative Month 3. Diffuse illumination. Four anchoring sutures in place, resolved epithelial bullae. b) Postoperative Month 4. Slit. One anchoring suture remained, improved corneal thickening and attached EndoArt. c) Postoperative month 12. Slit. Attached EndoArt without anchoring sutures, notice complete resolution of sutures related distortion.

a clear artificial water-impermeable device. It is optically clear, biocompatible, and biostable. The implant is made of the same material as a hydrophilic acrylic IOL. This gives the implant the advantage of being easily manipulated and more tolerant to damage. Instead of actively pumping the fluid out of the cornea, it reduces the net flow of fluid into the cornea, where the excess fluid then evaporates through the epithelial layer.

There was a rapid reduction of CCT in the previously published two cases. At 17 months of follow-up, the CCT reduced by 28% and 40%, respectively. In our case, the CCT reduced by around 24% in one year. Interestingly reduction was noted in the peripheral corneal thickness, as well as central, as was evident on OCT. Due to the advanced optic neuropathy from glaucoma, the maximum visual acuity achieved with correction was 20/100. In the previous two published cases, an asymptomatic inferior detachment was noticed at three weeks and six months and treated with air tamponade (5). In our case, implant detachment was noticed on day one and treated with gas injection. However, due to the complexity of our case, maintaining adequate gas tamponade was a significant obstacle, which is needed for good EndoArt tamponade. Hence, we elected to support the device attachment with additional anchoring sutures. Due to the difficulty in controlling suture tension in a soft eye, a significant distortion from the tight anchoring sutures was noticed postoperatively. However, the implant is resilient to damage, and the indentation entirely resolved once the sutures were removed and the edema improved (Fig. 4b and c). It is essential to notice that the primary purpose of the anchoring sutures is to hold the EndoArt in place rather than kink it against the posterior stroma.

Although IOL subluxation was noted at the end of the first surgery, given the size of the EndoArt, and the unavailability of a vitreoretinal



**Fig. 5.** OCT. a) Preoperative, horizontal cut. b) Preoperative, vertical cut. c) Postoperative, month 8, horizontal cut. d) Postoperative, month 8, vertical cut. e) Postoperative, 1 year, horizontal cut. EndoArt is firmly adherent to the posterior surface of the cornea (arrowhead, 5 c-e).

surgeon, a decision was made not to fixate the IOL, at the time, to allow easy retrieval of the device through levitation into the AC. Additionally, the same IOL was fixated to avoid further manipulation, wound enlargement, and due to limited intraocular view secondary to corneal edema. We do not advocate for fixation of such IOL.

In complex eyes, especially unstable iris lens diaphragm with poor surgical view, the implant might flip or even descend into the vitreous cavity, which puts the patient at risk of a second surgical intervention or even a PK to improve the view for the retina surgeon to retrieve the implant. In such cases we propose a pull-through technique to insert the implant into the AC. Using intraocular forceps to pull in the device allowed the surgeon to control the centration, ensure orientation and have control on the device till gas tamponade was complete. Anchoring sutures can then be used to anchor the implant to the stroma, similar to our case report. In conclusion, EndoArt is a potential treatment for endothelial failure in complex eyes. In addition, pull-through insertion and suture anchoring are surgical techniques to help improve control over the implant in very complicated eyes.

**Patient consent**

Consent to publish the case report was obtained. This report does not

contain any personal information that could lead to the identification of the patient.

### Funding

There is no funding or grant support.

### Authorship

All authors attest that they meet the current ICMJE criteria for Authorship.

### Declaration of competing interest

The authors declare that they have no known competing financial interests or personal relationships that could have appeared to influence the work reported in this paper.

### References

- Ong HS, Htoon HM, Ang M, Mehta J. 'Endothelium-Out' and 'endothelium-In' Descemet membrane endothelial keratoplasty graft insertion techniques: a systematic Review with meta-analysis. *Front Med.* 2022 Jun 14;1588.
- Siddiqui A, Chamberlain WD. Descemet membrane endothelial keratoplasty in complex eyes. *Curr Opin Ophthalmol.* 2022 Jul 1;33(4):324–331.
- Santaella G, Sorkin N, Mimouni M, et al. Outcomes of Descemet membrane endothelial keratoplasty in aphakic and aniridic patients. *Cornea.* 2020 Nov 1;39(11):1389–1393.
- Stuart AJ, Romano V, Virgili G, Shortt AJ. Descemet's membrane endothelial keratoplasty (DMEK) versus Descemet's stripping automated endothelial keratoplasty (DSAEK) for corneal endothelial failure. *Cochrane Database Syst Rev.* 2018;6.
- Auffarth GU, Son HS, Koch M, et al. Implantation of an artificial endothelial layer for treatment of chronic corneal edema. *Cornea.* 2021 Dec;40(12):1633.
- Daubert J, O'Brien TP, Adler E, Spierer O. Outcomes of complex Descemet stripping endothelial keratoplasty performed by cornea fellows. *BMC Ophthalmol.* 2018 Dec; 18(1):1–6.
- Mimouni M, Sorkin N, Slomovic J, et al. Descemet membrane endothelial keratoplasty versus Descemet stripping automated endothelial keratoplasty in complicated vitrectomized eyes. *Curr Eye Res.* 2021 Sep 2;46(9):1283–1290.
- Khor WB, Teo KY, Mehta JS, Tan DT. Descemet stripping automated endothelial keratoplasty in complex eyes: results with a donor insertion device. *Cornea.* 2013 Aug 1;32(8):1063–1068.
- Khor WB, Mehta JS, Tan DT. Descemet stripping automated endothelial keratoplasty with a graft insertion device: surgical technique and early clinical results. *Am J Ophthalmol.* 2011 Feb 1;151(2):223–232.
- Bahar I, Kaiserman I, Sansanayudh W, Levinger E, Rootman DS. Busin guide vs forceps for the insertion of the donor lenticule in Descemet stripping automated endothelial keratoplasty. *Am J Ophthalmol.* 2009 Feb 1;147(2):220–226.
- Mehta JS, Por YM, Poh R, Beuerman RW, Tan D. Comparison of donor insertion techniques for Descemet stripping automated endothelial keratoplasty. *Arch Ophthalmol.* 2008 Oct 13;126(10):1383–1388.
- Stuart AJ, Romano V, Virgili G, Shortt AJ. Descemet's membrane endothelial keratoplasty (DMEK) versus Descemet's stripping automated endothelial keratoplasty (DSAEK) for corneal endothelial failure. *Cochrane Database Syst Rev.* 2018;6.
- Tan D, Ang M, Arundhati A, Khor WB. Development of selective lamellar keratoplasty within an Asian corneal transplant program: the Singapore corneal transplant study (an American Ophthalmological Society thesis). *Trans Am Ophthalmol Soc.* 2015 Sep;113.
- EyeYon Medical. EndoArt [internet]. Ness ziona, Israel. Available from: <https://eye-yon.com/endoart/>.